

Macular changes among adult Egyptian patients with pathological myopia

Mona Nabeh Mansour, Hend Mohammed Safwat

Department of Ophthalmology, Faculty of Medicine for Girls, Al-Azhar University, Cairo Governorate 11884, Egypt

Correspondence to: Hend Mohammed Safwat. Department of Ophthalmology, Faculty of Medicine for Girls, Al-Azhar University, Cairo Governorate 11884, Egypt. hendsafwat.2053@azhar.edu.eg

Received: 2025-10-16 Accepted: 2026-02-10

Abstract

• **AIM:** To investigate macular changes characteristics among adults with high myopia in Egypt, and to evaluate the relationship between the degree of myopia and the extent of macular alterations.

• **METHODS:** A series of highly myopic eyes with axial length (AL) ≥ 26.0 mm and/or spherical equivalent (SE) ≤ -6.0 D were included. All subjects underwent automated refraction, correction of refractive error, AL measurement, and optical coherence tomography (OCT) for macular scanning. Myopic maculopathy (MM) for each eye was recorded, and their association with age, refractive error, and AL was determined.

• **RESULTS:** Among the 427 eyes (mean SE: -11.11 ± 4.34 D, mean AL: 27.84 ± 1.66 mm) of 250 subjects (77 males, mean age 56.84 ± 12.19 y), all had tigroid fundus (A1, ATN classification of MM), associated macular lesions were chorioretinal atrophy [C-R atrophy; 8.47% diffuse C-R atrophy (A2), 11.0% patchy C-R atrophy (A3)]. Neovascular MM was: lacquer cracks in (N1) 1.64%, myopic choroidal neovascularization [mCNV; 6.09% active CNV (N2a), 19.20% choroidal neovascular membrane (N2b)], myopic traction maculopathy (MTM) in 11.48%, macular hole (MH; 3.98% lamellar MH, 2.34% full thickness MH). Older age was associated with MTM, MH, and lacquer cracks ($P=0.004$, $P=0.025$, $P=0.013$). More myopic SE was associated with increased odds of atrophic MM, neovascular MM, and MTM ($P<0.001$, $P<0.001$, $P=0.002$). Increased AL was associated with increased odds of atrophic MM, neovascular MM, and dome shape macula ($P=0.049$, $P=0.037$, $P=0.001$). In the multivariable linear mixed model with adjustment of age, gender and SE: the presence of atrophic MM ($P<0.001$), neovascular MM ($P<0.001$) were significantly associated with poorer best corrected visual acuity (BCVA).

• **CONCLUSION:** Among adult Egyptian patients with high myopia: age, more myopic SE and longer AL are associated with increased odds of MM. Atrophic or neovascular MM is associated with poorer visual acuity.

• **KEYWORDS:** pathological myopia; atrophic myopic maculopathy; neovascular myopic maculopathy; myopic traction maculopathy; macular hole; Egypt

DOI:10.18240/ijo.2026.07.18

Citation: Mansour MN, Safwat HM. Macular changes among adult Egyptian patients with pathological myopia. *Int J Ophthalmol* 2026;19(7):1366-1373

INTRODUCTION

Myopia is a global health issue that causes visual impairment throughout the world. High myopia (HM) is defined as a spherical equivalent (SE) ≤ -6.0 D or as an axial length (AL) ≥ 26.0 mm^[1]. Pathologic myopia (PM) is defined as HM associated with excessive axial elongation leading to structural changes in the posterior segment of the eye including posterior staphyloma, myopic maculopathy, and optic neuropathy. PM causes vision impairment or blindness in 0.2%–1.5% of Asians and 0.1%–0.5% of Caucasians^[2].

Globally, PM found to affect 2.8% in 2010, it is estimated to affect 10.0% of the world's population by 2050^[3]. Regarding PM in Egypt, earlier study reported PM prevalence was 0.2%^[4], whereas more recent studies reported that it was 7.4%–10.9%^[5-7]. This means a possible dramatic increase in the prevalence of PM in Egypt over time.

Myopic macular degeneration (MMD) is a complex disease, and its diagnosis and follow-up give accurately to monitor changes over time because of the progressive nature of this condition^[8-9]. Ohno-Matsui *et al*^[10] developed a systematic classification based on a Meta-analysis of pathologic myopia (META-PM), with 5 different categories of myopic maculopathy: no myopic retinal lesions (category 0), tessellated fundus only (category 1), diffuse chorioretinal atrophy (C-R Atrophy; category 2), patchy C-R atrophy (category 3), and macular atrophy (category 4). The presence of lacquer cracks, myopic choroidal neovascularization (mCNV), and Fuch's spot was added as plus sign. The new

ATN classification of myopic maculopathy (MM) was based on three faces of the disease: atrophic MM (A0, no myopic retinal lesions; A1, tessellated fundus only; A2, diffuse C-R atrophy; A3, patchy C-R atrophy; A4, complete macular atrophy), neovascular MM (N0, no mCNV; N1, macular lacquer cracks; N2a, active CNV; N2b, scar or Fuch's spot), and tractional MM (T0, no macular schisis; T1, inner or outer foveoschisis; T2, inner+outer foveoschisis; T3, foveal detachment; T4, full-thickness macular hole; T5, macular hole+retinal detachment)^[8].

To our knowledge using international classifications (*e.g.*, ATN classification) plus imaging-based endpoints is not yet consistent across local work, this limits pooling of data and Meta-analysis. The present study aims to investigate the prevalence and characteristics of macular changes among adults with PM attending the ophthalmology clinic, Al-Zahraa University Hospital, Egypt, and to evaluate the relationship between the degree of myopia and the extent of macular alterations.

PARTICIPANTS AND METHODS

Ethical Approval Ethical approval (No.1748) was obtained from the Research Ethics Committee of the Faculty of Medicine, Al-Azhar University in accordance with the Declaration of Helsinki, 2013. Written informed consent was obtained from all participants.

This prospective, cross-sectional study was conducted over a period of 1y among individuals with PM ($SE \leq -6.0$ D) in one or both eyes, who were recruited from the Ophthalmology Outpatient Clinic of Al-Zahraa University hospital, age ≥ 25 y. The excluded subjects from this study were patients with history of ocular trauma, ocular surgery other than cataract, diabetic retinopathy, drusen, or media opacity that gives poor-quality optical coherence tomography (OCT) images. Each eye had full ophthalmological examination including the best corrected visual acuity (BCVA), slit-lamp examination, intraocular pressure (IOP) measured by Goldmann applanation tonometry, fundus examination after pupil dilatation by slit lamp bio microscopy with the 90 D lens and indirect ophthalmoscopy with the 20 D lens. NIDEK auto-refractor (ARK-510A; NIDEK Corp., Tokyo, Japan) was used for non-cycloplegic refraction. SE was calculated as the spherical value of the refractive error plus half of the cylindrical value. AL was measured by the AL-scan (Nidek Co. Ltd., Gamagori, Japan). Sonomed A scan ultrasonography PacScan 300A (Escalon, Ardmore, PA, USA) was used to measure the AL in the presence of staphyloma: five scans were done for each eye and the average value was documented. All myopic eyes were assessed with the spectral-domain optical coherence tomography (SD-OCT; Spectralis[®], Heidelberg Engineering, Germany). After adequate pupil dilation, image acquisition of the macula performed using a 6-mm-length high-resolution

scan using the radial scan modality, centered to the foveola and acquisitions were repeated if needed to obtain high-quality images. The images with poor signal strength < 6 were excluded. Specification of each myopic macular finding in this study was by agreement of 2 retinal consultants. The definite diagnosis was based on both fundus examination and OCT. We used ATN classification of MM^[8].

The eye was considered to have MMD if atrophic MM (A2, A3, or A4), neovascular MM (N1, N2a, or N2b), or tractional MM (T1, T2, T3, or T4).

Myopic traction maculopathy (MTM) is difficult clinically to be diagnosed, so we depend on SD-OCT findings in MTM (Figure 1).

Macular hole (MH) is difficult by biomicroscopic identification in HM eyes, due to several factors such as: the typical low contrast between the anatomical foveal defect and the retinal pigment epithelium (RPE), the C-R atrophy, or the presence of a deep posterior staphyloma. It should be confirmed by OCT as full thickness defect in neurosensory retina (FTMH) or inner layers of retina (lamellar).

Dome shaped maculopathy (DSM) is an inward bulge of the macula within the concavity of a posterior staphyloma in HM eyes based on OCT observations (Figure 2) as suggested by Gaucher *et al*^[11].

C-R atrophy is either diffuse or patchy. Diffuse C-R atrophy is observed as ill-defined yellowish lesion and OCT shows a marked thinning of the choroid in the area of diffuse atrophy. Patchy C-R atrophy (Figure 3) is observed as a grayish-white, well-defined atrophy, and OCT shows that in addition to the absence of the entire thickness of the choroid, the RPE as well as outer retina. The hyper-reflectivity in deep tissue due to an increased light penetration is noted in the area of patchy atrophy.

mCNV is either grayish membrane subretinal lesion with hyperpigmented borders or macular hemorrhage clinically. OCT shows either active mCNV (Figure 4) as medium reflective sub retinal lesion with irregular contour, internal limiting membrane (ILM) disruption, minimal intra-retinal and sub-retinal fluids, and subretinal hyper-reflective material, or CNV membrane (CNVM; Figure 5) that resembles inactive form. CNVM appears on OCT by high reflective subretinal lesion with regular contour and thin choroid.

Lacquer cracks are fine, irregular, yellow lines, often branching and crisscrossing. Stereoscopically are somewhat depressed compared to the surrounding retina. Larger choroidal vessels frequently traverse the lesions posteriorly. OCT finding shows the discontinuities of RPE and deep penetrance of the light signal at the corresponding site of lacquer cracks (Figure 6).

Statistical Analysis Data were coded and entered using the statistical package for the Social Sciences (SPSS) version

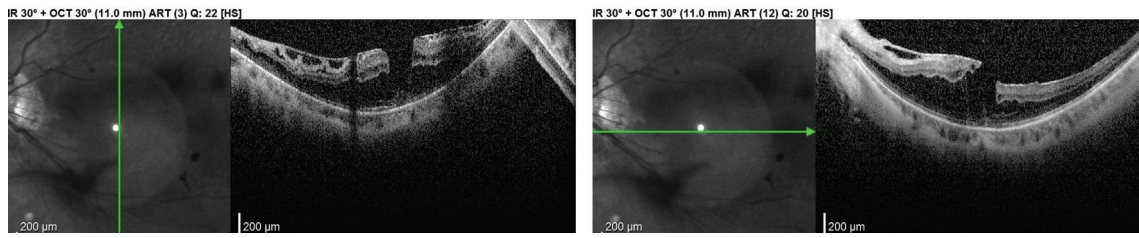


Figure 1 SD-OCT shows epi-retinal membrane with corrugated retinal surface and schitic changes (MTM) with lamellar macular hole SD-OCT: Spectral-domain optical coherence tomography; MTM: Myopic traction maculopathy.

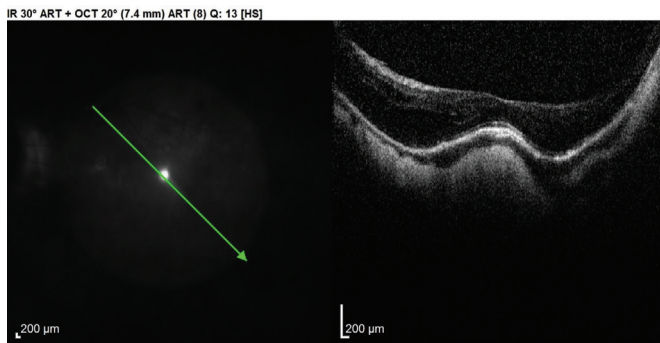


Figure 2 B scan of OCT shows inward bulging of macula and sub-retinal fluid (dome-shaped maculopathy) OCT: Optical coherence tomography.

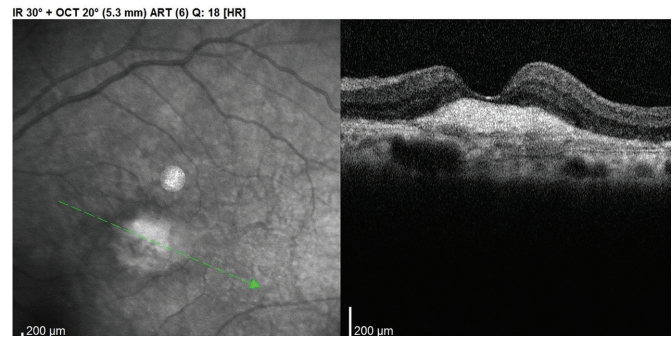


Figure 5 SD-OCT shows CNV membrane in myopic macula that is characterized by high hyper-reflectivity and absence of intra- or sub-retinal fluids SD-OCT: Spectral-domain optical coherence tomography; CNV: Choroidal neovascularization.

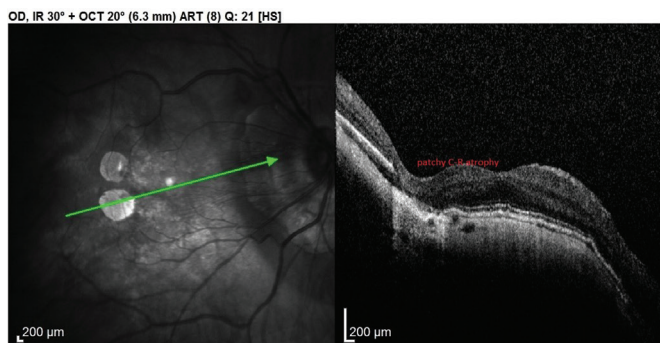


Figure 3 SD-OCT shows well defined area of outer retina and choroid absence (patchy C-R atrophy) SD-OCT: Spectral-domain optical coherence tomography.

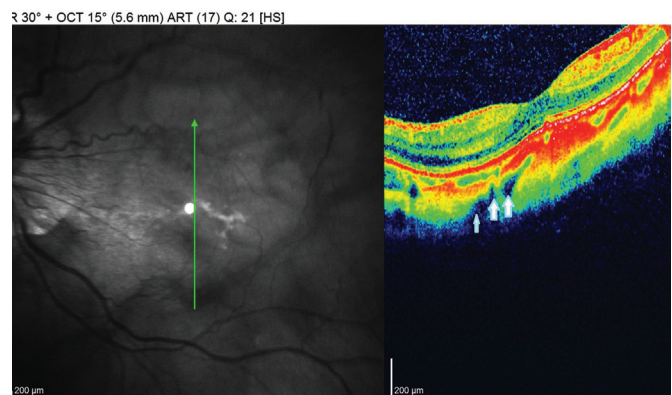


Figure 6 SD-OCT B scan in macular lacquer crack shows perforating scleral vessels (arrows) SD-OCT: Spectral-domain optical coherence tomography.

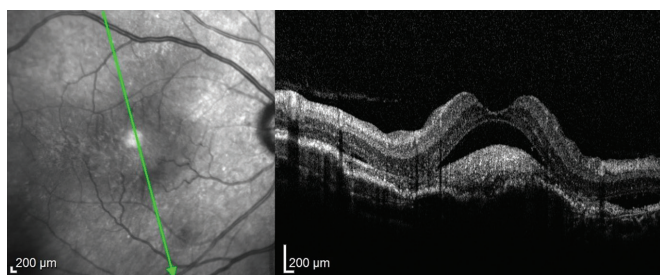


Figure 4 SD-OCT B scan in myopic macula that shows sub-retinal hyper-reflective lesion associated with sub-retinal fluid (active mCNV) SD-OCT: Spectral-domain optical coherence tomography; mCNV: Myopic choroidal neovascularization.

groups were done using unpaired *t*-test. For comparing categorical data, Chi-square (χ^2) test was performed. Logistic regression was done to detect independent predictors of fundus changes. The association between fundus changes and BCVA was assessed by multivariable linear mixed model with adjustment of age, gender, SE, and AL. *P*-values less than 0.05 were considered as statistically significant.

RESULTS

A total of 427 eyes from 250 participants, who had high myopia ($SE \leq -6.0$ D) in either eye at the first visit, had been included in this study. The mean age of participants was 56.84 ± 12.19 years old (range, 25–75y); females were the majority (69.20%). The mean SE of eyes was -11.11 ± 4.34 D (range, -6 to -20.0 D), and mean AL was 27.84 ± 1.66 mm (range,

28 (IBM Corp., Armonk, NY, USA). Data was summarized using mean and standard deviation for quantitative variables and frequencies (number of cases) and relative frequencies (percentages) for categorical variables. Comparisons between

26.0–32.1 mm). Mean BCVA (logMAR) for participants was 1.09±0.5 (range, 0–2.6).

All 427 eyes had tigroid fundus (A1, ATN classification of MM), associated macular lesions were C-R atrophy in about 20% of eyes [8.47% diffuse C-R atrophy (A2), 11.0% patchy C-R atrophy (A3)]. Neovascular MM was: lacquer cracks in (N1) 1.64%, mCNV in 25.29% of eyes [6.09% active CNV (N2a), 19.20% CNVM (N2b)]. MTM was 11.48%. MH in all myopic eyes (either associated with MTM or not) was 6.32% (3.98% lamellar MH, 2.34% FTMH). DSM was present in 4.45% (Table 1).

Multiple macular pathologies were noticed: CNVM (N2b) associated diffuse C-R atrophy (A2) in 24 eyes and associated patchy C-R atrophy (A3) in 32 eyes; among the 49 eyes with MTM, 1 eye had associated FTMH (T4), 10 eyes had lamellar MH.

In multivariable logistic regression, there is a tendency for increasing age to be associated with MTM ($P=0.004$), MH ($P=0.025$) and lacquer cracks ($P=0.013$), and marginal with DSM ($P=0.060$). More myopic SE was associated with increased odds of atrophic MM ($P<0.001$), neovascular MM ($P<0.001$), and MTM ($P=0.002$). Increased AL was associated with increased odds of atrophic MM ($P=0.049$), neovascular MM ($P=0.037$), and DSM ($P=0.001$). Female gender was nonsignificant ($P>0.05$) with any tendency of specific myopic macular pathology (Table 2).

In the multivariable linear mixed model with adjustment of age, gender, and SE: the presence of Atrophic MM ($P<0.001$) or neovascular MM ($P<0.001$) were significantly associated with poorer BCVA (Table 3).

DISCUSSION

Awareness of degenerative myopia and its complications, either macular or peripheral, has been increased worldwide. Multiple factors, such as genetic and environmental have a role in the aetiology and progression of PM^[12]. Comprehensive assessment of macular changes in patients with PM facilitates early detection and appropriate management of retinal complications as mCNV, MH^[13]. In our study, we investigated the prevalence of MM among adults with PM attending the ophthalmology clinic, Al-Zahraa University Hospital, Egypt, and studied the relationship between the degree of myopia and the extent of macular alterations.

We found that atrophic MM (A2, A3) was about 19.47%. A similar study done in Egypt^[14], showed that diffuse C-R atrophy (A2) was present in 40.9% of eyes, and patchy C-R atrophy (A3) was present in 18.9%. We think that their result overestimated due to multiple factors: less number in their study (127 eyes of 77 patients), longer AL (30.4±2.3), more SE (-20.3±3.4). Other studies revealed similar results to us; Adults 40 years and older ($n=359$) with HM were pooled from

Table 1 Demographic and macular changes in participants with pathological myopia

Parameters	Data
Age, mean±SD	56.84±12.19
Gender, <i>n</i> (%)	
Male	77 (30.80)
Female	173 (69.20)
Eye, <i>n</i> (%)	
OD	226 (52.93)
OS	201 (47.07)
SE, mean±SD	-11.11±4.34
AL, mean±SD	27.84±1.66
Myopic macular changes, <i>n</i> (%)	
Atrophic MM	
Diffuse C-R atrophy (A2)	36 (8.47)
Patchy C-R atrophy (A3)	47 (11.0)
Neovascular MM, <i>n</i> (%)	
Lacquer cracks (N1)	7 (1.64)
CNV (N2a)	26 (6.09)
CNVM (N2b)	82 (19.20)
MTM (T1, T2, T3), <i>n</i> (%)	49 (11.48)
MH, <i>n</i> (%)	
LMH	17 (3.98)
FTMH	10 (2.34)
DSM, <i>n</i> (%)	19 (4.45)

SD: Standard deviation; OD: Right eye; OS: Left eye; SE: Spherical equivalent; AL: Axial length; MM: Myopic maculopathy; C-R atrophy: Choriorretinal atrophy; CNV: Choroidal neovascularization; CNVM: Choroidal neovascular membrane; MTM: Myopic traction maculopathy; MH: Macular holes; LMH: Lamellar macular hole; FTMH: Full thickness macular hole; DSM: Dome shape macula.

3 population-based surveys in Singapore Asians, C-R atrophy was found in 19.3%^[15]. Du *et al*^[16] study, Tokyo Medical and Dental University, reported that 667 out of 6349 highly myopic eyes (10.5%) had patchy C-R atrophy, (28.3%) of them in the macular area. In contrast to our results, Chen *et al*^[17] in their study that included 691 eyes of 424 patients presenting to the Zhongshan Ophthalmic Center, China, reported patchy C-R atrophy (5.8 %); diffuse C-R atrophy (4.6 %), this difference may be due to selection criteria (ages 8–88y) or ethnicity difference.

We also found correlation of C-R atrophy to SE, and longer AL. A recent study included 445 adults with HM in Changsha, China, found greater myopic SE and longer AL are risk factors for MMD and not the age^[18]. However, some studies found that increasing age and female gender are also risk factor for atrophic MM or macular C-R atrophy^[19]. It is reported that diffuse C-R atrophy primarily appears around the optic disc and increases with age and finally covers the entire posterior pole^[20]. Liu *et al*^[21] found that the incidence of diffuse C-R atrophy increased with age and with longer AL.

Table 2 Logistic regression of clinical factors associated with macular changes in participants with pathological myopia

Risk factors	Univariate OR (95%CI)	P	Multivariate OR (95%CI)	P
Atrophic MM (A2, A3), n=83 eyes				
Age	1 (0.98–1.021)	0.987	1.007 (0.985–1.03)	0.542
Gender (female)	0.617 (0.341–1.117)	0.111	0.743 (0.393–1.402)	0.359
SE	0.818 (0.772–0.868)	<0.001	0.681 (0.559–0.83)	<0.001
AL	1.548 (1.336–1.793)	<0.001	0.605 (0.366–1.001)	0.049
Neovascular MM (N2a, N2b), n=108 eyes				
Age	0.997 (0.979–1.015)	0.742	1.002 (0.983–1.022)	0.851
Gender (female)	0.595 (0.349–1.016)	0.057	0.68 (0.39–1.187)	0.175
SE	0.869 (0.826–0.915)	<0.001	0.736 (0.622–0.871)	<0.001
AL	1.342 (1.178–1.529)	<0.001	0.629 (0.407–0.972)	0.037
MTM (T1, T2, T3), n=49 eyes				
Age	1.03 (1.001–1.059)	0.040	1.054 (1.017–1.092)	0.004
Gender (female)	1.441 (0.694–2.994)	0.327	1.065 (0.424–2.677)	0.893
SE	0.613 (0.535–0.702)	<0.001	0.639 (0.484–0.844)	0.002
AL	3.01 (2.256–4.018)	<0.001	1.168 (0.617–2.212)	0.633
MH, n=27 eyes				
Age	1.039 (1–1.08)	0.050	1.048 (1.006–1.092)	0.025
Gender (female)	1.607 (0.594–4.35)	0.351	1.357 (0.485–3.797)	0.561
SE	0.825 (0.752–0.907)	<0.001	0.796 (0.604–1.048)	0.104
AL	1.576 (1.252–1.983)	<0.001	0.923 (0.458–1.859)	0.822
DSM, n=19 eyes				
Age	0.97 (0.936–1.005)	0.092	0.954 (0.909–1.002)	0.060
Gender (female)	1.35 (0.438–4.157)	0.601	1.693 (0.334–8.566)	0.525
SE	0.369 (0.224–0.608)	<0.001	0.754 (0.419–1.358)	0.347
AL	6.704 (3.314–13.561)	<0.001	5.372 (2.011–14.354)	0.001
Lacquer cracks, n=7 eyes				
Age	0.928 (0.875–0.983)	0.011	0.927 (0.873–0.984)	0.013
Gender (female)	0.887 (0.17–4.638)	0.887	0.772 (0.141–4.219)	0.765
SE	0.871 (0.735–1.031)	0.108	0.877 (0.488–1.576)	0.660
AL	1.369 (0.9–2.084)	0.143	1.019 (0.224–4.635)	0.981

OR: Odds ratio; CI: Confidence interval; MM: Myopic maculopathy; MTM: Myopic traction maculopathy; DSM: Dome shaped maculopathy; MH: Macular hole; SE: Spherical equivalent; AL: Axial length.

Table 3 Univariate and multivariate linear regression for prediction of BCVA

Parameters	Univariate linear regression				Multivariate linear regression			
	B coefficient	95%CI	β coefficient	P	B coefficient	95%CI	β coefficient	P
Atrophic MM	0.304	0.180 to 0.429	0.238	<0.001	0.185	0.054 to 0.315	0.145	<0.001
Neovascular MM	0.355	0.244 to 0.465	0.307	<0.001	0.316	0.195 to 0.437	0.275	<0.001
MTM	0.066	-0.086 to -0.218	0.044	0.391	0.098	-0.049 to -0.246	0.065	0.191

B: Unstandardized coefficient; β : Standardized coefficient; CI: Confidence interval; BCVA: Best-corrected visual acuity; MM: Myopic maculopathy; MTM: Myopic traction maculopathy. A higher BCVA (logMAR) indicates poorer visual acuity.

We found that prevalence of neovascular MM was about 25 % either active (N2a) or inactive (N2b). In Japan it was ranged from 5.2% to 11.3%^[22]. The explanation may be due to the access to clinical services among Egyptian patients is triggered by serious health problems. This concept may falsely affect the prevalence of myopic CNV. Also, it may be due to genetic and environmental factors. It was reported that specific lesions

particularly associated with mCNV include patchy atrophy, lacquer cracks, and large myopic conus. Increased vascular endothelial growth factor (VEGF) level has been found in the aqueous humor in eyes with mCNV compared with eyes undergoing cataract surgery. There is also been a suggestion that genetic or hereditary factors may play a role in the development of mCNV^[2].

In our multivariate analysis, the presence of neovascular MM was associated with more myopic refractive error and longer AL. Other studies' findings found that mCNV directly related to AL elongation, thinning of the retina, attenuation of the RPE, and choroidal thinning. Increased age is disproportionately affecting the prevalence^[23-24].

Lacquer cracks represent healed and mechanical breaks of the RPE, Bruch's membrane, and the choriocapillaris complex. When lacquer cracks are newly formed, mCNV might develop through the Bruch's membrane rupture and once the Bruch's membrane rupture is healed with scar tissue, a secondary mCNV rarely occurs^[2]. We found prevalence of lacquer cracks is 1.64% in our study. This is lesser than reported in literature. Chen *et al*^[17] showed that lacquer cracks were the most prevalent manifestation of high myopia (29.1%). This might be due to use of fundus fluorescein angiography and indocyanine green angiography in that study. However, the prevalence of lacquer cracks ranged from 4.2% to 15.7% in HM eyes in several cohorts^[2].

In our multivariate analysis, the presence of lacquer cracks was associated with more myopic refractive error and longer AL although marginally nonsignificant. We agree with Chen *et al*^[17] study that showed lacquer cracks were significantly associated with younger age. Previous studies also indicated that lacquer cracks occur most often in eyes with an AL between 29.0 and 32.0 mm^[2].

MTM is a wide spectrum of clinical pictures that may affect up to 30% of eyes with PM^[25]. We found about 11.48% of our participants had MTM. The pathogenesis of MTM reported to be multifactorial, in PM, different centrifugal forces exerted by the vitreous and the sclera, with two main different directions: tangential or perpendicular to the retinal tissue, racing against the centripetal intraretinal force. If the prevalent centrifugal forces are perpendicular to the macular plane, the inner schisis progresses and involves the outer layers becoming an inner outer-schisis, a pure outer-schisis, and eventually a macular detachment. If the prevalent centrifugal forces are tangential to the macular plane, the eye will develop an inner LMH and eventually an FTMH^[25].

In our multivariate analysis, the presence of MTM was significantly associated with more myopic refractive error and age. This is with some agree with one study in Singapore, which reported myopic SE, longer AL, MMD were independent risk factors for MTM; and MTM was not associated with age^[26]. Another population-based study in China reported the frequency of retinoschisis is increased in the population aged ≥ 50 y^[27].

MH debate is that: it is either single entity or part from spectrum of MTM. So, comparison of prevalence of LMH or FTMH among studies cannot be justified. However, we

found prevalence of MH (either with MTM or not) was 6.32% of eyes in our study. Reviewing literature, we found similar results by Coppé *et al*^[28], who found macular holes in 6.3% of highly myopic eyes studied by OCT. One of Egyptian studies found that FTMH prevalence was about 4.7%^[14].

In our study age is only significant risk factor in multivariate analysis, not SE or AL. There are two types of MH in HM eyes. One is the type with thickened edges and retinal cysts, there is no retinal detachment around the hole clinically, and this type usually stable for months or years. The other type has surrounding retinoschisis, results from MTM and typically progresses rapidly because of underlying traction. The second type is associated with age and not AL or SE. He *et al*^[29] found that atrophic myopic MH is a hole associated with MTM, and increased by age. In our study, among the 49 eyes with MTM: 1 eye had associated FTMH (T4), 10 eyes had lamellar MH, this explain the lack of association between MH and AL in multivariate model.

We found prevalence of DSM is about 4.5%. The prevalence of DSM has been estimated at between 10.7% and 14.6% in the Chinese myopic population^[2]. The variation in the reported rate results from the different sample size, inclusion criteria (only symptomatic case versus all HM), diagnostic modality (spectral domain versus enhance depth/swept source), scan length, and scan protocols (6 versus 9/12 mm) and others^[30-31]. We found associated significant risk factor to DSM in multivariate analysis is AL ($P=0.001$). Zhao *et al*^[32] found that DSM is higher in HM (AL>30 mm) but without statistical difference from HM without DSM. The difference may be due to patho-etiological mechanisms in DSM influenced by genetic factors.

In multivariable linear mixed model with adjustment of age, gender, race, and SE, we found atrophic MM and neovascular MM are associated with visual impairment while MTM showed non-significant result. This may be explained by preserved photoreceptors in some myopic macular pathologies and absence in the others. In Singapore eye study they found about 22% of MMD had visual impairment. They defined MMD as C-R atrophy or macular atrophy. But they not studied other myopic pathologies as mCNV, MH, MTM, and DSM correlations to visual impairment^[33]. Another large study (ATN classification group) found macular C-R atrophy, MTM, mCNV are associated with significant visual impairment that none linearly increase with age^[34]. Reading acuity was significantly associated with the presence of C-R atrophy in the foveal central circle in univariate and multivariate analysis^[35].

The limitation of our study: the cross-sectional design of our study precluded the assessment of causality. Longitudinal studies are needed to clarify the role of staphyloma in the development of myopic maculopathy.

In conclusion, the PM and myopic maculopathy are increasing among adult Egyptians. The more myopic SE, longer AL, increasing age are associated with increased odds of having MM. The most MM associated with poorer visual acuity was atrophic or/and neovascular types.

ACKNOWLEDGEMENTS

Conflicts of Interest: Mansour MN, None; Safwat HM, None.

REFERENCES

- 1 Pan W, Morgan I, Flitcroft I, *et al.* The need to address the myopia pandemic: summary report of the global myopia public health summit 2024. *Glob Health Res Policy* 2025;10(1):45.
- 2 Ohno-Matsui K, Wu PC, Yamashiro K, *et al.* IMI pathologic myopia. *Invest Ophthalmol Vis Sci* 2021;62(5):5.
- 3 Pärssinen O, Grzybowski A. Myopia 2025: epidemiology, pathophysiology, treatment and complications. *Acta Ophthalmol* 2025;103(8):855-857.
- 4 Fuchs A. Frequency of myopia gravis. *Am J Ophthalmol* 1960;49(6):1418-1419.
- 5 Gawdat I. Studies on the incidence of refractive errors in Egypt. *Bull Ophthalmol Soc Egypt* 1976;69(73):513-520.
- 6 Ahmed ME. Prevalence of pathological myopia in upper Egypt. *Al Azhar Assiut Med J* 2022;20(1):158-161.
- 7 Elnahry AG, Khafagy MM, Esmat SM, *et al.* Prevalence of pathological myopia among patients in a large tertiary care center in Egypt. *New Front Ophthalmol* 2018;4(5):1-4.
- 8 Ruiz-Medrano J, Montero JA, Flores-Moreno I, *et al.* Myopic maculopathy: Current status and proposal for a new classification and grading system (ATN). *Prog Retin Eye Res* 2019;69:80-115.
- 9 Ng DSC, Chan LKY, Lai TYY. Myopic macular diseases: a review. *Clin Exp Ophthalmol* 2023;51(3):229-242.
- 10 Ohno-Matsui K, Kawasaki R, Jonas JB, *et al.* International photographic classification and grading system for myopic maculopathy. *Am J Ophthalmol* 2015;159(5):877-883.e7.
- 11 Gaucher D, Erginay A, Lecleire-Collet A, *et al.* Dome-shaped macula in eyes with myopic posterior staphyloma. *Am J Ophthalmol* 2008;145(5):909-914.e1.
- 12 Yang JY, Wu S, Zhang CX, *et al.* Global trends and frontiers of research on pathologic myopia since the millennium: a bibliometric analysis. *Front Public Health* 2022;10:1047787.
- 13 Çitirik M, Yavuzer K, Bağcı F. Assessment of changes in macular structural retinal layers in patients with pathological myopia. *Turk J Med Sci* 2023;53(6):1807-1816.
- 14 Elnahry AG, Khafagy MM, Esmat SM, *et al.* Prevalence and associations of posterior segment manifestations in a cohort of Egyptian patients with pathological myopia. *Curr Eye Res* 2019;44(9):955-962.
- 15 Chang L, Pan CW, Ohno-Matsui K, *et al.* Myopia-related fundus changes in Singapore adults with high myopia. *Am J Ophthalmol* 2013;155(6):991-999.e1.
- 16 Du R, Fang Y, Jonas JB, *et al.* Clinical features of patchy C-R atrophy in pathologic myopia. *Retina* 2020;40(5):951-959.
- 17 Chen H, Wen F, Li HT, *et al.* The types and severity of high myopic maculopathy in Chinese patients. *Ophthalmic Physiol Opt* 2012;32(1):60-67.
- 18 Foo LL, Jiang YF, Hoang QV, *et al.* Prevalence and risk factors of myopic macular degeneration: the Aier-SERI high myopia adult cohort. *Br J Ophthalmol* 2025;109(6):721-726.
- 19 Chen QY, He JN, Hu GY, *et al.* Morphological characteristics and risk factors of myopic maculopathy in an older high myopia population—based on the new classification system (ATN). *Am J Ophthalmol* 2019;208:356-366.
- 20 Park UC, Lee EK, Yoon CK, *et al.* Progression pattern of myopic maculopathy according to the severity of diffuse chorioretinal atrophy and choroidal thickness. *Sci Rep* 2022;12:3099.
- 21 Liu R, Guo XX, Xiao O, *et al.* Diffuse chorioretinal atrophy in Chinese high myopia: The zoc-bhvi High Myopia Cohort Study. *Retina* 2020;40(2):241-248.
- 22 Cheung CMG, Arnold JJ, Holz FG, *et al.* Myopic choroidal neovascularization review, guidance, and consensus statement on management. *Ophthalmology* 2017;124(11):1690-1711.
- 23 Haarman AEG, Tedja MS, Brussee C, *et al.* Prevalence of myopic macular features in Dutch individuals of European ancestry with high myopia. *JAMA Ophthalmol* 2022;140(2):115.
- 24 Midorikawa M, Mori K, Torii H, *et al.* Choroidal thinning in myopia is associated with axial elongation and severity of myopic maculopathy. *Sci Rep* 2024;14(1):17600.
- 25 Parolini B. Management of myopic traction maculopathy. *Community Eye Health* 2025;37(125):18-21.
- 26 Matsumura S, Sabanayagam C, Wong CW, *et al.* Characteristics of myopic traction maculopathy in myopic Singaporean adults. *Br J Ophthalmol* 2021;105(4):531-537.
- 27 Pan Z, Huang Y, Li ZH, *et al.* Prevalence, features, and risk factors of macular retinoschisis in high myopic population: the Beijing eye study 2011. *Am J Ophthalmol* 2025;270:227-236.
- 28 Coppé AM, Ripandelli G, Parisi V, *et al.* Prevalence of asymptomatic macular holes in highly myopic eyes. *Ophthalmology* 2005;112(12):2103-2109.
- 29 He HL, An GQ, Qi Y, *et al.* Clinical characteristics of atrophic macular hole in pathologic myopia: a multicenter study. *Photodiagn Photodyn Ther* 2025;54:104680.
- 30 Zhang YY, Qin XH, Zhang LY, *et al.* The features of dome-shape Macula and related complications in high myopia on optical coherence tomography. *Eur J Ophthalmol* 2024;34(5):1569-1575.
- 31 Carlà MM, Philippakis E, Gaucher D, *et al.* Current advances in dome-shaped macula and associated conditions. *Surv Ophthalmol* 2026;71(2):393-404.
- 32 Zhao XJ, Ding XY, Lyu CC, *et al.* Observational study of clinical characteristics of dome-shaped macula in Chinese Han with high myopia at Zhongshan Ophthalmic Centre. *BMJ Open* 2018;8(12):e021887.

- 33 Foo LL, Xu LQ, Sabanayagam C, *et al.* Predictors of myopic macular degeneration in a 12-year longitudinal study of Singapore adults with myopia. *Br J Ophthalmol* 2023;107(9):1363-1368.
- 34 Ye LY, Chen QY, Hu GY, *et al.* Distribution and association of visual impairment with myopic maculopathy across age groups among highly myopic eyes—based on the new classification system (ATN). *Acta Ophthalmol* 2022;100(4):e957-e967.
- 35 Carlà MM, Mateo C. Reading performances in highly myopic patients and correlation with the topography of atrophic maculopathy. *Ophthalmol Sci* 2025;5(4):100743.