• Clinical Research •

Pentagonal *vs* quadrangular conjunctival autograft in pterygium surgery: a comparative study on graft retraction

Alperen Bahar, Aysun Şanal Doğan

Department of Ophthalmology, Diskapi Yıldırım Beyazıt Training and Research Hospital, Ankara 06110, Türkiye
Correspondence to: Alperen Bahar. Diskapi Yıldırım Beyazıt Training and Research Hospital, Ankara 06110, Türkiye. alperenbahar@hotmail.com
Received: 2025-04-16 Accepted: 2025-08-05

Abstract

● **AIM:** To investigate the effect of pentagonal conjunctival autograft on reducing graft retraction following pterygium surgery.

● **METHODS:** This retrospective comparative study included patients who underwent primary pterygium excision with either pentagonal (created by shaping the junction with the recipient conjunctiva into a wedge) or quadrangular conjunctival autograft transplantation. All patients completed a 6mo postoperative follow-up. The primary outcome measure was the incidence of graft retraction; secondary outcomes included graft displacement requiring re-suturing and pterygium recurrence rate.

● **RESULTS:** The study enrolled 58 participants, comprising 26 (15 males, 11 females) in the pentagonal graft group (mean age: 54.9±13.1y), and 32 (17 males, 15 females) in the quadrangular graft group (mean age: 57.6±10.4y). Graft retraction occurred in only 1 eye (3.8%) in the pentagonal autograft group, compared to 9 eyes (28.1%) in the quadrangular autograft group. No cases of graft displacement requiring re-suturing were reported in the pentagonal autograft group. Although graft displacement and recurrence requiring re-suturing were observed less frequently in surgeries with a pentagonal graft, the difference was not statistically significant ($P>0.05$).

● **CONCLUSION:** Designing the conjunctival autograft in a pentagonal shape—mimicking geodesic dome architecture and conforming to the eye's spherical structure—enhances compatibility with the recipient conjunctiva and improves resistance to physical traction forces. This design effectively reduces the incidence of graft retraction and other related complications, providing a more favorable surgical option for pterygium treatment.

● **KEYWORDS:** pterygium; conjunctival autograft; pentagonal autograft; quadrangular autograft; graft retraction; surgical outcome

DOI:10.18240/ijo.2026.02.05

Citation: Bahar A, Dogan AS. Pentagonal *vs* quadrangular conjunctival autograft in pterygium surgery: a comparative study on graft retraction. *Int J Ophthalmol* 2026;19(2):247-251

INTRODUCTION

Pterygium is a benign, wing-shaped fibrovascular growth of the conjunctiva that extends onto the corneal surface. It is commonly associated with prolonged exposure to ultraviolet light, chronic irritation, and environmental factors such as wind and dust[1-5]. While often asymptomatic in its early stages, advanced cases can cause visual disturbances, irritation, and cosmetic concerns.

The treatment of pterygium generally involves the surgical excision of degenerated conjunctival tissue. After this initial step, the procedure can be completed using various techniques[6-9]. However, the current gold standard remains the use of a conjunctival autograft to cover the excised area[10-11]. Although fibrin glue is an easier and more comfortable method for securing the autograft, suturing remains one of the most commonly used techniques for autograft pterygium surgery worldwide due to its greater accessibility[10].

Postoperatively, suture dehiscence, graft retraction, and graft displacement, particularly in the nasal edge of the autograft, are common complications. Pterygium surgery is typically performed by suturing a rectangular autograft onto a rectangular recipient bed. However, due to the spherical structure of the eye, the rectangular shape can lead to increased tension at the center of the nasal edge of the autograft during eye movements. This increased tension may result in graft retraction and flap displacement. In this study, we aimed to evaluate the effectiveness of modifying the nasal edge of the autograft into a convex shape, creating a pentagon configuration, to prevent the aforementioned complications.

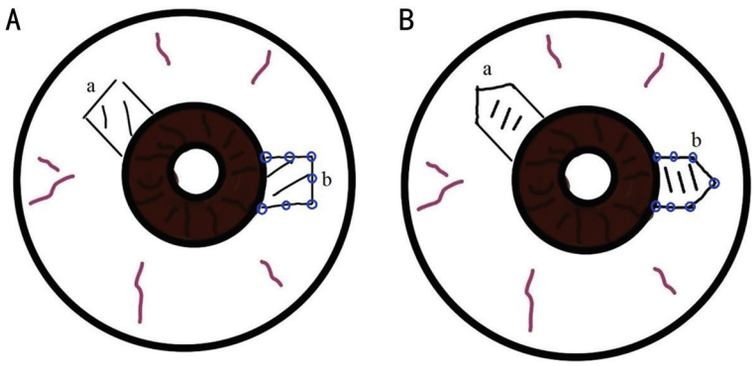

Figure 1 The autograft (a) can be shaped as either a classic quadrangular (A) or a pentagon (B) by modifying the edge farthest from the limbus into a convex wedge. It is then appropriately secured to the recipient site (b) The blue circles indicate the suture placement sites.

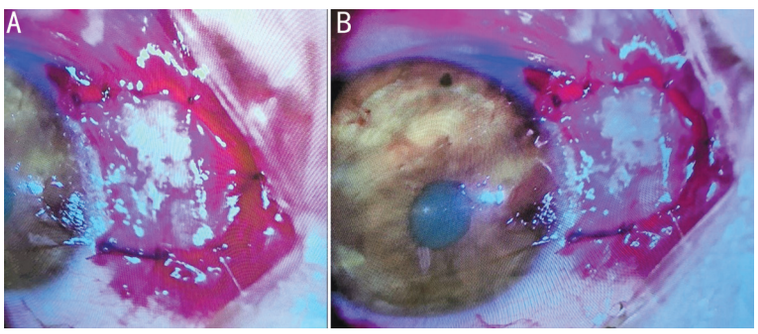

Figure 2 Appearance of a pentagonally shaped autograft harvested and sutured to the recipient bed at the end of surgery.

PARTICIPANTS AND METHODS

Ethical Approval This retrospective comparative study evaluated the postoperative outcomes of 58 patients who underwent pterygium surgery at a tertiary healthcare center between 2022 and 2024. Among them, 26 patients received a pentagonal autograft, while 32 underwent the conventional quadrangular autograft technique. This study was conducted in line with the Declaration of Helsinki and approved by the Etlik City Hospital Ethics Committee of University of Health Sciences (AESH-BADEK1-2025-025).

Study Population Patients who underwent surgery for the first time due to primary pterygium were included in the study. Those with comorbidities that could impair wound healing, such as diabetes mellitus, autoimmune diseases, or collagen tissue disorders, were excluded. Additionally, patients who did not adhere to the specified follow-up schedule, had missing data, or had any ocular disease or ongoing ocular treatment were also excluded from the study. During the examination, pterygium grading was performed according to the classification system described by Maheshwari[12]. Accordingly, if the head of the pterygium is located between the limbus and the midpoint between the limbus and the pupil, it is classified as Grade 1. If it extends between the limbus and the pupillary margin, it is classified as Grade 2. If it reaches the pupillary margin, it is classified as Grade 3.

Surgical Technique All surgical procedures were performed by the same experienced surgeon. After topical anesthesia (0.5% proparacaine hydrochloride; Alcaine, Alcon-Couvreur, Puurs, Belgium), subconjunctival anesthesia (2% lidocaine hydrochloride with 0.001% adrenaline; Jetokain, Adeka, Samsun, Türkiye) was administered beneath the pterygium. The pterygium was excised up to 5 mm beyond the limbus, including the underlying Tenon's capsule. Residual pterygium tissue on the cornea was removed using a crescent knife and further smoothed with a burr. Hemostasis was achieved using an adrenaline-impregnated cotton swab, and no cautery was used.

The autograft was harvested from the superotemporal conjunctiva. The intended conjunctival autograft area was marked with a surgical pen to match the size of the recipient bed. In one group, the graft was marked as a quadrangular, while in the other group, the fornix-side edge of the quadrangular was modified into a wedge shape (Figures 1, 2). After re-administering subconjunctival anesthesia to the donor site, the Tenon's capsule was separated, and the donor conjunctiva was excised. The harvested conjunctival graft was then appropriately sutured to the pterygium-excised area using an 8/0 Vicryl suture. Seven single sutures were placed in total (Figure 1). Additional sutures were applied if there was a noticeable separation between the graft and the recipient conjunctiva. The surgery was completed with subconjunctival gentamicin and dexamethasone application. After the procedure, a bandage contact lens was applied to the patients.

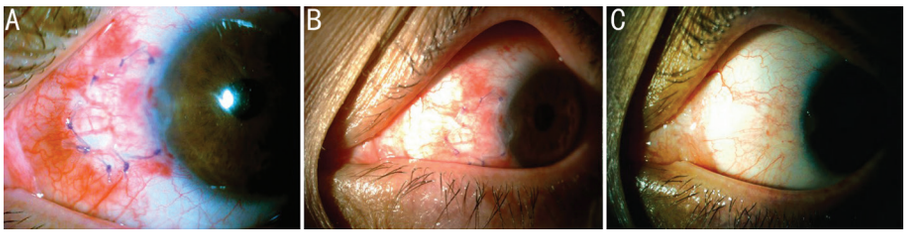

Figure 3 Anterior segment photographs of a patient who underwent pterygium surgery with a pentagonal autograft, taken immediately after surgery (A), on postoperative day 1 (B), and at the 1-month follow-up (C).

Patient Evaluation and Follow-Up Examinations On the first postoperative day, the patch was removed, and a combination of steroid and antibiotic eye drops (0.3% netilmicin+0.1% dexamethasone) along with 0.15% sodium hyaluronate artificial tears were administered four times daily for one month. On the third postoperative day, patients were called for a follow-up visit, and their bandage contact lenses were removed. Subsequent follow-ups were scheduled for the 15th day, the first month, and the sixth month (Figure 3).

Statistical Analysis After reviewing the patient files, the data were transferred to a computer. Statistical analysis was performed using SPSS version 23.0 for Windows (SPSS Inc., Chicago, IL, USA). The sample size was chosen by taking alpha: 0.05, beta: 0.20, and standard effect size: 0.70 in the *t*-test table. The normality of the data was examined using the Shapiro-Wilk test. The Chi-square test was conducted to compare categorical data between the two groups, while an independent samples *t*-test was employed to compare continuous data. Values of $P \leq 0.05$ were considered statistically significant.

RESULTS

There was no significant difference between the two groups in terms of patient demographic data (Table 1). When surgical outcomes were evaluated, graft retraction was significantly lower in surgeries performed with a pentagonal autograft. Although graft displacement and recurrence requiring re-suturing were observed less frequently in surgeries with a pentagonal graft, the difference was not statistically significant (Table 2).

Table 1 Preoperative characteristics of patients who underwent pterygium surgery with pentagonal and quadrilateral autografts

Parameters	Pentagonal graft group (*n*=26)	Quadrangular graft group (*n*=32)	*P*
Age (mean±SD), y	54.9±13.1	57.6±10.4	0.18[a]
Sex (*n*)			0.32[b]
Male	15	17	
Female	11	15	
Pterygium grade (*n*)			0.41[b]
Grade 1	1	1	
Grade 2	15	19	
Grade 3	10	16	

SD: Standard deviation. [a]Independent sample *t*-test; [b]Chi-square test.

Table 2 Post-surgical outcomes of pentagonal and quadrangular autograft groups *n* (%)

Parameters	Pentagonal graft group (*n*=26)	Quadrangular graft group (*n*=32)	*P*
Graft retraction	1 (3.8)	9 (28.1)	0.015[a]
Graft sliding	0	4 (15.6)	0.085[a]
Recurrence	2 (7.6)	4 (12.5)	0.24[a]

[a]Fisher's exact test. The recurrence rates presented in the table represent the rates observed within the first 6mo after surgery.

DISCUSSION

Pterygium surgery is one of the oldest surgery procedures performed in ophthalmology, and numerous techniques have been described to date[13]. However, one of the primary surgical objectives—preventing recurrence—has yet to be fully achieved. The lowest recurrence rates have been reported in surgeries performed with autografts, which is currently the most widely accepted method worldwide[14]. In this technique, the pterygium tissue is excised, and the exposed scleral tissue is covered with conjunctiva harvested from another region. Postoperative graft separation from the bulbar conjunctiva and suture breakage—referred to as graft retraction—are common complications. Graft retraction may subsequently lead to graft displacement, often necessitating resuturing.

Postoperative graft retraction occurs predominantly on the nasal side of the graft, at the edge opposite the limbus. We hypothesize that a primary contributing factor to this complication is the common practice of creating autografts in a quadrilateral shape. A quadrilateral graft may lead to concentrated tension, particularly along the nasal edge. Due to the spherical structure of the eye, a straight-edged graft experiences increased tension at its ends and center, especially during eye movements. This results in mechanical stress accumulating along a single line (linear tension), thereby increasing the risk of retraction or graft separation (Figure 4).

In contrast, the convex design of the nasal edge in a pentagonal graft distributes tension over a broader area. This prevents excessive stress accumulation at a single point, enhancing graft stability. Additionally, the expanded structure at the nasal edge of the pentagonal graft increases the graft's contact surface with the recipient bed. A larger contact area promotes better biological adhesion, allowing the graft to remain more securely in place (Figure 5).

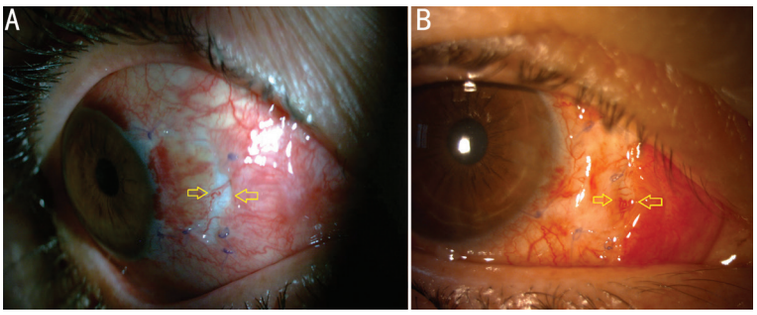

Figure 4 Graft retractions (yellow arrows) observed after pterygium surgeries with different rectangular autografts These retractions typically occur on the nasal edge of the autograft, away from the limbus, due to eye movements.

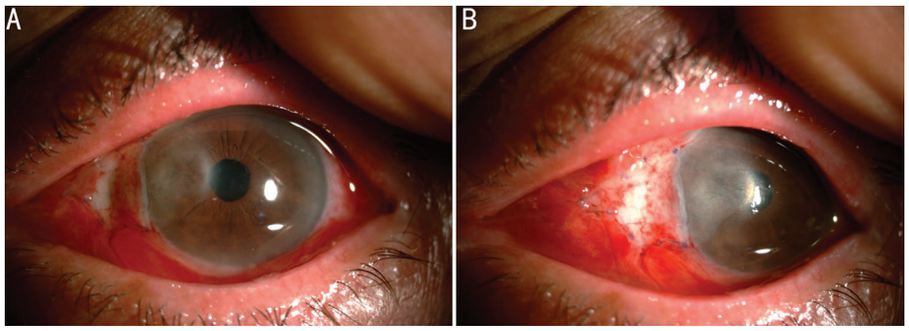

Figure 5 Graft stability on postoperative day 1 in primary gaze (A) and outward gaze (B) after pterygium surgery with a pentagonal autograft.

In the coverage of spherical surfaces, the use of flat geometric shapes presents challenges due to surface curvature. To achieve a smooth and compatible coverage, specific geometric solutions have been developed. Traditional soccer balls, for example, consist of 32 panels: 12 pentagons and 20 hexagons. This design represents one of the most optimal geometric arrangements for covering a spherical surface. The combination of pentagonal and hexagonal panels allows for a more rounded and balanced shape. This structure is based on a geometric form known as the truncated icosahedron[15].

Similarly, geodesic domes are another example of structures used for covering spherical surfaces. These structures are formed by the assembly of triangular panels, resulting in a spherical form. The use of triangles enhances structural stability and ensures an even distribution of mechanical stress[16]. These principles contribute to the equal distribution of tension and increased structural stability in spherical surface coverage.

Applying these principles to pterygium surgery, optimizing the shape of the conjunctival autograft can improve its adaptation to the ocular surface and contribute to the even distribution of mechanical stress. By modifying the graft shape, it may be possible to reduce localized tension, thereby minimizing the risk of retraction and displacement.

The present study results were consistent with our hypothesis. Graft retraction was significantly lower in surgeries performed with a pentagonal graft. Similarly, graft displacement requiring suturing was also found to be lower compared to the quadrilateral graft. A review of the literature shows that graft retraction rates vary between 2% and 50% with different graft fixation methods[17-19]. In our study, graft retraction occurred in only one patient after surgery with a pentagonal autograft. Graft retraction, displacement, and loss are also important because they are associated with pterygium recurrence. Studies have shown that recurrence rates increase in such cases[9,20-23]. In our study, although the difference was not statistically significant, the lower recurrence rate observed in the pentagonal graft group may be related to this association. On the other hand, making the graft pentagonal results in a larger graft. The larger graft allows for a wider excision of the pterygium tissue on the nasal side. Studies have shown that a wider excision may reduce recurrence rates[24-27]. Another factor contributing to the lower recurrence rates in pentagonal autograft surgery may be this wider excision.

In the present study, due to the limited number of patients who attended the 12-month follow-up, recurrence rates were evaluated based on the 6-month follow-up data. Therefore, the lack of 1-year recurrence rates is one of the study's limitations. However, the first 6mo are considered the most critical period for pterygium recurrence[20]. Another limitation of the study is that achieving a pentagonal shape while harvesting the autograft may not always be feasible. Shaping the graft requires surgical expertise. However, recent studies have reported the use of femtosecond laser technology for autograft harvesting[28-30]. The ability to obtain a graft with the desired shape using a laser may facilitate this process. Another limitation is the small number of patients, especially for evaluating recurrence. Studies with larger patient populations are needed.

As a result, shaping the autograft in accordance with the spherical structure of the eye during pterygium surgery may help reduce graft retraction and related complications by balancing the traction forces exerted on the graft during eye movements. Additional studies are needed to evaluate whether the effectiveness observed in sutured surgery also applies to other fixation techniques, such as fibrin glue.

ACKNOWLEDGEMENTS

Conflicts of Interest: Bahar A, None; **Dogan AS,** None.

REFERENCES

1 Ding PQ, Wang RQ, He YX. Risk factors for pterygium: latest research progress on major pathogenesis. *Exp Eye Res* 2024;243:109900.

2 Hashemi A, Aghamirsalim M, Hashemi H, *et al*. Prevalence of pterygium and pinguecula and their risk factors: Tehran Geriatric Eye Study. *Int J Ophthalmol* 2025;18(4):699-706.

3 Lin YH, Sun CC, Yeung L, *et al*. Epidemiologic study of pterygium in Taiwan. *Jpn J Ophthalmol* 2019;63(4):297-303.

4 Rezvan F, Khabazkhoob M, Hooshmand E, *et al*. Prevalence and risk factors of pterygium: a systematic review and meta-analysis. *Surv Ophthalmol* 2018;63(5):719-735.

5 Akbari M. Update on overview of pterygium and its surgical management. *J De La Ther Des Popul De La Pharmacol Clin* 2022;29(4):e30-e45.

6 Patel ED, Rhee MK. Surgical techniques and adjuvants for the management of pterygium. *Eye Contact Lens* 2022;48(1):3-13.

7 Ge HM, Cao GF, Wang J, *et al*. Modified protocol for pterygium surgery without blades and electrocoagulation. *Front Med* 2025;12:1522167.

8 Kase S, Chin S, Ishida S. Z-shaped incision without epithelial resection in pterygium surgery. *Int J Ophthalmol* 2024;17(7):1262-1266.

9 Kim YJ, Rao R, Lee HJ. Comparison of surgical techniques for recurrent pterygium. *Can J Ophthalmol* 2023;58(5):422-425.

10 Hovanesian JA, Starr CE, Vroman DT, *et al*. Surgical techniques and adjuvants for the management of primary and recurrent pterygia. *J Cataract Refract Surg* 2017;43(3):405-419.

11 Wanzeler ACV, Duarte B, de Andrade VDM, *et al*. Impact of conjunctival autograft on pterygium treatment: evaluation of related symptoms and patients' satisfaction after surgery. *Clin Ophthalmol* 2018;12:833-837.

12 Maheshwari S. Pterygium-induced corneal refractive changes. *Indian J Ophthalmol* 2007;55(5):383-386.

13 Hirschberg J. The History of Ophthalmology. Vol 1. Antiquity. Blodi FC, trans. Bonn, Germany: Wayenborgh; 1982:47,57, 87, 190, 199, 203, 239, 288, 345.

14 Paganelli B, Sahyoun M, Gabison E. Conjunctival and limbal conjunctival autograft *vs*. amniotic membrane graft in primary pterygium surgery: a 30-year comprehensive review. *Ophthalmol Ther* 2023;12(3):1501-1517.

15 Truncated icosahedron. (2025, January 21). Wikipedia. https://en.wikipedia.org/wiki/Truncated_icosahedron utm_source8. Accessed on: 2025, March 4.

16 Geodesic Domes. (2023, February 23). Buckminster Fuller Institute. https://www.bfi.org/about-fuller/geodesic-domes/. Accessed on: 2025, March 5.

17 Kodavoor SK, Rathi N, Dandapani R. Tuck in versus cauterisation of graft edge in pterygium management: a comparative retrospective interventional analysis. *Oman J Ophthalmol* 2022;15(2):193-197.

18 Zeng W, Dai H, Luo H. Evaluation of autologous blood in pterygium surgery with conjunctival autograft. *Cornea* 2019;38(2):210-216.

19 Kodavoor SK, Preethi V, Dandapani R. Profile of complications in pterygium surgery - A retrospective analysis. *Indian J Ophthalmol* 2021;69(7):1697-1701.

20 Ghiasian L, Samavat B, Hadi Y, *et al*. Recurrent pterygium: a review. *J Curr Ophthalmol* 2021;33(4):367-378.

21 Kusano Y, Den S, Yamaguchi T, *et al*. Risk factors for recurrence in the treatment of recurrent pterygium. *Cornea* 2024;43(6):740-745.

22 Chen S, Zhang M, Lin Y, *et al*. Risk factors for pterygium recurrence based on a retrospective study of 196 patients. *Sci Rep* 2025;15(1):6646.

23 Ha SW, Park JH, Shin IH, *et al*. Clinical analysis of risk factors contributing to recurrence of pterygium after excision and graft surgery. *Int J Ophthalmol* 2015;8(3):522-527.

24 Hirst LW. Prospective study of primary pterygium surgery using pterygium extended removal followed by extended conjunctival transplantation. *Ophthalmology* 2008;115(10):1663-1672.

25 Allam WA, Alagorie AR, Nasef MH, *et al*. Safety and efficacy of pterygium extended removal followed by extended conjunctival transplant for recurrent pterygia. *Int Ophthalmol* 2022;42(7):2047-2053.

26 Liu HY, Chen YF, Chen TC, *et al*. Surgical result of pterygium extended removal followed by fibrin glue-assisted amniotic membrane transplantation. *Taiwan Yi Zhi* 2017;116(1):10-17.

27 Allam WA. Recurrence and complications of pterygium extended removal followed by extended conjunctival transplant for primary pterygia. *Eur J Ophthalmol* 2016;26(3):203-208.

28 Tan SS, Liu YC, Han EJY, *et al*. Femtosecond laser-assisted pterygium surgery using a customized algorithm for trapezoidal conjunctival grafts. *Cornea* 2025;44(12):1508-1514.

29 Ting DSJ, Liu YC, Lee YF, *et al*. Cosmetic outcome of femtosecond laser-assisted pterygium surgery. *Eye Vis* 2021;8(1):7.

30 Liu YC, Ji AJS, Tan TN, *et al*. Femtosecond laser-assisted preparation of conjunctival autograft for pterygium surgery. *Sci Rep* 2020;10:2674.