

First case of fungal keratitis secondary to *Yamadazyma mexicana*

Ioannis Giachos¹, Aristeia Velegraki^{2,3}, Sotiria Palioura⁴

¹First Department of Ophthalmology, National and Kapodistrian University of Athens Medical School, Athens 11527, Greece

²Mycology Research Laboratory, Microbiology Department, Medical School, National and Kapodistrian University of Athens, Athen 11527, Greece

³BIOIATRIKI S.A Healthcare Group, Athens 11526, Greece

⁴Department of Ophthalmology, University of Cyprus Medical School, Nicosia 2109, Cyprus

Correspondence to: Sotiria Palioura. 7 Lampsas Str, Athens 11524, Greece. sotiria.palioura@gmail.com

Received: 2023-08-18 Accepted: 2024-02-29

DOI:10.18240/ijo.2024.06.24

Citation: Giachos I, Velegraki A, Palioura S. First case of fungal keratitis secondary to *Yamadazyma mexicana*. *Int J Ophthalmol* 2024;17(6):1164-1167

Dear Editor,

Fungal keratitis is a serious and potentially sight-threatening infection that poses a global health concern, with higher incidence rates reported in low-income countries and regions with tropical climates^[1-3]. Risk factors for fungal keratitis include trauma with vegetative matter, contact lens wear, history of ocular surgery, chronic topical steroid use, low socioeconomic status and tropical climate^[1-2].

Fungi have the propensity to penetrate deep into the corneal stroma, making the infection difficult to treat with topical antifungal agents alone. Complications such as corneal perforation and endophthalmitis can arise in severe cases, making early identification of the causative fungal pathogen of utmost importance^[4-5]. Moreover, obtaining susceptibilities to the available antifungal agents can be sight and eye saving^[5]. Corneal stains and cultures are the gold standard for diagnosis, but they can take several days to yield results. Thus, molecular tools such as polymerase chain reaction (PCR) using pan-fungal primers have been increasingly utilized due to their higher sensitivity and specificity and faster turnaround time^[1,6]. The most common fungi isolated from corneal scrapings belong to the *Fusarium*, *Aspergillus*, and *Candida* species^[7].

Yet, there is a variety of fungal species that can potentially cause fungal keratitis and should be included in the differential diagnosis. Herein, we present the first recorded case of *Yamadazyma mexicana* infection in humans, its management, and the importance of molecular identification in treating fungal keratitis.

Case Presentation

The study was conducted in accordance with the principles of the Declaration of Helsinki. The informed consent was obtained from the subject.

A 71-year-old monocular farmer presented with chronic ocular pain and poor vision in his left eye. He reported history of chemical alkali burn in both eyes about 20y prior to presentation. His right eye was phthisical. He had been wearing a bandage contact lens in the left eye for the past 3y due to recurrent epithelial erosions from limbal stem cell deficiency.

Visual acuity was no light perception in the right eye and counting fingers at 30 cm in the left eye. Slit lamp examination revealed a central corneal epithelial defect with concomitant stromal thinning as well as peripheral corneal neovascularization (Figure 1). No infiltrate was present. Management options included allogeneic simple limbal epithelial transplantation (SLET) as well as Boston keratoprosthesis (KPro) type I and were discussed with the patient and his family. He opted to proceed with allogeneic SLET from his daughter. He was thus, started on mycophenolate 500 mg twice a day with gradual dose escalation to 1000 mg twice a day and allogeneic SLET was performed uneventfully 2mo later.

In short, a 3.5 mm limbal graft was obtained from his daughter's superior limbus and was stored in balanced salt solution. Attention was then turned to the patient's left eye. A 360° conjunctival peritomy was performed and the pannus was carefully dissected off the patient's cornea. A cryopreserved human amniotic membrane was secured over the cornea using fibrin glue and a peripheral purse string 10-0 nylon suture. The limbal explant that had been procured from his daughter was cut in 10 pieces and placed over the amniotic membrane with fibrin glue. A bandage contact lens was then placed on top. Postoperatively the patient was started on preservative-free

dexamethasone eye drops every 2h, moxifloxacin eye drops every 4h and preservative-free artificial tears. He had received intravenous methylprednisolone (1 g) during the procedure and was continued on mycophenolate mofetil 2 g per day postoperatively.

At his postoperative day 1 and week 1 visits, his left eye was quiet, and the limbal explants and the contact lens were in place. Two weeks later, the patient returned urgently with pain, redness, and reduced vision. He reported that he applied a bandage contact lens himself because he erroneously thought that the old one had been lost. His vision was light perception with projection. Upon slit lamp examination, two contact lenses were noted to be present in his operated eye, and a central corneal perforation (2 mm × 2 mm) was observed in the center of a corneal infiltrate with fluffy borders (Figure 2). No satellite lesions were seen.

The patient underwent a therapeutic penetrating keratoplasty and both contact lenses and scrapings from the ulcer borders were sent for microscopy and cultures. Cohesive viscoelastic was injected through the perforation to form the anterior chamber. A 7.75 mm Baron corneal donor punch was used to trephinate the donor graft and a 7.5 mm Hessburg-Baron vacuum trephine was used to remove the patient's cornea, which was sent for histopathological evaluation. An anterior chamber washout with vancomycin 1 mg/0.1 mL, ceftazidime 2.2 mg/0.1 mL and voriconazole 0.1 mg/0.2 mL was performed and an amniotic membrane graft was secured with 8-0 Vicryl sutures over the patient's ocular surface. The patient was started on topical vancomycin 5%, moxifloxacin and voriconazole 1% eye drops every 1h while awake.

Histologic sections of the corneal button stained with Grocott methenamine silver stain revealed fungal spores and a few hyphae (Figure 3). Giemsa staining of the corneal scrapings revealed fungal spores and cultures grew a yeast species that could not be identified *via* the standard MALDI TOF MS Biotyper (Bruker®, Billerica, Massachusetts, USA). Thus, sequencing of the D1/D2 region of the nrRNA gene and the barcoding internal transcribed spacer (ITS) region of fungi was performed and the organism was identified as *Yamadazyma mexicana*. The isolate was deposited to the National and Kapodistrian University of Athens, Hellenic Collection of Pathogenic Fungi under the Accession UOA/HCPF 17073. Sequences of the large and small subunits ribosomal RNA, generated by Sanger dideoxy sequencing, were submitted to the GenBank (<https://www.ncbi.nlm.nih.gov/nuccore/ON256360.1>; <https://www.ncbi.nlm.nih.gov/nuccore/ON256361.1>) with accession numbers ON256360.1 and ON256361.1 respectively.

Susceptibility tests were performed according to the European Committee on antifungal susceptibility testing (EUCAST)

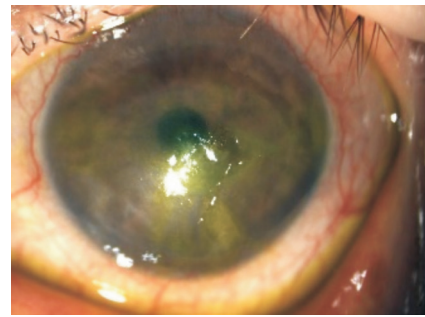


Figure 1 Slit lamp photograph of the patient's left eye prior to the allogeneic limbal stem cell transplantation. A central corneal epithelial defect with concomitant stromal thinning and peripheral corneal neovascularization are present.

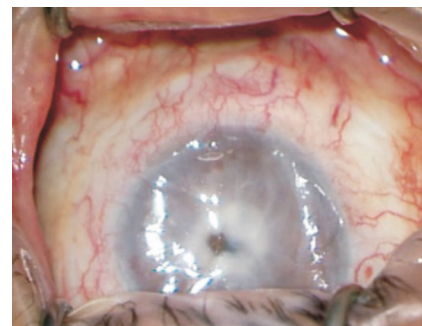


Figure 2 Intraoperative photograph of the patient's left eye. A central corneal infiltrate with perforation (2 mm × 2 mm) is present.

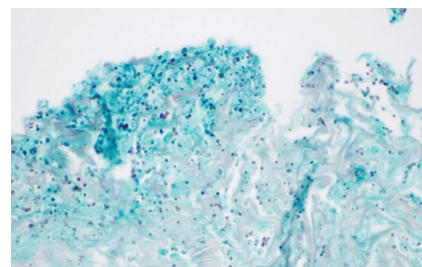


Figure 3 Histopathological photograph after Grocott methenamine silver (GMS) staining of the corneal button revealed fungal spores and hyphae.

microdilution guidelines for yeasts (E.DEF 7.3.2; https://www.eucast.org/ast_of_fungi). The following antifungals displayed low minimum inhibitory concentration (MIC) against *Yamadazyma mexicana*: voriconazole (0.03 mg/mL), posaconazole (0.008 µg/mL), itraconazole (0.03 mg/mL), micafungin (0.06 mg/mL), flucytosine (0.06 mg/mL) and anidulafungin (0.01 mg/mL). Amphotericin B and caspofungin MICs were 0.12 µg/mL respectively. Fluconazole and natamycin MICs were correspondingly 4 and 64 mg/mL. As there are no EUCAST clinical breakpoints for rare yeasts, including *Yamadazyma mexicana*, no MIC value interpretation was attempted with reference to susceptible, intermediate susceptibility and resistant. However, therapeutic decisions were guided by the low MICs displayed by azoles.

The patient was, thus, treated with topical voriconazole 1% eye drops for 2mo (Figure 4) and underwent Boston KPro type

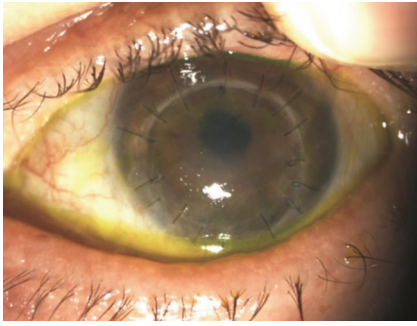


Figure 4 Slit lamp photograph of the patient's left eye 2mo following the therapeutic penetrating keratoplasty.

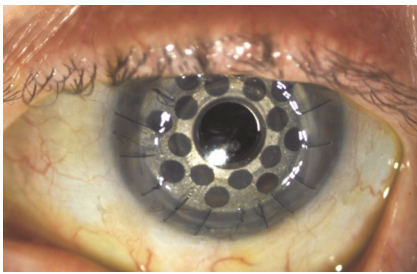


Figure 5 Slit lamp photograph of the patient's left eye 1y following Boston keratoprosthesis type I implantation.

I implantation 4mo later (Figure 5). At his last follow-up visit, his visual acuity was 20/60 and he has not experienced any recurrence of the fungal infection at 1.5y post-operatively.

DISCUSSION

In this report, we present the first known case of a human infection caused by the rare heterothallic fungal species *Yamadazyma mexicana*^[8-9]. Kurtzman and Suzuki^[9] defined the genus *Yamadazyma* phylogenetically, using the sequences from the D1/D2 domains of the nuclear ribosomal subunit and the nearly complete small subunit rRNA genes. The genus *Yamadazyma* is one of the largest genera in the family Debaryomycetaceae and includes species that are commonly found in various environmental sources such as flowers, fruits, seawater and rotting wood^[9-10]. The particular species *Yamadazyma mexicana* is commonly found in olive oil, soil, the gut of bark beetles and cacti^[8,11-12]. Based on the patient's history of being a farmer, we suspect that the most likely source of the fungus was flora in his immediate environment.

Fungi are opportunistic pathogens and when the ocular surface is compromised, they gain access to the corneal stroma. Cheung *et al*^[13] reported that 18.7% of patients undergoing ocular surface stem cell transplantation develop infectious keratitis in the post-operative period. Risk factors are a persistent epithelial defect prior to surgery (33%), chronic use of a bandage contact lens (69%), and systemic immunosuppression (91%). In total, fungi were the causative agents of infection in 32% of the cases with *Candida* species being the most common etiology (73%). A therapeutic penetrating keratoplasty was needed in 25% of the cases in order to clear the infection. Our patient

had several risk factors to develop fungal keratitis including a persistent epithelial defect preoperatively that required chronic use of a bandage contact lens, frequent topical steroid use, and systemic immunosuppression after the allogeneic SLET procedure, and living in a rural environment. Additionally, the patient applied a second contact lens on top of the first one, which likely caused significant corneal hypoxia and created an ideal environment for the fungus to grow.

Corneal cultures and susceptibility testing of the isolated pathogen play a pivotal role in guiding the treatment of fungal keratitis and are considered the gold standard in clinical practice. While PCR with pan-fungal primers has demonstrated utility in detecting certain prevalent fungal genera such as *Candida*, *Aspergillus*, *Mucor*, and *Fusarium*, its effectiveness in identifying less common species is limited. Therefore, it is essential to rely on a combination of culture-based techniques and molecular methods to ensure accurate identification of the causative pathogen.

Natamycin is considered the first line therapy for fungal keratitis as most fungi are sensitive to it and it was found to be superior to topical voriconazole in the Mycotic Ulcer Treatment Trial 1^[14]. Interestingly, the *Yamadazyma mexicana* isolate from our patient was resistant to natamycin and susceptible to voriconazole, emphasizing the importance of isolating the causative agent and consequently testing it for susceptibility to antifungals. This results in implementing targeted treatment strategies, hence improving patient outcome. In summary, this case highlights the identification and management of the first case of a *Yamadazyma mexicana* infection in a patient who presented with a central corneal infiltrate and perforation two weeks following allogeneic limbal stem cell transplantation and was treated with a therapeutic penetrating keratoplasty and topical voriconazole 1%. It also accentuates the significance of antibiotic susceptibility testing and accurate identification of fungal isolates in the clinical setting, which may require specialized molecular sequencing techniques.

ACKNOWLEDGEMENTS

Conflicts of Interest: Giachos I, None; Velegraki A, None; Palioura S, None.

REFERENCES

- 1 Brown L, Leck AK, Gichangi M, Burton MJ, Denning DW. The global incidence and diagnosis of fungal keratitis. *Lancet Infect Dis* 2021;21(3):e49-e57.
- 2 Atta S, Perera C, Kowalski RP, Jhanji V. Fungal keratitis: clinical features, risk factors, treatment, and outcomes. *J Fungi* 2022;8(9):962.
- 3 Ahmadikia K, Gharehbolagh SA, Fallah B, *et al*. Distribution, prevalence, and causative agents of fungal keratitis: a systematic review and meta-analysis (1990 to 2020). *Front Cell Infect Microbiol* 2021;11:698780.

- 4 Maharana PK, Sharma N, Nagpal R, Jhanji V, Das S, Vajpayee RB. Recent advances in diagnosis and management of mycotic keratitis. *Indian J Ophthalmol* 2016;64(5):346-357.
- 5 Ting DSJ, Galal M, Kulkarni B, Elalfy MS, Lake DM, Hamada S, Said DG, Dua HS. Clinical characteristics and outcomes of fungal keratitis in the United Kingdom 2011-2020: a 10-year study. *J Fungi* 2021;7(11):966.
- 6 Ansari Z, Miller D, Galor A. Current thoughts in fungal keratitis: diagnosis and treatment. *Curr Fungal Infect Rep* 2013;7(3):209-218.
- 7 Wang LL, Wang LY, Han L, Yin WJ. Study of pathogens of fungal keratitis and the sensitivity of pathogenic fungi to therapeutic agents with the disk diffusion method. *Curr Eye Res* 2015;40(11):1095-1101.
- 8 Kaewwichian R, Yongmanitchai W, Kawasaki H, Wang PH, Yang SH, Limtong S. *Yamadazyma siamensis* sp. nov., *Yamadazyma phyllophila* sp. nov. and *Yamadazyma paraphyllophila* sp. nov., three novel yeast species isolated from phylloplane in Thailand and Taiwan. *Antonie Van Leeuwenhoek* 2013;103(4):777-788.
- 9 Kurtzman CP, Suzuki M. Phylogenetic analysis of ascomycete yeasts that form coenzyme Q-9 and the proposal of the new Genera *Babjeviella*, *Meyerozyma*, *Millerozyma*, *Priceomyces*, and *Scheffersomyces*. *Mycoscience* 2010;51(1):2-14.
- 10 Kurtzman C, Fell J, Boekhout T. *Yamadazyma* Billon-Grand (1989). In *The Yeasts, a Taxonomic Study*, 5th ed., 919-925. Amsterdam: Elsevier.
- 11 Zullo BA, Ciafardini G. Virgin olive oil quality is affected by the microbiota that comprise the biotic fraction of the oil. *Microorganisms* 2020;8(5):663.
- 12 Gao WL, Li Y, Chai CY, Yan ZL, Hui FL. New species of *Yamadazyma* from rotting wood in China. *MycKeys* 2021;83:69-84.
- 13 Cheung AY, Sarnicola E, Eslani M, Kurji KH, Genereux BM, Govil A, Holland EJ. Infectious keratitis after ocular surface stem cell transplantation. *Cornea* 2018;37(11):1395-1399.
- 14 Prajna NV, Krishnan T, Mascarenhas J, et al, Group MUTT. The mycotic ulcer treatment trial: a randomized trial comparing natamycin vs voriconazole. *JAMA Ophthalmol* 2013;131(4):422-429.