

Factors affecting meibomian gland area loss in symptomatic adults

Si-Cheng Ding¹, Jing-Jing Su², Qing Zhan², Jiao-Man Wang¹, Fang Zheng³, Xu-Xuan Fang², Dan Cheng², Ping Guo^{1,2}

¹The Second Clinical Medical College, Jinan University, Shenzhen 518000, Guangdong Province, China

²Shenzhen Eye Hospital, Jinan University, Shenzhen Eye Institute, Shenzhen 518040, Guangdong Province, China

³Department of Ophthalmology, Jinzhou Medical University, Jinzhou 121000, Liaoning Province, China

Co-first authors: Si-Cheng Ding and Jing-Jing Su

Correspondence to: Ping Guo. Shenzhen Eye Hospital, Jinan University, Shenzhen Eye Institute, 18 Zetian Road, Futian District, Shenzhen 518040, Guangdong Province, China. 2607212858@qq.com

Received: 2023-11-12 Accepted: 2024-02-02

DOI:10.18240/ijo.2024.06.07

Citation: Ding SC, Su JJ, Zhan Q, Wang JM, Zheng F, Fang XX, Cheng D, Guo P. Factors affecting meibomian gland area loss in symptomatic adults. *Int J Ophthalmol* 2024;17(6):1036-1041

INTRODUCTION

The meibomian glands (MG) are large sebaceous glands located on the upper and lower eyelids that form the lipid layer of the tear film and play an essential role in preventing tear evaporation and maintaining homeostasis of the ocular surface by synthesizing, storing, and secreting various lipids^[1]. The function and morphological structure of the MGs are closely related. Specifically, age, sex hormone levels, *Demodex* mites, local ocular surface inflammation, and other factors affect their number and morphology, lipid secretion, and tear film stability, and MG abnormalities can cause MG disease (MGD)^[2]. Overall, 20%-55% of the general population have MG abnormalities, which increases to up to 65% in patients with dry eyes^[3]. At present, infrared imaging technology of MGs is mainly used in clinical practice to observe the presence or absence of the MGs, their morphology, and any morphological changes^[4]. Images obtained by infrared imaging technology are objective and reproducible. However, they can only be used to quantitatively analyze the glands' morphological structure and missing areas, and the relationship between the actual image characteristics and the patient's clinical symptoms remains unclear.

Therefore, this study conducted an epidemiological survey of patients who visited the Dry Eye Clinic of Shenzhen Eye Hospital to understand the distribution characteristics of MG area loss (MGL) in the general population and its relationship with clinical symptoms and other relevant factors and aimed to provide clinical data for preventing and controlling MG dysfunction.

SUBJECTS AND METHODS

Ethical Approval The Ethics Committee of Shenzhen Eye Hospital, Jinan University, approved this study (approval number 2023KYPJ046). All examinations and electronic questionnaires were administered after the participant provided informed consent.

Abstract

• **AIM:** To characterize the distribution of meibomian gland (MG) area loss (MGL) and its relationship with demographic characteristics, mites, and symptoms.

• **METHODS:** This retrospective observational study included patients who visited the Dry Eye Clinic of Shenzhen Eye Hospital between June 2020 and August 2021. General patient characteristics, ocular symptoms, *Demodex* test results of the eyelid edges, and the results of a comprehensive ocular surface analysis were collected. MGL was analyzed using Image J software.

• **RESULTS:** This study enrolled 1204 outpatients aged 20-80 (40.70±13.44)y, including 357 males (29.65%) and 847 females (70.35%). The patients were classified into mild ($n=155$; 12.87%), moderate ($n=795$; 66.03%), severe ($n=206$; 17.11%), and extremely severe ($n=48$; 3.99%) MGL groups. MGL was significantly larger in female than in male ($P=0.006$). The degree of MGL also significantly differed in age ($P<0.001$) and the more numbers of mites with severity ($P<0.001$). Multivariate disordered multinomial logistic regression analysis identified that female sex, older age, secretory symptoms, and a large number of mites were risk factors for MGL ($P<0.05$).

• **CONCLUSION:** Patients with MGL are more likely to be older, female, more numbers of mites, and increased secretion.

• **KEYWORDS:** meibomian glands; aging; sex; symptomatology; *Demodex*

Participants Data were collected at the Shenzhen Eye Hospital from June 2020 to August 2021, including clinical symptoms and the results of an eyelid mite examination and a comprehensive eye surface. The right eye was selected as the study eye.

The inclusion criteria were voluntary participation; age ≥ 20 y; and with dry eye symptoms and MG obstruction (all degrees). Patients with any of the following were excluded: age < 20 y; inability to cooperate with the eye examination; systematic diseases such as Sjögren's syndrome, orgraft-versus-host disease; systemic administration that might affect MG function or morphology; acute inflammation of the conjunctiva and cornea not associated with blepharitis; and a history of local eye medication, eye surgery within one month.

Methods All participants completed the questionnaire and underwent comprehensive ocular surface analysis and palpebral mite detection. The same physician performed each examination.

Symptomatology Age, sex, and ocular symptoms were collected using an electronic questionnaire on eye itching, dry eye, foreign body sensation, ciliary loss, redness and swelling, blurred vision, and increased secretion. The patients were divided into three groups based on age: 20-39y, 40-59y, and ≥ 60 y.

Meibomian Gland Photography and Loss Grading The right upper eyelid was gently turned over, the upper palpebral surface was exposed, and the MG image was obtained. MG images were imported into Image J software (v.2.0.0, National Institute of Health, Bethesda, MD, USA). First, the total area of the MG in the upper eyelid was outlined and recorded as the total area (pixel values). The area of the developed MGs was outlined and recorded as the residual area (in pixels), and the percentage of MGL was calculated as $1 - (\text{residual area} / \text{total area})$. Based on the degree of MGL of the right upper eyelid, the participants were divided into four groups^[5], with a score of 0-3 as follows: 1) mild: area loss $\leq 25\%$, 0 points; 2) moderate: $25\% < \text{area loss} \leq 50\%$, 1 point; 3) severe: $50\% < \text{area loss} \leq 75\%$, 2 points; 4) extremely severe: area loss $> 75\%$, 3 points.

Mite Examination The *Demodex*-positive diagnostic criteria used in this study were based on the diagnosis and treatment of *Demodex* blepharitis in China^[6]. Three eyelashes from each of the eyelids, along the nasal, center, and temporal side, were in turn epilated under a slit-lamp microscope. A total of 12 eyelashes, were placed on a slide soaked in turpentine, and *Demodex* mites were observed under an optical microscope. The number of *Demodex* mites in the right eyelash sample was calculated.

Statistical Analysis SPSS 26.0 Software (IBM Corp., Armonk, NY, USA) was used to analyze the data. Measurement data following a normal distribution were presented as

means \pm standard deviations and analyzed by one-way analysis of variance. The Bonferroni method was used for the pairwise comparisons. Measurement data that did not follow a normal distribution were presented as medians (upper and lower quartiles), and the non-parametric Kruskal-Wallis test was used to analyze the differences. Pairwise comparisons were performed using an all-pairwise method. Count data were described as frequencies and percentages, and difference analysis was performed using the χ^2 test. The Chi-square segmentation method was used for pairwise comparisons, and a *P*-value correction was performed. For the sampling Spearman correlation analysis, *P*-values of ≤ 0.05 were considered statistically significant. Multiple logistic regression models were utilized to evaluate odds ratios (OR) with 95% confidence intervals (CI) for MGL.

RESULTS

Participant Characteristics In total, 1204 patients were enrolled, including 357 male and 847 female patients. The ages ranged from 20 to 80y (average: 40.70 ± 13.44 y). The male group had an average age of 40.38 ± 12.12 y, and female group had an average age of 41.21 ± 12.81 y. There was no significant difference for the age of patients in the male and female groups ($P=0.298$). Among them, 613 (50.91%) were 20-39 years old, 488 (40.53%) were 40-59 years old, and 103 (8.55%) were > 60 years old. Furthermore, 155 patients (12.87%) had mild loss, 795 (66.03%) had moderate loss, 206 (17.11%) had severe loss, and 48 (3.99%) had extremely severe loss.

Sex Overall, the degree of MGL differed significantly between male and female patients ($\chi^2=12.474$, $P=0.006$; Table 1). Multiple comparisons of multiple sample rate 2 (sample rate=4, number of testing hypothesis=6, corrected test level $\alpha'=0.008$) showed that the distribution of male-to-female ratio in patients with moderate and severe loss was different from that in patients with mild loss ($\chi^2=7.524$, $P=0.006$; $\chi^2=11.171$, $P=0.001$), and women were more likely than men to have moderate to severe area loss. Differences among the remaining groups were not observed.

Ageing The degree of MGL gradually increased with age (Figure 1) and significantly differed among the groups ($\chi^2=67.2$, $P<0.001$; Table 2).

Symptoms The ocular symptoms from low to high incidence were ciliary loss, increased secretion, redness and swelling, blurred vision, foreign body sensation, itching, and dryness (Table 3). The incidence of "increased ocular secretion" significantly differed among the area loss groups ($P=0.003$). The incidence of other ocular symptoms and the area loss degree did not differ among the groups ($P>0.05$).

Multiple comparisons between multiple sample rates (sample rate=4, number of testing hypotheses=6, corrected test level $\alpha'=0.008$) showed that the incidence of increased ocular

Meibomian gland area loss

Table 1 Degree of MGL based on sex n (%)

Degree of area loss	Male	Female	χ^2	P
Mild	63 (17.64)	92 (10.86)	12.474	0.006
Moderate	232 (64.99)	563 (66.47)		
Severe	51 (14.29)	155 (18.30)		
Extremely severe	11 (3.08)	37 (4.37)		

MGL: Meibomian gland area loss.

Table 2 Constituent ratio of MGL based on age n (%)

Degree of area loss	20-39y	40-59y	≥60y	χ^2	P
Mild	107 (17.46)	43 (8.81)	5 (4.85)	67.2	<0.001
Moderate	400 (65.25)	343 (70.29)	52 (50.49)		
Severe	88 (14.36)	86 (17.62)	32 (31.07)		
Extremely severe	18 (2.94)	16 (3.28)	14 (13.59)		

MGL: Meibomian gland area loss.

secretion in the mild area loss group was significantly lower than that in the severe ($P=0.001$) and extremely severe groups ($P=0.007$). The increased secretion incidence rate did not differ among the other groups.

Number of *Demodex* Mites The number of mites was significantly higher in the severe loss group than in the mild and moderate loss groups ($P<0.001$; Kruskal-Wallis H test; Table 4). The number of mites was significantly higher in the moderate loss group than in the mild loss group ($P=0.049$). Differences did not occur among the other groups ($P>0.05$).

Spearman Correlation Analysis The degree of MGL was weakly positively correlated with age ($r=0.177$, $P<0.001$), sex ($r=0.101$, $P=0.006$), increased secretion ($r=0.108$, $P<0.001$), and mite numbers ($r=0.109$, $P<0.001$). The degree of meibomian gland area loss was associated with $\geq 60y$, female sex, increased secretion, and more mites (Figure 2).

Multiple Logistic Regression Analysis The results of the parallelism test in this study were $P<0.05$; therefore, disordered multinomial logistic regression was used to analyze the factors affecting the degree of MGL. The area loss degree was used as the dependent variable, and sex, age, increased secretion, and the number of mites were used as independent variables; Table 5 describes the variable assignments. The model-fitting results demonstrated that the model was superior to the model with only constant terms ($\chi^2=823.79$, $P<0.001$). When the mild loss group was used as the reference group, the area loss degree was higher in patients with aged over 60, female sex, secretion symptoms, and many mites (Tables 5 and 6).

DISCUSSION

The MG is the largest sebaceous gland of the human body, and MG secretion is a critical component of the tear film and plays a vital role in maintaining tear film homeostasis on the ocular surface. Abnormal morphology and function of the MG affect lipid secretion and tear film stability and cause MGD-related dry eye. Moreover, MGL is typical of MGD^[7]. Liang *et al*^[8]

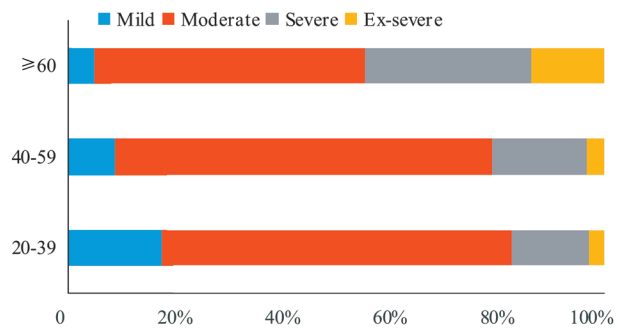


Figure 1 Meibomian gland loss group distributions based on age (y).

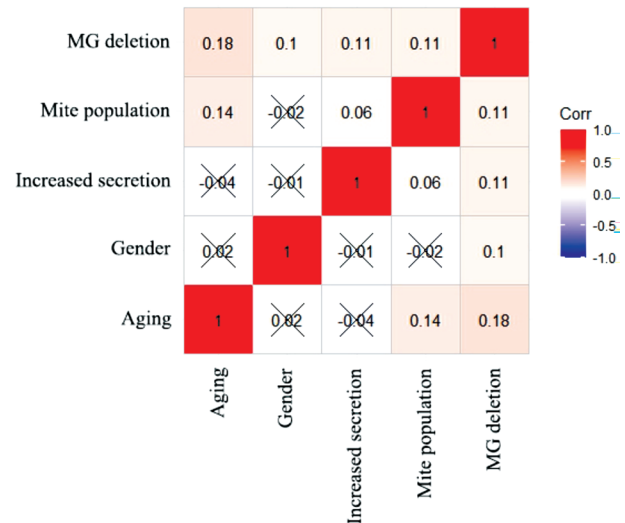


Figure 2 Correlations between the degree of MGL and related factors MGL: Meibomian gland area loss.

found that morphological changes in the MG of the upper eyelid can be used to evaluate the degree and characteristics of MG dysfunction. The MG in the upper eyelid are relatively abundant and have a greater muscular secretory function; therefore, the upper eyelid is used to evaluate the degree of MGL in patients with dry eyes. When we initially counted the MGL, the independent t -test of MGL in the right eye compared with the left eye and the right eye compared with average of both eyes found no statistical significance in 400 patients ($P=0.849$; $P=0.917$). Due to previous statistics and the eye which corresponding to the patient's symptoms, we took the right eye for study.

Den *et al*^[9] and Arita *et al*^[3] reported that the incidence of MGL in the non-dry eye population over 20 years old was approximately 20%-55%. In contrast, MG changes were rarely observed in men and women $<20y$. In Asia, reports suggest that the incidence of MG dysfunction is as high as 68%-70.9%^[10]. Gao *et al*^[11] found that dry eye related to MG dysfunction was present in $>65\%$ of patients with dry eye. In this study, 87% of patients aged $>20y$ with dry eye in Shenzhen had moderate or severe MGL. This high proportion of MGL associated with dry eye may be related to the characteristics of the city, where most live fast-paced and high-intensity lives. Furthermore, electronic work increases the number of young and middle-

Table 3 Symptoms of adults with MGL

Symptoms	Mild (n=155)	Moderate (n=795)	Severe (n=206)	Extremely severe (n=48)	χ^2	P
Ciliary loss	11.61	11.45	14.08	16.67	2.048	0.563
Increased secretion	21.94	30.82	38.83	41.67	14.184	0.003
Redness and swelling	27.74	28.30	34.95	37.50	5.144	0.162
Blurred vision	39.35	44.15	43.20	56.25	4.334	0.228
Foreign body sensation	54.19	56.98	59.22	43.75	4.206	0.24
Itching	51.61	61.13	55.34	50.00	7.571	0.056
Dryness	81.94	85.16	82.52	77.08	3.320	0.345

MGL: Meibomian gland area loss.

Table 4 Mite populations in adults with MGL

Degree of area loss	Mite population	M (P25, P75)	
		H	P
Mild	1 (0, 3.50)	19.470	<0.001
Moderate	2 (0, 4.00)		
Severe	3 (0, 7.00)		
Extremely severe	2 (0, 5.00)		

MGL: Meibomian gland area loss.

Table 5 Assignment table

Independent variables	Label	Assignment
Sex	X ₁	Female=1, Male=2
Aging	X ₂	≥60=1, 40-59=2, 20-39=3
Increased secretion	X ₃	Yes=1, No=2
Number of mites	X ₄	Continuous variable
Degree of MGL	Y	Extremely severe=1, Severe=2, Moderate=3, Mild=4

MGL: Meibomian gland area loss.

Table 6 Factors affecting the degree of MGL

Variables	Moderate		Severe		Extremely severe	
	OR (95%CI)	P	OR (95%CI)	P	OR (95%CI)	P
Sex (control: male)	1.680 (1.172-2.408)	0.005	2.143 (1.350-3.403)	0.001	2.376 (1.111-5.082)	0.026
Age 40-59y (control: 20-39y)	2.151 (1.462-3.164)	<0.001	2.420 (1.512-3.872)	<0.001	2.306 (1.071-4.965)	0.033
Age ≥60y (control: 20-39y)	2.774 (1.075-7.156)	0.035	7.060 (2.601-19.164)	<0.001	17.413 (5.497-55.158)	<0.001
Increased secretion (control: no secretion)	1.664 (1.100-2.519)	0.016	2.363 (1.456-3.835)	<0.001	2.834 (1.400-5.737)	0.004
Number of mites	1.019 (0.976-1.064)	0.394	1.067 (1.017-1.119)	0.008	1.015 (0.945-1.091)	0.682

MGL: Meibomian gland area loss; CI: Confidence interval; OR: Odds ratio.

aged people with video terminal syndrome. Prolonged exposure to electronic screens leads to decreased blinking, meibomian ester secretion, tear film instability, accelerated tear accumulation, and an increased incidence of MGD-related dry eye syndrome.

MG are apparent in images of younger adults but blur with age. Arita *et al*^[3] found that the MGL score in healthy eyes negatively correlated with age. We also found a significant difference in the area loss degree in patients of different ages. In addition, age positively correlated with the degree of area loss, which increased with age. Additionally, the multinomial logistic regression analysis revealed a higher OR value in the elderly group. However, the number of mites was found to be significant only in the intergroup regression analysis between the mild and severe groups. This suggests that age-related MG atrophy predominantly contributes to severe MGL among patients, while *Demodex* mite infection has a relatively minor influence. As indicated by Lee *et al*^[12], within the elderly population (aged ≥60y), no correlation was observed between *Demodex* count and OSDI score. Consequently, it is essential to approach the interpretation of *Demodex* mite presence in the

eyelids of elderly individuals with serious MGL and MGD as a potential pathogenic factor with caution. The atrophy may also be associated with obstructive MGD, forward migration of the mucocutaneous junction in front of the glandular orifice, and keratosis of the MG. Alternatively, androgen levels decline with age, especially in people over 60 to 70y, consistent with the absence of MG in older adults and women^[3,6].

The morphology and function of MG are also affected by factors such as hormones, aging, mites, and systemic diseases. This study compared the degree of MGL in different sex groups and found that the proportion of moderate-to-very severe area loss was higher in female than in male. Previous studies have found that the MG have receptors for both estrogen and androgen, which are crucial for determining the quantity and quality of tear production^[13]. The Tear Film & Ocular Surface Society's DEWS II report stated that androgen (testosterone) can upregulate the critical enzymes involved in meibum synthesis, ATP citrate lyase, and acetylcoenzyme A synthetase, promoting the activity of MG cells, stimulating adipogenesis and maturation of acinar cells, and exerting anti-inflammatory effects^[14]. Clinical studies have confirmed that

an androgen deficiency changes in MG function. Androgen deficiency, androgen receptor dysfunction or insensitivity, and anti-androgen therapy can change MG function, reduce meibum secretion, and decrease tear film stability, inducing the onset of dry eye^[2].

This study also identified an association between mite infection and MGL. Sun *et al*^[15] reported that the greater the *Demodex* infection on the eyelid margin, the greater the facial plate gland loss area. Liang *et al*^[16] also found that 90% of patients under 35 years old with ocular *Demodex* infection had facial gland loss, of which 58.4% had apparent MGL (>1/3 area). After treatment, the number of *Demodex* mites decreased, relieving the ocular symptoms. In addition, Cheng *et al*^[17], on the basis of confocal microscopy findings, proposed *Demodex* semilunar infection caused a larger acinar diameter, reduced density, and several facial plate glands. Together, these studies suggest that *Demodex* infection affects the MG. *Demodex* mites block hair follicles and MG through the dissolution of metabolic waste and dead bodies, affecting the discharge of meibum and causing physical damage. The parasite can also cause foreign body granuloma reactions in tissues, and its metabolites can induce delayed hypersensitivity reactions. The bacteria it carries, such as *Bacillus*, can induce an immune response, which, in turn, causes pathological changes, such as inflammatory infiltration and acinar atrophy^[6,18]. The number of male patients with extremely severe and mild MG deletion too small to perform multiple logistic regression after different genders, as a consequence, this study has further use Pearson correlation analysis for statistical analysis. Surprisingly, in male there was a low correlation between the MGL and the number of mites, with statistical significance ($r=0.155$, $P=0.003$). When age was controlled, there was no significant difference between the loss area and mite number ($P=0.018$). In female, there was a low correlation between the MGL and the number of mites, with statistical significance ($r=0.115$, $P=0.001$). When age was controlled, there was no significant difference in the correlation between the loss area and mite number ($P=0.020$). It was suggested that MG atrophy and mite accumulation were aggravated with age. After adjusting for age, the infection of eye mites may not be related to the degree of MGL. This may indicate that the chronic infection by *Demodex palpebralis* might trigger compensatory stress-relieving signals. This mechanism could involve the desensitization or inhibition of polymodal nociceptors due to long-term or repeated stimulation caused by long-lasting but not severe inflammatory stimuli induced by mite infection^[12].

Common symptoms of MGL include dryness, foreign-body sensation, itchy eyes, and blurred vision. Previous studies have found a strong correlation between the MGL area

and the Ocular Surface Disease Index questionnaire score, proposing that MGL of more than 32% can be considered a dry eye-related symptom^[19-20]. This study found that the incidence of increased ocular secretion significantly differed among the four area loss groups and that the incidence of ocular secretion significantly increased as the area loss degree increased. The lack of a lipid layer causes a compensatory response to increased tear secretion, which could explain this result^[5]. Interestingly, the incidence of eye dryness and eye irritation did not differ among the four groups of patients with different MGL, indicating that the compensatory secretion of tears or partial MGL does not affect the secretion of meibum and masks the discomfort of the ocular surface, except for increased secretion.

The limitation of this study lies in the presence of certain subjects with prominent eye sockets or wide eyelids, resulting in upper eyelid surface after overturning or non-parallel alignment between the eyelids and conjunctival surface, along with the discrepancy between the peripheral conjunctival surface and the focal plane of MG photography, leads to suboptimal image quality in the peripheral region. Moreover, there is a considerable time requirement for manually drawing images using Image J analysis software. Furthermore, all samples were collected from outpatient ophthalmology patients at our hospital, potentially introducing selection bias and yielding biased outcomes. Future investigations will encompass additional factors such as palpebral margin microenvironment and hormonal influences to comprehensively assess the extent of MGL and its associated determinants, aiming to provide enhanced guidance for clinical diagnosis and treatment.

In summary, this study explored the relationships between imaging characteristics for MGL and patient symptoms. Patients with MGL were more likely to be with aged over 60 and female. Area loss was also related to the number of mites and increased ocular secretion. Understanding these characteristics may help prevent and control MG dysfunction.

ACKNOWLEDGEMENTS

Authors' contributions: Ding SC, research ideas and objectives, data processing and analysis, original draft writing; Su JJ, conceptualization, data processing; Zhan Q, data collection, resources; Wang JM, data processing and analysis; Zheng F, resources; Fang XX, data collection, resources; Cheng D, data collection; Guo P, supervision, research ideas and objectives, funding acquisition, resources, manuscript review and editing.

Foundation: Supported by the Science, Technology, and Innovation Commission of Shenzhen Municipality (JCYJ20230807114605011).

Conflicts of Interest: Ding SC, None; Su JJ, None; Zhan Q, None; Wang JM, None; Zheng F, None; Fang XX, None; Cheng D, None; Guo P, None.

REFERENCES

- 1 Wang Y, Dong N, Wu H. Meibomian gland morphology study progression. *Zhonghua Yan Ke Za Zhi* 2014;50(4):299-302.
- 2 Moreno I, Verma S, Gesteira TF, Coulson-Thomas VJ. Recent advances in age-related meibomian gland dysfunction (ARMGD). *Ocul Surf* 2023;30:298-306.
- 3 Arita R, Itoh K, Inoue K, Amano S. Noncontact infrared meibography to document age-related changes of the meibomian glands in a normal population. *Ophthalmology* 2008;115(5):911-915.
- 4 Chinese Branch of the Asian Dry Eye Society, Ocular Surface and Tear Film Diseases Group of Ophthalmology Committee of Cross-Straits Medicine Exchange Association, Ocular Surface and Dry Eye Group of Chinese Ophthalmologist Association. Chinese expert consensus on dry eye: examination and diagnosis (2020). *Zhonghua Yan Ke Za Zhi* 2020;56(10):741-747.
- 5 Adil MY, Xiao J, Olafsson J, Chen X, Lagali NS, Ræder S, Utheim ØA, Dartt DA, Utheim TP. Meibomian gland morphology is a sensitive early indicator of meibomian gland dysfunction. *Am J Ophthalmol* 2019;200:16-25.
- 6 China branch of Asian dry eye Association, Ocular Surface and Tear Film Diseases Group of Ophthalmology Committee of Cross-Straits Medicine Exchange Association. Ocular surface and tear disease group of ophthalmology specialized committee of the cross-strait medical exchange association expert consensus of diagnosis and treatment of demodex blepharitis in China. *Zhonghua Yan Ke Za Zhi* 2018;54:491-495.
- 7 Chinese Branch of the Asian Dry Eye Society, Ocular Surface and Tear Film Diseases Group of Ophthalmology Committee of Cross-Straits Medicine Exchange Association, Ocular surface and dry eye group of chinese ophthalmologist association. Chinese expert consensus on meibomian gland dysfunction: definition and classification (2023). *Zhonghua Yan Ke Za Zhi* 2023;59(4):256-261.
- 8 Liang Q, Pan Z, Zhou M, Zhang Y, Want N, Li B, Baudouin C, Labbé A. Evaluation of optical coherence tomography meibography in patients with obstructive meibomian gland dysfunction. *Cornea* 2015;34(10):1193-1199.
- 9 Den S, Shimizu K, Ikeda T, Tsubota K, Shimmura S, Shimazaki J. Association between meibomian gland changes and aging, sex, or tear function. *Cornea* 2006;25(6):651-655.
- 10 Hassanzadeh S, Varmaghani M, Zarei-Ghanavati S, Heravian Shandiz J, Azimi Khorasani A. Global prevalence of meibomian gland dysfunction: a systematic review and meta-analysis. *Ocul Immunol Inflamm* 2021;29(1):66-75.
- 11 Gao Y, Li C, Wang X. Effect observation of comprehensive therapy in the treatment of MGD by infrared meibography. *Zhongguo Shiyong Yanke Zazhi (Chin J Pract Ophthalmol)* 2016;34(11):1211-1214.
- 12 Lee WJ, Kim M, Lee SH, Chun YS, Kim KW. The varied influence of ocular Demodex infestation on dry eye disease and meibomian gland dysfunction across different age groups. *Sci Rep* 2023;13(1):16324.
- 13 Nuzzi R, Caselgrandi P. Sex hormones and their effects on ocular disorders and pathophysiology: current aspects and our experience. *Int J Mol Sci* 2022;23(6):3269.
- 14 Bron AJ, de Paiva CS, Chauhan SK, Bonini S, Gabison EE, Jain S, Knop E, Markoulli M, Ogawa Y, Perez V, Uchino Y, Yokoi N, Zoukhri D, Sullivan DA. TFOS DEWS II pathophysiology report. *Ocul Surf* 2017;15(3):438-510. Erratum in: *Ocul Surf* 2019;17(4):842.
- 15 Sun XW, Liu ZL, Sun SS, Zhao SZ, Zhang XM, Huang Y. The correlation between Demodex infestation and meibomian gland dysfunction at different ages. *BMC Ophthalmol* 2022;22(1):388.
- 16 Liang LY, Liu Y, Ding XH, Ke HM, Chen C, Tseng SCG. Significant correlation between meibomian gland dysfunction and keratitis in young patients with *Demodex brevis* infestation. *Br J Ophthalmol* 2018;102(8):1098-1102.
- 17 Cheng SN, Zhang MC, Chen H, Fan WL, Huang YK. The correlation between the microstructure of meibomian glands and ocular Demodex infestation: a retrospective case-control study in a Chinese population. *Medicine (Baltimore)* 2019;98(19):e15595.
- 18 Li X, Gao Y, Yang Y, Gao X. The status of research on emodex-related eye diseases. *Chin J Optom Ophthalmol Vis Sci* 2020;22(03):236-236.
- 19 Pult H, Riede-Pult BH. Non-contact meibography: keep it simple but effective. *Cont Lens Anterior Eye* 2012;35(2):77-80.
- 20 Srivastav S, Hasnat Ali M, Basu S, Singh S. Morphologic variants of meibomian glands: age-wise distribution and differences between upper and lower eyelids. *Front Med* 2023;10:1195568.