

Comment on: Recurrence after spontaneous separation of epiretinal membrane in a young woman: a case report

Yusuke Kameda¹, Yutaka Kaneko², Karin Ishinabe¹, Nichika Fukuoka¹

¹Yotsuya-sanchome Ekimae Eye Clinic, Tokyo 160-0004, Japan

²Department of Ophthalmology and Visual Sciences, Yamagata University Faculty of Medicine, Yamagata 990-9585, Japan

Correspondence to: Yusuke Kameda. Yotsuya-sanchome Ekimae Eye Clinic, 3-7-24 Yotsuya, Shinjuku-ku Tokyo 160-0004, Japan. y09025618059@leaf.ocn.ne.jp

Received: 2023-08-29 Accepted: 2023-12-01

DOI:10.18240/ijo.2024.04.26

Citation: Kameda Y, Kaneko Y, Ishinabe K, Fukuoka N. Comment on: Recurrence after spontaneous separation of epiretinal membrane in a young woman: a case report. *Int J Ophthalmol* 2024;17(4):783-784

Dear Editor,

Herein, we provide a commentary on the recently published article by Zeng QZ and Yu WZ^[1]. This case report provides interesting novel insights into the recurrence of epiretinal membrane (ERM) following self-separation in a young patient. In addition to the study, we have been investigating spontaneous ERM release for many years and have recently published a related paper^[2]. We support and appreciate the authors' work which included highly detailed descriptions of the findings and images that can convince readers and agree with their conclusions. Furthermore, we greatly hope that the authors will continue to follow this case to elucidate the exact mechanism of spontaneous ERM separation.

We assumed that the recurrent ERM in the case of Zeng and Yu's study occurred in eyes in which posterior vitreous detachment (PVD) had already developed because the authors observed the Weiss ring using binocular indirect ophthalmoscopy prior to identifying the recurrence phenomenon. Incidentally, our recent report demonstrated that widespread ERM, which may develop following PVD, disappears because of ERM self-separation^[2]. The most common mechanism proposed for spontaneous ERM separation in the literature is a process that occurs owing to the induction of PVD (*i.e.*, PVD with pulling of the ERM)^[3-5]. However, as in our reported case, another mechanism in which

the etiological membrane peels off noninvasively through ERM remodeling due to myofibroblast contraction should also be considered^[2-4]. The latter phenomenon occurs in the eyes in which PVD has already developed, and this contraction force induces slow tangential traction on the edges of the ERM, resulting in gradual separation from the edges towards the center^[2-4]. ERM self-separation is a rare event that occurs in 3% of patients with ERMs^[5]. However, from the point of view of the second mechanism (myofibroblast contraction), it is unsurprising that the patient in Zeng and Yu's study developed ERM self-separation even after an incident of PVD. To the best of our knowledge, no case of spontaneous ERM release occurring twice in the same eye has yet been reported. Therefore, we would like to encourage the authors to report their detailed progress to their readers if a second ERM self-separation occurs in their patient.

ACKNOWLEDGEMENTS

Authors' contributions: Kameda Y read the study by Zeng and Yu, wrote the manuscript, and contributed to the comments. Kaneko Y, Ishinabe K, and Fukuoka N helped in reviewing and editing the manuscript. All the authors approved the final version of the manuscript.

Conflicts of Interest: Kameda Y, None; Kaneko Y, None; Ishinabe K, None; Fukuoka N, None.

REFERENCES

- 1 Zeng QZ, Yu WZ. Recurrence after spontaneous separation of epiretinal membrane in a young woman: a case report. *Int J Ophthalmol* 2023;16(3):476-478.
- 2 Kameda Y, Kaneko Y, Suzuki Y, Tobimatsu Y, Ishinabe K, Fukuoka N. Where did the macular pucker go? *JFO Open Ophthalmol* 2023;3:100047.
- 3 Mansour AM, Mansour HA, Arevalo JF. Spontaneous release of epiretinal membrane in a young weight-lifting athlete by presumed central rupture and centrifugal pull. *Clin Ophthalmol* 2014;8:2243-2250.
- 4 Menteş J, Nalçacı S. An unusual case: self-separation of an idiopathic epiretinal membrane. *Turk J Ophthalmol* 2020;50(1):56-58.
- 5 Yang HS, Hong JW, Kim YJ, Kim JG, Joe SG. Characteristics of spontaneous idiopathic epiretinal membrane separation in spectral domain optical coherence tomography. *Retina* 2014;34(10):2079-2087.

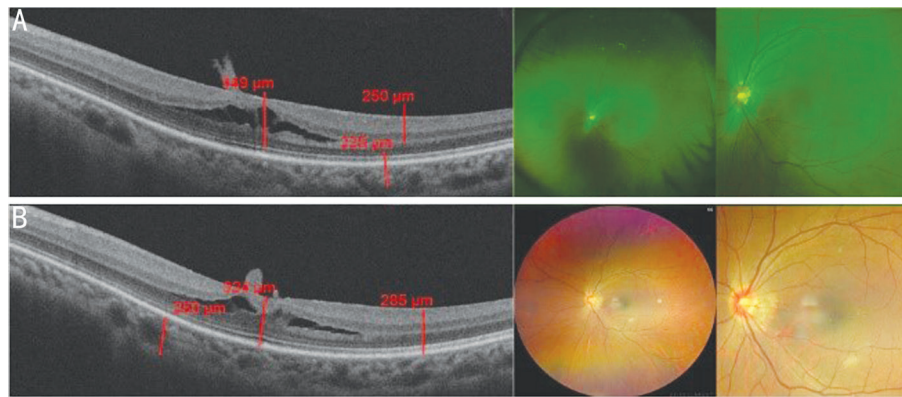


Figure 1 The vertical OCT scans and the corresponding color photographs of the left eye on May 2023 (A) and on September 2023 (B) OCT: Optical coherence tomography.

Authors Reply to the Editor

Dear Editor,

We appreciated for Kameda *et al* for their interest in our study^[1]. This encourages us to continue to follow this case of spontaneous epiretinal membrane (ERM) separation, as suggested.

Indeed, no case of spontaneous ERM release occurring twice in the same eye has yet been reported. We have contacted this patient recently, and obtained her examination reports in May and September in 2023. The report of optical coherence tomography (Carl Zeiss Meditec, Cirrus) and fundus photography still confirmed ERM overlying the macula (Figure 1), which was although less severe than that on August 2021. The ERM was not obvious in the fovea, but it can be recognized in the temporal field. Unfortunately, the patient did not revisit any hospital for further follow-up of the ERM during 2022. The status of the ERM during that time was unknown. We are going to continue the follow-up and report detailed progress to our readers if a second ERM self-separation occurs in this patient.

In the case by Kameda *et al*^[2], the ERM separation could be contributed to the remodeling by myofibroblast contraction. Similarly, the tangential cell-mediated traction along the inner retinal layer^[3] was suspected in our case, which may be further studied and determined if it was myofibroblast contraction.

We thank Yusuke Kameda and other colleagues once again for their attention to our research, as well as their comprehensive study on spontaneous ERM release.

Qiao-Zhu Zeng^{1,2}, Wen-Zhen Yu^{1,2}

¹Department of Ophthalmology, Eye Diseases and Optometry Institute, Peking University People's Hospital, Beijing 100044, China

²Beijing Key Laboratory of Diagnosis and Therapy of Retinal and Choroid Diseases, College of Optometry, Peking University Health Science Center, Beijing 100044, China

Correspondence to: Wen-Zhen Yu. Department of Ophthalmology, Peking University People's Hospital, No.11 Xizhimen South Street, Xicheng District, Beijing 100044, China. wenzhenyubjmu@163.com

REFERENCES

- 1 Zeng QZ, Yu WZ. Recurrence after spontaneous separation of epiretinal membrane in a young woman: a case report. *Int J Ophthalmol* 2023;16(3):476-478.
- 2 Kameda Y, Kaneko Y, Suzuki Y, Tobimatsu Y, Ishinabe K, Fukuoka N. Where did the macular pucker go? *JFO Open Ophthalmol* 2023;3:100047.
- 3 Meyer CH, Rodrigues EB, Mennel S, Schmidt JC, Kroll P. Spontaneous separation of epiretinal membrane in young subjects: personal observations and review of the literature. *Graefes Arch Clin Exp Ophthalmol* 2004;242(12):977-985.