

# Surgical outcomes of complicated cataract with pediatric trematode granulomatous uveitis

Mahmoud M. Farouk, Amr Mounir, Mortada Ahmed Abozaid, Engy Mohamed Mostafa, Marwa Mahmoud Abdellah

Department of Ophthalmology, Sohag Faculty of Medicine, Sohag University, Sohag 82524, Egypt

**Correspondence to:** Amr Mounir. Department of Ophthalmology, Sohag Faculty of Medicine, Sohag University, Sohag 82524, Egypt. drammonir@yahoo.com

Received: 2022-02-02 Accepted: 2023-02-01

DOI:10.18240/ijo.2023.03.04

**Citation:** Farouk MM, Mounir A, Abozaid MA, Mostafa EM, Abdellah MM. Surgical outcomes of complicated cataract with pediatric trematode granulomatous uveitis. *Int J Ophthalmol* 2023;16(3):354-360

## Abstract

• **AIM:** To describe the clinical characteristics and surgical outcomes of complicated cataract with pediatric trematodal granulomatous uveitis (TGU).

• **METHODS:** Patients of cataract with TGU in the membranous (inactive) stage underwent cataract surgery with intraocular lens (IOL) implantation. Preoperative history and ophthalmic examination were conducted for all cases, whereas Schimphlug imaging and corneal topography were done for some patients. Postoperative follow up was done on the 1<sup>st</sup>, 2<sup>nd</sup>, and 5<sup>th</sup> postoperative days after surgery. Then, it was done at least at one, three, and six months postoperatively. Intraoperative and postoperative complications and the methods of their management were reported.

• **RESULTS:** Twelve eyes of 12 male children were included in this study ranging from 8 to 16y. The mean best corrected Snellen visual acuity (BCVA) was significantly improved from 0.09±0.06 preoperatively to 0.37±0.11 at the final visit 6mo postoperatively ( $P<0.001$ ). Schimphlug imaging and corneal topography showed flattening of the anterior surface of the inferior cornea. Intraoperative difficulties and complications included the poor dilatibility of the down pupil, strong posterior synechia between the anterior lens capsule and the iris at the site of the inferior retrocorneal vascularized membrane and hyphema. All cases underwent primary hydrophobic IOL implantation.

• **CONCLUSION:** Surgery for this type of cataract is relatively safe and effective. It is associated with some specific difficulties and complications that should be considered during surgery and follow up.

• **KEYWORDS:** complicated cataract; trematode granulomatous uveitis; surgical outcomes

## INTRODUCTION

The human eye had been reported to be affected by variable parasitic infestations which could affect the uveal tissue<sup>[1-4]</sup>. Presumed trematodal granulomatous uveitis (TGU) is a newly described condition in Egypt and India<sup>[5-7]</sup>. In the past, it was described as posterior phlyctenular keratitis<sup>[8]</sup>. Another recent study defined it as pearl-like lesions in the anterior chamber<sup>[9]</sup>. The condition is considered the most common cause of pediatric anterior uveitis in Egypt (22.2%)<sup>[10]</sup>. This is not the case in worldwide prevalence, as juvenile idiopathic arthritis (JIA) is considered the most common cause<sup>[11-12]</sup>.

The exact etiology of this pearl-like lesion was not clear. In 2002, a study by Rathinam *et al*<sup>[5]</sup> in India concluded that it is due to presumed water-borne trematode infection. In 2012, they investigated these cases by molecular studies and got evidence that the cause was a trematode infestation<sup>[13]</sup>. Another study by the same group used the polymerase chain reaction (PCR) of the aspirated material from this lesion showed that it is due to a particular type of trematode known as *Procerovum varium*<sup>[7]</sup>. A similar study in Egypt concluded that it is also due to trematode infestation without pointing to a specific species<sup>[6]</sup>.

Presumed TGU mainly affects young boys in rural areas with a history of swimming in rivers or ponds. Clinically, it was described to be presented in three forms. The granulomatous form presented by single or multiple white lesions (pearl-like) in the inferior part of the anterior chamber or subconjunctival granuloma with active anterior uveitis in the form of ciliary injection, aqueous cells and posterior synechia. If the nodules evolved into a vascularized retrocorneal membranes they were described as membranous form. Patients who presented with both a membrane and a whitish granuloma at one edge were classified as mixed form<sup>[6-7]</sup>. The condition can be

treated by topical, systemic, and/or periocular injection of steroids<sup>[14-15]</sup>. The fate of the lesion is to end by the formation of a retrocorneal vascularized membrane and resolution of the anterior uveitis<sup>[6,9]</sup>. Reported complications of presumed TGU were cataract (14%), glaucoma, anterior synechiae with severe corectopia and phthisis bulbi<sup>[6]</sup>.

Cataract is the most common complication of presumed TGU<sup>[6]</sup>. The aim of this study was to describe the clinical characteristics of this particular type of cataract and to document the preoperative, intraoperative, and postoperative difficulties and complications of cataract surgery in this disease.

## SUBJECTS AND METHODS

**Ethical Approval** Cases were among the attendants of the outpatient clinic of Sohag University Hospital throughout the period from October 2016 to March 2019. The study followed the tenets of the Declaration of Helsinki, and the approval of the ethics committees was obtained from the "Medical Research Ethics Committee" of Sohag Faculty of Medicine and the approval number was (IBR# S20-132). This study was registered in the Pan-African Clinical Trial Registration with the number PACTR202102855369241.

This study was a prospective, non-comparative, interventional case series including cases of pediatric cataract with presumed TGU in the membranous (inactive) stage. Patients were eligible for this study if they had a visually significant cataract in the absence of active anterior uveitis.

**Preoperative Evaluation** All patients underwent full history taking, including age, gender, residence, history of previous ocular inflammation and its treatment, trauma or surgery. We asked all patients and their families about the habit of swimming in rivers or ponds in rural areas. Any case with previous intraocular surgery or trauma was excluded from the study. All cases should have inactivity of uveitis for at least three months preoperatively.

Complete ophthalmic examination was done for all patients, including best corrected visual acuity (BCVA) in Snellen decimal notation, intraocular pressure (IOP) by I-care ic100 tonometer (ICare Finland Oy, Helsinki, Finland), and slit lamp examination with special emphasis on the anterior chamber reaction, keratic precipitates, the retro-corneal membrane, anterior chamber granuloma, the state of the pupil (size, shape, and dilatability) and lens opacification. Any cases with a pearl-like lesion or active anterior uveitis were excluded. Fundus examination was performed by indirect ophthalmoscopy with full dilatation of the pupil. B-scan ultrasonography was needed if the density of cataract interferes with fundus examination. Schimphlug imaging and corneal topography were done using Sirius Scheimpflug Placido topography (Costruzione Strumenti Oftalmici, Florence, Italy) to some patients who were cooperative to allow the investigator to get a clear image.

Biometry was done by ultrasonography (Digital A/B scan 5500; Sonomed Inc., Lake Success, NY, USA).

Medical assessment, chest radiography, and serological testing were indicated if other causes of granulomatous anterior uveitis were suspected to be excluded from the study. A complete informed consent was obtained for all patients. Any special difficulties in the preoperative evaluation were reported.

**Surgical Details** All cases were operated by the same surgeon (Farouk MM). For dilatation of the pupil, 2.5% phenylephrine hydrochloride and 1% cyclopentolate hydrochloride eye drops were instilled in the conjunctival sac one hour before surgery and repeated as needed. All patients underwent surgery under general anesthesia. Povidone-iodine solution (10%) was used to prepare the periocular skin. The conjunctival sac was irrigated with a povidone-iodine solution (5%) and then washed with a balanced salt solution.

The main incision was made in the clear cornea by a 2.2 mm keratome (Alcon Laboratories, Inc.). The two side-ports were made with a microvitrectomy blade (Alcon Laboratories, Inc.). A high-viscosity ophthalmic viscosurgical device (OVD, sodium hyaluronate 1.0%) was injected through the side port. If posterior synechia was present due to previous inflammation, it was released by blunt spatula. If pupillary dilatation was not enough, iris hooks were used to allow a suitable pupil size to visualize the cataractous lens. Because most cases had a drowned down pupil, three iris hooks were used at 3, 9, and 12 o'clock.

A continuous curvilinear capsulorhexis (CCC) was initiated with a bent cystotome and completed with micro-capsulorhexis forceps. While creating the CCC, the surgeon avoided being close to the inferior retrocorneal vascularized membrane because it is attached to the iris and anterior capsule and can hinder the progression of CCC. Hydrodissection was performed to separate the lens matter from the lens capsule. As all cases were pediatric soft cataract, the phacoemulsification of the nucleus was not needed, and the lens material could be aspirated totally by bimanual automated irrigation/aspiration using Infinity machine (Alcon, Inc.). A foldable hydrophobic single-piece intraocular lens (IOL) was implanted in the bag. A sphincterotomy was made at 12 o'clock if the pupil was drowned down by a micro-scissor.

Iris hooks were removed, the reformation of the anterior chamber was done by a balanced salt solution, and the wounds were hydrated. A 10-0 monofilament nylon suture was placed at the main wound. A subconjunctival injection of 4 mg dexamethasone was done and topical antibiotic (moxifloxacin 0.5%) and steroid (prednisolone acetate 1%) eye drops were administered. Finally, the eye was patched and shielded. Any intraoperative complications and the methods of its management were reported.

**Postoperative Treatment and Follow-up** Postoperative topical treatment included 0.5% moxifloxacin eye drops five times daily, 1% prednisolone acetate eye drops eight times daily, and mydriatic eye drops (1% cyclopentolate hydrochloride) twice daily. Tapering was done according to the inflammatory reaction. Postoperative follow up were done on the 1<sup>st</sup>, 2<sup>nd</sup>, and 5<sup>th</sup> postoperative days. Then, at least at one, three, and six months postoperatively. Each time, the following data were recorded: BCVA and refraction (only at one, three, and six months postoperatively), IOP measurement, a description of the slit-lamp biomicroscopy of the anterior segment, and fundus examination with recording any detected complications. The 10-0 monofilament nylon suture was removed three months postoperatively.

**Statistical Analysis** All analyses were performed using SPSS for windows version 9.0 (SPSS, Inc., Chicago, IL, USA). Data were expressed as mean±standard deviation (SD). A paired Student's *t*-test was used to make statistical comparisons between preoperative and postoperative visual acuity and IOP. A *P*-value <0.05 was considered significant.

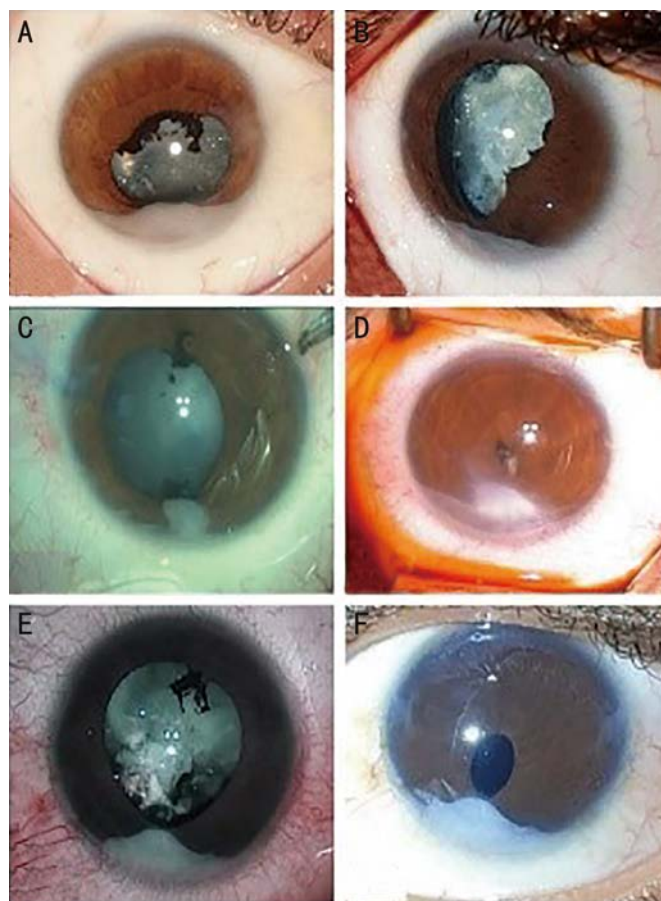
**RESULTS**

This study included 12 eyes of 12 children suffering from visually significant complicated cataract with presumed TGU in the membranous (inactive) stage. All patients were males aged 8 to 16y (mean age was 11.4y). The preoperative data of the 12 cases are summarized in Table 1.

All cases lived in rural areas in Upper Egypt with a history of swimming in rivers or ponds. All cases had monocular involvement. Eight cases (66.7%) gave a clear history of recurrent ocular inflammations managed by topical steroids. One case had a history of periocular injection. None of the cases had any history of ocular trauma or surgery.

Preoperative mean BCVA was 0.09±0.06 Snellen decimal notation (range 0.02–0.2), and the mean IOP was 12.8±2.7 mm Hg. Slit-lamp examination of all cases showed no signs of active anterior uveitis with the characteristic vascularized retrocorneal membranes, indicating the inactive form of pediatric presumed TGU as described by Amin *et al*<sup>[6]</sup>. The pupils showed different degrees of abnormalities. All cases had a poorly dilatable drown-down pupil (towards the retrocorneal membranes). Lens opacification was reported in all cases (Figure 1).

Fundus examination was not possible in most cases due to poor dilatability of the pupil and lens opacification. Only two cases could be examined by indirect ophthalmoscopy showing normal retina with mild vitreous haze. B-scan ultrasonography was done for all cases showing low amplitude vitreous echoes. Schimphlug imaging and corneal topography were done for seven cases showing flattening of the anterior surface of the inferior cornea at the tangential anterior map and depressed posterior surface of the inferior cornea at the posterior elevation



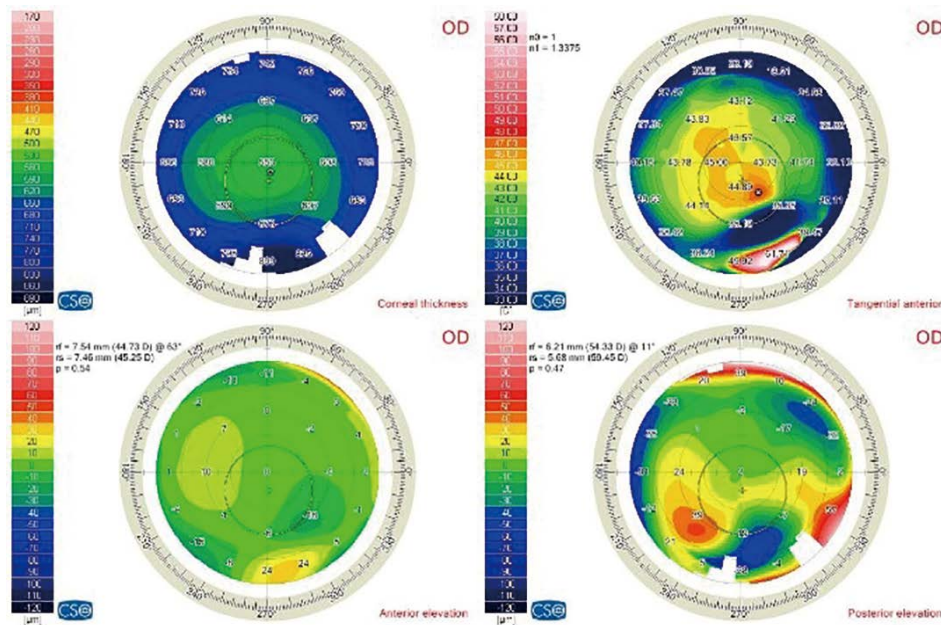
**Figure 1** Cases of complicated cataract with the characteristic vascularized retrocorneal membranes which indicates the inactive form of pediatric trematodal granulomatous uveitis A–C: Dilatable pupil; D: Un-dilatable pupil; E: Preoperative; F: Postoperative.

**Table 1** Preoperative data of the 12 cases of complicated cataract included in this study

Patient	Age (y)	Duration of uveitis (mo)	BCVA (decimal notation)	IOP (mm Hg)
1	8	12	0.05	8
2	11	24	0.02	12
3	16	48	0.1	12
4	12	12	0.1	14
5	14	6	0.05	10
6	10	18	0.16	17
7	15	48	0.2	12
8	10	36	0.2	15
9	9	36	0.02	17
10	8	12	0.05	12
11	11	6	0.1	9
12	13	12	0.02	16

BCVA: Best corrected visual acuity; IOP: Intraocular pressure.

map (Figure 2, Table 2). The superior-inferior difference at the level of 3 mm showed no statistically significant difference between the superior keratometry and inferior keratometry. In contrast, the superior-inferior difference at the level of 5 mm circles showed a statistically significant difference



**Figure 2** A printout of corneal topography of one of the cases of complicated cataract with TGU showing flattening of the anterior surface of inferior cornea at the tangential anterior map and depressed posterior surface of the inferior cornea at the posterior elevation map.

**Table 2** The results of Schimflug imaging and corneal topography for 7 cases showing the data of the tangential anterior map

Patient	Keratometry at 3 mm circle superiorly	Keratometry at 3 mm circle inferiorly	Keratometry at 5 mm circle superiorly	Keratometry at 5 mm circle inferiorly	Superior-inferior difference at 3 mm circle	Superior-inferior difference at 5 mm circle
3	43.57	41.15	43.37	37.76	2.42	5.61
4	43.56	44.89	43.12	35.19	-1.33	7.93
7	42.51	44.69	40.7	36.55	-2.18	4.15
8	44.73	42.29	45.23	37.49	2.44	7.74
10	46.39	45.87	44.56	40.12	0.52	4.44
11	43.22	42.51	42.39	35.21	0.71	7.18
12	41.31	43.93	42.88	38.63	-2.62	4.25
Mean	43.613	43.619	43.179	37.279	-0.006	5.9
SD	1.5	1.6	1.4	1.6	1.9	1.6

between the superior keratometry and inferior keratometry ( $P=0.001$ ; Table 2).

Medical assessment, chest radiography, and serological testing did not show any positive data suggesting other causes of granulomatous anterior uveitis in all cases.

During surgery, the most common difficulty was the poorly dilatable drawn-downward pupil. This problem was reported in all cases (Figure 1). Some cases required the use of iris hooks (3 cases), and one case required a sphincterotomy at 12 o'clock. As the pupil was drawn-down by the inferior retrocorneal membrane at six o'clock, only three iris hokes were needed to dilate the pupil (*i.e.*, at three, nine, and twelve o'clock).

Another difficulty reported intraoperatively was the strong posterior synechia between the anterior lens capsule and the iris at the site of the inferior retrocorneal vascularized membrane because it is attached to the iris and anterior capsule and can hinder the progression of CCC. This problem was reported in six cases and managed by avoiding passing close to this area while making the CCC.

HypHEMA was reported in one case intraoperatively during irrigation-aspiration of lens matter. The source of hypHEMA was the vascularized membrane and precipitated by surgical trauma. The condition was managed intraoperatively by injection of high-viscosity OVD (1.0% sodium hyaluronate) for a few minutes. All cases underwent hydrophobic IOL implantation in the same surgery (none of the cases were left aphakic).

All cases completed a follow-up period of six months. The mean overall BCVA (in Snellen decimal notation) was significantly improved from  $0.09\pm 0.06$  preoperatively to  $0.37\pm 0.11$  at the final visit of six months postoperatively ( $P<0.001$ ). There was also significant improvement at the 1<sup>st</sup> and 3<sup>rd</sup> months postoperatively. The mean BCVA at the 6<sup>th</sup> month was significantly lower than the 1<sup>st</sup> month postoperatively due to the development of posterior capsule opacification. The mean overall preoperative IOP was  $15.14\pm 4.78$  mm Hg. There were no significant changes in the IOP on day five and the 1<sup>st</sup>, 3<sup>rd</sup>, and 6<sup>th</sup> months

**Table 3 Difficulties and complications (intraoperative and postoperative) reported in cases of pediatric cataract with trematodal granulomatous anterior uveitis**

Difficulties and complications	No. of eyes (%)	Notes
Poor dilatability of the down pupil	12 (100)	Some cases required iris hooks and sphincterotomy
Strong posterior synechia	6 (50)	It can hinder the progression of CCC
Hyphema from the vascularized membrane	1 (8.3)	Managed by injection of high-viscosity OVD
Postoperative anterior segment fibrin reaction	2 (16.6)	Managed by increasing the frequency of topical steroid
Postoperative posterior capsule opacification	10 (83)	Affects the BCVA at 6 <sup>th</sup> month postoperatively

CCC: Continuous curvilinear capsulorhexis; OVD: Ophthalmic viscosurgical device; BCVA: Best corrected visual acuity.

postoperatively. The IOP was not measured at the 1<sup>st</sup> and 3<sup>rd</sup> days postoperatively due to patient un-cooperation.

The slit-lamp biomicroscopy examination of the anterior segment showed a fibrin reaction in the anterior chamber in two cases on postoperative days one, two, and five. This complication was managed by increasing the frequency of topical steroid (prednisolone acetate 1%) for one week.

On the 6<sup>th</sup> month postoperatively, it was noted that 10 (83%) cases developed posterior capsule opacification associated with a decreased BCVA. None of the cases showed recurrence of active granulomatous anterior uveitis or any posterior segment pathology during the follow-up period. Specific difficulties and complications (intraoperative and postoperative) reported in this study are summarized in Table 3.

## DISCUSSION

Cataract surgery in children suffering from intraocular inflammations is a challenging condition carrying its own complications<sup>[16-22]</sup>. Most of the studies recommend managing these cases with strong preoperative and postoperative anti-inflammatory treatment, including immunosuppressive therapy to achieve the least incidence of complications and a better visual improvement<sup>[23-25]</sup>. It was reported worldwide that the most common type of pediatric uveitis that can lead to pediatric complicated cataract is JIA<sup>[17-18]</sup>. In the locality of this study, the presumed TGU is the most common cause of this condition and showed a more benign course than JIA<sup>[10]</sup>. This condition was described in India<sup>[5,7]</sup> and may be present in other parts of the third world but unreported.

To the best of our knowledge, this is the first study reporting cataract surgery outcomes in children suffering from presumed TGU. Compared to other studies that evaluated cataract surgery in children suffering from uveitis, we found some differences in the surgical considerations and postoperative outcomes<sup>[19,25]</sup>. This study included 12 eyes of 12 children suffering from cataracts in the inactive stage of presumed TGU for at least three months. No immunosuppressive drugs were needed in this study to control pre- and postoperative intraocular inflammation. All cases were boys aged from 8 to 16y because this age group have the habit of swimming in rivers or ponds in Upper Egypt.

The diagnosis of all cases in this study depended on the typical clinical picture of membranous presumed TGU described in previous studies and the history of swimming in ponds or rivers<sup>[5-7]</sup>. No ancillary tests were used to confirm the diagnosis. In India, Arya *et al*<sup>[7]</sup> isolated the DNA of the trematode from the patient excised granuloma by real-time and conventional PCR. In Egypt, Amin *et al*<sup>[6]</sup> isolated the trematode DNA from the anterior chamber extract. The clinical picture of our cases was the same as described in these studies, and all cases were considered a presumed TGU uveitis in the membranous (inactive) stage.

It is proven by this study that cataract surgery in children with presumed TGU is visually beneficial. BenEzra and Cohen<sup>[17]</sup> reported the same conclusion in children with JIA and idiopathic uveitis. However, the degree of visual gain was more in our study due to the difference in the underlying disease.

The primary implantation of IOL was an essential concern in several studies<sup>[17-18,23]</sup>. Due to the risk of postoperative complications, some studies recommended and others did not recommend to implant the IOL in the same surgery in cases with JIA<sup>[26-27]</sup>.

In our study, primary hydrophobic foldable IOL implantation was done in all cases without any reported complications related to the IOL (except posterior capsule opacification). This issue may be explained by the more benign course of presumed TGU compared to JIA and the low rate of recurrence of inflammation as it is not a systemic disease. The unilateral nature of presumed TGU made the primary IOL implantation the best choice for the optical correction of aphakia. Guindolet *et al*<sup>[16]</sup> recommended the primary implantation of hydrophobic foldable IOL in pediatric chronic uveitis and suggested that few patients suffering from hypotony, IOL-related complications in the other eye, or shallow anterior chamber should be left aphakic. Their study included 14 eyes, most of them suffering from JIA and idiopathic anterior uveitis, but none of their cases suffered from TGU. Yangzes *et al*<sup>[19]</sup> compared the surgical outcomes of pediatric uveitic cataracts with and without primary IOL implantation. They found that secondary procedures were more in the pseudophakic group. In our study, all cases did not require secondary surgical

interventions, which may be due to the difference in the underlying type of uveitis.

This study reported the specific difficulties and complications of cataract surgery in presumed TGU in the membranous (inactive) stage (Table 3). These issues should be taken into consideration in surgery for this specific type of complicated cataract. The most pronounced surgical difficulty was the poorly dilatable down-down pupil (Figure 1). Terrada *et al*<sup>[18]</sup> described the presence of pupillary membranes in cataract cases with pediatric uveitis and the need for pupillary expansion to perform cataract surgery. Iris hooks were described as an efficient method to manage the small pupil in cataract surgery<sup>[28]</sup>. Lu *et al*<sup>[29]</sup> reported that pupilloplasty combined with phacomulsification and IOL implantation improves the visual gain in patients with uveitic cataract and prevents the long-term recurrence of uveitis. In our study, the condition was managed by iris hooks in a specific way described above because the pupil was down-down toward the characteristic retrocorneal membrane at 12 o'clock.

Corneal topography of seven cases of this study showed a characteristic flattening pattern at the site of the retrocorneal membrane, which can be explained by the traction force exerted by the membrane on the back surface of the cornea. This flattening was limited to the periphery (at a line of 5 mm circle) and was not affecting the central 3 mm of the cornea.

In our study none of the cases suffered from significant changes in the IOP postoperatively. Almobarak *et al*<sup>[30]</sup> described that cataract surgery after trabeculectomy for uveitic glaucoma is a safe procedure with minimal visual improvement. None of our cases had previous trabeculectomy or needed trabeculectomy after cataract surgery.

The limitations of this study were the small number of cases and the absence of a specific ancillary test to prove the diagnosis of TGU. Aqueous sampling and analysis by PCR may be recommended to confirm the diagnosis in future studies<sup>[31-32]</sup>.

In conclusion, this specific type of pediatric cataract is not well described in the literature because it is not a worldwide disease. In contrast, it may be the most common type of pediatric uveitic cataract in some parts of the third world. The surgery of this type of cataract is relatively safe and effective. It is associated with some specific difficulties and complications that should be considered during surgery and follow-up.

#### ACKNOWLEDGEMENTS

**Conflicts of Interest:** Farouk MM, None; Mounir A, None; Abozaid MA, None; Mostafa EM, None; Abdallah MM, None.

#### REFERENCES

- Otranto D, Eberhard ML. Zoonotic helminths affecting the human eye. *Parasit Vectors* 2011;4:41.
- Sabrosa NA, Cunningham ET Jr, Arevalo JF. Ocular nematode and trematode infections in the developing world. *Int Ophthalmol Clin* 2010;50(2):71-85.
- Doğan N. Globalisation and ocular parasitic infections: a review of recent studies. *Turkiye Parazitol Derg* 2020;44(4):239-257.
- Esen E, Sizmaz S, Balci S, Ekinci RMK, Demircan N. Clinical features of childhood uveitis at a tertiary referral center in Southern Turkey. *Int Ophthalmol* 2021;41(6):2073-2081.
- Rathinam SR, Usha KR, Rao NA. Presumed trematode-induced granulomatous anterior uveitis: a newly recognized cause of intraocular inflammation in children from south India. *Am J Ophthalmol* 2002; 133(6):773-779.
- Amin RM, Goweida MB, El Goweini HF, Bedda AM, Lotfy WM, Gaballah AH, Nadar AA, Radwan AE. Trematodal granulomatous uveitis in paediatric Egyptian patients: a case series. *Br J Ophthalmol* 2017;101(8):999-1002.
- Arya LK, Rathinam SR, Lalitha P, Kim UR, Ghatani S, Tandon V. Trematode fluke procerovum varium as cause of ocular inflammation in children, south India. *Emerg Infect Dis* 2016;22(2):192-200.
- Gibson GG. Posterior phlyctenular keratitis. Society transactions: College of Physicians of Philadelphia, section on ophthalmology. *Arch Ophthalmol* 1942;29:159-166
- Soliman W, Wasfi EI, Ali OM. Spectral domain optical coherence tomography study of pearl-like lesions in the anterior chamber. *Clin Ophthalmol* 2012;6:903-907.
- Amin RM, Goweida M, Bedda A, Kamel A, Radwan A. Clinical patterns and causes of intraocular inflammation in a uveitis patient cohort from Egypt. *Ocular Immunol Inflamm* 2019;27(6):859-867.
- Sen ES, Ramanan AV. Juvenile idiopathic arthritis-associated uveitis. *Clin Immunol* 2020;211:108322.
- Maleki A, Anesi SD, Look-Why S, Manhapra A, Foster CS. Pediatric uveitis: a comprehensive review. *Surv Ophthalmol* 2022;67(2):510-529.
- Rathinam SR, Arya LK, Usha KR, Prajna L, Tandon V. Novel etiological agent: molecular evidence for trematode-induced anterior uveitis in children. *Arch Ophthalmol* 2012;130(11):1481-1484.
- El Nokrashy A, Abou Samra W, Sobeih D, Lamin AL, Hashish A, Tarshouby S, Lightman S, Sewelam A. Treatment of presumed trematode-induced granulomatous anterior uveitis among children in rural areas of Egypt. *Eye (Lond)* 2019;33(10):1525-1533.
- Amin RM, Radwan AE, Goweida MB, El Goweini HF, Bedda AM, Lotfy WM, Ahmed ARH. Management of presumed trematode induced granulomatous uveitis in pediatric patients. *Jpn J Ophthalmol* 2019;63(1):119-125.
- Guindolet D, Dureau P, Terrada C, Edelson C, Barjol A, Caputo G, LeHoang P, Bodaghi B. Cataract surgery with primary lens implantation in children with chronic uveitis. *Ocular Immunol Inflamm* 2018;26(2):298-304.
- BenEzra D, Cohen E. Cataract surgery in children with chronic uveitis. *Ophthalmology* 2000;107(7):1255-1260.
- Terrada C, Julian K, Cassoux N, Prieur AM, Debre M, Quartier P, LeHoang P, Bodaghi B. Cataract surgery with primary intraocular lens implantation in children with uveitis: long-term outcomes. *J Cataract*

- Refract Surg* 2011;37(11):1977-1983.
- 19 Yangzes S, Seth NG, Singh R, Gupta PC, Jinagal J, Pandav SS, Gupta V, Gupta A, Ram J. Long-term outcomes of cataract surgery in children with uveitis. *Indian J Ophthalmol* 2019;67(4):490-495.
- 20 Kramer M, Tomkins-Netzer O. Cataract risk and topical corticosteroids among children with juvenile idiopathic arthritis-related uveitis. *Ophthalmology* 2020;127(4S):S19-S20.
- 21 O'Rourke M, McCreery K, Kilmartin D, Brosnahan D. Paediatric cataract in the uveitis setting. *Eur J Ophthalmol* 2021;31(5):2651-2658.
- 22 AlAmeer AM, Al Shamrani M. Outcome of cataract surgery in pediatric uveitis (experience at King Khalid Eye Specialist Hospital). *Oman J Ophthalmol* 2022;15(1):43-48.
- 23 Nemet AY, Raz J, Sachs D, Friling R, Neuman R, Kramer M, Pandi SK, Sharma V, Assia EI. Primary intraocular lens implantation in pediatric uveitis: a comparison of 2 populations. *Arch Ophthalmol* 2007;125(3):354-360.
- 24 Rosenberg KD, Feuer WJ, Davis JL. Ocular complications of pediatric uveitis. *Ophthalmology* 2004;111(12):2299-2306.
- 25 Foster CS, Rashid S. Management of coincident cataract and uveitis. *Curr Opin Ophthalmol* 2003;14(1):1-6.
- 26 Magli A, Forte R, Rombetto L, Alessio M. Cataract management in juvenile idiopathic arthritis: simultaneous versus secondary intraocular lens implantation. *Ocular Immunol Inflamm* 2014;22(2):133-137.
- 27 Kulik U, Wiklund A, Kugelberg M, Lundvall A. Long-term results after primary intraocular lens implantation in children with juvenile idiopathic arthritis-associated uveitis. *Eur J Ophthalmol* 2019;29(5):494-498.
- 28 Balal S, Jbari AS, Nitiahpapand R, Cook E, Akhtar W, Din N, Sharma A. Management and outcomes of the small pupil in cataract surgery: iris hooks, Malyugin ring or phenylephrine? *Eye (Lond)* 2021;35(10):2714-2718.
- 29 Lu H, Chen DD, Zhu SQ. Therapeutic potential of pupilloplasty combined with phacomulsification and intraocular lens implantation against uveitis-induced cataract. *Int J Ophthalmol* 2022;15(10):1598-1603.
- 30 Almobarak FA, Alharbi AH, Aljadaan I, Aldhibi H. Phacoemulsification after trabeculectomy in uveitis associated with Vogt-Koyanagi-Harada disease: intermediate-term visual outcome, IOP control and trabeculectomy survival. *BMC Ophthalmol* 2022;22(1):210.
- 31 Minkus CL, Bispo PJM, Papaliodis GN, Sobrin L. Real-time multiplex PCR analysis in infectious uveitis. *Semin Ophthalmol* 2019;34(4):252-255.
- 32 Santos HNVD, Ferracioli-Oda E, Barbosa TS, Otani CSV, Tanaka T, Silva LCSD, Lopes GO, Doi A, Hirata CE, Yamamoto JH. Usefulness of aqueous and vitreous humor analysis in infectious uveitis. *Clinics (Sao Paulo)* 2020;75:e1498.