

Silicone oil injection and removal in 27-gauge vitreous surgery

Yorihisa Kitagawa¹, Hiroyuki Shimada¹, Masayoshi Yukita², Saigen Naruse²

¹Department of Ophthalmology, Nihon University Hospital, 1-6 Surugadai, Kanda, Chiyodaku, Tokyo 101-8309, Japan

²Miyahara Ophthalmological Clinic, Saitama City, Saitama 331-0812, Japan

Correspondence to: Hiroyuki Shimada. Department of Ophthalmology, Nihon University Hospital, 1-6 Surugadai, Kanda, Chiyodaku, Tokyo 101-8309, Japan. sshimada@olive.ocn.ne.jp

Received: 2021-09-19 Accepted: 2022-09-27

DOI:10.18240/ijo.2023.01.21

Citation: Kitagawa Y, Shimada H, Yukita M, Naruse S. Silicone oil injection and removal in 27-gauge vitreous surgery. *Int J Ophthalmol* 2023;16(1):139-142

Dear Editor,

The advent of 23-gauge (G), 25-G, and 27-G vitrectomy systems^[1] since the beginning of the 21st century has allowed vitrectomy *via* a smaller incision compared to the 20-G system; hence the name “microincision vitrectomy surgery”. Microincision vitrectomy surgery has gained popularity among vitreoretinal surgeons. The 27-G vitrectomy has better wound closure than 25-G vitrectomy, and sutureless surgery can be performed in many patients^[2-4]. This modality has become popular as day surgery not only in Europe and the United States but also in Japan^[2-3]. In many facilities, silicon oil injection and removal are performed by connecting a viscous fluid injector (VFI) of the Viscous Fluid Control Pak (Alcon Laboratories, Fort Worth, TX, USA) to the Viscous Fluid Control port of the vitrectomy machine. Currently, a Viscous Fluid Control Pak contains a set of 20-G, 23-G, and 25-G VFI cannulae, but 27-G VFI cannula is not available. Therefore, a method of injecting silicon oil by docking the 25-G VFI cannula into a 27-G cannula by bimanual manipulation was used^[5]. This method has the advantage that the 27-G scleral wound can be preserved and there is no extra cost. However, when silicon oil is injected from the 25-G VFI cannula through the 27-G cannula, there is a concern that high intraocular pressure may cause optic nerve and retinal ischemia^[6]. To address this issue, the manufacturer recommends the “hybrid

27/25-G technique”. In this method, one 25-G cannula is placed, through which a 25-G VFI cannula is inserted for silicon oil injection and removal^[7]. Given this situation, many ophthalmologists choose 25-G vitrectomy from the beginning when performing vitrectomies for proliferative vitreoretinopathy and proliferative diabetic retinopathy, which require silicon oil injection.

Recently, the 27-G VFI cannula (MedOne Surgical, Sarasota, FL, USA) has become available and is compatible with the Viscous Fluid Control in 27-G vitrectomy. Using this cannula, one-handed 27-G silicon oil injection and removal is possible^[8]. The 27-G VFI cannula can be used to inject not only 1000 Centistokes (cSt) silicon oil, but also 5000 cSt silicon oil^[8]. In Japan, 5000 cSt silicon oil is not approved, and only the approved 1000 cSt silicon oil is being used. There is no report comparing 25-G VFI cannula and 27-G VFI cannula for silicon oil injection and removal during 27-G vitrectomy. In this Letter, we report and compare cases using 25-G and 27-G VFI cannulas.

Vitrectomy was performed using the Constellation System (Alcon). A sclerotomy was created by inserting a 27-G trocar/cannula at an oblique angle of 30 degree^[9]. Three 27-G cannulae were placed. Before introducing instruments or silicon oil into the eye, the ocular surface was washed with 0.25% povidone iodine to prevent bacteria on the surface of the eye from entering the eye^[10]. For silicon oil injection and removal, the Viscous Fluid Control function of the vitrectomy machine was used. Injection and removal of silicon oil was performed using a 25-G VFI cannula (Figure 1A) or a 27-G VFI cannula (Figure 2A) connected to a 10-mL syringe.

This study was approved by the Ethical Committee of the Nihon University School of Medicine (No.20161203). The informed consent was obtained from the subjects.

Case 1 A 76-year-old woman presented with vitreous hemorrhage in her left eye. The left eye had an inserted intraocular lens, with best corrected visual acuity (BCVA) of light perception (+). When vitrectomy was performed, bleeding from age-related macular degeneration and retinal detachment were observed. The subretinal bleeding was thick and difficult to remove. Therefore, silicon oil injection was performed after fluid-air replacement. The tip of the 25-G

VFI cannula could not be fully inserted into the 27-G cannula. The intraocular pressure was increased to 30 mm Hg, and compression of the 27-G cannula by the 25-G VFI cannula caused deformation of the eyeball (Figure 1B). The injection pressure during silicon oil injection was 50 psi (pound-force per square inch). During silicon oil injection, air was egressed from the left 27-G cannula using forceps to prevent increase in intraocular pressure. The BCVA 3mo after surgery was light perception (+), and the patient has been followed with silicon oil remaining in her eye.

Case 2 A 52-year-old woman presented with vitreous hemorrhage in her right eye, with BCVA of 20/32. A 27-G vitrectomy was conducted after cataract surgery. When the vitreous hemorrhage was removed, a subretinal hemorrhage was found at the inferior aspect, together with retinal detachment. Therefore, silicon oil injection was performed after fluid-air replacement. One month after surgery, her BCVA improved to 20/20. However, two months after surgery, she was diagnosed with proliferative vitreoretinopathy, and BCVA decreased to 20/630. A silicon buckle was placed at the inferior aspect of her eyeball. Silicon oil removal was performed using a 25-G VFI cannula, with the 27-G cannula secured with forceps and intraocular pressure increased to 40 mm Hg. The 27-G cannula was strongly compressed by the 25G VFI cannula, causing hyphema from the corner (Figure 1C). The silicon oil was removed at a pressure of 500–650 mm Hg. During silicon oil removal, attention was paid to eyeball collapse, because the 25-G VFI cannula was not controlled by the 27-G Viscous Fluid Control. After removal of the hyphema followed by fluid-gas replacement, surgery was completed. Her BCVA improved to 20/63 3mo after surgery.

Case 3 A 59-year-old man presented with a giant retinal tear and detachment in his right eye, with BCVA of 20/63. He underwent 27-G vitrectomy after cataract surgery, and silicon oil injection was performed after fluid-air replacement. At intraocular pressure of 20 mm Hg, a 27-G VFI cannula was inserted into the 27-G cannula (Figure 2B). The injection pressure during silicon oil injection was 50–80 psi. The 27-G VFI cannula was easily inserted. Air inside the eye was egressed through the 27-G cannula using forceps with the left hand. Three months after surgery, since the retina was reattached, silicon oil was removed and corrected visual acuity was 20/32.

Case 4 A 35-year-old man presented with retinal detachment with multiple retinal tears in his left eye, with corrected visual acuity of 20/400. A 27-G vitrectomy was performed following cataract surgery, and silicon oil was injected after fluid-air replacement. The injection pressure during silicon oil injection was 50-80 psi. Since the retina was reattached after surgery, silicon oil was removed 4mo after vitrectomy. His corrected

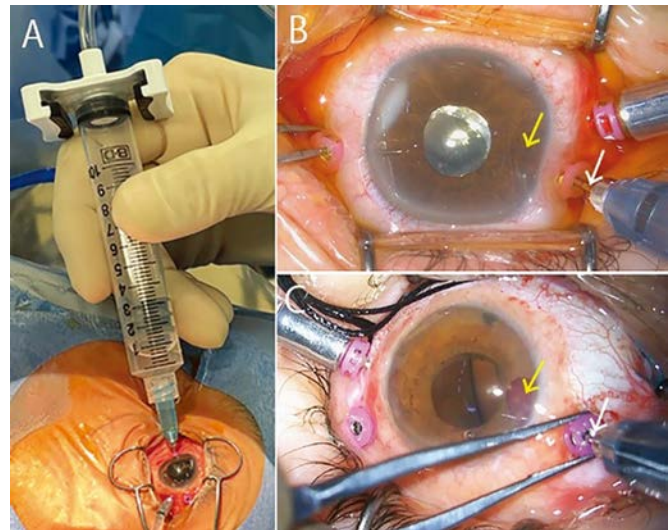


Figure 1 Silicone oil injection and removal using a 25-G VFI cannula A: A 25-G VFI cannula is connected to a 10-mL syringe for injection and removal of silicon oil, without observation using a wide viewing system. B: Silicon oil injection: The tip of the 25-G VFI cannula is not completely inserted into the 27-G cannula (white arrow). The eyeball is deformed from being compressed by the 27-G cannula (yellow arrow). The air in the eye is egressed *via* the 27-G cannula with forceps held by the left hand. C: Silicon oil removal: The tip of the 25-G VFI cannula is not completely inserted into the 27-G cannula (white arrow). Although the 27-G cannula is secured with the forceps in a raised position, hyphema from the corner (yellow arrow) occurs due to eyeball compression. Since the 25-G VFI cannula is not supported by the 27-G Viscous Fluid Control, attention should be paid to eyeball collapse. VFI: Viscous fluid injector.

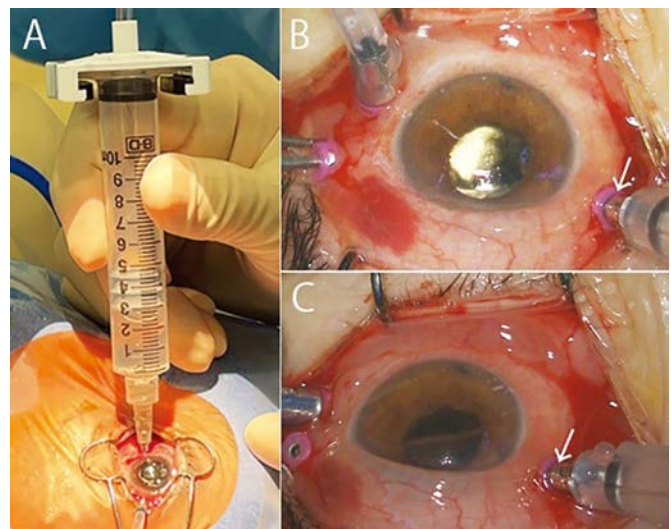


Figure 2 Silicone oil injection and removal using a 27-G VFI cannula A: A 27-G VFI cannula is connected to a 10-mL syringe for injection and removal of silicon oil, without observation using a wide viewing system. B: Silicon oil injection: The tip of the 27-G VFI cannula is inserted into the 27-G cannula (white arrow). The air in the eye is egressed *via* the 27-G cannula with forceps held by the left hand. C: Silicon oil removal: As the tip of the 27-G VFI cannula is fully inserted into the 27-G cannula (white arrow), operation is easy. Since the 27-G VFI cannula is supported by the 27-G Viscous Fluid Control, there is low risk of eyeball collapse. VFI: Viscous fluid injector.

visual acuity was 20/32. At intraocular pressure of 40 mm Hg, a 27-G VFI cannula was inserted into the 27-G cannula (Figure 2C). The silicon oil was removed at a pressure of 500–650 mm Hg. During silicon oil removal, because intraocular pressure at the 27-G VFI cannula was controlled by the 27-G Viscous Fluid Control, his eyeball did not collapse.

Currently, the Viscous Fluid Control Pak contains three VFI cannulae: 20-G (yellow), 23-G (orange), and 25-G (blue). The 27-G (gray) VFI cannula has to be purchased separately. Although extra cost is incurred, the 27-G VFI cannula is compatible with the 27-G Viscous Fluid Control, and surgeons can use it safely and with reassurance. Since the speed of silicon oil injection and removal is regulated by the surgeon's foot pedal, there is individual difference in the time required for these procedures. Before injection and removal of silicone oil, the operation should be checked by injecting and removing irrigation fluid in a cup with the VFI cannula.

When injecting silicon oil using a 25-G or 27-G VFI cannula, the intraocular pressure is set at approximately 20–30 mm Hg. When injecting silicon oil using a 25-G VFI cannula, if the 27-G cannula held by the left hand is inserted into Vent (Alcon) to egress air, the left hand can then hold the forceps to secure the 27-G cannula held by the right hand. This method of silicon oil injection using a 25-G VFI cannula by docking by bimanual manipulation has been reported by Toygar *et al*^[5]. The time required to inject silicon oil is theoretically longer when using the 27-G VFI cannula with smaller diameter. The injection pressure during silicon oil injection is 50–80 psi. The time required for injecting silicon oil using a 27-G VFI cannula has been reported to be 1–2min for 1000 cSt and 3–5min for 5000 cSt silicon oil^[8].

When removing silicon oil using a 25-G VFI cannula, the intraocular pressure is set at approximately 30–40 mm Hg and forceps are used to raise and secure the 27-G cannula. If the 27-G cannula is not firmly secured to the forceps, eyeball deformation due to ocular compression, hyphema from the angle, and air leakage into the syringe will occur. During silicon oil removal, attention should be paid to eyeball collapse, because the 25-G VFI cannula is not controlled by the 27-G Viscous Fluid Control. The silicon oil is removed at a pressure of 500–650 mm Hg. Using a 25-G VFI cannula for silicon oil removal requires firmer fixation to the 27-G cannula than when it is used in silicon oil injection. The time required to remove silicon oil is theoretically longer when using the 27-G VFI cannula with a smaller diameter. When the amount of silicone oil is small, the aspiration pressure is lowered to prevent a sudden drop in intraocular pressure. The 27-G VFI cannula is compatible with the 27-G Viscous Fluid Control, and therefore has low risk of eyeball collapse, allowing operation with reassurance.

During the silicone oil injection procedure using a 27-G VFI cannula, utilizing a light-guide with the left hand would allow brief observation of the fundus with a wide viewing system. However, observing with a wide viewing system using a light guide on the left side of the eye blocks the expulsion of air from the eye, with the risk of increasing intraocular pressure. Note that the 50–80 psi during silicone oil injection is equivalent to 2500–4000 mm Hg, and silicone oil is injected slowly under a very strong force. Therefore, it is important to repeatedly check for increase in intraocular pressure by finger palpation. When injecting silicone oil using a 27-G VFI cannula, it is safer to observe the condition of the silicone oil and the anterior segment of the eye without using a wide viewing system. We reported cases of silicon oil injection and removal using a 25-G VFI cannula or a 27-G VFI cannula during 27-G vitrectomy. The 27-G VFI cannula matches the Viscous Fluid Control of the 27-G vitrectomy system, allowing highly safe silicon oil injection and removal.

ACKNOWLEDGEMENTS

Conflicts of Interest: Kitagawa Y, None; Shimada H, None; Yukita M, None; Naruse S, None.

REFERENCES

- 1 Shinkai Y, Oshima Y, Yoneda K, Kogo J, Imai H, Watanabe A, Matsui Y, Suzuki K, Sotozono C; 27G Vitrectomy Study Group. Multicenter survey of sutureless 27-gauge vitrectomy for primary rhegmatogenous retinal detachment: a consecutive series of 410 cases. *Graefes Arch Clin Exp Ophthalmol* 2019;257(12):2591-2600.
- 2 Mori R, Naruse S, Shimada H. Comparative study of 27-gauge and 25-gauge vitrectomy performed as day surgery. *Int Ophthalmol* 2018;38(4):1575-1582.
- 3 Naruse Z, Shimada H, Mori R. Surgical outcomes of 27-gauge and 25-gauge vitrectomy day surgery for proliferative diabetic retinopathy. *Int Ophthalmol* 2019;39(9):1973-1980.
- 4 Li J, Liu SM, Dong WT, Li F, Zhou CH, Xu XD, Zhong J. Outcomes of transconjunctival sutureless 27-gauge vitrectomy for vitreoretinal diseases. *Int J Ophthalmol* 2018;11(3):408-415.
- 5 Toygar O, Mi CW, Miller DM, Riemann CD. Outcomes of transconjunctival sutureless 27-gauge vitrectomy with silicone oil infusion. *Graefes Arch Clin Exp Ophthalmol* 2016;254(11):2111-2118.
- 6 Takkar B, Venkatesh P, Azad SV, Temkar S. Comments on outcomes of transconjunctival sutureless 27-gauge vitrectomy with silicone oil infusion. *Graefes Arch Clin Exp Ophthalmol* 2016;254(11):2281-2282.
- 7 Yonekawa Y, Thanos A, Abbey AM, Thomas BJ, Todorich B, Faia LJ, Williams-GA, Capone A Jr, Wolfe JD, Hassan TS. Hybrid 25- and 27-gauge vitrectomy for complex vitreoretinal surgery. *Ophthalmic Surg Lasers Imaging Retina* 2016;47(4):352-355.
- 8 Toygar O, Mi CW, Miller DM, Riemann CD. Reply to the comment on "Outcomes of transconjunctival sutureless 27-gauge vitrectomy with silicone oil infusion". *Graefes Arch Clin Exp Ophthalmol* 2016;254(11):2283.

9 Chen PL, Chen YT, Chen SN. Comparison of 27-gauge and 25-gauge vitrectomy in the management of tractional retinal detachment secondary to proliferative diabetic retinopathy. *PLoS One* 2021;16(3):e0249139.

10 Grzybowski A, Shimada H, Nakashizuka H, Koerner J. Low-concentration povidone-iodine for the prevention of intraocular infections in ophthalmic surgery. *Curr Opin Ophthalmol* 2021;33(1):28-34.