

Clinical observation of recombinant human nerve growth factor in the treatment of neurotrophic keratitis

Mi Hao, Yan Cheng, Jie Wu, Yu Cheng, Jing Wang

Department of Ophthalmology, First Affiliated Hospital of Northwest University, Xi'an No.1 Hospital, Shaanxi Institute of Ophthalmology, Xi'an 710002, Shaanxi Province, China

Co-first authors: Mi Hao and Yan Cheng

Correspondence to: Jie Wu. Department of Ophthalmology, First Affiliated Hospital of Northwest University, Xi'an No.1 Hospital, Shaanxi Institute of Ophthalmology, Xi'an 710002, Shaanxi Province, China. wutu63@163.com

Received: 2022-09-01 Accepted: 2022-11-11

Abstract

• **AIM:** To characterize changes of corneal nerve morphology and tear indices in patients with neurotrophic keratitis (NK) treated with recombinant human nerve growth factor (rhNGF).

• **METHODS:** In a prospective observational study, six patients (nine eyes) were locally treated with rhNGF. Visual acuity, corneal fluorescein staining score, the heights of the tear river, lipid layer thickness (LLT), tear ferning (TF) test, conjunctival impression cytology (CIC) examination, the densities of cornea subbasal nerve fibers were determined before and after treatment.

• **RESULTS:** Compared with baseline, there was a significant difference in corneal fluorescence staining scores ($P < 0.01$); all patient corneal epithelial defects recovered completely within 8wk, but there was no significant improvement in the height of the tear river ($P = 0.202$). LLT was significantly increased when compared with baseline ($P = 0.042$); however, the function of conjunctival goblet cells and mucin content did not significantly improve using the TF test and CIC examination ($P = 0.557$, $P = 0.539$). After 8wk of treatment, the average corneal subbasal nerve fiber density increased significantly ($P < 0.01$), as did the number of corneal nerve fiber branches ($P = 0.001$).

• **CONCLUSION:** RhNGF can increase the density of corneal subbasal nerve fibers, promote the healing of persistent corneal epithelial defects and corneal ulcers in patients with NK, also improving tear function partially.

• **KEYWORDS:** recombinant human nerve growth factor; neurotrophic keratitis; corneal subbasal nerve

DOI:10.18240/ijo.2023.01.09

Citation: Hao M, Cheng Y, Wu J, Cheng Y, Wang J. Clinical observation of recombinant human nerve growth factor in the treatment of neurotrophic keratitis. *Int J Ophthalmol* 2023;16(1):60-66

INTRODUCTION

Neurotrophic keratitis (NK) is a degenerative disease of the cornea caused by trigeminal nerve injury, including virus infection, trauma, surgery, inflammation and other factors, decreased corneal perception and nutritional disorder after denervation, weakened defenses against external harmful factors, dry eye, corneal epithelial defects and corneal ulcers, and corneal stroma melting and perforations^[1].

The principle of NK treatment is to prevent the progression of corneal injury and improve corneal trigeminal innervation, to restore the nutritional supply of corneal nerves, and promote corneal renewal and healing^[2]. Current treatments for NK include autologous serum, preservative-free artificial tears, a corneal bandage lens, and an amniotic membrane transplantation^[3]. The best treatment involves restoring the trophic supply of corneal nerves, as well as stimulating corneal re-innervation and healing. As a neurotrophic factor and immunomodulatory factor, nerve growth factor (NGF) plays an important role in the survival, growth, and differentiation of sensory neurons, as well as in promoting wound healing^[4]. Recombinant human NGF (rhNGF) has the same structure as endogenous NGF, so it can quickly promote corneal wound healing and improve the corneal perception and tear production^[5].

RhNGF (cenegermin, 20 µg/mL of rhNGF) has been clinically used in Europe, United States, etc, and has been shown to aid in the recovery of corneal nerve function^[6-8]. Cenegermin has been presently approved for clinical treatment of moderate or severe NK, which is the only effective biotherapy for clinical treatment of this disorder, but there is no relevant research reports in China. The purpose of this study was explored the clinical efficacy of rhNGF for corneal nerve regeneration and corneal epithelial healing in NK patients in China.

SUBJECTS AND METHODS

Ethical Approval This study was approved by the Ethics Committee of Xi'an No.1 Hospital (Approval No.2021-11), and followed the tenets of the Declaration of Helsinki. The

number of Clinical Trial Registry is ChiCTR2100053592. The diagnosis and treatment processes were described in detail to the patients and their families, and informed consent was signed with the consent of the patients' families.

Six patients (nine eyes) with NK diagnosed in our hospital from January 2021 to June 2021 were collected. All patients received cenegermin six times a day for 8wk. Other drugs included 0.05% cyclosporine eye drops, twice a day; 0.3% gatifloxacin eye drops, twice a day; and vitamin A palmitate ophthalmic gel once a night. At baseline and at 2, 4, 6, and 8wk of treatment, the patients underwent eye examinations, including visual acuity, slit lamp examination, corneal fluorescein staining, *in vivo* confocal microscopy *etc.*

Inclusion criteria included patients diagnosed as moderate or severe NK at our hospital. And after more than 4wk of traditional treatment, including antibiotics, artificial tears, autologous sera, corneal bandage lenses *etc.*, the corneal lesion area still was not healed, the depth of keratopathy was less than two-thirds, and there was no perforation and/or stromal melting.

Exclusion criteria included infectious corneal ulcers, peripheral corneal ulcers associated with autoimmune diseases, endophthalmitis, corneal dystrophies, glaucoma patients who needed to change the treatment plan midway according to the specific conditions of their eyes, and patients with loss of follow-up and incomplete data records.

Visual acuity examination was conducted using the international standard visual acuity chart, and the best-corrected visual acuity (BCVA) at baseline and 8wk after treatment were recorded.

For the corneal fluorescence staining score, sodium fluorescein was dropped into the conjunctival sac of the affected eye, the staining of the corneal epithelium was observed with cobalt blue light under a slit lamp, and the corneal staining results were recorded using a 0-12 point scale. First, the cornea was divided into four quadrants involving the supranasal, infranasal, supratemporal, and infratemporal quadrants. According to the degree of staining and staining area, it was divided into 0-3 scores (0: no staining, 1 scores: less than 5 points, 3 scores: flake staining, and 2 scores: between 1 and 3 scores).

For *in vivo* confocal microscopy (IVCM; HRT II Rostock Cornea Module; Heidelberg Engineering, Heidelberg, Germany), the central part of the cornea and the superior, inferior, nasal, and temporal quadrants were scanned, and the NeuronJ analysis plug-in in Image J software (National Institutes of Health, Bethesda, MD, USA) was used to track the density and the number of nerve branches of the corneal subbasal nerves. The images were processed anonymously before analysis to avoid statistician bias. The nerve fiber density was calculated in $\mu\text{m}/\text{mm}^2$. In each picture, the number of subbasal nerve fiber branches and nerve fiber bifurcation

points were counted and reported as numbers. Ten different IVCM images were selected to calculate the average corneal nerve density and number of nerve branches and bifurcations.

For the corneal sensation test, cotton was twisted at the end of the disinfection cotton swab into a slender cotton yarn and bent to 45° with the cotton stick. The approach involved the side of the tested eye with the tip of cotton filament, which gently touched the cornea. The resulting judgments involved those with normal corneal sensation who immediately had a reflex blink or perception response. The absence of a blinking reflex indicated a decrease or disappearance of corneal perception.

The tear index used the Keratograph 5M (Oculus, Wetzlar, Germany), which automatically measured the height of the tear river before and after stimulation during non-contact conditions. A LipiView II interferometer (TearScience Inc, Morrisville, NC, USA) used the white light interference principle and specular reflection method to directly evaluate the color of the tear film interference light, indirect measurement of lipid layer thickness (LLT).

For the conjunctival impression cytology (CIC) examination, a prepared cellulose acetate filter paper was taken from the conjunctiva of the lower eyelid after ocular surface anesthesia and placed on a slide. A total of 1-2 drops of 100 mg/L acridine orange saline solution was added to the filter membrane. After 3-5min, the fluorescence was observed using a fluorescence microscope. According to the number and morphology of cells attached to the filter paper, the cells were graded according to the Tseng classification^[9] (grade V).

For the tear ferning (TF) test, tears from the fornix of the affected eye were collected with a capillary glass tube and coated on clean slides. After drying, according to the appearance of the crystal-like branched ferns, it was roughly divided into four grades: grade I was a large and compact continuous dendritic distribution; grade II was a small, sparse, and scattered dendritic distribution; grade III was rarely a dendritic distribution, accompanied by a large number of vacuoles; and grade IV was a complete loss of fern-like appearance, with only the clustered mucus.

Statistical Analysis The data were analyzed by SPSS statistical software for Windows, version 23.0 (SPSS, Chicago, IL, USA). The Shapiro-Wilke test was used to test the normal distribution, and the mean and standard deviation (SD) were used to represent mean±SD. Variables in accordance with the normal distribution were analyzed by repeated measurement analysis of variance, and variables that did not correspond with the normal distribution were tested using a nonparametric Friedman test. All tests were two-sided and a level of statistical significance was set at $P<0.05$.

RESULTS

The general data of six NK patients in this study are shown

Table 1 General data of patients

Patients number	Age (y)	Sex	Eye	Primary disease
1	4	Female	Right	Trigeminal nerve injury caused by craniocerebral trauma, half a year after biological keratoplasty
2	7	Female	Right	Scleroderma
3	34	Female	Double	Dry eye
4	47	Female	Double	Dry eye, hypothyroidism
5	61	Male	Right	2y after biological keratoplasty, type 2 diabetes mellitus
6	40	Male	Double	Chemical burn (acid)

NK: Neurotrophic keratitis.

Table 2 Changes of corneal fluorescence staining score, conjunctival imprinting cytology, and the tear fern test at baseline and after rhNGF treatment

Ocular surface related score items	Baseline	2wk	4wk	6wk	8wk	P (Friedman)
Corneal fluorescein staining score	5.89±2.71	4.22±3.07	2.67±2.83	1.00±2.65	0.00±0.00	<0.01
Conjunctival Impression cytology grading	2.00±0.71	2.22±0.44	2.22±0.44	2.56±0.73	2.22±0.83	0.557
Tear ferning test grading	2.67±0.50	2.78±0.44	2.67±0.50	2.78±0.44	2.89±0.60	0.539

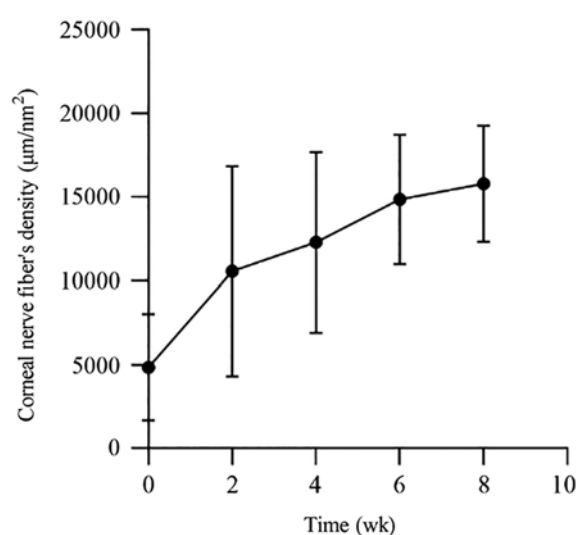
rhNGF: Recombinant human nerve growth factor.

in Table 1. All patients were from 4-61 years of age, with an average age of 32.17 ± 22.55 y. There were four females and two males, as shown in Table 1.

The average BCVA of NK patients at baseline and 8wk after treatment were 0.27 ± 0.51 and 0.18 ± 0.33 , respectively ($P=0.414$). It could not be determined whether the visual acuity of patients with NK could be improved after treatment. Corneal fluorescence staining using a slit lamp showed that all patients had corneal epithelial defects. After 2wk of treatment, complete corneal healing was observed in two eyes of one patient; after 4wk of treatment, corneal ulcers were completely healed in four eyes of three patients; and after 8wk of treatment, all corneal ulcers of patients were completely healed. After 8wk of rhNGF treatment, the score of corneal fluorescent staining was significantly lower than that of the baseline, and the difference was statistically significant ($P<0.01$), as shown in Table 2.

For the tear-related index, as shown in Table 3, there was no significant difference in the height of the tear river before and after rhNGF treatment ($P=0.202$), with the same height of the tear river after stimulation ($P=0.081$). After 8wk of treatment, there was a significant increase in the thickness of the lipid layer ($P=0.042$). The grades of CIC and TF shown in Table 2 were not significantly improved after treatment with rhNGF ($P=0.557$, $P=0.539$). It could not be considered that rhNGF significantly increased tear secretion and the mucin.

Regarding morphological changes of corneal nerve fibers *in vivo* using confocal microscopy, at baseline, the corneal subbasal nerve fibers of NK patients were sparse, uneven in thickness, and irregular in course. After 8wk of treatment, the density of corneal subbasal nerve fibers increased and progressed normally. Table 4 shows that the density of subbasal nerve fibers significantly increased from the second

**Figure 1 Changes of the corneal nerve fiber density at baseline and after rhNGF treatment.**

week to the eighth week after treatment, which was statistically significant ($P<0.01$). At the same time, Figure 1 shows that the corneal nerve fiber density increased gradually with the progression of treatment. When the density of nerve fibers increased, the number of ramification and bifurcation points of subbasal nerve fibers significantly increased ($P=0.001$, $P=0.003$). Figure 2 shows that an NK patient's IVCN images. Regarding corneal sensation, because of the limitation of conditions, the corneal sensation of patients could not be measured quantitatively in the course of this treatment. We only measured the changes of corneal sensation using the cotton silk method. At baseline, the corneal sensation decreased in eight eyes and disappeared in one eye, and after 8wk of treatment, the corneal sensation was basically normal in two eyes, decreased in six eyes, and disappeared in one eye.

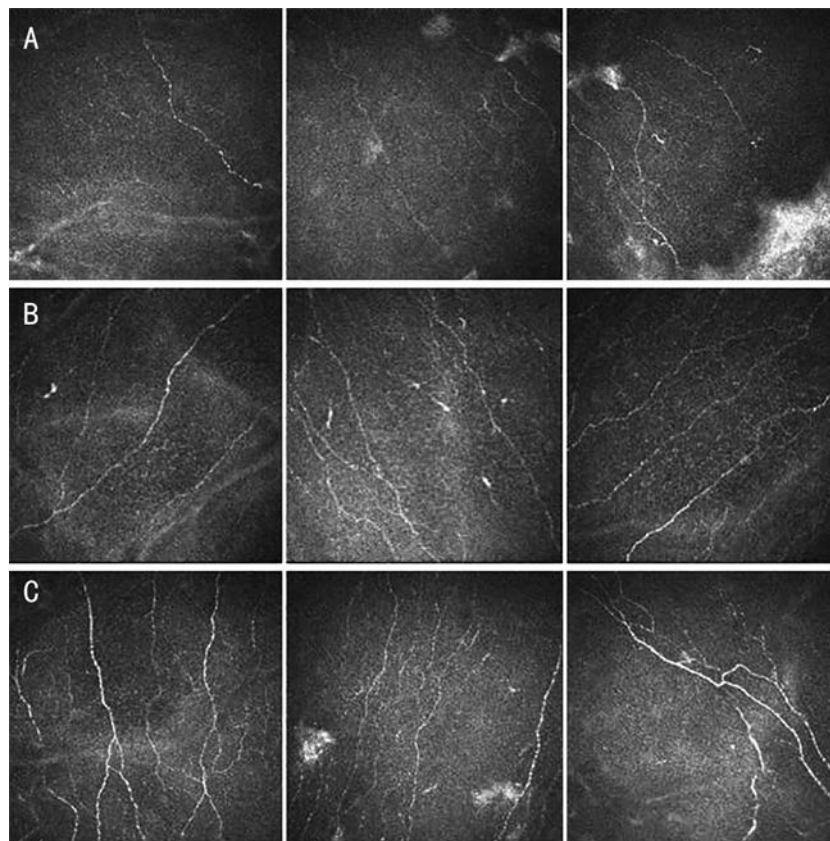


Figure 2 *In vivo* confocal microscopy analysis Representative images of a case of NK, male, 40-year-old, affected by chemical burn (acid). A: The nerve fibers evaluated at baseline were sparse, uneven in thickness; B: Nerve fiber density, ramification and bifurcation point showed a significant increase at week 4 of treatment with recombinant human nerve growth factor; C: The improvement was maintained at the 8-week follow-up.

Tear indices	Baseline	2wk	4wk	6wk	8wk	<i>F</i>	<i>P</i>	mean±SD
Tear river height (mm)	0.16±0.07	0.17±0.04	0.17±0.07	0.18±0.08	0.21±0.10	1.69	0.202	
Tear river height after stimulation (mm)	0.24±0.09	0.29±0.11	0.24±0.06	0.23±0.08	0.36±0.23	3.96	0.081	
LLT (nm)	64.11±18.98	47.22±14.70	49.44±12.76	66.22±21.38	69.33±16.91	3.52	0.042	

rhNGF: Recombinant human nerve growth factor; LLT: Lipid layer thickness.

Corneal nerve fibers	Baseline	2wk	4wk	6wk	8wk	<i>F</i>	<i>P</i>	mean±SD
Density (µm/mm ²)	4833.76±3176.91	10563.06±6275.79	12311.97±5414.21	14869.13±3875.11	15804.13±3477.85	25.49	<0.01	
Ramification (<i>n</i>)	2.92	7.57	9.22	11.21	12.33	15.97	0.001	
Bifurcation point (<i>n</i>)	2.12	5.16	6.41	7.40	9.03	11.81	0.003	

rhNGF: Recombinant human nerve growth factor.

DISCUSSION

The cornea is innervated by ocular branches of the trigeminal nerve, including the long ciliary, short ciliary, and autonomic nerves. It is the most densely distributed tissue of nerve fibers in the entire body. The corneal nerve is very important in maintaining the stability of the ocular surface and the normal function of the cornea. It can trigger protective reflexes such as blinking and tears by causing ocular symptoms such as pain and irritation. It can also provide nutritional support for ocular surface tissue by releasing neurotransmitters, which promote wound healing and maintain the integrity of the

anatomical structure. Corneal denervation causes decreased vitality, decreased metabolism, and mitosis of epithelial cells, with subsequent epithelial cell changes, including intracellular edema, loss of microvilli, and abnormal development of the basal lamina, accompanied by slow corneal wound healing^[1,10-11]. Sensory innervation injury leads to the decrease or complete loss of corneal sensitivity, resulting in refractory corneal ulcers, including NK.

Regarding the relationship between corneal nerve and epithelial cell integrity^[12], the corneal nerve promotes corneal epithelial cell proliferation, migration, and differentiation, as well as

nerve development and survival by releasing a variety of nerve mediators, which involve substance P, calcitonin gene-related peptide, acetylcholine, norepinephrine *etc.* In addition, corneal epithelial cells release a variety of neurotrophic growth factors, including NGF, ciliary neurotrophic factor, and glial cell line-derived neurotrophic factor, which are the basis of ocular surface balance and wound healing^[13]. NGF can be synthesized and secreted by the corneal epithelium, stroma, endothelial cells, limbal stem cells, and conjunctiva. NGF can bind to two receptor proteins, high affinity receptor (tropomyosin receptor kinase A, TrkA) and low affinity receptor (p75 neurotrophin receptor, p75NTR), to maintain cell survival and promote cell migration, proliferation, and differentiation^[14].

Bonini *et al*^[15] reported that after treatment with 20 µg/mL rhNGF, the area of keratopathy was reduced by 49.8%, and corneal healing was 58.0% at week 4 (<0.5 mm lesion staining). At 8wk, 74.0% of the patients' corneas healed. There was a significant difference between the 20 µg/mL rhNGF group and the control group ($P < 0.01$). In the follow-up of patients with corneal healing, there were few corneal epithelial defects or corneal ulcer recurrences. Pflugfelder *et al*^[8] showed in a multicenter, randomized, double-blind, case-control study that corneal healing occurred in 16 (69.6%) of 23 patients treated with rhNGF at week 8, and seven (29.2%) of 24 patients in the control group ($P = 0.006$). Our results showed that corneal healing was 44.4% at week 4 and 100% at week 8. Previous studies have also shown that corneal defects in the initial treatment were negatively correlated with the results the larger the defect, the less likely the healing^[8,12].

Mastropasqua *et al*^[7] evaluated the healing of the corneal nerve and epithelium after treatment of NK with rhNGF. The results showed that corneal ulcer healing was associated with corneal subbasal nerve regeneration, and the average density of subbasal nerve fibers was significantly higher than the baseline at the 4th and 8th weeks after treatment. The density of nerve fibers, the number of nerve branches, and the diameter of nerve fibers significantly increased, and the differences were statistically significant. These morphological changes were observed as early as 4wk after treatment, but the rate of improvement decreased after 4wk. However, the corneal nerve density, nerve fiber branches, and diameter did not reach values observed in the healthy control group. Our study showed that the density of subbasal nerve fibers and the number of nerves in NK patients significantly increased after treatment. The difference before and after treatment was statistically significant, but did not reach the corneal nerve fiber density of healthy patients reported in previous studies.

The complex relationship between corneal epithelial cells and nerves is very important in maintaining corneal physiological function and wound healing. The impairment

of corneal perception will also hinder this nutritional relationship^[12]. Previous studies reported that the corneal sensation was not completely related to changes of the subbasal plexus^[16-17]. It was therefore speculated that the sensory and nutritional functions of trigeminal nerve fibers existed as separate entities, at least partially independent of each other^[18]. These results suggested that corneal perception measurement may not be sufficient to determine the specific nutritional functions of corneal nerve fibers. To characterize the structural changes of corneal nerve fibers, accurate imaging and quantitative analysis of the subbasal plexus are needed. IVCM is considered to be the gold standard for diagnosis^[19]. Previous studies^[10] reported that the density of corneal subbasal nerve fibers in severe NK patients were lower than those in mild to moderate patients, which was similar to the decrease in corneal perception in mild to moderate patients, and was the most important diagnostic basis for the density and number of corneal nerve fibers. When the density of corneal subbasal nerve fibers significantly decreased in patients with mild NK, the risk of developing epithelial defects significantly increased. Persistent epithelial defects (PEDs) with severe reduction of the subbasal nerve are more likely to develop stromal ulcers, resulting in severe NK. Based on the results of the present study, we need to further quantitatively monitor corneal perception in order to determine changes in corneal nerve functions.

Deeks and Lamb^[12] reported that the visual acuity of patients did not provide a statistically significant advantage after 8wk of rhNGF treatment, so the analysis of visual acuity may not necessarily reflect the severity or healing state of NK^[15], when considering that the cornea is usually opaque during healing, and re-epithelialization of the central or para-central cornea may lead to optical aberrations, which leads to a loss of eyesight. The results of the present study showed that there was no statistical difference in visual acuity before and after treatment, which is consistent with previous studies. At the same time, it must be considered that it was related to scar formation in the process of corneal repair.

Increasing evidence has shown that NGF regulated tear production and maintained tear film homeostasis, suggesting the potential role of NGF in the treatment of dry eye^[20-21], the increase of NGF in tears was the result of ocular surface injury in stimulating corneal healing. The researchers also studied the role of NGF in limbal stem cell differentiation, herpetic keratitis, dry eye, and corneal allograft rejection, suggesting that NGF was effective in the local treatment of other ocular surface diseases^[22-24]. NGF regulates tear film function through receptor-binding nerve reflexes, which is expressed by tear glands, and induces goblet cell differentiation and mucin production^[25-26].

Our results showed that the thickness of the lipid layer increased after 8wk of treatment with rhNGF. It was speculated that rhNGF promoted the secretion of lipid components by the Meibomian gland and maintained the stability of tear film by repairing corneal or conjunctival nerve fibers and improving the tear regulatory reflex pathway. The height of the tear river was no significant difference with baseline. According to the results of the CIC examination and TF test, the function of conjunctival goblet cells was not significantly improved. The possible reasons included the following: first, it has been thought that the height of tear river measured by an ocular surface analyzer and the height of tear river after stimulation may be affected by many factors; second, it may be related to the etiology of the patients, such as chemical burns and moderate and severe dry eye surface inflammation, resulting in conjunctival goblet cell damage; and finally, it may be related to the small sample size, which still needs to be increased in further studies.

In conclusion, we found that rhNGF can stimulate the healing of corneal epithelial cells, contribute to the repair and regeneration of injured nerves in Chinese patients with NK, and obtain a good clinical effect. However, this study failed to obtain the changes in the sensory function of corneal nerve fibers, which needs further study. In short, rhNGF is a welcome non-surgical treatment option for this challenging degenerative disease.

ACKNOWLEDGEMENTS

Foundation: Supported by the Shaanxi Provincial Department of Science and Technology (No.2021SF-331).

Conflicts of Interest: Hao M, None; Cheng Y, None; Wu J, None; Cheng Y, None; Wang J, None.

REFERENCES

- 1 Keratology Group of Ophthalmology Branch of Chinese Medical Association. Consensus of experts on diagnosis and treatment of neurotrophic keratitis in China (2021). *Zhonghua Yan Ke Za Zhi* 2021;57(2):90-94.
- 2 Semeraro F, Forbice E, Romano V, Angi M, Romano MR, Filippelli ME, di Iorio R, Costagliola C. Neurotrophic keratitis. *Ophthalmologica* 2014;231(4):191-197.
- 3 Dohlman TH, Singh RB, Dana R. Advances in the medical management of neurotrophic keratitis. *Semin Ophthalmol* 2021;36(4):335-340.
- 4 Lambiase A, Sacchetti M, Bonini S. Nerve growth factor therapy for corneal disease. *Curr Opin Ophthalmol* 2012;23(4):296-302.
- 5 Bonzano C, Olivari S, Cutolo CA, Macri A, Sindaco D, Borroni D, Bonzano E, Traverso CE. Recombinant human nerve growth factor (cenegermin)-driven corneal wound healing process: an evidence-based analysis. *Front Pharmacol* 2022;12:760507.
- 6 Rocco ML, Soligo M, Manni L, Aloe L. Nerve growth factor: early studies and recent clinical trials. *Curr Neuropharmacol* 2018;16(10):1455-1465.

- 7 Mastropasqua L, Lanzini M, Dua HS, D' Uffizi A, di Nicola M, Calienno R, Bondi J, Said DG, Nubile M. *In vivo* evaluation of corneal nerves and epithelial healing after treatment with recombinant nerve growth factor for neurotrophic keratopathy. *Am J Ophthalmol* 2020;217:278-286.
- 8 Pflugfelder SC, Massaro-Giordano M, Perez VL, et al. Topical recombinant human nerve growth factor (cenegermin) for neurotrophic keratopathy. *Ophthalmology* 2020;127(1):14-26.
- 9 Tseng SCG. Staging of conjunctival squamous metaplasia by impression cytology. *Ophthalmology* 1985;92(6):728-733.
- 10 Mastropasqua L, Massaro-Giordano G, Nubile M, Sacchetti M. Understanding the pathogenesis of neurotrophic keratitis: the role of corneal nerves. *J Cell Physiol* 2017;232(4):717-724.
- 11 Mastropasqua L, Nubile M, Lanzini M, Calienno R, Dua HS. *In vivo* microscopic and optical coherence tomography classification of neurotrophic keratopathy. *J Cell Physiol* 2019;234(5):6108-6115.
- 12 Deeks ED, Lamb YN. Cenegermin: a review in neurotrophic keratitis. *Drugs* 2020;80(5):489-494.
- 13 Versura P, Giannaccare G, Pellegrini M, Sebastiani S, Campos EC. Neurotrophic keratitis: current challenges and future prospects. *Eye Brain* 2018;10:37-45.
- 14 Li B, Sheng X, Bao LH, Huang SY, Li QL, Liu YN, Han YY, Watanabe G, Taya K, Weng Q. Seasonal changes in expression of nerve growth factor and its receptors TrkA and p75 in the ovary of wild ground squirrel (*Citellus dauricus* Brandt). *J Ovarian Res* 2014;7:3.
- 15 Bonini S, Lambiase A, Rama P, Sinigaglia F, Allegretti M, Chao W, Mantelli F, REPARO Study Group. Phase II randomized, double-masked, vehicle-controlled trial of recombinant human nerve growth factor for neurotrophic keratitis. *Ophthalmology* 2018;125(9):1332-1343.
- 16 Gatzoufas Z, Labiris G, Hafezi F, Schnaidt A, Pajic B, Langenbucher A, Seitz B. Corneal sensitivity and morphology of the corneal subbasal nerve plexus in primary congenital glaucoma. *Eye (Lond)* 2014;28(4):466-471.
- 17 Dhillon VK, Elalfy MS, Al-Aqaba M, Dua HS. Anaesthetic corneas with intact sub-basal nerve plexus. *Br J Ophthalmol* 2014;98(3):417-418.
- 18 Dhillon VK, Elalfy MS, Al-Aqaba M, Gupta A, Basu S, Dua HS. Corneal hypoesthesia with normal sub-basal nerve density following surgery for trigeminal neuralgia. *Acta Ophthalmol* 2016; 94(1):e6-e10.
- 19 Cruzat A, Qazi Y, Hamrah P. *In vivo* confocal microscopy of corneal nerves in health and disease. *Ocular Surf* 2017;15(1):15-47.
- 20 Gong QW, Zhang SS, Jiang L, Lin M, Xu ZQ, Yu Y, Wang QM, Lu F, Hu L. The effect of nerve growth factor on corneal nerve regeneration and dry eye after LASIK. *Exp Eye Res* 2021;203:108428.
- 21 Cortes M, Esposito G, Sacco R, Gillet VB, Ianni A, Micera A. NGF and iNOS changes in tears from video display terminal workers. *Curr Eye Res* 2018;43(9):1119-1125.
- 22 Lambiase A, Coassin M, Costa N, Lauretti P, Micera A, Ghinelli E, Aloe L, Rama P, Bonini S. Topical treatment with nerve growth

- factor in an animal model of herpetic keratitis. *Graefes Arch Clin Exp Ophthalmol* 2008;246(1):121-127.
- 23 Sacchetti M, Lambiase A, Schmidl D, Schmetterer L, Ferrari M, Mantelli F, Allegretti M, Garhofer G. Effect of recombinant human nerve growth factor eye drops in patients with dry eye: a phase IIa, open label, multiple-dose study. *Br J Ophthalmol* 2020;104(1):127-135.
- 24 Hamrah P, Yavuz Saricay L, Ozmen MC. Cutting edge: topical recombinant nerve growth factor for the treatment of neurotrophic keratopathy-biologicals as a novel therapy for neurotrophic keratopathy. *Cornea* 2022;41(6):673-679.
- 25 Lambiase A, Micera A, Pellegrini G, Merlo D, Rama P, De Luca M, Bonini S, Bonini S. *In vitro* evidence of nerve growth factor effects on human conjunctival epithelial cell differentiation and mucin gene expression. *Invest Ophthalmol Vis Sci* 2009;50(10):4622-4630.
- 26 Muzi S, Colafrancesco V, Sornelli F, Mantelli F, Lambiase A, Aloe L. Nerve growth factor in the developing and adult lacrimal glands of rat with and without inherited retinitis pigmentosa. *Cornea* 2010;29(10):1163-1168.