

Altered spontaneous brain activity patterns in patients with hyperthyroidism exophthalmos using amplitude of low-frequency fluctuation: a resting-state fMRI study

Ling Ling^{1,2}, Wen-Feng Liu³, Yu Guo⁴, Rong-Bin Liang², Hui-Ye Shu², Li-Juan Zhang², Qiu-Yu Li², Qian-Min Ge², Yi-Cong Pan², Yi Shao²

¹Affiliated Eye Hospital of Nanchang University, Nanchang 330006, Jiangxi Province, China

²Department of Ophthalmology, the First Affiliated Hospital of Nanchang University, Jiangxi Province Clinical Ophthalmology Institute, Nanchang 330006, Jiangxi Province, China

³Department of Hepatic Oncology, Zhongshan Hospital, Fudan University, Shanghai 200032, China

⁴Department of Radiology, the First Affiliated Hospital of Nanchang University, Nanchang 330006, Jiangxi Province, China

Co-first authors: Ling Ling and Wen-Feng Liu

Correspondence to: Yi Shao. Department of Ophthalmology, the First Affiliated Hospital of Nanchang University, No.17, Yong Wai Zheng Street, Dong Hu District, Nanchang 330006, Jiangxi Province, China. freebee99@163.com

Received: 2020-07-23 Accepted: 2020-12-16

Abstract

• **AIM:** To assess changed spontaneous brain activity in hyperthyroid exophthalmos (HE) patients by the amplitude of the low-frequency fluctuation (ALFF) method, and to analyze the correlation between brain activity and ALFF values in these patients.

• **METHODS:** Totally 18 HE and 18 hyperthyroid non-exophthalmos (HNE) patients were enrolled. The participants were tested by resting-state functional magnetic resonance imaging, and receiver operating characteristic (ROC) curves were generated to classify the ALFF values of the study population. Pearson's correlation analysis was utilized to evaluate the relationship between the ALFF values obtained from different brain areas and clinical manifestations.

• **RESULTS:** Contrary to HNE patients, we observed lower ALFF values in the left calcarine fissure and surrounding cortex (LCFSC) in HE patients. In the ROC curve analysis of the LCFSC, the area under the curve reflected a high degree of accuracy. In addition, there was positive correlation between mean ALFF values of the LCFSC and the best-corrected visual acuity of the affected eyes.

• **CONCLUSION:** The study displays abnormal brain activity in LCFSC in patients with HE, which might suggest pathological mechanism of visual impairment of HE patients.

• **KEYWORDS:** hyperthyroid exophthalmos; amplitude of low-frequency fluctuation; functional magnetic resonance imaging; spontaneous brain activity

DOI:10.18240/ijo.2021.12.22

Citation: Ling L, Liu WF, Guo Y, Liang RB, Shu HY, Zhang LJ, Li QY, Ge QM, Pan YC, Shao Y. Altered spontaneous brain activity patterns in patients with hyperthyroidism exophthalmos using amplitude of low-frequency fluctuation: a resting-state fMRI study. *Int J Ophthalmol* 2021;14(12):1957-1962

INTRODUCTION

Hyperthyroidism is a prevalent disorder in which an excess of hormones is synthesized and secreted by the thyroid gland. Hyperthyroid exophthalmos (HE) is a common and refractory complication of hyperthyroidism and the most frequent symptom of thyroid eye disease, occurring in 20%-30% of Graves' disease and 40%-70% of Graves' orbitopathy patients^[1-2]. Although HE can be asymmetric or unilateral, both eyes are equally affected in most patients. The characteristics of proptosis include inflammation, impaired eyeball movement, eyelid retraction, and vision loss^[3]. Even mild ocular changes can have a significant negative effect on the facial appearance and life quality^[4].

Proptosis is one of the characteristic ocular manifestations of HE patients^[5]. HE patients usually were afraid of light and had diplopia, eye swelling and foreign body sensation. Optic neuropathy might be a serious complication because of orbital apex muscle hypertrophy and edema. Large parts of these HE patients may have different degree of vision defects. The conventional modalities used for diagnosis of the disease, only identify changes in the eye itself. As far as we know, scanty study has concentrated on variations in spontaneous brain activity in HE patients. Additionally, the clinical management of HE is inadequate, mainly because available treatment methods do not target the specific pathogenesis^[6].

Functional magnetic resonance imaging (fMRI) is a powerful tool which can help to clarify the relationship between HE and dysfunction in various brain regions. fMRI is the main approach used to localize and quantify brain activity and is useful for brain functional connectivity analyses. The most widely used mode is blood oxygenation level-dependent fMRI, which reflects local neuronal activation and is used to investigate brain activity associated with cognitive function. Resting-state MRI (rs-fMRI), in which the patient is not required to think while engaged with a specific task, is the main paradigm to detect brain functional organization.

Low-frequency oscillation of the rs-fMRI signal is closely related to spontaneous neuronal activity. In previous studies, ALFF method has shown the advantage of good-to-moderate test-retest reliability^[7]. ALFF method has been utilized to the study of neurodegenerative^[8-9], psychiatric^[10], and endocrine diseases^[11-12]. However, it has not yet been applied to the study of HE. Here, we used the ALFF to explore the correlation between changes in brain activity and clinical symptoms in HE patients.

SUBJECTS AND METHODS

Ethical Approval The study received approval from the Medical Ethics Committee of the First Affiliated Hospital of Nanchang University, and abided by the Declaration of Helsinki. Informed consent was obtained from all individual participants included in the study.

Patients Totally 18 HE patients and 18 hyperthyroid non-exophthalmos (HNE) patients who were recruited between November 2017 and August 2018. The inclusion criteria for HE patients ($n=18$; 8 males, 10 females) were as follows: 1) male patients aged 18-60y and female patients aged 18-65y; 2) diagnosed with hyperthyroidism according to the 2016 guidelines established by the American Thyroid Association^[13]; 3) meeting the Bratly diagnostic criteria for HE; 4) bilateral exophthalmos and orbital computed tomography examination showed extraocular muscle hypertrophy; 5) clinical activity score for HE ≥ 3 ; 6) no obvious neurological or sensory dysfunction; 7) not receiving any treatment; and 8) right-handedness. The exclusion criteria were: 1) patients that had previously undergone intraocular or extraocular surgery; 2) patients who had other eye diseases such as vascular disease and infection and diseases which can caused eyelid retraction, exophthalmos and extraocular muscle hypertrophy; 3) mental disorders, cardiovascular disease, and other systemic diseases; 4) history of severe cranial or cerebral trauma; 5) evidence of unstable physical diseases and other endocrine or autoimmune diseases; 6) pregnancy; and 7) contraindications for/intolerance to MRI scanning (*e.g.*, claustrophobia, heart pacemakers, or other metallic/ferromagnetic implanted devices).

Eighteen HNE patients (8 males, 10 females) who were matched in education level, age, and sex with HE patients

constituted the control group. The inclusion criteria were: 1) meeting specific criteria for the diagnosis of hyperthyroidism^[13]; 2) no signs of exophthalmos; 3) no obvious neurological or sensory dysfunction; 4) not receiving any treatment; 5) right-handedness; and 6) no contraindications for/intolerance to MRI scanning.

MRI Parameters MRI scans were performed with a Trio 3-Tesla MR scanner (Siemens, Munich, Germany). Functional data were obtained with a three-dimensional spoiled gradient recalled-echo pulse sequence: acquisition matrix=256×256, field of view=250×250 mm², echo time (TE)=2.26ms, repetition time (TR)=1900ms, thickness=1.0 mm, gap=0.5 mm, and turning angle=9°. A total of 240 functional images (acquisition matrix=64×64, field of view=220×220 mm², thickness=4.0 mm, gap=1.2 mm, TR=2000ms, TE=30ms, flip angle=90°, 29 axial) were acquired.

fMRI Data Analysis MRICro software was applied to classify the functional data. DPARSF 4.0 software was utilized for head motion correction, spatial normalization and slice timing. Full-width smoothing with a Gaussian kernel of 6×6×6 mm³ at half-maximum was based on the rs-fMRI Data Analysis Toolkit and SPM8 software. The effects of head motion were removed using six head motion parameters, which was reported to be more effective^[14]. Linear regression also involved removing false variables from other sources, including regions of interest (ROIs) in the ventricular region and white matter. Then, functional images were standardized to standard of the Montreal Neurological Institute.

Brain-Behavior Correlation Analysis REST software was applied to organize encephalic regions with different ALFF values between the two groups. The mean ALFF value was then calculated for each group by averaging all voxels. What's more, the correlation between the average ALFF value and behavioral performance was examined by Pearson's correlation analysis.

Statistical Analysis Data pertaining to the clinical characteristics of the HE and HNE groups were analyzed with the independent samples *t* test using SPSS 20.0 software (IBM Corp, Armonk, NY, USA), with $P<0.05$ taken as the threshold of significance for inter-group differences. The general linear model was utilized to compare the difference between patients with HE and control group. Calibration was performed for a cluster size >40 voxels, with a significance level of $P<0.01$. ALFF values in brain regions of HE and HNE patients were classified based on receiver operating characteristic (ROC) curves.

RESULTS

Demographic and Clinical Information on the Study Population There were no differences between HE and HNE patients in terms of sex, age, weight, handedness, intraocular pressure, and serum free triiodothyronine, free thyroxine, and

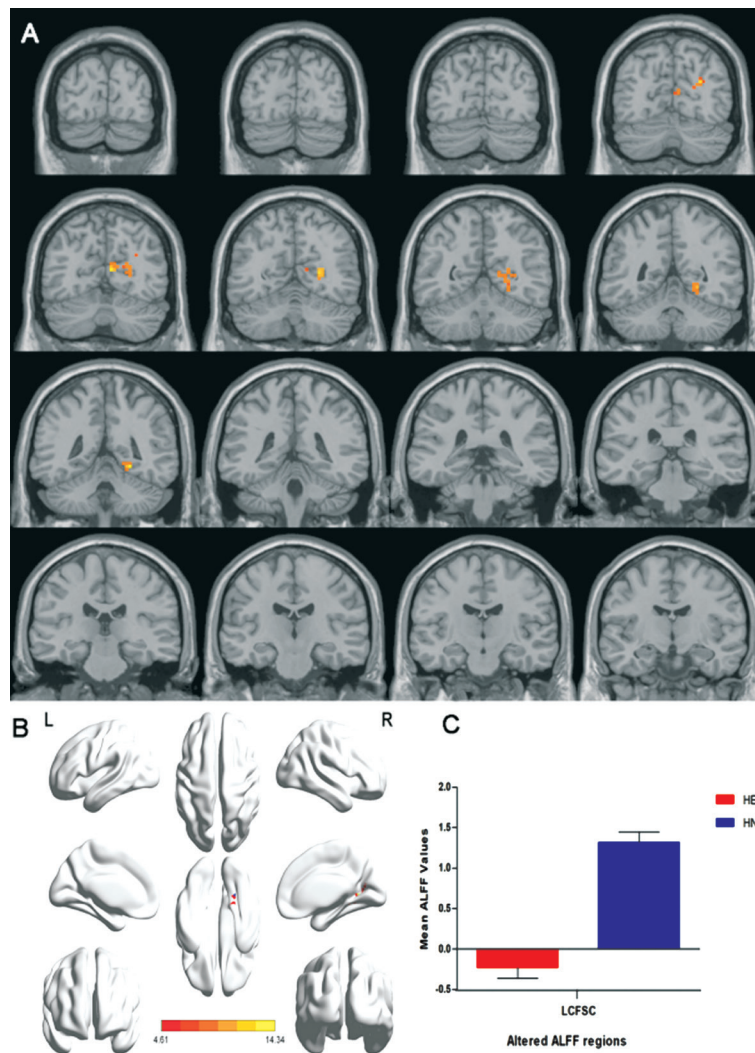


Figure 1 Comparison of average ALFF values between HE and HNE patients A: ALFF values in the LCFS differed significantly between HE and HNE patients; B: Stereoscopic form of the cerebrum; C: Mean altered ALFF values in HE and HNE patients. Red areas denote reduced ALFF values. ALFF: Amplitude of the low-frequency fluctuation; HE: Hyperthyroid exophthalmos; HNE: Hyperthyroid non-exophthalmos; LCFS: Left calcarine fissure and surrounding cortex.

thyroid-stimulating hormone levels (Table 1). Nevertheless, remarkable differences in the duration of hyperthyroidism ($P=0.041$), best-corrected visual acuity for left and right eyes (BCVA-L and -R, respectively; both $P<0.001$) were observed (Table 1).

ALFF Values HE patients displayed reduced ALFF values in the left calcarine fissure and surrounding cortex (LCFS) than HNE patients (Figure 1 and Table 2). And the ALFF values of the two groups were -0.23 ± 0.13 and 1.31 ± 0.13 , respectively (Figure 1C).

Correlation Analysis In HE group, mean ALFF values of the LCFS were positively correlated with BCVA-L ($r=0.713$, $P=0.001$) and BCVA-R ($r=0.659$, $P=0.003$; Figure 2).

ROC Curve The area under the curve (AUC) represents the rate of diagnosis; values between 0.5-0.7 and 0.7-0.9 suggest a limited and perfect diagnostic value, respectively, whereas values >0.9 suggest high accuracy. Here the AUC of the LCFS ROC curve was 1.000 ($P<0.001$; Figure 3), with sensitivity and specificity of 0.944 and 1.000.

Table 1 Demographics and measurements by groups

Condition	HE	HNE	<i>t</i>	<i>P</i> ^a
Male/female	8/10	8/10	-	>0.99
Age (y)	52 ± 6	54 ± 7	0.178	0.989
Weight (kg)	53.82 ± 6.86	55.72 ± 7.12	0.088	0.692
Handedness	18R	18R	-	>0.99
Duration of hyperthyroidism (y)	11.01 ± 5.98	12.82 ± 6.13	0.079	0.041
BCVA-L	0.83 ± 0.13	0.99 ± 0.02	-5.274	<0.001
BCVA-R	0.77 ± 0.15	0.98 ± 0.04	-6.108	<0.001
IOP-L (mm Hg)	18.12 ± 3.98	17.23 ± 2.47	0.081	0.884
IOP-R (mm Hg)	18.71 ± 3.87	19.14 ± 2.91	0.078	0.711
Ocular protrusion-L (mm)	16.97 ± 1.29	13.09 ± 0.38	12.253	<0.001
Ocular protrusion-R (mm)	17.31 ± 1.52	13.06 ± 0.36	12.351	<0.001
FT3 (pmol/L)	10.78 ± 2.79	9.91 ± 3.11	0.065	0.325
FT4 (ng/dL)	3.74 ± 1.93	3.62 ± 2.19	0.059	0.391
TSH (uIU/mL)	0.12 ± 0.02	0.14 ± 0.04	0.071	0.502

Independent *t*-tests comparing the two groups. HE: Hyperthyroid exophthalmos; HNE: Hyperthyroid non-exophthalmos; IOP: Intraocular pressure; L: Left; R: Right; BCVA: Best-corrected visual acuity; FT: Free triiodothyronine; TSH: Thyroid-stimulating hormone.

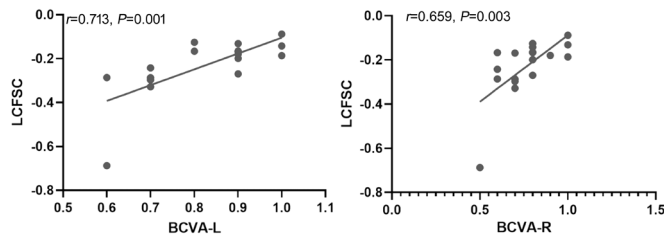


Figure 2 Correlations between mean ALFF values and clinical symptoms BCVA of the left and right eyes were positively correlated with mean ALFF values of the LCFSC (L: $r=0.713$, $P=0.001$; R: $r=0.659$, $P=0.003$). BCVA: Best-corrected visual acuity; ALFF: Amplitude of the low-frequency fluctuation; LCFSC: Left calcarine fissure and surrounding cortex; L: Left; R: Right.

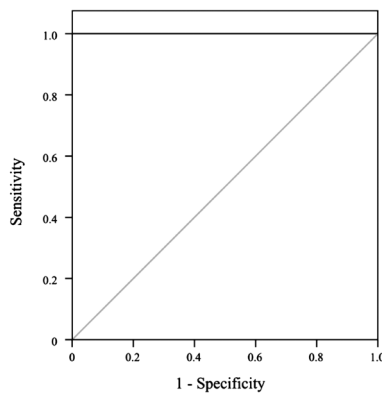


Figure 3 ROC curve analysis of mean ALFF values in the LCFSC The area under the ROC curve was 1.000 ($P<0.001$; 95% confidence interval: 1.000-1.000) for LCFSC (HE<HNE). ROC: Receiver operating characteristic; ALFF: Amplitude of the low-frequency fluctuation; LCFSC: Left calcarine fissure and surrounding cortex; HE: Hyperthyroid exophthalmos; HNE: Hyperthyroid non-exophthalmos.

Table 2 Brain regions with significant differences in ALFF between HE patients and HNEs

Brain areas	BA	T-values	Peak voxels	MNI coordinates		
				x	y	z
LCFSC	19.30	14.343	97	6	-66	12

The statistical threshold was set at voxel with $P<0.05$. ALFF: Amplitude of the low-frequency fluctuation; HE: Hyperthyroid exophthalmos; HNE: Hyperthyroid non-exophthalmos; MNI: Montreal Neurological Institute; LCFSC: The left calcarine fissure and surrounding cortex; BA: Brodmann area.

DISCUSSION

Previous rs-fMRI researches focus on exploring neural activity in functionally related distant brain regions^[15]. Experiments on the visual and sensorimotor systems and cognition have revealed that these networks are based on anatomical connections among neural subsystems^[16]. Rs-fMRI is particularly useful in clarifying the relationship between spontaneous activity in the central nervous system and behavior. ALFF is a widely used analytical technique in rs-fMRI that serves as an indicator of brain disease status; it has

been effectively applied to various ophthalmic diseases^[17-24] (Figure 4). This was the first study evaluating brain activity in HE patients using ALFF method. We observed HE patients displayed lower ALFF values in the LCFSC compared with HNE patients (Figure 5).

The superior (cuneus) and inferior (lingual gyrus) banks of alcarine fissure constitute the primary cortical projection area for vision. The cuneus forms the primary visual cortex (V1), the initial site of visual information processing^[25]. Previous studies have reported a reduction in gray matter volume in the cuneus gyrus and lingual gyrus in patients with strabismus^[26]. In addition, patients with acute eye pain showed declined grey matter volume in the right cuneus, indicating dysfunction of the right cuneus^[27]. Meanwhile, there are numerous reports of patients with amblyopic signs exhibiting decreased cerebral blood flow and reduced activation in V1 during visual stimulation^[28-29]. In an fMRI study of infants with periventricular leukomalacia, a decreased blood oxygenation level-dependent signal was recorded in the calcarine fissure, revealing cortical visual impairment in these patients^[30]. Moreover, previous studies found that the functional connectivity between V1 and the lingual gyrus was reduced in amblyopia and comitant exotropia patients^[31-32]. These findings suggest that visual deficits are related to changes in activity in V1 and the lingual gyrus. In accordance with the results of previous fMRI studies, patients with monocular blindness showed decreased voxel-mirrored homotopic connectivity and ALFF values in the cuneus, indicating that monocular blindness disrupts functional connectivity and spontaneous brain activity in the cuneus^[24,33]. However, higher ALFF values were reported for the left cuneus in patients with optic neuritis and unilateral acute open globe injury^[21,23] as well as those with strabismus and amblyopia^[34], possibly reflecting compensation for visual deficiency. In the present study, the HE group showed lower ALFF values—indicating dysfunction—in the LCFSC. What’s more, there were positively correlations between ALFF value of the LCFSC and the BCVA of both eyes. Based on these findings, we proposed that visual deficiency associated with HE could lead to dysfunction of the LCFSC. In this study, the AUC of the LCFSC was 1.000, suggesting that the ALFF values of changed brain region had a diagnostic accuracy for the distinguish of HE.

The present study had some limitations. On the one hand, the study design was cross-sectional. The number of subjects was relatively small, which could influence the observed differences between groups. On the other hand, although our study found a correlation between ALFF values of the LCFSC and HE, it remains unclear how HE symptoms induce activity changes in the brain; additional studies are needed to explain the molecular mechanisms.

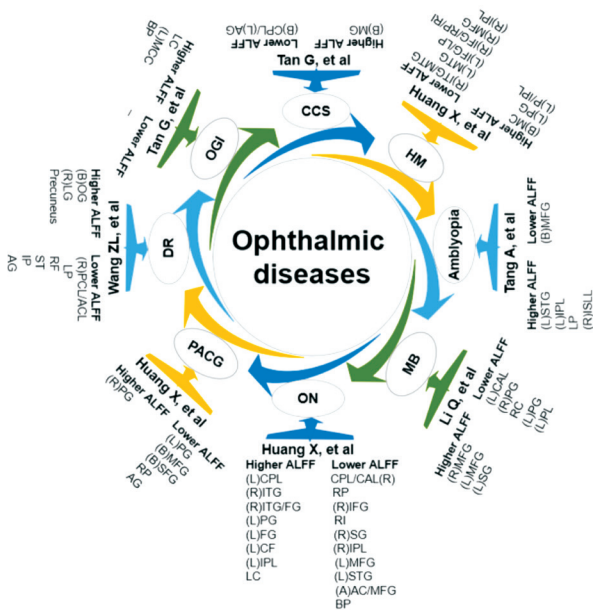


Figure 4 ALFF method applied to ophthalmic diseases ON: Optic neuritis; MB: Monocular blindness; CCS: Congenital comitant strabismus; OGI: Open globe injury; DR: Diabetic retinopathy; PACG: Primary angle-closure glaucoma; HM: High myopic; R: Right; L: Left; B: Bilateral; CPL/CAL: Posterior and anterior lobes of cerebellum; RP: Right putamen; IFG: Inferior frontal gyrus; RI: Right insula; SG: Supramarginal gyrus; IPL: Inferior parietal lobule; MFG: Medial frontal gyrus; STG: Superior temporal gyrus; AC: Anterior cingulate; BP: Bilateral precuneus; ITG: Inferior temporal gyrus; IFG: Inferior fusiform gyrus; PG: Parahippocampal gyrus; FG: Fusiform gyrus; CF: Calcarine fissure; LC: Left cuneus; RC: Right cuneus; PL: Paracentral lobule; LP: Left pons; ISLL: Inferior semi-lunar lobe; MTG: Middle temporal gyrus; LP: Left putamen; MC: Midcingulate cortex; PG: Postcentral gyrus; PL: Precuneus lobule; MG: Medialfrontal gyrus; AG: Angular gyrus; MCC: Middle cingulum cortex; OG: Occipital gyrus; LG: Lingual gyrus; LP: Left parahippocampal; RF: Right fusiform; ST: Superior temporal; IP: Inferior parietal; SFG: Superior frontal gyrus; RP: Right precuneus.

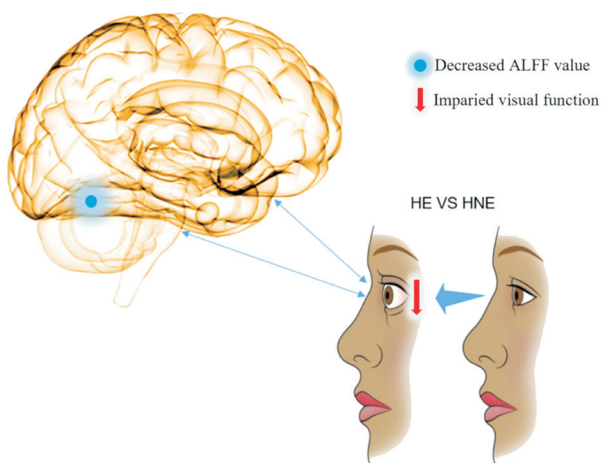


Figure 5 ALFF values of brain regions altered in HE patients ALFF values of the LCFSC (BA19/30) were decreased in HE as compared to HNE patients. ALFF: Amplitude of the low-frequency fluctuation; HE: Hyperthyroid exophthalmos; HNE: Hyperthyroid non-exophthalmos; LCFSC: Left calcarine fissure and surrounding cortex.

To sum up, the results suggested the HE patients exhibited abnormal activity in LCFSC. Moreover, our results showed that this abnormal activity may be associated with the visual impairment of exophthalmos. These findings might have implications for pathological mechanism of visual impairment of HE patients.

ACKNOWLEDGEMENTS

Foundations: Supported by the National Natural Science Foundation (No.82160195); Central Government Guides Local Science and Technology Development Foundation (No.20211ZDG02003); Key Research Foundation of Jiangxi Province (No.20181BBG70004; No.20203BBG73059); Excellent Talents Development Project of Jiangxi Province (No.20192BCBL23020).

Conflicts of Interest: Ling L, None; Liu WF, None; Guo Y, None; Liang RB, None; Shu HY, None; Zhang LJ, None; Li QY, None; Ge QM, None; Pan YC, None; Shao Y, None.

REFERENCES

- Bartalena L. Diagnosis and management of Graves disease: a global overview. *Nat Rev Endocrinol* 2013;9(12):724-734.
- Joffe BI, Panz VR, Yamada M, Wall JR. Thyroid-associated ophthalmopathy in black South Africans with Graves' disease: relationship to serum antibodies reactive against eye muscle and orbital connective tissue autoantigens. *Endocrine* 2000;13(3):325-328.
- Uccello G, Vassallo P, Strianese D, Bonavolonta G. Free levator complex recession in Graves' ophthalmopathy Our experience. *Orbit* 1994;13(3):119-123.
- Estcourt S, Quinn AG, Vaidya B. Quality of life in thyroid eye disease: impact of quality of care. *Eur J Endocrinol* 2011;164(5):649-655.
- Lindholm J, Laurberg P. Hyperthyroidism, exophthalmos, and goiter: historical notes on the orbitopathy. *Thyroid* 2010;20(3):291-300.
- Bartalena L, Baldeschi L, Boboridis K, Eckstein A, Kahaly GJ, Marcocci C, Perros P, Salvi M, Wiersinga WM, European Group on Graves' Orbitopathy (EUGOGO). The 2016 European thyroid association/European group on Graves' orbitopathy guidelines for the management of Graves' orbitopathy. *Eur Thyroid J* 2016; 5(1):9-26.
- Jing B, Liu CH, Ma X, Yan HG, Zhuo ZZ, Zhang Y, Wang SH, Li HY, Wang CY. Difference in amplitude of low-frequency fluctuation between currently depressed and remitted females with major depressive disorder. *Brain Res* 2013;1540:74-83.
- Qiao PF, Niu GM. The application of ALFF to the idiopathic complex partial seizures epilepsy of teenagers. *Neurol Psychiatry Brain Res* 2015;21(1):27-32.
- Yao NL, Pang S, Cheung C, Chang RSK, Lau KK, Suckling J, Yu K, Mak HKF, McAlonan G, Ho SL, Chua SE. Resting activity in visual and corticostriatal pathways in Parkinson's disease with hallucinations. *Park Relat Disord* 2015;21(2):131-137.
- Wang L, Kong QM, Li K, Su YN, Zeng YW, Zhang QG, Dai WJ, Xia MR, Wang G, Jin Z, Yu X, Si TM. Frequency-dependent changes in

- amplitude of low-frequency oscillations in depression: a resting-state fMRI study. *Neurosci Lett* 2016;614:105-111.
- 11 Xia WQ, Wang SH, Sun ZL, Bai F, Zhou Y, Yang Y, Wang P, Huang Y, Yuan Y. Altered baseline brain activity in type 2 diabetes: a resting-state fMRI study. *Psychoneuroendocrinology* 2013;38(11):2493-2501.
 - 12 Zhi MM, Hou ZH, We Q, Zhang YQ, Li L, Yuan YG. Abnormal spontaneous brain activity is associated with impaired emotion and cognition in hyperthyroidism: a rs-fMRI study. *Behav Brain Res* 2018;351:188-194.
 - 13 Ross DS, Burch HB, Cooper DS, Greenlee MC, Laurberg P, Maia AL, Rivkees SA, Samuels M, Sosa JA, Stan MN, Walter MA. 2016 American thyroid association guidelines for diagnosis and management of hyperthyroidism and other causes of thyrotoxicosis. *Thyroid* 2016;26(10):1343-1421.
 - 14 Hagemeyer J, Weinstock-Guttman B, Bergsland N, Heininen-Brown M, Carl E, Kennedy C, Magnano C, Hojnacki D, Dwyer MG, Zivadinov R. Iron deposition on SWI-filtered phase in the subcortical deep gray matter of patients with clinically isolated syndrome may precede structure-specific atrophy. *AJNR Am J Neuroradiol* 2012;33(8):1596-1601.
 - 15 Amemiya S, Takao H, Hanaoka S, Ohtomo K. Global and structured waves of rs-fMRI signal identified as putative propagation of spontaneous neural activity. *Neuroimage* 2016;133:331-340.
 - 16 Bernard JA, Seidler RD. Relationships between regional cerebellar volume and sensorimotor and cognitive function in young and older adults. *Cerebellum* 2013;12(5):721-737.
 - 17 Huang X, Zhou FQ, Hu YX, Xu XX, Zhou X, Zhong YL, Wang J, Wu XR. Altered spontaneous brain activity pattern in patients with high myopia using amplitude of low-frequency fluctuation: a resting-state fMRI study. *Neuropsychiatr Dis Treat* 2016;12:2949-2956.
 - 18 Huang X, Zhong YL, Zeng XJ, Zhou F, Liu XH, Hu PH, Pei CG, Shao Y, Dai XJ. Disturbed spontaneous brain activity pattern in patients with primary angle-closure glaucoma using amplitude of low-frequency fluctuation: a fMRI study. *Neuropsychiatr Dis Treat* 2015;11:1877-1883.
 - 19 Tan G, Huang X, Zhang Y, Wu AH, Zhong YL, Wu K, Zhou FQ, Shao Y. A functional MRI study of altered spontaneous brain activity pattern in patients with congenital comitant strabismus using amplitude of low-frequency fluctuation. *Neuropsychiatr Dis Treat* 2016;12:1243-1250.
 - 20 Tang A, Chen T, Zhang J, Gong Q, Liu L. Abnormal spontaneous brain activity in patients with anisometropic amblyopia using resting-state functional magnetic resonance imaging. *J Pediatr Ophthalmol Strabismus* 2017;54(5):303-310.
 - 21 Huang X, Cai FQ, Hu PH, Zhong YL, Zhang Y, Wei R, Pei CG, Zhou FQ, Shao Y. Disturbed spontaneous brain-activity pattern in patients with optic neuritis using amplitude of low-frequency fluctuation: a functional magnetic resonance imaging study. *Neuropsychiatr Dis Treat* 2015;11:3075-3083.
 - 22 Wang ZL, Zou L, Lu ZW, Xie XQ, Jia ZZ, Pan CJ, Zhang GX, Ge XM. Abnormal spontaneous brain activity in type 2 diabetic retinopathy revealed by amplitude of low-frequency fluctuations: a resting-state fMRI study. *Clin Radiol* 2017;72(4):340.e1-340340.e7.
 - 23 Tan G, Huang X, Ye L, Wu AH, He LX, Zhong YL, Jiang N, Zhou FQ, Shao Y. Altered spontaneous brain activity patterns in patients with unilateral acute open globe injury using amplitude of low-frequency fluctuation: a functional magnetic resonance imaging study. *Neuropsychiatr Dis Treat* 2016;12:2015-2020.
 - 24 Li Q, Huang X, Ye L, Wei R, Zhang Y, Zhong YL, Jiang N, Shao Y. Altered spontaneous brain activity pattern in patients with late monocular blindness in middle-age using amplitude of low-frequency fluctuation: a resting-state functional MRI study. *Clin Interv Aging* 2016;11:1773-1780.
 - 25 Dougherty RF, Koch VM, Brewer AA, Fischer B, Modersitzki J, Wandell BA. Visual field representations and locations of visual areas V1/2/3 in human visual cortex. *J Vis* 2003;3(10):586-598.
 - 26 Chan ST, Tang KW, Lam KC, Chan LK, Mendola JD, Kwong KK. Neuroanatomy of adult strabismus: a voxel-based morphometric analysis of magnetic resonance structural scans. *Neuroimage* 2004;22(2):986-994.
 - 27 Lan DY, Zhu PW, He Y, Xu QH, Su T, Li B, Shi WQ, Lin Q, Yang YC, Yuan Q, Fang JW, Li QH, Shao Y. Gray matter volume changes in patients with acute eye pain: a voxel-based morphometry study. *Transl Vis Sci Technol* 2019;8(1):1.
 - 28 Algaze A, Roberts C, Leguire L, Schmalbrock P, Rogers G. Functional magnetic resonance imaging as a tool for investigating amblyopia in the human visual cortex: a pilot study. *J AAPOS* 2002;6(5):300-308.
 - 29 Liu GT, Miki A, Francis E, Quinn GE, Modestino EJ, Bonhomme GR, Haselgrove JC. Eye dominance in visual cortex in amblyopia using functional magnetic resonance imaging. *J AAPOS* 2004;8(2):184-186.
 - 30 Yu B, Guo QY, Fan GG, Liu N. Assessment of cortical visual impairment in infants with periventricular leukomalacia: a pilot event-related fMRI study. *Korean J Radiol* 2011;12(4):463-472.
 - 31 Liang ML, Xie B, Yang H, Yin XT, Wang H, Yu LH, He S, Wang J. Altered interhemispheric functional connectivity in patients with anisometropic and strabismic amblyopia: a resting-state fMRI study. *Neuroradiology* 2017;59(5):517-524.
 - 32 Zhu PW, Huang X, Ye L, Jiang N, Zhong YL, Yuan Q, Zhou FQ, Shao Y. Altered intrinsic functional connectivity of the primary visual cortex in youth patients with comitant exotropia: a resting state fMRI study. *Int J Ophthalmol* 2018;11(4):668-673.
 - 33 Shao Y, Bao J, Huang X, Zhou FQ, Ye L, Min YL, Yang L, Sethi Z, Yuan Q, Zhou Q. Comparative study of interhemispheric functional connectivity in left eye monocular blindness versus right eye monocular blindness: a resting-state functional MRI study. *Oncotarget* 2018;9(18):14285-14295.
 - 34 Min YL, Su T, Shu YQ, Liu WF, Chen LL, Shi WQ, Jiang N, Zhu PW, Yuan Q, Xu XW, Ye L, Shao Y. Altered spontaneous brain activity patterns in strabismus with amblyopia patients using amplitude of low-frequency fluctuation: a resting-state fMRI study. *Neuropsychiatr Dis Treat* 2018;14:2351-2359.