

# Effect of vitamin B12 deficiency anemia on peripapillary retinal nerve fiber layer

Sushobhan Das Gupta, Tarannum Shakeel, Aeshwarya Dhawan, Aashish Kakkar

Department of Ophthalmology, Shri Guru Ram Rai Institute of Medical and Health Science, Patel Nagar, Dehradun 248001, India

**Correspondence to:** Tarannum Shakeel. Lane No.2, House No.13, Aashirwaad Enclave, Dehradun 248001, India. tarannumshakeel9@gmail.com

Received: 2020-05-11 Accepted: 2021-01-14

## Abstract

• **AIM:** To evaluate the effect of vitamin B12 deficiency anemia (BDA) on peripapillary retinal nerve fiber layer thickness (RNFLT) using spectral domain optical coherence tomography (SD-OCT), and to determine any correlation arising thereof.

• **METHODS:** In this cross-sectional observational study, 99 eyes of 50 BDA patients of age 18-65y were compared with 100 eyes of 50 healthy control subjects. All subjects underwent comprehensive clinical, ophthalmic, and hematological evaluation, followed by peripapillary RNFLT assessment using SD-OCT.

• **RESULTS:** The mean total, inferior, nasal, and temporal RNFLT were significantly lower in BDA group as compared to control group ( $P < 0.05$ ). The mean total, inferior and nasal RNFLT correlated significantly ( $P < 0.05$ ) with serum Hb%, B12 and mean corpuscular volume (MCV) level ( $r = 0.310, 0.435, -0.386$  for total;  $r = 0.932, 0.481, -0.513$  for inferior;  $r = 0.344, 0.254, -0.233$  for nasal; respectively), while temporal and superior RNFLT quadrant did not show any correlation with any of the hematological parameters ( $r = 0.144, 0.167, -0.096; r = 0.111, 0.070, -0.099$ ; respectively). The mean total RNFLT showed progressive thinning at par with the progression of anemia, except in very severe BDA, where an inverse relationship was documented.

• **CONCLUSION:** The mean total, inferior, nasal, and temporal peripapillary RNFLT was significantly thinner in BDA patients. Peripapillary RNFLT thinning seemed to proceed at par with the progression of severity of anemia, except in very severe grade. Early assessment of peripapillary RNFLT may be crucial in BDA patients to prevent potential blinding sequelae. Peripapillary RNFLT thinning in BDA

patients should be considered in the differential diagnosis of other non-glaucomatous optic neuropathies, as well.

• **KEYWORDS:** vitamin B12 deficiency anemia; retinal nerve fiber layer; spectral domain optical coherence tomography

**DOI:** 10.18240/ijo.2021.09.20

**Citation:** Das Gupta S, Shakeel T, Dhawan A, Kakkar A. Effect of vitamin B12 deficiency anemia on peripapillary retinal nerve fiber layer. *Int J Ophthalmol* 2021;14(9):1424-1429

## INTRODUCTION

Vitamin B12 deficiency (BD) is a worldwide problem<sup>[1]</sup>. Vitamin B12 deficiency anemia (BDA) has recently been reported to become endemic in India and it may be as high as 70%-100%, mostly because majority of Indian population is vegetarian by food habits<sup>[2-3]</sup>. Other than vegetarian/vegan diet, less common causes of BD in adults include autoimmune and parasitic diseases, gastro-intestinal surgery, defect in B12-transport, intrinsic factor deficiency, drugs (metformin, antacids), pancreatic disease, increased physiological demand (pregnancy, lactation), inherited metabolic diseases, etc<sup>[3-5]</sup>. Chronic BD (not merely sub-normal serum level) may lead to macrocytic megaloblastic anemia as well as various non-specific neurological or neuropsychiatric manifestations or even life threatening atherosclerosis because of increased serum homocysteine level<sup>[5-6]</sup>.

Although hematological abnormalities frequently begin before the onset of neurologic disease, in nearly a quarter of patients these neurological disorders may manifest before or even without hematological abnormalities, making the diagnosis difficult in subclinical BD without anemia<sup>[1,7]</sup>.

Vitamin B12 is a major co-factor in the synthesis of myelin. A chronic BD is definitively proved to cause bilateral optic neuropathy characterized by cecentral scotoma and eventually loss of vision from optic atrophy, possibly due to derangement of superoxide scavenging mechanism as well as myelin synthesis<sup>[1,8]</sup>. It is thus prudent to measure the retinal nerve fiber layer thickness (RNFLT) by utilizing optical coherence tomography (OCT) in BDA patients, considering that retinal nerve fiber thinning (RNFL-t) might

precede development of frank optic neuropathy, as is the rule in cases with glaucomatous optic neuropathy. Typical pattern of RNFLT-t has also been reported in various ischemic retinal diseases, myopia, chronic obstructive pulmonary disease, neurological (e.g., multiple sclerosis, Parkinson's disease, migraine) and neuropsychiatric illnesses (Alzheimer's disease)<sup>[9]</sup>. Spectral domain-optical coherence tomography (SD-OCT) is especially known for its capability of enhancing the image resolution, improved quality of measurements, reduced scan-time, and reproducibility<sup>[9]</sup>.

Currently, as far as our knowledge, RNFLT-study on BDA is scarce. Therefore, the aim of this study was to evaluate the effect of BDA on peripapillary RNFLT in adult patients by SD-OCT and to determine any correlation arising thereof. We also tried to correlate peripapillary RNFLT with varying grades of BDA.

## SUBJECTS AND METHODS

**Ethical Approval** This hospital based cross-sectional observational study was carried out for a period of 1.5y (September 2017-February 2019) in the Department of Ophthalmology at a tertiary care multispecialty referral hospital of Northern India, that caters to a large population of this state and neighboring states, as well. Consensus from institutional research ethical committee and patients' consent were obtained. This study adhered to the tenets of Declaration of Helsinki.

**Patients Included** In this study, a total of 99 eyes of 50 consecutive clinically diagnosed BDA patients (BDA group) aged 18-65y, who were recruited from the Department of Medicine in- and out-patient clinic, were included. A total 50 age and sex-matched healthy non-anemic subjects were included as controls (control group). Both study and control group comprised of only non-glaucomatous patients who had normal intraocular pressure of <21 mm Hg, open anterior chamber angle, no cup/disc ratio (C/D) abnormalities or documented glaucomatous visual field defects, in both the eyes (including a one eyed patient).

**Patients Excluded** Patients with history of external trauma or ocular surgery or laser/injection procedures, best corrected visual acuity (BCVA) of <6/6 (Snellen converted into logMAR), myopia or hypermetropia of >6 diopters, uveitis, pseudoexfoliation syndrome, squint, amblyopia, alcoholism, smoking, systemic diseases other than BDA (diabetes, hypertension, obstructive lung disease, thyroid disorders, Alzheimers, Parkinsonism, multiple sclerosis), structural or organic ocular disease (acquired or congenital), pregnancy, significant ocular media opacity, signal strength of <6 in SD-OCT, were excluded.

**Diagnostic Criteria** BDA was diagnosed when hematological parameters reported serum hemoglobin (Hb%)<11 g/dL

in conjunction with serum vitamin B12<200 pg/mL. Hematological and biochemical measurements were performed using CELLDYN<sup>®</sup> Ruby (Abbott, USA) and the VITROS<sup>®</sup>5600 integrated system (Ortho Clinical Diagnostics, USA), respectively. Anemia was graded according to the Hb% level as, mild (Hb%: 9-11 g/dL), moderate (Hb%: 7-<9 g/dL), severe (Hb%: 5-<7 g/dL) and very severe (Hb%: <5 g/dL).

**Examination Procedure** Once included, each patient (both study and control group) underwent detailed history taking followed by comprehensive ocular examination. Ocular examination was done by a single blind observer, that included assessment of BCVA, refraction by auto-refracto-keratometer (ARK-1, Nidek Co. Ltd., Japan), slit-lamp biomicroscopy (Haag-Streit), tonometry (Goldmann applanation tonometry), perimetry (Humphrey Visual Field Analyser; Carl Zeiss Meditec Inc. Dublin, CA, USA), funduscopy with 90D and 20D-lens, and RNFLT assessment by SD-OCT (RS-3000 Nidek Gamagori, Aichi 443-0038, Japan). Peripapillary RNFLT-scans were obtained for the mean total, inferior, superior, nasal and temporal quadrants using optic disc 200×200 pixels on 6×6 mm<sup>2</sup> cube scan protocol within 3.45 mm diameter centered on the optic nerve head. During scan, best possible fixation was ensured in each case after full dilation of the pupil by a combination of 0.8% tropicamide and 5% phenylephrine eye drops.

**Statistical Analysis** All collected data were recorded on Microsoft Excel Windows 10 (USA), and then analyzed using SPSS software (version 21.0, SPSS Inc., Chicago, IL, USA). The quantitative data was expressed as mean with standard deviation (SD). Categorical and nominal data was expressed in percentage. Quantitative data (intra-group analysis) was analyzed using Paired *t*-test, non-parametric data by using Mann-Whitney *U* test, and categorical data by using Chi-square test. Pearson's correlation coefficient analysis was used for correlating intra-group quantitative variables. Statistical significance was set at *P*<0.05.

## RESULTS

**Baseline Characteristics of BDA vs Control Group** In the present study, the mean age, gender distribution, vertical C/D ratio, rim area, and disc area between the BDA and control group patients were comparable (*P*>0.05). Serum iron, ferritin and folic acid levels were also found comparable (*P*>0.05), however, serum Hb%, vitamin B12 and mean corpuscular volume (MCV) level were significantly different (*P*<0.05). None of the patients in either group had detectable visual field defects (Table 1).

**RNFLT of BDA vs Control Group** For BDA cases, except superior RNFLT (121.62±10.03 μm vs 123.23±8.13 μm, *P*=0.214), there was significant RNFLT of the mean total, inferior, nasal and temporal quadrant, as compared to the controls

**Table 1 Baseline demographic, hematological and clinical characteristics of the BDA and control group** mean±SD

Parameters	BDA group (n=50)	Control group (n=50)	P
Age (y)	43.58±13.40	42.40±12.90	0.650
Gender (M:F)	27:23	28:22	0.214
Blood parameters			
Hb% (g/dL)	7.62±1.86	13.58±1.43	<0.01
MCV (fL)	110.23±7.63	89.58±2.25	<0.01
Serum vitamin B12 (pg/mL)	175.3±22.71	830.86±157.96	<0.001
Serum folic acid (ng/mL)	10.8±4.26	11.08± 4.60	0.752
Serum iron (µg/dL)	82.19±18.74	87.07±2.45	0.070
Serum ferritin (µg/dL)	41.91±7.23	38.50±10.57	0.062
Optic disc parameters			
C/D	0.43±0.12	0.45±0.11	0.221
Rim area (mm <sup>2</sup> )	1.47±0.33	1.43±0.37	0.422
Disc area (mm <sup>2</sup> )	2.39±0.47	2.31±0.45	0.221
Peripapillary RNFLT			
Superior (µm)	121.62±10.03	123.23±8.13	0.214
Inferior (µm)	119.11±11.8	126.03±7.88	<0.001
Nasal (µm)	69.74±8.30	74.82±6.02	<0.001
Temporal (µm)	63.28±7.87	66.20±6.10	0.003
Total (µm)	92.26±8.0	97.28±5.06	<0.001

BDA: Vitamin B12 deficiency anemia; Hb%: Hemoglobin; MCV: Mean corpuscular volume; RNFLT: Retinal nerve fiber layer thickness; C/D: Cup:disc ratio.

(92.26±8.0 µm vs 97.28±5.06 µm, *P*<0.001; 119.11±11.8 µm vs 126.03±7.88 µm, *P*<0.001; 69.74±8.30 µm vs 74.82±6.02 µm, *P*<0.001; 63.28±7.87 µm vs 66.20±6.10 µm, *P*=0.003; respectively; Table 1).

**RNFLT and Blood Parameters** Serum Hb%, B12, and MCV level correlated significantly (*P*<0.05) with the mean total (*r*=0.310, 0.435, -0.386; respectively), inferior (*r*=0.932, 0.481, -0.513; respectively) and nasal RNFLT (*r*=0.344, 0.254, -0.233; respectively). However, no significant correlation could be established (*P*>0.05) in the superior (*r*=0.111, 0.070, -0.099; respectively) and temporal RNFLT (*r*=0.144, 0.167, -0.096; respectively; Table 2; Figure 1).

**RNFLT and Severity of BDA** According to the severity of BDA, there were 16 (32%) mild, 14 (28%) moderate and 15 (30%) severe grade of BDA patients, while only 5 (5%) had very severe anemia who required extensive evaluation by the physician. Mean total RNFLT-t in all BDA group cases showed progression with the increasing severity of anemia, except in very severe BDA, where an inverse relationship was documented (Figure 2). None of the patients required bone marrow examination, as neither was detected to have pancytopenia or features of non-megaloblastic anemia.

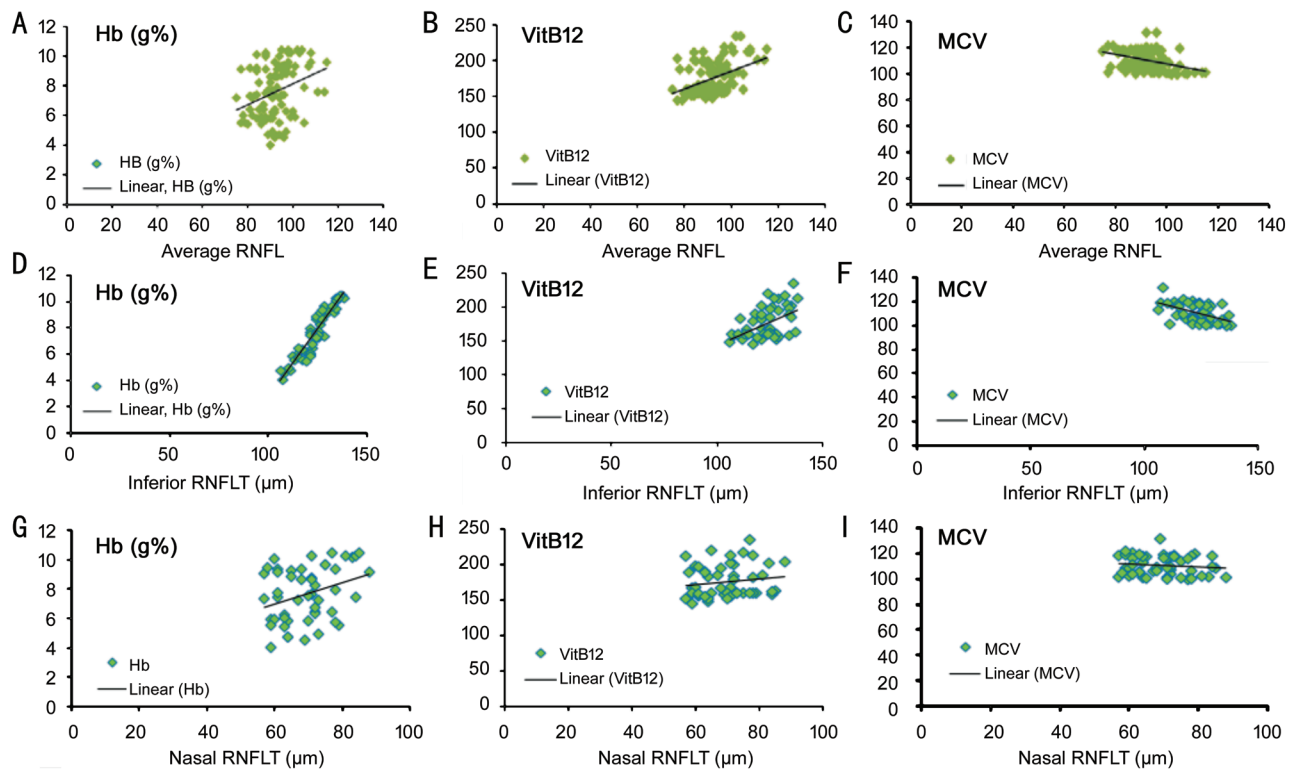
**DISCUSSION**

Although, BD is prevalent in almost every race throughout the world including central Europe and Western countries,

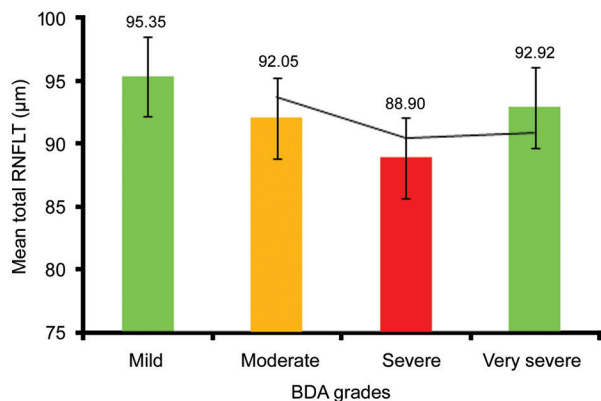
**Table 2 Pearson’s correlation between RNFLT with blood parameters in BDA group of patients**

Parameters	Pearson’s correlation coefficient ( <i>r</i> )	<i>P</i>
Total		
B12	0.435	<0.0001
Hb%	0.310	<0.0001
MCV	-0.386	<0.0001
Inferior		
B12	0.481	<0.0001
Hb%	0.932	<0.0001
MCV	-0.513	<0.0001
Temporal		
B12	0.167	0.098
Hb%	0.144	0.155
MCV	-0.096	0.342
Nasal		
B12	0.254	0.011
Hb%	0.344	<0.0001
MCV	-0.233	0.020
Superior		
B12	0.070	0.489
Hb%	0.111	0.272
MCV	-0.099	0.328

BDA: Vitamin B12 deficiency anemia; Hb%: Hemoglobin; MCV: Mean corpuscular volume; RNFLT: Retinal nerve fiber layer thickness.



**Figure 1** Pearson's correlation of the hematological parameters (serum Hb%, vitamin B12 and MCV) in BDA group of patients with the mean total RNFLT (A, B, C, respectively), inferior RNFLT (D, E, F, respectively), and nasal RNFLT (G, H, I, respectively).



**Figure 2** The mean total RNFLT values in different grades of BDA patients Only eight (0.16%) BDA patients had associated non-specific neurological features that were mostly limited to paresthesia of extremities, movement disorders, auditory symptoms, and mental depression.

it is recently reported to be endemic in India<sup>[1-2]</sup>. The latest National Family Health Survey (NFHS 4) carried out by the Ministry of Health and Family Welfare in India reported that the prevalence of anemia amongst Indian women aged 15-49y and men aged 15-49y was 53.1% and 22.7%, respectively<sup>[2]</sup>. The diagnosis of subclinical BD without anemia is difficult<sup>[1-2]</sup>. Elderly patients are more prone to develop BD due to atrophic gastritis, malabsorption or insufficient dietary intake. Although currently there is no internationally accepted standard for

diagnosis of BD, serum concentrations of vitamin B12 is a relatively good indicator of body store<sup>[10]</sup>.

Initial clinical manifestations may be of non-specific neurological nature, may precede hematological manifestations, and may take 5-6y after the onset of BD<sup>[11]</sup>. Additionally, due to difficulty in laboratory diagnosis, results even from standard laboratories are not reliable due to several reasons<sup>[5,12]</sup>. This study was undertaken with an aim to evaluate the effect of BDA on peripapillary RNFLT using SD-OCT. To the best of our knowledge, currently there is no such similar study yet published, other than handful of studies which are mainly based on the sub-normal BD without anemia, and that too on elderly susceptible group is very limited<sup>[1,12-13]</sup>.

Significant global, inferior, temporal, nasal and insignificant superior peripapillary RNFLT-t was the hallmark of this study. Currently, there is no supportive data available worldwide. However, working with non-anemic BD patients, different authors reported varying results. Türkyılmaz *et al*<sup>[13]</sup> in their study group of younger patients reported significant mean total and temporal RNFLT-t as measured by Cirrus HD-OCT (mean age=31y, serum B12 cut off ≤189 pg/mL); Dogan *et al*<sup>[12]</sup> reported insignificant RNFLT-t of mean total and superior-temporal as measured by Spectralis-OCT with a B12-deficient cut off level ≤200 pg/dL; Özkasap *et al*<sup>[11]</sup> reported significant superior but insignificant mean total RNFLT-t as measured by Cirrus HD-OCT in children (mean age 12.9±2.4y, serum B12

<200 pg/mL). Inclusion of variant age groups, sample size, B12-cut off level, duration and severity of deficiency, OCT-techniques and exclusion of anaemia might be the possible cause for such differences. In this study, except temporal and superior RNFLT, global, inferior and nasal RNFLT correlated significantly ( $P<0.05$ ) with the corresponding blood parameters (serum B12, Hb%, MCV level). At present, there is no relevant study available to testify this. However, in studies with BD in non-anemic subjects, Turkimalyz *et al*<sup>[13]</sup>, Dogan *et al*<sup>[12]</sup> and Özkazap *et al*<sup>[11]</sup> have found correlation of serum B12 with mean total and temporal RNFLT, supero-temporal RNFLT, and mean total and superior RNFLT, respectively. Variation in the nature of the study as already explained, as well as geographic and age-related variation in retinal thickness, possibly played a role for such differences.

In this study, except in the very severe grade of BDA patients, an exponential mean total RNFL-t was observed in all other grades (mild, moderate and severe) which was at par with the advancement of severity of anemia. This although conforms to the study by Han *et al*<sup>[14]</sup> who reported RNFL-t corresponding to the exponential decrease of Hb% level, an existence of inverse relationship between the severity of anemia and degree of neurological features has also been reported by Heaton *et al*<sup>[15]</sup>. Further similar large-scale studies may certainly throw some light in causation of such paradox. None of our study subjects had visual deterioration or perimetrically proven visual field defects.

Pandey *et al*<sup>[16]</sup> in their study on chronic persistent BD patients (with or without anemia), reported prolongation of P-100 latency as recorded by visual evoked potential in 58% (10/17) of their study participants, even though they all were having normal visual acuity, which they inferred to be due to chronic demyelination and remyelination processes. Turkimalyz *et al*<sup>[13]</sup> also had similar observation with their study group of BD patients without anemia. This prompted us to believe that the pattern of RNFL-t in BDA reflects pre-perimetric early structural damage (demyelination), which deserves urgent attention to rule out other causes of non-glaucomatous optic neuropathy and thus initiate preventive measures to arrest irreversible axonal damage.

This study was possibly limited by its cross-sectional nature that restricted us to study the effect of vitamin B12 supplementation on RNFLT, duration of anemia could not be ascertained due to lack of information provided by the patient and by our inability to perform sophisticated tests like, GI-endoscopy, MRI-spinal cord, methylmalonyl coenzyme test, serum homocysteine estimation, *etc.*, either because of the cost-factor or non-availability. Nevertheless, the characteristic changes as observed in this study may have enormous clinical significance.

To conclude, in the current study, SD-OCT showed a significant peripapillary RNFL-t of the mean total, inferior, nasal, and temporal quadrant in BDA patients, as compared to their age and sex-matched healthy non-anemic controls. The RNFLT of mean total, inferior and nasal quadrant significantly correlated with the relevant hematological parameters (serum Hb%, B12 and MCV level). Although, mean total RNFLT showed a graded thinning response at par with progression of severity of anemia, its inverse relationship in very severe grade of BDA patients was a notable exception in this study. RNFL-t can progress with the progression of anemia even without showing signs of optic neuropathy or obvious visual field changes, and this can be an ominous sign. SD-OCT thus may prove to be a valuable tool for early detection of RNFL-t in BDA patients and can aid in preventing further irreversible neurological sequelae by identifying high risk patients who require prophylactic therapy, and also in differentiating from other non-glaucomatous optic neuropathies. Further similar prospective, multicenter, randomized studies with bigger cohort would be warranted to better understand and characterize the changes imposed and also to determine the effects of treatment in BDA patients.

#### ACKNOWLEDGEMENTS

**Conflicts of Interest:** Das Gupta S, None; Shakeel T, None; Dhawan A, None; Kakkar A, None.

#### REFERENCES

- Özkazap S, Türkyılmaz K, Dereci S, Öner V, Calapoğlu T, Cüre MC, Durmuş M. Assessment of peripapillary retinal nerve fiber layer thickness in children with vitamin B12 deficiency. *Childs Nerv Syst* 2013;29(12):2281-2286.
- Gonmei Z, Toteja GS. Micronutrient status of Indian population. *Indian J Med Res* 2018;148(5):511-521.
- Singla R, Garg A, Surana V, Aggarwal S, Gupta G, Singla S. Vitamin B12 deficiency is endemic in Indian population: a perspective from north India. *Indian J Endocrinol Metab* 2019;23(2):211-214.
- Nagao T, Hirokawa M. Diagnosis and treatment of macrocytic anemias in adults. *J Gen Fam Med* 2017;18(5):200-204.
- Sasidharan PK. B12 deficiency in India. *Arch Med Health Sci* 2017;5(2):261.
- Raina S, Sharma KK, Chahal J, Kaur N. How common is vitamin B12 deficiency - a report on deficiency among healthy adults from a medical college in rural area of North-West India. *Int J Nutr Pharmacol Neurol Dis* 2014;4(4):241.
- Snow CF. Laboratory diagnosis of vitamin B12 and folate deficiency: a guide for the primary care physician. *Arch Intern Med* 1999;159(12):1289-1298.
- Chan W, Almasieh M, Catrinescu MM, Levin LA. Cobalamin-associated superoxide scavenging in neuronal cells is a potential mechanism for vitamin B12-deprivation optic neuropathy. *Am J Pathol* 2018;188(1):160-172.

- 9 Mukherjee C, Al-Fahad Q, Elsherbiny S. The role of optical coherence tomography in therapeutics and conditions, which primarily have systemic manifestations: a narrative review. *Ther Adv Ophthalmol* 2019;11:2515841419831155.
- 10 Allen LH. Folate and vitamin B12 status in the Americas. *Nutr Rev* 2004;62(6 Pt 2):S29-S33; discussion S34.
- 11 Andrès E, Loukili NH, Noel E, Kaltenbach G, Abdelgheni MB, Perrin AE, Noblet-Dick M, Maloisel F, Schlienger JL, Blicklé JF. Vitamin B12 (cobalamin) deficiency in elderly patients. *CMAJ* 2004;171(3):251-259.
- 12 Dogan U, Turkoglu SA, Ulas F, Soydan A, Kaymaz A, Eroglu T, Agca S. Evaluation of retinal nerve fiber layer and ganglion cell layer thicknesses with optical coherence tomography in patients with vitamin B12 deficiency. *J-ibr* 2018;1(3):103-109.
- 13 Türkyılmaz K, Öner V, Türkyılmaz AK, Kırbaş A, Kırbaş S, Şekeryapan B. Evaluation of peripapillary retinal nerve fiber layer thickness in patients with vitamin B12 deficiency using spectral domain optical coherence tomography. *Curr Eye Res* 2013;38(6):680-684.
- 14 Han JN, Kim JH, Yoo H, Han SH, Hong SM, Seong GJ, Kim CY. Retinal nerve fiber layer thickness is decreased in patients with hematologic malignancy. *J Glaucoma* 2016;25(3):e175-e181.
- 15 Healton EB, Savage DG, Brust JC, Garrett TJ, Lindenbaum J. Neurologic aspects of cobalamin deficiency. *Medicine (Baltimore)* 1991;70(4):229-245.
- 16 Pandey S, Kalita J, Misra UK. A sequential study of visual evoked potential in patients with vitamin B12 deficiency neurological syndrome. *Clin Neuro physiol* 2004;115(4):914-918.