

# Toric intraocular collamer lens with anterior chamber maintainer for myopic astigmatism following penetrating keratoplasty: a case report

Zong-Ming Zhuang<sup>1,2</sup>, Hao-Yu Li<sup>2</sup>, Shao-Jian Tan<sup>1,2</sup>

<sup>1</sup>Department of Ophthalmology, the First Affiliated Hospital of Guangxi Medical University, Nanning 530021, Guangxi Zhuang Autonomous Region, China

<sup>2</sup>Jingliang Eye Hospital of Guangxi Medical University, Nanning 530021, Guangxi Zhuang Autonomous Region, China

**Correspondence to:** Shao-Jian Tan. Department of Ophthalmology, the First Affiliated Hospital of Guangxi Medical University; Jingliang Eye Hospital of Guangxi Medical University, 6 Shuangyong Rd, Nanning 530021, Guangxi Zhuang Autonomous Region, China. shaojiantan@163.com

Received: 2020-06-15 Accepted: 2020-08-24

**DOI:10.18240/ijo.2021.02.24**

**Citation:** Zhuang ZM, Li HY, Tan SJ. Toric intraocular collamer lens with anterior chamber maintainer for myopic astigmatism following penetrating keratoplasty: a case report. *Int J Ophthalmol* 2021;14(2):330-332

## Dear Editor,

I am Zong-Ming Zhuang, from the Department of Ophthalmology, the First Affiliated Hospital of Guangxi Medical University, Nanning, China. I am writing to present a case of toric intraocular collamer lens (TICL) implantation for myopic astigmatism after penetrating keratoplasty (PK) with anterior chamber maintainer (ACM) and without ophthalmic viscoelastic surgical device (OVD). The current study was conducted in accordance with the Declaration of Helsinki principles, the patient signed a written informed consent.

Surgical treatment for high myopic astigmatism after corneal transplantation is more complicated than ordinary refractive surgery, because the donor cornea is thinner than the patient's own cornea, the biomechanics of the transplanted cornea is instable, and avoiding the pre-existent PK incisions might be challenging. The currently available choices of the surgical procedures included femtosecond lenticule extraction (FLEX), laser-assisted sub-epithelial keratectomy (LASEK) and small incision lenticule extraction (SMILE). However, the

success of those above-mentioned procedures relies on the adequate corneal thickness. In terms of underlying limitations, the risk of allograft rejection should not be underestimated while transplanted tissues are involved<sup>[1]</sup>. Moreover, the mechanical incisions resulted from the surgeries may disrupt the biomechanical stability within the corneas, thereby inducing persistent refractive instability. In comparison, the application of implantable collamer lens (ICL), which is a posterior chamber phakic intraocular lens (IOL), can avoid the limitations, while it has been widely recognized as an advanced treatment strategy against myopia at any degree of severity<sup>[2-5]</sup>. The TICL (STAAR SURGICAL, Nidau, Switzerland) is a toric foldable posterior chamber lens designed to be placed anterior of the natural crystalline lens, for correction of myopia and astigmatism. The TICL is composed of a hydrophilic copolymer of collagen and poly(hydroxyethyl methacrylate), and an ultraviolet-filtering chromophore. Here we present a case of myopic astigmatism after PK and subsequent implantation of a TICL with porous perfusion ACM (Zhengtong Medical Company Ltd., patent: ZL01228569.2, Jiangsu Province, China) and without ophthalmic viscosurgical device (OVD).

A 33-year-old male patient with high myopic astigmatism in both eyes. He reported corneal transplantation by PK in the left eye for keratoconus 12 years ago. With the clear allograft, his visual acuity was compromised by severe myopic astigmatism. Now he required treatment to resolve the refractive errors. His preoperative uncorrected visual acuity (UCVA) was 0.12/0.08 (right/left), the distance-corrected visual acuity (DCVA) was 1.0 of each eye. The manifest refraction was -6.0/-10.0, -2.0×90° (right/left). The intraocular pressure (IOP) was 15/13 mm Hg (right/left), and the corneal endothelial cell density (ECD) 2828 and 2544 cells/mm<sup>2</sup>, respectively. Furthermore, the pupil sizes were 5.4 and 5.81 mm in a dark examination room, and 3.99 and 3.71 mm in a bright examination room; the anterior chamber depths (ACD) were 3.43 and 3.67 mm, the white-to-white (WTW) diameters were 12.2 and 12.2 mm, the corneal thickness was 586 and 484 μm (right/left), respectively. The status of both eyes was phakic. Based on the calculation for the TICL software (STAAR SURGICAL) and comprehensive

optometry analysis, we chose the VTICMO13.2 model, with a power of -7.00 for the right eye, the VICMO13.2 model, with a power of -13.0+2.0×179° for the left eye, and a diameter of 13.2 mm for both eyes. The ICL was implanted into the right eye, the TICL was implanted at 1° anticlockwise from the horizontal meridian into the left eye. The preoperative keratometry reading was 40.8/41.7@100 and 44.3/45.4@15 (right/left). The corneal topography (ATLAS9000, Carl Zeiss Meditec) and Scheimpflug imaging (Pentacam, Oculus, Germany) visualized the steepness in the centre of the cornea in both eyes. The slit lamp examination visualized the central flat within the cornea in the presence 16 of incisions resulted from previous PK (Figure 1). Before surgical procedure the pupil was dilated with tropicamide phenylephrine eye drops. The operation was performed under topical anesthesia (proparacaine hydrochloride eye drops). All surgeries were performed under surgical microscopes OPMI Lumerai (Carl Zeiss Meditec Inc, Germany). The TICL was implanted in the left eye, through a 3.0 mm temporal corneal incision to avoid the PK incisions, with ACM and without OVD. The 4-day postoperative UCVA was 1.2/1.0 (right/left). The IOP was 16 and 15 mm Hg. The ECD was 2842/2609 cells/mm<sup>2</sup> (right/left). The central vault (the distance between the crystalline lens and the TICL/ICL) was 475/595 μm (right/left). The resulting efficacy index were 1.2 and 1.0 (right/left), the safety indexes were 1.2 and 1.0 (right/left), respectively. The complications had been excluded (Figure 2).

To modify the refractive error, commonly considered post-PK approaches in clinical practice still mainly rely on external equipment, the spectacles and contact lenses. However, the effect of applying spectacles may be unsatisfactory due to severe anisometropia and astigmatism which are related to PK. Moreover, the use of contact lenses is often impeded by the occurrence or risks of dry eyes, corneal neovascularization, blepharitis, and ocular surface abnormalities associated with corneal graft<sup>[6-7]</sup>. Rigid gas permeable (RGP) lens may be an option but can be difficult to fit, because the thickness of the donor cornea is thinner than the patient's cornea. Although conventional corneal refractive surgical procedures can be selected to treat myopic astigmatism, they may be associated with high risks of the adverse sequelae of corneal transplant, for example, graft rejection and wound dehiscence. Moreover, post-keratoplasty corneal refractive surgical procedures may be associated with astigmatism, as well as other unpredictable refractive outcomes.

TICL is expected to be a potential alternative to effectively resolve severe myopic astigmatism after corneal transplantation. Compared with conventional corneal refractive surgical procedures, implantation of a TICL could avoid any excessive

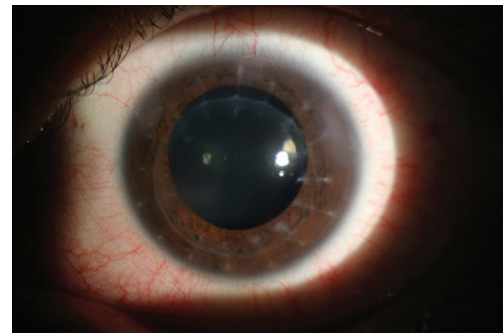


Figure 1 The preoperative anterior segment of the left eye.

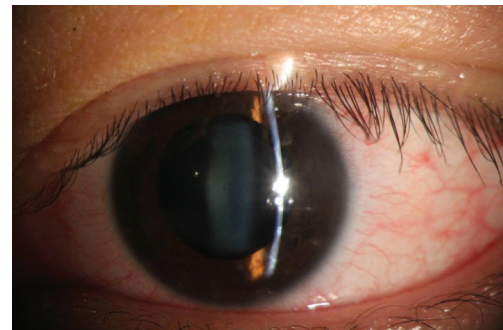


Figure 2 Photograph of the left eye shows the corneal graft and the TICL.

manipulation of the donor cornea which may result in a compromised quality of surgery. In addition, the simplification of the insertion step and the possibility of removal or renewal of this lens could be significantly advantageous for subsequent clinical procedures. Moreover, application of a TICL could resolve severe myopic astigmatism and effectively increase the UCVA, CDVA, contrast sensitivity, and decrease the rate of refractive abnormality. Some previous reports<sup>[8-9]</sup> concluded that implantation of ICL could provide an effective and safe alternative method for correcting anisometropia and astigmatism after corneal transplantation. In comparison to these similar reports, we used V4c TICL with peri-optic and central holes for aqueous flow, which eliminated the need for iridotomy before surgery. Alfonso *et al*<sup>[10]</sup> reported that TICL may be proven to be more appropriate for the correction of myopia astigmatism after PK. In contrast with the report above, we used ACM instead of OVD in this case.

Porous perfusion ACM is composed of porous cannula designed for insertion into the anterior chamber from the limbus to maintain adequate infusion into the eye during a surgical maneuver. As firstly proposed by Thrasher<sup>[11]</sup>, the ACM could inhibit the collapse of the anterior chamber induced by an IOL insertion or any other postinsertion surgical process. While implanting ICL/TICL into the eye, the application of ACM could also minimize the chance of accidentally leaving an OVD within the anterior chamber as a result of the surgical procedure. Compared to the conventional approaches, TICL implantation with ACM could be evaluated

as more advanced in protecting the endothelial cells, reducing the IOP and saving cost.

#### ACKNOWLEDGEMENTS

**Conflicts of Interest:** Zhuang ZM, None; Li HY, None; Tan SJ, None.

#### REFERENCES

- 1 Hardten DR, Chittcharus A, Lindstrom RL. Long term analysis of LASIK for the correction of refractive errors after penetrating keratoplasty. *Cornea* 2004;23(5):479-489.
- 2 Niu LL, Miao HM, Han T, Ding L, Wang XY, Zhou XT. Visual outcomes of Visian ICL implantation for high myopia in patients with shallow anterior chamber depth. *BMC Ophthalmol* 2019;19(1):121.
- 3 Packer M. Meta-analysis and review: effectiveness, safety, and central port design of the intraocular collamer lens. *Clin Ophthalmol* 2016;10:1059-1077.
- 4 Sanders DR, Schneider D, Martin R, Brown D, Dulaney D, Vukich J, Slade S, Schallhorn S. Toric implantable collamer lens for moderate to high myopic astigmatism. *Ophthalmology* 2007;114(1):54-61.
- 5 Takagi Y, Nakamura T, Ichikawa K, Kojima T. Recurrent prolapse of toric implantable collamer lens after blunt ocular trauma under mesopic conditions. *Clin Case Rep* 2019;7(4):626-629.
- 6 Nuijts RM, Abhilakh Missier KA, Nabar VA, Japing WJ. Artisan toric lens implantation for correction of postkeratoplasty astigmatism. *Ophthalmology* 2004;111(6):1086-1094.
- 7 Moshirfar M, Barsam CA, Parker JW. Implantation of an Artisan phakic intraocular lens for the correction of high myopia after penetrating keratoplasty. *J Cataract Refract Surg* 2004;30(7):1578-1581.
- 8 Akcay L, Kaplan AT, Kandemir B, Gunaydin NT, Dogan OK. Toric intraocular collamer lens for high myopic astigmatism after penetrating keratoplasty. *J Cataract Refract Surg* 2009;35(12):2161-2163.
- 9 Alfonso JF, Lisa C, Abdelhamid A, Montés-Micó R, Poo-López A, Ferrer-Blasco T. Posterior chamber phakic intraocular lenses after penetrating keratoplasty. *J Cataract Refract Surg* 2009;35(7):1166-1173.
- 10 Iovieno A, Guglielmetti S, Capuano V, Allan BD, Maurino V. Correction of postkeratoplasty ametropia in keratoconus patients using a toric implantable Collamer lens. *Eur J Ophthalmol* 2013;23(3):361-367.
- 11 Thrasher B. Maintaining an anterior chamber with the Cavitron unit. *J Am Intraocul Implant Soc* 1978;4(4):220-221.