

Exudative hemorrhagic retinopathy related to all-trans retinoic acid differentiation syndrome in a patient with acute promyelocytic leukemia

Emily K. Tam¹, Steven Ness¹, Crandall E. Peeler^{1,2}

¹Department of Ophthalmology, Boston Medical Center, Boston, Massachusetts 02118, USA

²Department of Neurology, Boston Medical Center, Boston, Massachusetts 02118, USA

Correspondence to: Emily K. Tam. 85 East Concord St 8th Floor, Boston, MA 02118, USA. Kayi.Tam@bmc.org

Received: 2020-07-24 Accepted: 2020-10-19

DOI:10.18240/ijo.2021.02.22

Citation: Tam EK, Ness S, Peeler CE. Exudative hemorrhagic retinopathy related to all-trans retinoic acid differentiation syndrome in a patient with acute promyelocytic leukemia. *Int J Ophthalmol* 2021;14(2):323-325

Dear Editor,

We report a case of significant exudative hemorrhagic retinopathy attributed to differentiation syndrome (DS). DS is a systemic inflammatory condition seen in patients with acute promyelocytic leukemia (APML) undergoing treatment with all-trans retinoic acid (ATRA). DS can lead to endothelial injury and capillary leakage throughout the body. Treatment with corticosteroids during chemotherapy has been shown to reduce the risk of developing DS^[1-2]. There are limited reports of the ocular manifestations of DS in the literature, including pale yellow choroidal lesions, scattered retinal hemorrhages, and serous retinal detachments^[3-5].

A 25-year-old male presented to the Emergency Department with two weeks of fatigue and intermittent bleeding from his nose and gums. A complete blood count demonstrated profound thrombocytopenia (platelet count of 5 k/ μ L, reference range 150-400 k/ μ L) and leukocytosis (white cell count of 22.4 k/ μ L, reference range 4.0-11.0 k/ μ L) with blasts. Hemoglobin was 10.5 g/dL (reference range 13.5-17.5 g/dL). A peripheral blood smear and bone marrow biopsy were consistent with APML [t(15;17)(q24;q21)/PML-RARA translocation]. He was admitted for standard treatment with ATRA, arsenic trioxide, and intravenous corticosteroids. An initial ophthalmology consult for bilateral blurring of vision demonstrated visual

acuity of 20/30 in both eyes with scattered subretinal, intraretinal, and preretinal hemorrhages (Figure 1) consistent with typical leukemic retinopathy^[6].

Ten days later, shortly after cessation of intravenous steroids, he developed hypoxia, tachycardia, fever, and worsening vision in both eyes. Best corrected visual acuity at that point was 20/60 on the right and 20/200 on the left. Repeat fundoscopic examination demonstrated significant worsening of his retinal hemorrhages with new-onset optic nerve swelling (Figure 2) and bilateral macular edema (Figure 3).

Repeat labs demonstrated a white blood cell count of 0.7 k/ μ L, a platelet count of 28 k/ μ L, and hemoglobin of 7.8 g/dL. Serum viscosity was normal (viscosity level of 1.3 Centipoise, reference range 1.4-1.8 Centipoise). Fluorescein angiogram (FA; Figure 4) showed normal arteriovenous transit times with intact retinal perfusion and diffuse leakage from the optic nerves and retinal vessels. Magnetic resonance imaging (MRI) of the brain and orbits with contrast showed no leukemic

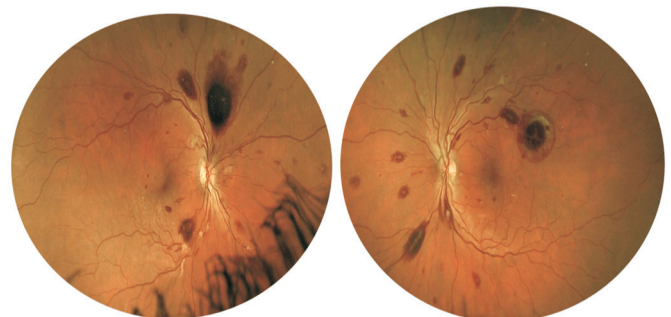


Figure 1 Fundus photos of both eyes demonstrating retinal hemorrhages in multiple layers of the retina.

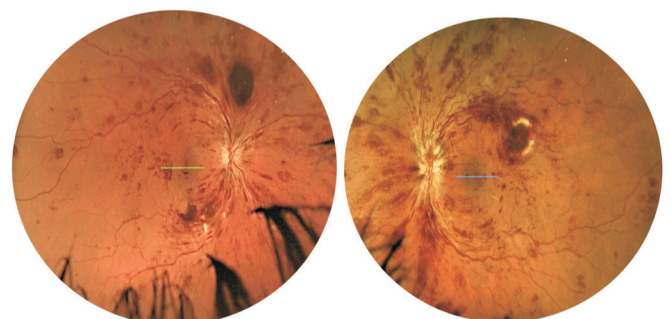


Figure 2 Fundus photos of both eyes demonstrating worsening retinal hemorrhages with new onset optic disc edema (left eye more than right eye) after cessation of prophylactic steroid therapy.

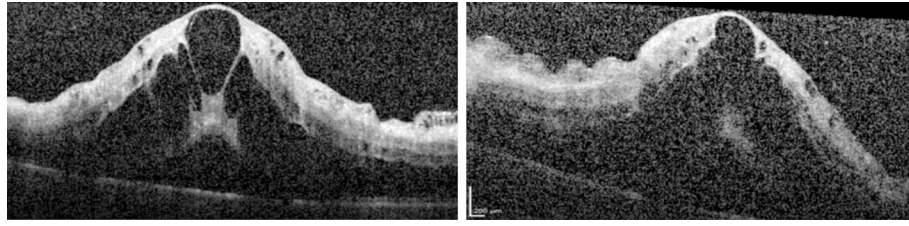


Figure 3 Optical coherence tomography images of both eyes demonstrating macular edema.

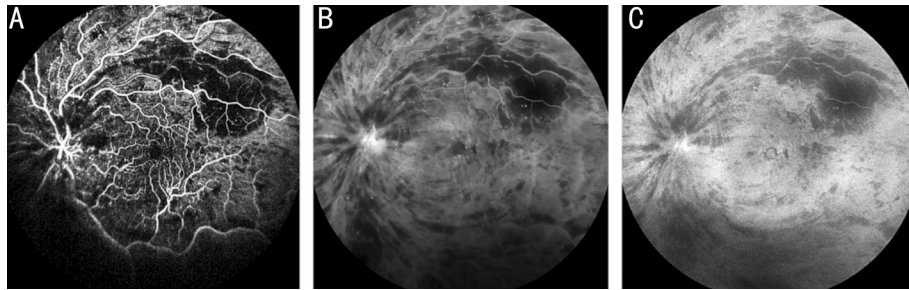


Figure 4 FA photos of transit eyes demonstrating blockage from subretinal and intraretinal hemorrhages, normal arterial venous transit (A) and diffuse leakage from retinal vessels and optic nerve (B, C).

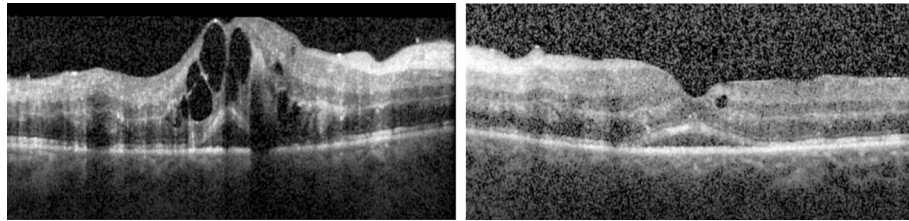


Figure 5 Optical coherence tomography images of both eyes demonstrating marked improvement of macular edema after re-initiation of steroid therapy.

infiltration of the optic nerves and no signs of increased intracranial pressure.

Retinal hemorrhages in typical leukemic retinopathy have been associated with anemia, which can be exacerbated by coexisting thrombocytopenia and decreased platelet adhesion to the vascular endothelium^[6-7]. Macular edema, however, is not a usual finding for leukemic retinopathy, but is more commonly associated with central retinal vein occlusion (CRVO) due to increased serum viscosity from leukocytosis and/or thrombocytosis^[7-8]. In our case, the acute onset of bilateral macular edema occurred in the setting of normal serum viscosity and an improving platelet count and leukocytosis. In addition, the normal transit time on fluorescein angiography argues against CRVO.

We therefore attributed the acutely worsening retinopathy with macular and optic nerve edema, coinciding with worsening systemic symptoms, to DS, a common complication of retinoic acid treatment characterized by dyspnea, fever, weight gain, hypotension, and pulmonary exudates^[1-2]. While the exact cause of DS has not been fully elucidated, a proinflammatory cytokine surge triggered by ATRA-induced blast cell differentiation resulting in increased systemic vascular permeability has been hypothesized^[1-2].

DS occurs in 2%-27% of APLM patients treated with ATRA, typically at 7-12d after onset of therapy^[1-2]. Current treatment recommendations in cases of DS include intravenous steroids, although there remains controversy as to whether ATRA therapy should be temporarily discontinued^[2]. In our patient's case, DS resulted in diffuse retinal vascular leakage that (together with his systemic symptoms) responded to re-initiation of intravenous steroid therapy for one week. At follow-up exam, the patient's vision improved to 20/40 in both eyes with decreased macular edema (Figure 5).

There are currently few reports of the ocular manifestations of DS. A case series of two patients by Newman *et al*^[3] described multifocal, pale yellow choroidal lesions, scattered retinal hemorrhages, and diffuse late leakage on FA associated with subretinal fluid that improved with steroid therapy. Levasseur *et al*^[4] reported a case of DS-induced multifocal serous retinal detachment that completely resolved after initiation of steroid therapy. Another study by Hua *et al*^[5] found choroidal effusions with serous retinal detachments involving the macula. Our case is the first to report significant exudative hemorrhagic retinopathy from DS. Similar to the aforementioned studies, our patient's ocular manifestations improved with re-initiation of steroid therapy. Although less common than the classic

systemic symptoms, vision loss due to increased retinal vascular permeability should be recognized as a potential complication of DS and treated promptly with systemic steroid therapy.

ACKNOWLEDGEMENTS

Conflicts of Interest: Tam EK, None; Ness S, None; Peeler CE, None.

REFERENCES

- 1 Montesinos P, Sanz MA. The differentiation syndrome in patients with acute promyelocytic leukemia: experience of the pethema group and review of the literature. *Mediterr J Hematol Infect Dis* 2011;3(1):e2011059.
- 2 Stahl M, Tallman MS. Differentiation syndrome in acute promyelocytic leukaemia. *Br J Haematol* 2019;187(2):157-162.
- 3 Newman AR, Leung B, Richards A, Campbell TG, Wellwood J, Imrie FR. Two cases of differentiation syndrome with ocular manifestations in patients with acute promyelocytic leukaemia treated with all-trans retinoic acid and arsenic trioxide. *Am J Ophthalmol Case Rep* 2018;9:106-111.
- 4 Levasseur SD, Tantiworawik A, Lambert Maberley DA. All-trans retinoic acid differentiation syndrome chorioretinopathy: a case of multifocal serous neurosensory detachments in a patient with acute promyelocytic leukemia treated with all-trans retinoic acid. *Retin Cases Brief Rep* 2013;7(1):46-49.
- 5 Hua HU, Rayess N, Moshfeghi AA. Acute promyelocytic leukemia with sudden vision loss. *JAMA Ophthalmol* 2020;138(2):206-207.
- 6 Guyer DR, Schachat AP, Vitale S, Markowitz JA, Braine H, Burke PJ, Karp JE, Graham M. Leukemic retinopathy. Relationship between fundus lesions and hematologic parameters at diagnosis. *Ophthalmology* 1989;96(6):860-864.
- 7 Koshy J, John MJ, Thomas S, Kaur G, Batra N, Xavier WJ. Ophthalmic manifestations of acute and chronic leukemias presenting to a tertiary care center in India. *Indian J Ophthalmol* 2015;63(8):659-664.
- 8 Dhasmana R, Prakash A, Gupta N, Verma SK. Ocular manifestations in leukemia and myeloproliferative disorders and their association with hematological parameters. *Ann Afr Med* 2016;15(3):97-103.