

# Comparative study on pharmacokinetics and toxicity of intravitreal and sub-Tenon injection of triamcinolone acetonide in ocular tissues

Yuko Arie<sup>1</sup>, Hiroko Miyai<sup>1</sup>, Ayako Suzuki<sup>1</sup>, Takeshi Okabe<sup>1</sup>, Mitsuyo Takashima<sup>1</sup>, Mayumi Takata<sup>1</sup>, Takashi Kurasawa<sup>1</sup>, Masaki Ito<sup>1</sup>, Reijiro Arakawa<sup>1</sup>, Yuichiro Ogura<sup>2</sup>, Akira Naito<sup>1</sup>

<sup>1</sup>Sagami Research Laboratories, Wakamoto Pharmaceutical Corporation Ltd., Kanagawa 2580018, Japan

<sup>2</sup>Department of Ophthalmology and Visual Science, Nagoya City University Graduate School of Medical Sciences, Nagoya 4678601, Japan

**Correspondence to:** Reijiro Arakawa. Sagami Research Laboratories, Wakamoto Pharmaceutical Corporation Ltd., Kanagawa 2580018, Japan. reijiro.arakawa@wakamoto-pharm.co.jp

Received: 2019-12-30 Accepted: 2020-08-26

## Abstract

• **AIM:** To compare the differences in kinetics, distribution, and toxicity of triamcinolone acetonide (TA) between the injection methods, sub-Tenon and intravitreal injections in rabbit ocular tissues.

• **METHODS:** TA was injected into the vitreous or the sub-Tenon in rabbits. For pharmacokinetic study, rabbits were sacrificed periodically and then TA in blood and ocular tissues (retina/choroids, vitreous, and aqueous humor) were measured over 91d. For toxicological study, clinical signs, slit-lamp microscopic examination, ophthalmological test were performed. The eyeballs and surrounding tissues were collected and fixed with glutaraldehyde-formalin solution, and then paraffin embedded for histological investigation.

• **RESULTS:** Higher levels of TA were distributed in the intraocular tissues when injected into the vitreous compared to the sub-Tenon. Conversely, TA level was remarkably lower in the rabbits which received intravitreal TA injections than those treated with sub-Tenon injection throughout the study period in plasma. Optical discharge probably caused by systemic circulation of TA was observed by receiving sub-Tenon TA injection. Meanwhile, technic-associated toxicological ocular symptoms and findings were more frequently observed in intravitreal injection than in sub-Tenon injection.

• **CONCLUSION:** There are significant differences in kinetics and distribution of TA in vitreous body, aqueous humor and plasma, between the two injection methods.

Although further study is needed to explain the species difference between human and rabbit, it is assumed that the difference in the frequency of intraocular pressure elevation and cataract formation by TA between the two injection methods are directly related to the TA concentrations in aqueous humor and vitreous body in each injection methods. Systemic toxicity and technic-associated toxicity are also closely related to kinetics of TA in plasma and each injection method itself, respectively.

• **KEYWORDS:** corticosteroid(s); pharmacokinetics; injection; ophthalmic drug delivery; toxicity

**DOI:10.18240/ijo.2020.12.04**

**Citation:** Arie Y, Miyai H, Suzuki A, Okabe T, Takashima M, Takata M, Kurasawa T, Ito M, Arakawa R, Ogura Y, Naito A. Comparative study on pharmacokinetics and toxicity of intravitreal and sub-Tenon injection of triamcinolone acetonide in ocular tissues. *Int J Ophthalmol* 2020;13(12):1864-1871

## INTRODUCTION

**T**riamcinolone acetonide (TA), one of the synthetic corticosteroids, has been widely used as an anti-inflammatory agent. Several reports showed efficacy and toxicity of TA in cases where it was used topically or systemically. For the topical use of TA, there are many evidences that intraocular injection of TA was effective in treatments of ocular diseases including diabetic macular edema (DME)<sup>[1-2]</sup> and retinopathy<sup>[3-4]</sup>, uveitis<sup>[5-6]</sup>, age-related macular degeneration<sup>[7-8]</sup>, and vitreous body operation<sup>[9-10]</sup>. In such cases, either sub-Tenon or intravitreal injection was available as the injection method of TA. The intravitreal administration of TA had provided promising results for the treatment of these ocular diseases. However, the risk of ocular complications such as intraocular pressure (IOP) elevation<sup>[2,11-12]</sup>, endophthalmitis<sup>[13]</sup>, glaucoma<sup>[14]</sup>, and cataract<sup>[15]</sup> were reported. By contrast, the posterior sub-Tenon injection of TA showed a lower risk of these complications. Therefore, sub-Tenon injection of TA was an alternative method with proven effectiveness in various ocular diseases<sup>[16-17]</sup>. It has been

previously reported that there were some differences between two injections of TA in efficacy and toxicity<sup>[16-19]</sup>. However, the cause of differences in two injections have not been elucidated. Although some reports showed pharmacokinetic profile of TA after intravitreal injection<sup>[20-21]</sup>, there is no report comparing differences between these methods from pharmacokinetic and toxicity perspectives.

In this study, to elucidate the cause of differences in two injections, we compared the differences in kinetics, distribution and toxicity of TA between the injection methods, sub-Tenon and intravitreal injections in rabbit ocular tissues.

## MATERIALS AND METHODS

**Ethical Approval** All animals were treated and cared for in compliance with the Guiding Principles in the Care and Use of Animals. This study was approved and monitored by Internal Animal Research Ethical Committee of Wakamoto Pharmaceutical Co., Ltd. and all of the procedures were performed according to the Association for Research and Vision in Ophthalmology (ARVO) Statement for the Use of Animals in Ophthalmic and Vision Research.

**Materials** MaQaid<sup>®</sup> (Wakamoto Pharmaceutical, Tokyo, Japan) is a preservative-free TA product marketed in Japan for the aim of visualizing posterior hyaloid during vitrectomy, improving visual acuity in DME patients and improving edema accompanied by retinal vein occlusion, noninfectious uveitis and DME. TA was suspended in saline (20-80 mg/mL) immediately before injection.

**Animals** Male and female Japanese white rabbits (KITAYAMA LABES Co., Ltd.) with 1.6-3.2 kg of weight were used. In each experiment, injection was performed in one eye, and the other was left intact.

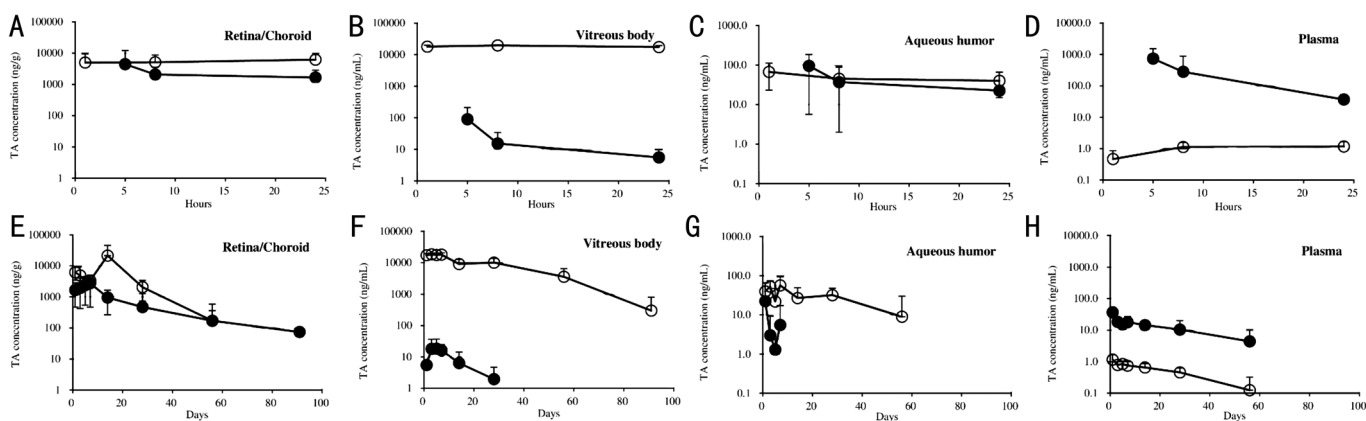
**Injection of Triamcinolone Acetonide** General anesthesia was performed in rabbits *via* intramuscular administration of medetomidine hydrochloride (0.25 mg/kg), intravenous injection of pentobarbital (30 mg/kg), or intramuscular injection of xylazine hydrochloride (1.5-2.4 mg/kg) and ketamine hydrochloride (44-48 mg/kg) separately or concomitantly, if necessary. Oxybuprocaine hydrochloride was applied topically in animals under general anesthesia before TA injections. For intravitreal injections, tropicamide was applied topically to induce mydriasis before rabbits were anesthetized systemically. The eyes were further sterilized with 0.2% povidone-iodine ophthalmic solution after anesthesia. Then, TA was injected into the vitreous or sub-Tenon as described below. Briefly, for intravitreal injection, TA suspension was directly injected into the vitreous. For sub-Tenon injection, incisions were made at the superonasal quadrant of the conjunctiva and then on the Tenon's sacs to expose the white sclera. Then 0.5 mL of TA suspension was injected into the space between the sclera and the Tenon's sac through

the incisions. Levofloxacin (Cravit<sup>®</sup> ophthalmic solution 0.5%; Santen Pharmaceutical, Co., Ltd., Osaka, Japan) was applied after each TA injection to prevent bacterial infections. In pharmacokinetic studies, a single dose of TA was injected either into the vitreous at a dose of 1.2 mg/30  $\mu$ L/eye or into the sub-Tenon at a dose of 40 mg/0.5 mL/eye, respectively. In toxicological studies, TA was injected either into the vitreous for 4 times at 4wk intervals at a dose of 1.8-7.2 mg/90  $\mu$ L/eye or into the sub-Tenon capsule for 6 times at 6wk intervals at a dose of 20-40 mg/0.5 mL/eye, respectively.

**Pharmacokinetic Study** After injection of TA, rabbits were sacrificed periodically over 91d. Blood was collected from auricular veins into tubes containing heparin and centrifuged at 3000 rpm for 10min at 4°C to separate plasma. The treated eye of each rabbit was enucleated in 5 and 8h, 1, 3, 5, 7, 14, 28, 56 and 91d after sub-Tenon injection, and in 1 and 8h, 1, 2, 3, 5, 7, 14, 28, 56, and 91d after intravitreal injection, respectively. The ocular tissues (retina/choroids, vitreous, and aqueous humor) were collected and stored at -20°C or below until use. Before determination of TA, the aqueous humor in the intravitreal injection group, was filtrated (Ultra free-MC; Millipore Corp.). The aqueous humor, the vitreous and retina/choroids in the sub-Tenon injection group, were denatured by adding trifluoroacetic acid. And the samples in the retina/choroids were extracted by t-butyl methyl ether. The retina/choroids and the vitreous in the intravitreal injection group, were extracted by t-butyl methyl ether. The contents of TA in these tissues were determined by high performance liquid chromatography (HPLC, LC-10AD, Shimadzu Corporation) or liquid chromatography-mass spectrometry (LC/MS/MS, HPLC; SIL-HTC, LC-10A series, Shimadzu Corporation, AQUITY UPLC, Waters Corp., Tandem mass; API4000, AB Sciex Pte. Ltd.). TA in the plasma was extracted by the solid column [Oasis HLB Cartridge (3 mL/60 mg, 30  $\mu$ m, Waters Corp.)], then the content of TA in the plasma was determined by LC/MS/MS (HPLC; SIL-HTC, LC-10A series, Shimadzu Corporation, AQUITY UPLC, Waters Corp., Tandem mass; API4000, AB Sciex Pte. Ltd.). Pharmacokinetic parameters were calculated using Phoenix WinNonlin 6.3 (Pharsight Corporation as part of Certara) or MOMENT (EXCEL).

**Toxicological Study** TA was injected either into the sub-Tenon capsule for 6 times at 6wk intervals or into the vitreous for 4 times at 4wk intervals. Clinical signs were observed every 24h throughout the experimental period. Slit-lamp microscopic examination was performed in 1, 3, and 6wk after sub-Tenon injection, and in 2d, 1, 2, and 4wk after intravitreal injection, using portable slit lamp (SL-15, Kowa Company. Ltd.) or ophthalmological test was performed in 3 and 5wk after sub-Tenon injection using binocular Indirect ophthalmoscope (Omega 200, Heine Optotechnik GmbH

## Kinetics and toxicity of triamcinolone acetoneide



**Figure 1** Pharmacokinetic profile of TA after sub-Tenon and intravitreal injection in rabbits A-D: From 0 to 24h after the injection; E-H: From 1 to 91d after the injection. ○: Intravitreal injection, ●: Sub-Tenon injection. Data indicate the mean±SD of 6 rabbits.

**Table 1** Ocular symptoms and findings after intravitreal or sub-Tenon's injection of TA

Examinations	Symptoms and findings	Intravitreal injection						Sub-Tenon injection						
		Control		1.8 mg		3.6 mg		Control		20 mg		40 mg		
		M:5 <sup>a</sup>	F:5	M:5	F:5	M:5	F:5	M:6	F:6	M:4	F:4	M:4	F:4	
Clinical signs	Optical discharge <sup>b</sup>	-	-	-	-	-	-	-	1	-	4	3	3	4
Ophthalmological test	Lens-opacity, focal, lens suture	-	-	-	-	-	-	-	-	-	-	-	1 <sup>c</sup>	-
Histopathological findings in lacrimal gland	Increase in secretory granule of acinar cell, very slight	-	-	-	-	-	1	-	-	-	-	-	-	-
	Vacuolation of acinar cell, very slight	-	-	-	-	-	1	-	-	-	-	-	-	-
Histopathological findings in accessory lacrimal gland	Increase in secretory granule of acinar cell, slight	-	-	-	-	-	1	-	-	-	-	-	-	-
	Vacuolation of acinar cell, very slight	-	-	-	-	-	1	-	-	-	-	-	-	-
	Degeneration of acinar cell, slight	-	-	-	-	-	-	-	-	1 <sup>d</sup>	-	-	-	-
Histopathological findings in Tenon capsule	Cell infiltration, very slight	-	-	-	-	-	-	-	-	3	1	1	2	-
	Cell infiltration, slight	-	-	-	-	-	-	-	-	-	-	1	-	-
	Macrophage infiltration, very slight	-	-	-	-	-	-	-	-	3	2	1	3	-
	Macrophage infiltration, slight	-	-	-	-	-	-	-	-	1	2	2	-	-

<sup>a</sup>Sex:number of animals; <sup>b</sup>Observed in injected eye, non-injected eye or both of them; <sup>c</sup>Observed in non-treated eye; <sup>d</sup>Observed in both of injected and non-injected eyes.

& Co.Kg.). Rabbits were sacrificed 42d after the 6<sup>th</sup> sub-Tenon injection or 28d after the 4<sup>th</sup> intravitreal injection. The eyeballs and surrounding tissues were collected and fixed with glutaraldehyde-formalin solution, and then paraffin embedded for histological investigation.

## RESULTS

**Pharmacokinetics** After injection of TA into the sub-Tenon or the vitreous, the concentrations of TA in the plasma and ocular tissues were measured periodically over 91d. The TA levels of plasma and ocular tissues are shown in Figure 1. The TA concentrations in the retina/choroid were consistent around 2000-5000 ng/g for 7d in rabbits with sub-Tenon injection and for 28d in those with vitreous injection. In these tissues, TA was detectable for up to 91 and 56d in rabbits treated with sub-Tenon injection and vitreous injection, respectively. In the vitreous and the aqueous humor, TA levels decreased rapidly after sub-Tenon injection, while after intravitreal injection, the levels decreased gradually. In the vitreous, TA was detectable for up to 91d after intravitreal injection but it was not detectable at 56d after sub-Tenon injection. In the aqueous humor, TA was detectable for up to 56d after intravitreal injection, while on the other hand after the sub-

Tenon injection, it was negligible in 14d. In the plasma, TA level reached the peak 5h after the sub-Tenon injection ( $C_{max}=736.96\pm 803.36$  ng/mL) and declined to 5% of  $C_{max}$  on the following day. Meanwhile, it was remarkably lower ( $C_{max}=1.191\pm 0.735$  ng/mL) in the rabbits which received intravitreal TA injections than those treated with sub-Tenon injection throughout the study period.

**Toxicity** There were some changes in ocular tissues following sub-Tenon or intravitreal TA injection (Table 1). Optical discharge was observed with sub-Tenon injections of TA and saline (control), both in treated and untreated eyes of these animals (Figure 2). Lens focal opacity was also seen in the non-treated eye of one male rabbit which received 40 mg of sub-Tenon TA injections. Slight degeneration of acinar cells in the accessory lacrimal gland was histologically observed both in the treated and untreated eyes of one male rabbit which received 20 mg of sub-Tenon TA injection. Infiltration of macrophage-like inflammatory cells in Tenon capsule was histologically observed in rabbit eyes treated with 20 and 40 mg of sub-Tenon TA injections. Residual TA depot was observed in the Tenon-capsule even after 91d in these animals treated with TA injection (data not shown). Increase

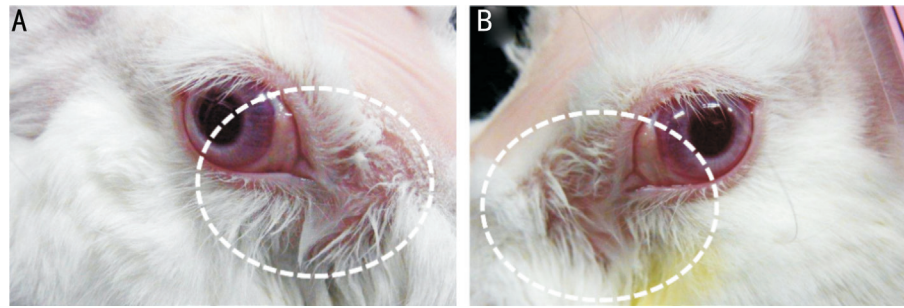


Figure 2 Optical discharge observed by sub-Tenon injection of TA in rabbits A: Male, 20 mg, treated-eye; B: Male, 40 mg, untreated eye.

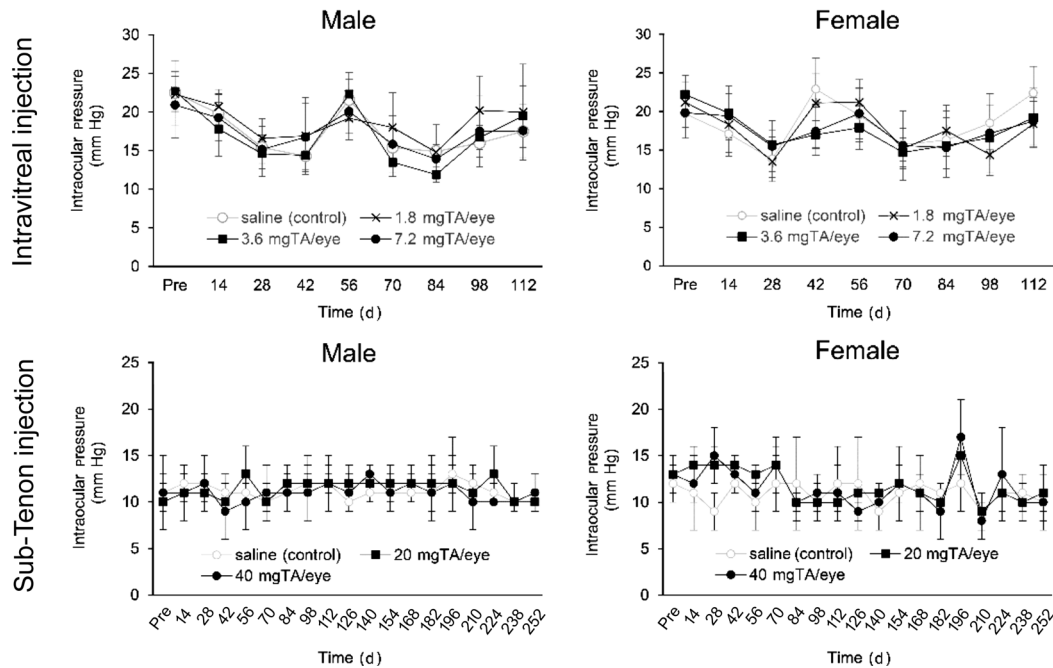


Figure 3 Change of IOP during the TA treatment in rabbits Data indicate the mean±SD of 4-6 rabbits.

of secretory granules and vacuolation in acinar cell of lacrimal gland and accessory lacrimal gland were histologically observed in one male rabbit which received 7.2 mg of TA injection. There were some symptoms and findings that were likely to be caused by injection procedures (Table 2). Redness in conjunctiva was induced by both injections. Other changes were observed in clinical sign, eyeball, conjunctiva, vitreous body, lens, and retina only with intravitreal injections. Elevation of IOP, a typical side effect observed in steroid-treated patients, was not observed as a result of either injections throughout the study (Figure 3). There were no signs of toxicities in other examinations (funduscopy examination, electroretinography examination and light reflex examination) after sub-Tenon or intravitreal injection (data not shown).

### DISCUSSION

In this study, comparisons were made on pharmacokinetics and toxicity of TA between two injection methods (sub-Tenon and intravitreal injections). Several studies have reported the intraocular or systemic pharmacokinetics of TA after intravitreal injection or sub-Tenon injection in human<sup>[20,22]</sup>. In these studies, pharmacokinetics of TA was demonstrated

in different ocular tissues among the studies. Additionally, in contrast to aqueous humor and vitreous body, few studies have reported pharmacokinetics of TA in retina/choroid. Whereas, in our study, we confirmed pharmacokinetic differences of TA in retina/choroid, vitreous body, aqueous humor and plasma in both intravitreal injection and sub-Tenon injection. These results enabled us to compare the pharmacokinetics of TA in two injections correctly. Further, we studied the toxicity of TA in both injections and then discussed the relation between the pharmacokinetics and toxicity of TA. In the pharmacokinetic study, rabbits received 40 mg/eye of sub-Tenon or 1.2 mg/eye of intravitreal TA injection, and TA concentrations in ocular tissues were measured periodically over 91d (Figure 1). In most ocular tissues, TA reached  $T_{max}$  within 8h after both injections. In retina/choroids, which are the target tissue of TA for treatment of DME, both of these two injections attained adequate TA concentration known to show anti-inflammatory effects ( $170 \text{ ng/g} \approx 3.9 \times 10^{-7} \text{ mol/L}$ , data not shown). In the retina/choroid, vitreous and the aqueous humor, TA levels were higher with intravitreal injection than with sub-Tenon injection, although the amount of TA injected into the sub-Tenon was

**Table 2 Ocular symptoms and findings caused by injection technique**

Examinations	Symptoms and findings	Intravitreal injection								Sub-Tenon injection					
		Control		1.8 mg		3.6 mg		7.2 mg		Control		20 mg		40 mg	
		M:5 <sup>a</sup>	F:5	M:5	F:5	M:5	F:5	M:5	F:6	M:4	F:4	M:4	F:4	M:4	F:4
Clinical signs	Incomplete eyelid opening <sup>b</sup>	5	4	5	5	5	5	6	6	-	-	-	-	-	-
	Redness in conjunctiva	2	1	2	1	-	2	2	-	1	3	2	2	3	4
	White turbidity in eyeball	5	3	5	4	5	3	6	5	-	-	-	-	-	-
Slit-lamp microscopic examination	Clear and colorless flottage in eyeball	-	-	2	1	3	-	3	-	-	-	-	-	-	-
	White flottage in anterior chamber	-	-	3	1	2	1	2	1	-	-	-	-	-	-
	Clear and colorless flottage in anterior chamber	-	-	1	1	-	-	-	-	-	-	-	-	-	-
	Vitreous body-white turbidity like test article	-	-	5	5	5	5	6	6	-	-	-	-	-	-
	White discoloration of vitreous body	-	-	1	-	-	-	1	1	-	-	-	-	-	-
	Thinning of lens	-	-	-	-	-	-	1	-	-	-	-	-	-	-
	White focus, lens	2	-	2	1	3	1	2	-	-	-	-	-	-	-
Gross pathological findings	White material, vitreous body	-	-	3	4	5	5	5	5	-	-	-	-	-	-
	Residue of test substance, very slight	-	-	-	-	-	-	-	-	-	-	3	4	1	1
	Residue of test substance, slight	-	-	-	-	-	-	-	-	-	-	1	-	2	3
Histopathological findings in eyeball including bulbar conjunctiva and optic nerve	Hemorrhage in vitreous body, very slight	-	1	-	-	1	-	-	-	-	-	-	-	-	-
	Focal retinal degeneration, very slight	-	1	-	1	1	1	1	-	-	-	-	-	-	-

<sup>a</sup>Sex: Number of animals; <sup>b</sup>Observed in both of injected and non-injected eyes.

thirty times greater than that injected into the vitreous body. Elimination of TA in the vitreous and aqueous humor was slower with intravitreal injection compared to sub-Tenon injection. These results indicate that TA can be distributed more efficiently in the intraocular tissues when injected into the vitreous compared to the sub-Tenon, as the percentage of ocular tissue-specific TA distribution in the total amount of injection was much higher with vitreous injection compared to sub-Tenon injection. It was reported that transscleral drug delivery was regulated by 3 types of barriers<sup>[23-25]</sup> and that disruption of these barriers increased delivery of TA into vitreous from Tenon’s capsule<sup>[25]</sup>. As the barriers were not disturbed in our study and the TA concentrations were significantly high at retina/choroid, which was closely located to the injection sites in both injections, TA seemed to have distributed into retina/choroid from each injected site in density-dependent diffusion system. TA hardly dissolves in water (saturated solubility of TA was about 20 µg/mL<sup>[26]</sup>). Hence, TA seemed to have gradually dissolved at the injected site then continuously diffused to the retina/choroids for as long as the TA depot existed in the injection sites. At the same time, TA was detected in the vitreous body following sub-Tenon injection. Similar results were obtained in the previous report<sup>[25]</sup>. Although the mechanism of TA delivery from Tenon’s capsule into the vitreous body was not fully discussed in their report, based on our data, it was assumed that density-dependent diffusion may be mainly involved in the delivery of TA into vitreous from Tenon-capsule. With regard to the aqueous humor, TA distribution after intravitreal injection and sub-Tenon injection were seemed to be regulated by density-dependent diffusion from the vitreous body and delivery from plasma, respectively. In our study the mean half-life of TA in vitreous body and aqueous humor after an intravitreal injection were 15.8d and

18.5d, respectively. These results were coincident with the previous reports in human<sup>[20]</sup> and were also indicating that metabolic rates of TA in these tissues were similar between the species. Regarding to the actual concentration of TA in aqueous humor, it was lower in rabbit compared with human when it is injected into vitreous body<sup>[27]</sup>. As mentioned below, these results might relate to the difference in occurrence frequency of IOP elevation and cataract formation between the species. It is presumed that difference in size of crystalline lens between rabbit and human affects the TA concentration in aqueous humor. That is, diffusion of TA from vitreous body to aqueous humor is supposed to be disturbed by crystalline lens, and then this disturbance effect of crystalline lens might be more significantly observed in rabbit compared to human, because thickness of crystalline lens is 1.3-1.7 times larger in rabbit than that of human<sup>[28]</sup>. In the plasma, concentration of TA was much higher in sub-Tenon injection than in intravitreal injection throughout the experimental period. Since Tenon’s capsule is located near the highly vascular tissue, TA was supposed to be directly absorbed into the whole blood through these blood vessels in the Tenon-capsule. Our results also showed that plasma TA concentration after sub-Tenon injection was significantly higher in rabbit compared with human<sup>[22]</sup>. However, considering difference in total blood volume between rabbit and human, it was reasonable to suppose that plasma TA concentration in rabbit was higher than that of human. On the other hand, although there have been few reports about the plasma levels of TA after intravitreal injection in human, from our results it was suggested that plasma TA concentration in intravitreal injection was lower than that in sub-Tenon injection in human. Some toxicological ocular symptoms and findings were obtained with sub-Tenon and intravitreal injections (Table 1).

Optical discharge was observed by the sub-Tenon injection of TA and saline (control; Table 1, Figure 2). It was considered to be systemically caused by TA, because these were observed both in injected eyes and non-injected eyes. These symptoms are supported by a report in which a derivative of dexamethasone which was perorally, subcutaneously or intraperitoneally administered at a systemic toxic dose caused optical discharge in rats and rabbits<sup>[29]</sup>. Indeed, our data showed that the plasma TA level observed in sub-Tenon injection closed to toxic level in rabbits. Lens cataract-related finding was not observed by intravitreal injection and was observed in one individual rat by high dose of sub-Tenon TA injection. We concluded that the absence of significant effect of steroid on cataract was due to insufficiency in the experiment term for inducing cataract in our study. These findings are supported by another study, in which intravitreal injection of TA did not cause cataract in rabbits during one month after the injection of TA<sup>[30]</sup>. The report concluded that long-term study will be needed to confirm the relevance of these effects in animals. Indeed, 41wk of corticosteroid administration into subconjunctiva caused cataract in rabbits<sup>[31]</sup>. Further, in our study high dose of sub-Tenon injection of TA caused lens opacity in non-treated eye, indicating that systemic circulation of steroid might be related to cataract formation during a short-term exposure of TA. Elevation of IOP which was another potential adverse event of TA and was frequently observed in intravitreal injection of TA, was not observed either (Figure 3). Although further study is needed to explain the difference in TA-mediated elevation of IOP and cataract formation between humans and animals<sup>[32-33]</sup>, the difference in the TA concentration in aqueous humor between rabbit and human might related to the difference in occurrence frequency of these adverse effects between the species. In humans, TA-induced these adverse effects, cataract and IOP elevation, were observed at a higher frequency in intravitreal injection as compared with sub-Tenon injection<sup>[16,18]</sup>. Our results showed that the differences in a frequency of IOP elevation and cataract formation by TA between the two injections were directly related to the TA concentrations in vitreous and aqueous humor in each injection.

Some ocular symptoms and findings were also obtained in acinar cells in lacrimal gland and accessory lacrimal gland following both injections. Although the mechanisms of these changes were not fully explained, individual specificity may be related to develop these findings because it was observed in one individual rat both in intravitreal injection and in low dose of sub-Tenon injection. Infiltration of macrophage-like inflammatory cells in Tenon capsule was histologically observed in sub-Tenon TA injection. It was assumed not to be a result from toxicity of TA but to be a biological defense reaction against an exogenous substance, TA.

As previously mentioned, some ocular symptoms and findings were obtained following administration of TA by two injection routes. On the other hand, the injection procedure itself also seemed to be related to development of some toxicological ocular symptoms or findings in clinical sign, eyeball, conjunctiva, vitreous body, lens and retina (Table 2). These changes were more frequently observed in intravitreal injection than in sub-Tenon injection. Several studies suggested that there may be some technic-associated findings that include endophthalmitis, redness in conjunctiva, chemosis of conjunctiva, retinal tear, detachment of retina, increased IOP and cataract<sup>[34-35]</sup> in patients with intravitreal injection. Furthermore, another study suggested some risks of damaging the crystalline lens by intravitreal injection<sup>[36]</sup>. Although technic-associated findings and the risks of procedure could be more significant in rabbits than in humans, results of this study partially support the findings and the risks reported in these studies.

In conclusion, there were significant differences in kinetics and distribution of TA in vitreous body, aqueous humor and plasma, between the two injection methods in rabbits. Although further study is needed to explain the species difference in TA-dependent adverse effects between human and rabbit, it is assumed that the difference in the frequency of these adverse effects by TA between the two injection methods were directly related to the TA concentrations in aqueous humor and vitreous body in each injection methods. Although systemic toxicities might be concerned when excess dose of TA was injected into the sub-Tenon, so far as optimum dose was used, sub-Tenon injection appeared to be more useful than intravitreal injection, because the risks of technic-associated toxicities were less significant in the case of sub-Tenon TA injection compared with intravitreal injection and development of cataract and elevation of IOP were still concerned in intravitreal injection of TA both in humans and animals.

#### ACKNOWLEDGEMENTS

**Conflicts of Interest:** Arie Y, None; Miyai H, None; Suzuki A, None; Okabe T, None; Takashima M, None; Takata M, None; Kurasawa T, None; Ito M, None; Arakawa R, None; Ogura Y, None; Naito A, None.

#### REFERENCES

- 1 Ghoraba HH, Leila M, Elgouhary SM, Elgemai EEM, Abdelfattah HM, Ghoraba HH, Heikal MA. Safety of high-dose intravitreal triamcinolone acetonide as low-cost alternative to anti-vascular endothelial growth factor agents in lower-middle-income countries. *Clin Ophthalmol* 2018;12:2383-2391.
- 2 Shin YU, Hong EH, Lim HW, Kang MH, Seong M, Cho H. Quantitative evaluation of hard exudates in diabetic macular edema after short-term intravitreal triamcinolone, dexamethasone implant or bevacizumab injections. *BMC Ophthalmol* 2017;17(1):182.

- 3 Unoki N, Nishijima K, Kita M, Suzuma K, Watanabe D, Oh H, Kimura T, Sakamoto A, Yoshimura N. Randomised controlled trial of posterior sub-Tenon triamcinolone as adjunct to panretinal photocoagulation for treatment of diabetic retinopathy. *Br J Ophthalmol* 2009;93(6):765-770.
- 4 Fujiwara Y, Iwase T, Yamamoto K, Ueno Y, Ra E, Terasaki H. Effect of intravitreal or sub-tenon triamcinolone acetonide injection at completion of vitrectomy on peripheral retinochoroidal thickness in eyes with proliferative diabetic retinopathy. *Sci Rep* 2019;9(1):171.
- 5 Ferreira BG, Marinho DR, Diligenti FT. Effects of sub-Tenon's triamcinolone injections in patients with uveitis. *Arq Bras Ophthalmol* 2018;81(4):323-329.
- 6 Sreekantam S, MacDonald T, Keane PA, Sim DA, Murray PI, Denniston AK. Quantitative analysis of vitreous inflammation using optical coherence tomography in patients receiving sub-Tenon's triamcinolone acetonide for uveitic cystoid macular oedema. *Br J Ophthalmol* 2017;101(2):175-179.
- 7 Veritti D, Sarao V, Lanzetta P. Bevacizumab and triamcinolone acetonide for choroidal neovascularization due to age-related macular degeneration unresponsive to anti-vascular endothelial growth factors. *J Ocul Pharmacol Ther* 2013;29(4):437-441.
- 8 Becerra EM, Morescalchi F, Gandolfo F, Danzi P, Nascimbeni G, Arcidiacono B, Semeraro F. Clinical evidence of intravitreal triamcinolone acetonide in the management of age-related macular degeneration. *Curr Drug Targets* 2011;12(2):149-172.
- 9 Qi Y, Duan AL, Meng X, Wang NL. Vitrectomy without inner limiting membrane peeling for macular retinoschisis in highly myopic eyes. *Retina* 2016;36(5):953-956.
- 10 Couch SM, Bakri SJ. Use of triamcinolone during vitrectomy surgery to visualize membranes and vitreous. *Clin Ophthalmol* 2008;2(4):891-896.
- 11 Chang AA, Li HT, Broadhead GK, Luo KH, Zhu MD. Safety and efficacy of intravitreal preservative-free triamcinolone acetonide (trienesce) for macular edema. *J Ocul Pharmacol Ther* 2015;31(9):563-569.
- 12 Ogura Y, Shimura M, Iida T, Sakamoto T, Yoshimura N, Yamada M, Ishibashi T. Phase II/III clinical trial of sub-tenon injection of triamcinolone acetonide (WP-0508ST) for diabetic macular edema. *Ophthalmologica* 2019;241(3):161-169.
- 13 Dodwell DG, Krimmel DA, de Fiebre CM. Sterile endophthalmitis rates and particle size analyses of different formulations of triamcinolone acetonide. *Clin Ophthalmol* 2015;9:1033-1040.
- 14 Baath J, Ells AL, Crichton A, Kherani A, Williams RG. Safety profile of intravitreal triamcinolone acetonide. *J Ocul Pharmacol Ther* 2007;23(3):304-310.
- 15 Garoon RB, Coffee RE, Jiang L, Weng CY, Carvounis PE. Adjunct intravitreal triamcinolone acetonide in the treatment of diabetic macular edema with anti-VEGF agents. *J Ophthalmol* 2016;2016:5282470.
- 16 Luo DW, Zhu BJ, Zheng Z, Zhou HD, Sun XD, Xu X. Subtenon vs intravitreal triamcinolone injection in diabetic macular edema, a prospective study in Chinese population. *Pak J Med Sci* 2014;30(4):749-754.
- 17 Qi HP, Bi S, Wei SQ, Cui H, Zhao JB. Intravitreal versus subtenon triamcinolone acetonide injection for diabetic macular edema: a systematic review and meta-analysis. *Curr Eye Res* 2012;37(12):1136-1147.
- 18 Abd El-Razik AH, El-Sayed S, Ellakwa AA, Badawi N. Intravitreal versus subtenon injection of triamcinolone acetonide for diabetic macular edema. *Menoufia Med J* 2014;27(4):636.
- 19 Takata C, Messias A, Folgosa MS, Lucena LR, Lucena DR, Scott IU, Jorge R. Intravitreal injection versus subtenon infusion of triamcinolone acetonide during cataract surgery in patients with refractory diabetic macular edema. *Retina* 2010;30(4):562-569.
- 20 Yang Y, Bailey C, Loewenstein A, Massin P. Intravitreal corticosteroids in diabetic macular edema: pharmacokinetic considerations. *Retina* 2015;35(12):2440-2449.
- 21 Ye YF, Gao YF, Xie HT, Wang HJ. Pharmacokinetics and retinal toxicity of various doses of intravitreal triamcinolone acetonide in rabbits. *Mol Vis* 2014;20:629-636.
- 22 Kovacs K, Wagley S, Quirk MT, Ceron OM, Silva PA, Singh RJ, Gukasyan HJ, Arroyo JG. Pharmacokinetic study of vitreous and serum concentrations of triamcinolone acetonide after posterior sub-tenon's injection. *Am J Ophthalmol* 2012;153(5):939-948.
- 23 Pickrell A, Harris A, Ngo S, Amireskandari A, Stewart E, Siesky B. Delivery of intraocular triamcinolone acetonide in the treatment of macular edema. *Pharmaceutics* 2012;4(1):230-242.
- 24 Kim SH, Lutz RJ, Wang NS, Robinson MR. Transport barriers in transscleral drug delivery for retinal diseases. *Ophthalmic Res* 2007;39(5):244-254.
- 25 Robinson MR, Lee SS, Kim H, Kim S, Lutz RJ, Galban C, Bungay PM, Yuan P, Wang NS, Kim J, Csaky KG. A rabbit model for assessing the ocular barriers to the transscleral delivery of triamcinolone acetonide. *Exp Eye Res* 2006;82(3):479-487.
- 26 Behl CR, Block LH, Borke ML. Aqueous solubility of 14C-triamcinolone acetonide. *J Pharm Sci* 1976;65(3):429-430.
- 27 Beer PM, Bakri SJ, Singh RJ, Liu WG, Peters GB 3rd, Miller M. Intraocular concentration and pharmacokinetics of triamcinolone acetonide after a single intravitreal injection. *Ophthalmology* 2003;110(4):681-686.
- 28 Atsumi I, Kurata M, Sasaki H. Comparative study on ocular anatomical features among rabbits, beagle dogs and cynomolgus monkeys. *Anim Eye Res* 2013;32:35-41.
- 29 Sutou H, Ohmae S, Imamura K, Nakano S, Morita K. Acute toxicity study of dexamethasone 17,21-dipropionate (THS-101) in rats and rabbits. *Oyo yakuri* 1984;28(4):687-695.
- 30 McGee DH, Dembinska O, Gruebbel MM. Evaluation of triamcinolone acetonide following intravitreal injection in New Zealand white rabbits. *Int J Toxicol* 2005;24(6):419-425.
- 31 Tarkkanen A, Esilä R, Liesmaa M. Experimental cataracts following long-term administration of corticosteroids. *Acta Ophthalmol (Copenh)* 1966;44(4):665-668.

- 32 Rybkin I, Gerometta R, Fridman G, Candia O, Danias J. Model systems for the study of steroid-induced IOP elevation. *Exp Eye Res* 2017;158:51-58.
- 33 Xu X, Han Y, Kong L, Ding X, Liu F, Cheng L. Clinical implication of triamcinolone in aqueous humor after depository sub-Tenon application. *J Cataract Refract Surg* 2017;43(11):1383-1390.
- 34 Nelson ML, Tennant MT, Sivalingam A, Regillo CD, Belmont JB, Martidis A. Infectious and presumed noninfectious endophthalmitis after intravitreal triamcinolone acetonide injection. *Retina* 2003;23(5):686-691.
- 35 Ogura Y, Takahashi K, Iida T. Guidelines for intravitreal injection for macular diseases. *Nippon Ganka Gakkai Zasshi* 2016;120(2):87-90.
- 36 Alam MS, Khetan V. Inadvertent steroid injection into the crystalline lens. *GMS Ophthalmol Cases* 2017;7.