

Newer trends in tubercular uveitis: a case series with systemic correlation

Radha Annamalai, Meera Mohanakumar, Krishnima Raghu, Muthukumar Muthayya

Department of Ophthalmology, Sri Ramachandra Medical College and Research Institute, Porur, Chennai 600116, India

Correspondence to: Radha Annamalai. Department of Ophthalmology, Sri Ramachandra Medical College and Research Institute, Porur, Chennai 600116, India. dradhasmc@gmail.com

Received: 2019-11-19 Accepted: 2020-03-19

Abstract

• **AIM:** To determine the spectrum of uveitis, causes of visual loss in systemic tuberculosis (TB), role of investigations and outcome after anti-TB therapy (ATT).

• **METHODS:** A retrospective study was conducted on 250 patients with systemic TB at a referral center in Chennai, South India from April 2016 to May 2019. Systemic workup comprised of Mantoux, chest X-ray, polymerase chain reaction (PCR) and QuantiFERON (QFT) TB Gold. Aqueous humor analysis by nested PCR or real time PCR (RT-PCR) and ancillary ophthalmic investigations such as fundus fluorescein angiography, optical coherence tomography were performed.

• **RESULTS:** Multifocal choroiditis and vasculitis were the most common manifestations (39% and 24% respectively) together accounting for 61% of cases and they had a higher risk of recurrence (3%). Pulmonary tuberculosis (PTB) was more frequently associated with uveitis (18%). Among those with extra-pulmonary tuberculosis (EPTB), uveitis occurred in miliary TB (2%), bone (1%) and abdominal TB (1%). Complications such as cystoid macular edema, choroidal neovascular membranes and macular scarring caused visual loss. Aqueous humor analysis detected mycobacterium TB antigen. Collectively, systemic investigations such as chest X-ray, Mantoux test and those performed on blood samples such as PCR and QFT were positive in 39% of patients. In inconclusive patients, nested PCR and/or RT-PCR were done on aqueous humor samples and were diagnostic in 96%. A combination of tests was diagnostic in 92%. ATT in isolation in 71% and combined with corticosteroids in 29% was used for treatment of which signs of resolution and improvement in vision started as early as 6wk in those who were started immediately on corticosteroids and ATT and

longer than 3mo in those on ATT alone. Prompt treatment with ATT and corticosteroids improved vision in 23% of our patients within 2mo. Vitritis with choroiditis causes cystoid macular oedema and requires longer duration of ATT. Vision improved in 69%. Complete resolution occurred in 75% and worsening in 12%.

• **CONCLUSION:** A combination of investigations guided by clinical suspicion helps in precise diagnosis. In diagnostic dilemmas analysis of ocular samples is reliable and confirmatory. Screening all patients and a multidisciplinary approach in TB (active, healed or during treatment) is recommended.

• **KEYWORDS:** uveitis; tuberculosis; choroiditis; anti-tuberculosis therapy; vasculitis

DOI:10.18240/ijo.2020.11.09

Citation: Annamalai R, Mohanakumar M, Raghu K, Muthayya M. Newer trends in tubercular uveitis: a case series with systemic correlation. *Int J Ophthalmol* 2020;13(11):1739-1744

INTRODUCTION

Tuberculosis (TB) continues to remain the most common infectious disease and a major public concern^[1]. Ocular inflammation and uveitis can occur in pulmonary tuberculosis (PTB) or extra-pulmonary tuberculosis (EPTB) and result in visual loss during both the active and healed stages^[2]. The quality of life is severely affected in these patients. There has been a resurgence of TB uveitis due to acquired immunodeficiency syndrome. Other factors which contribute to diagnosis are a history of contact with TB, systemic disease, drug use and socioeconomic status. TB uveitis can be treated and vision completely restored with prompt diagnosis and early treatment with anti-TB therapy (ATT) along with topical medications. The patient needs to be monitored for improvement in signs, visual recovery, complications and recurrences.

Both the presence of active bacilli and an immune response to tuberculous antigens, which have been proven by microbiological or histopathological investigations, support the diagnosis of TB uveitis. Miliary TB accounts for 2% of all new cases of TB and approximately 20% of all extra-pulmonary

cases^[3]. It is a potentially fatal form of disseminated TB that follows massive hematogenous spread and inhibition of protective immune responses allowing dissemination^[4]. The incidence of tubercular uveitis due to active disease as against latent TB due to hypersensitivity to the DNA TB bacillus has not been studied and we tried to establish which was more frequent. We also analyzed if there was any difference in the pattern of uveitis in these two types. There has been no study to assess and compare the role of systemic and ocular investigations when combined and their effects on treatment or visual outcome. We conducted a retrospective study of patients with TB to assess the specific patterns of uveitis, type of systemic TB and assessed their response to ATT. The role of systemic and ocular investigations in the diagnosis of tubercular uveitis was to be analyzed as part of our study. Previous reports stating the application and reliability of polymerase chain reaction (PCR) and real time polymerase chain reaction (RT-PCR) on vitreous samples in TB uveitis exist. We have studied the role of RT-PCR in various forms of posterior uveitis (PU) and its application in TB and EPTB and its usefulness along with nested PCR on aqueous samples and compared these results with systemic investigations.

SUBJECTS AND METHODS

Ethical Approval Approval for this study was obtained from the Institutional Ethics Committee of Sri Ramachandra Medical College and Research institute, Chennai, India, where this study was conducted (Ethics Committee Reference number: CSP-MED/19/JUL/54/96). A retrospective study of 250 proven cases of TB was done over a period of 3y. An informed consent explaining the need for investigations and the type of treatment was obtained from all patients.

Subjects Case records of 250 patients with TB over 3y from April 2016 to May 2019 were analyzed. Ophthalmic examination included visual acuity check, intraocular pressures, slit lamp examination, indirect ophthalmoscopy and fundus photography. Ancillary tests such as fundus fluorescein angiography (FFA), optical coherence tomography (OCT) and B-Scan were done when indicated. Results of Mantoux, chest X-ray, PCR, gamma interferon assay and duration of treatment with ATT were evaluated in all patients. Patients with PTB and EPTB were included while infections other than TB, non-infectious and autoimmune causes were excluded from the study. Patients were classified as responders when signs of resolution and visual recovery were noted or non-responders when there was worsening of signs or vision. For all patients, a physician's opinion was obtained and follow up for a minimum period of 9mo was done.

Examination and Grouping of Patients The anatomical classification was based on the International Uveitis Study Group Classification system. A diagnosis of TB uveitis was

made if the patient satisfied the criteria (A was mandatory along with B or C): A, suspicion of TB in which clinical features of any of the following are present (granulomatous anterior uveitis, vitritis, chorioretinitis, retinal vasculitis or granuloma); B, more than one positive investigation such as Mantoux test (10 mm), positive chest X-ray, aqueous or vitreous tap positive by PCR for mycobacterium tuberculosis (MTB), histopathological evidence; C or positive response with ATT.

Ocular Investigations FFA (FF 450 Plus, Zeiss India) was done to delineate active lesions which have typical early hypofluorescence and late hyperfluorescence. Tuberculous vasculitis was identified by vascular leaking and staining^[5].

OCT (model: Cirrus HD400, Carl Zeiss, India), a noninvasive, three-dimensional imaging of the retina, choroid, and optic nerve head was used in the detection of retinal complications and to monitor treatment response^[6]. B-scan (B31000, Sonomed, Appasamy Associates), a non-invasive two-dimensional tool was done to detect vitreous hemorrhage, masquerade syndrome and retinal detachment.

PCR detects the TB antigen by DNA amplification of small genomic sequences^[7] and is more rapid than culture^[8]. In all our patients, blood or aqueous samples were used. Those with inconclusive or false results were categorized separately. PCR was performed under stringent conditions to decrease the chances of contamination.

Aqueous humor samples were collected using anterior chamber tap done under aseptic precautions, topical anaesthesia and a sterile 26-gauge needle mounted on a tuberculin syringe. The 0.1 mL of aspirate was sent for microbiological analysis. Antibiotic drops were applied after the procedure and the patient was reviewed after 6h.

Systemic Investigations Tuberculin skin test, X-ray chest, QuantiFERON TB Gold (QFT-G) and when indicated high resolution computed tomography (HRCT) was done. An *in vitro* assessment of gamma interferon increased the sensitivity of diagnosis of TB, recent or past especially the latent type^[9]. The kit used was QFT-G where heparinised blood was incubated with test antigens.

We used a combination of positive tuberculin test, QFT-G and clinical features in the identification of TB uveitis.

The outcome of the study was measured with reference to the following criteria. However, variations within the group of patients based on the site and severity of inflammation were to be considered before analysis.

Signs of clinical resolution were based on the following criteria: A: 2 step decrease in vitreous haze from the baseline visit to 3mo after treatment detected on indirect ophthalmoscopy and slit lamp biomicroscopy; B: Better definition of the borders of the lesion within 4wk; C: Pigmentation around or within

the infiltrate by 2mo; D: 2 step decrease in anterior chamber cells from baseline, brisk papillary reaction in 5d. Evidence of early hypofluorescence and late staining of the lesion on FFA; E: Decreasing or resolving macular oedema at 2wk; F: Improvement in distant visual acuity by 1 line from baseline by 1mo of treatment.

Comparison was performed between the number of patients who benefitted from ATT alone and those who required combination treatment with ATT and corticosteroids. Also, the usefulness of systemic investigations as against ocular investigations and the requirement to use blood or ocular samples was compared. The extent of improvement in vision and the complications that lead to visual loss were analyzed.

Statistical Analysis Results of examination, investigations and outcome were analyzed statistically using SPSS software. Descriptive statistics were calculated for background variables. To test the association between categorical variables, to compare between the main cohort and controls and to calculate the distribution and prevalence, Chi-square test was done as test of significance. Sub-group analysis was performed and a bias free calculation was done for correlation of clinical signs with systemic manifestations. Calculation of between group differences and categorical variables were tested for significance using Fisher exact tests. Inferences with *P*-values of less than 0.05 were considered as statistically significant.

RESULTS

A total of 250 patients with a diagnosis of TB (pulmonary and extra-pulmonary) were included in the study. The mean duration of TB in these patients was 9mo.

Mean age of onset was 35±5y and the percentage of males and females affected was 54% and 46% respectively. Uveitis was seen in 63 of 200 patients (32%). The most common symptom was visual loss which was the presentation in 69% followed by floaters in 30%, pain in 12% and redness in 8%. TB uveitis was more commonly bilateral (21 patients) and on average 5y older than those without ocular lesions (*P*=0.01). Anatomically, posterior uveitis was the most common; seen in 36 patients (87%) with *P*=0.03, followed by intermediate uveitis in 14 patients (22%), anterior uveitis 10 patients (15%) and panuveitis in 3 patients (4%).

In anterior uveitis, bilateral granulomatous iridocyclitis with iris nodules was the most common presentation. In posterior uveitis the clinical signs seen were multifocal choroiditis in 32%, vasculitis in 29%, intermediate uveitis, tuberculoma and subretinal abscess in 11% and anterior uveitis in 8% with *P*=0.3 (Table 1). Though posterior uveitis was the most frequent manifestation, we did not note any statistical significance with regard to the type of lesions. The percentage of uveitis was 18% (45 patients) in PTB and 4% (10 patients) in EPTB with *P*=0.6 (Table 2). Among those with EPTB,

Table 1 Distribution and pattern of the types of uveitis

| Types of uveitis | Distribution (%) |
|-----------------------------------|------------------|
| Multifocal choroiditis | 39 |
| Vasculitis | 24 |
| Panuveitis | 2 |
| Intermediate uveitis and vitritis | 9 |
| Acute anterior uveitis | 12 |
| Focal choroiditis | 6 |
| Subretinal abscess | 11 |

Table 2 Type of systemic TB in TB uveitis

| Spectrum of tuberculous uveitis | No. of patients |
|---------------------------------|-----------------|
| PTB | 45 (18%) |
| EPTB | 9 (4%) |
| Miliary TB | 3 |
| TB pleura | 1 |
| Abdominal TB | 1 |
| Cervical node TB | 1 |
| TB of spine | 1 |
| TB of bone | 1 |
| Breast abscess | 1 |

TB: Tuberculosis; PTB: Pulmonary tuberculosis; EPTB: Extra-pulmonary tuberculosis.

miliary TB (2%) was most common followed by bone (1%) and abdominal TB (1%). Severe visual loss was due to cystoid macular edema (CME), choroidal neovascular membranes or macular scarring in posterior uveitis and vasculitis.

TB uveitis occurred in 9% of active disease and in 87% of latent TB due to hypersensitivity to TB DNA. This was statistically significant with *P*=0.03. Among them 18% were asymptomatic. The commonest signs were vasculitis in 11%, peripheral vitreous opacities with vitreous condensation in 6% and choroiditis in 1%. Systemic investigations were positive in chest X-ray (12%), Mantoux test (66%), PCR (45%) and QFT-G (33%). Nested PCR on ocular samples and RT-PCR was positive in 96% of patients. The sensitivity was 93% for HRCT, 77% for QFT-G, 58% with PCR and 95% with RT-PCR. Specificity was defined as the conditional probability of an absence of TB as an etiology and found to be 73% with HRCT, 93% with QFT-G, 57% with PCR and 96% with RT-PCR. The predictive value showed that systemic investigations were positive in 27% and ocular investigations were positive in 96%. Combined systemic and ocular tests were positive in 92% of patients which was statistically significant (*P*<0.05).

Improvement was seen in 3mo in 22% and 6mo in 74%. In our study, duration of ATT ranged from 6 to 12mo. ATT was the only mode of treatment in 71% and ATT along with corticosteroids in 29%. In keeping with recommendations, the treatment regimen in all our patients consisted of isoniazid

5 mg/kg·d, rifampicin 450 mg/d, ethambutol 15 mg/kg·d and pyrazinamide 25 mg/kg·d for 2mo. Isoniazid and rifampicin were used for another 4 to 6mo^[10]. Oral steroids in the dose of 1 mg/kg bodyweight under cover of ATT were given till the inflammation subsided and then tapered^[11].

In terms of outcome, the first sign of improvement was seen clinically as decrease in retinitis/choroiditis with a decrease in the size of the infiltrate and better definition of the lesion due to resolution of the surrounding oedema. Of those with resolution this was noted earliest in 9% in 4wk, 42% in 2mo and 33% within 4mo. Scarring occurred in 4% of patients. Pigmented vitreous cells and haze persisted at the end of 3mo in 21%. FFA was seen as hypofluorescence and late staining in choroiditis but was contributory only during follow up.

Response to treatment started as early as 6wk with significant improvement by 3mo in 72% of patients who had received combination treatment with ATT and corticosteroids and in 28% on ATT alone. Duration of treatment required in vitritis with choroiditis was longer and did not resolve completely till the 7th month of ATT in 87% of patients with these lesions. The incidence of CME was higher in this group. Improvement in vision occurred in 69%, complete resolution in 75% and worsening in 12%.

DISCUSSION

The spectrum of clinical features, prognosis and outcome of treatment in our patients with uveitis and systemic TB are described here. There was a predominance of uveitis in the 4th decade and in males. Our results following statistical analysis suggest that individual signs, laboratory or ocular investigations in isolation are insufficient to diagnose TB uveitis. A holistic and standardized approach taking into account clinical features, investigation results and treatment response will confirm the presence of infection^[12].

The Collaborative Ocular Tuberculosis Study (COTS-1), a multinational study analysed the therapeutic effects of ATT in TB uveitis and also analysed 250 patients with retinal vasculitis^[13]. In COTS-1, report 3, the role of PCR in the diagnosis and management of TB uveitis was analysed which found that a positive or negative PCR in anterior, intermediate, posterior or panuveitis may not always be reliable as a basis for management^[14].

To our knowledge, this is the first report on 250 patients, taking into account both results of investigations (systemic and ocular) and management with ATT, for the diagnosis of TB uveitis as it has never been done as a combined study. Also, to our knowledge, an analysis to compare the incidence of active or latent TB and PTB or EPTB on the same cohort of patients has never been reported.

Uveitis was the initial manifestation of systemic TB in 21% of our patients. Isolated ocular TB without systemic

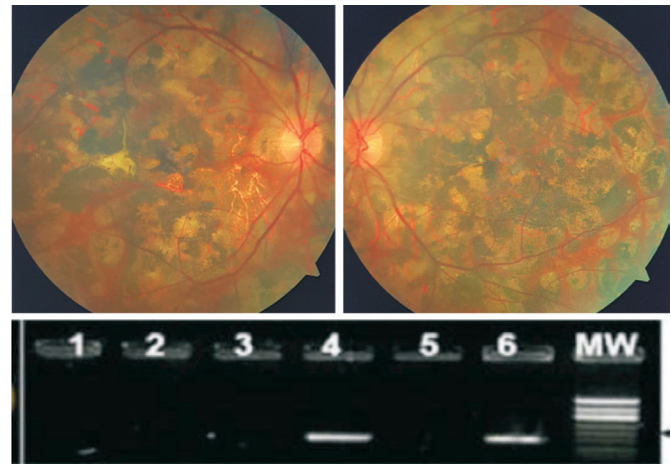


Figure 1 Both eyes showing extensive multifocal choroiditis with positive nested PCR in aqueous sample.

manifestations was present in 27%. We proposed that hypersensitivity to the DNA antigen plays a role in the pathogenesis of ocular inflammation in these patients. Reactivation is more common in this group of patients and the disease is more difficult to control.

In 70% there was evidence of systemic TB. Uveitis was more common in PTB than in EPTB, but the incidence was almost the same in latent and active types. This finding is consistent with the current reports, which state that uveitis can occur due to systemic dissemination or an immune mediated response to the TB DNA apart from active disease^[15].

In our study, posterior uveitis followed by vasculitis was the most common and we were able to achieve ocular inflammation control with adequate treatment. Bilateral multifocal choroiditis (Figure 1) was the commonest finding followed by vasculitis, or intermediate uveitis. Patients with active TB frequently presented with anterior uveitis and hypersensitivity was the cause of posterior uveitis. The most common association of uveitis in these patients was miliary TB followed by abdominal and bone TB. The most common complications were CME, choroidal neovascular membranes (CNVM) and scarring in posterior uveitis and vasculitis. Most patients who developed complications had macula involving choroiditis, scarring secondary to previous lesion with recent reactivation and development of choroidal neovascularisation. Recurrence was noted in multifocal choroiditis and vitritis in 3% of patients. was associated with a higher risk of recurrence^[16]. Mantoux test was positive in many patients with active systemic TB and may thus indicate an ongoing TB infection. We inferred that the Mantoux test may not be useful in uveitis where latent TB was the etiology. X-ray was positive in only few patients with ocular TB but in negative X-ray, HRCT was more reliable to detect signs that could not be visualized on chest X-ray. Positive serology using PCR on aqueous humour sample can occur in patients even when all other tests are

negative^[17-18]. RT-PCR and nested PCR on aqueous humor samples are reliable in the identification of MTB DNA and treatment with ATT can be started based on these results alone. Therapy is directed against TB infection and the inflammatory reaction that has occurred secondary to the antigen^[19]. Improvement was noted within 5mo in 89% of patients.

Poor response to ATT in some patients was because the inflammation was severe and steroids had not been started early. ATT for more than 9mo was associated with a significant improvement in vision. Recurrences in these patients were not seen in our study group but longer follow-up is required to assess the long term prognosis after ATT. Rao *et al*^[20] demonstrated the presence of TB bacilli in the retinal pigment epithelium of enucleated eye in panuveitis thus proving that reactivation can occur even after years and uveitis can occur a long after the systemic disease.

Those patients in our study, with vitritis in association with choroiditis developed chronic CME, required longer duration of ATT and closer monitoring. Visual recovery was delayed or poor due to the development of epiretinal membrane in the majority of our patients but other causes such as lamellar macular hole or CNVM have been reported^[21].

Rich's law of primary TB^[22] states that the extent of a tuberculous lesion is directly proportional to the number and virulence of the bacilli or hypersensitivity of the infected tissue. We found that many patients with extensive ocular lesions had latent disease suggesting that the DNA of MTB incites a reaction even in the absence of active systemic infection and the severity is determined by the age group, immune status and health of the patient. Based on our study results, in inconclusive clinical scenarios after investigations, where clinical suspicions remain high, we recommend the use of aqueous humor analysis by RT-PCR for precise identification of the TB antigen.

The conditional probability of detecting a tubercular aetiology when there is an underlying active or latent disease with uveitis is higher when a tailored approach is used combining results of investigations performed on blood and ocular samples and a delay in diagnosis can be avoided^[23].

It is important to be aware that uveitis may be the initial manifestation of active systemic TB and it is essential that all patients must be referred to the infectious diseases and pulmonology clinic as part of routine work up. Patients with choroidal involvement and associated vitreous haze have higher risk of treatment failure and complications. A good response is reported in patients in whom ATT is started early. Duration of 9-12mo of ATT gives a positive response to treatment and good prognosis in both PTB and EPTB. Our study is limited by differences in duration of ATT and corticosteroid regimens and there is a need for long-term

follow-up to evaluate recurrence of inflammation. We inferred from our study that screening for ocular involvement is necessary in all TB patients to detect evolving uveitis which can be subclinical and hence asymptomatic. The incidence of uveitis in our patients was more common in the latent type than in active TB and if left undetected the lesions can enlarge with increasing severity of inflammation. A combination of systemic and ocular investigations taking into account the type of uveitis and its severity would be more reliable. We recommend follow up at regular intervals both during the active and resolving phase to prevent complications and visual morbidity.

ACKNOWLEDGEMENTS

Authors' contributions: Annamalai R: data collection, analysis, drafting of manuscript (practical and theoretical); Mohanakumar M: data collection, drafting of manuscript (practical and theoretical); Raghu K: data collection (practical); Muthayya M: analysis and checking of manuscript (theoretical).

Conflicts of Interest: Annamalai R, None; Mohanakumar M, None; Raghu K, None; Muthayya M, None.

REFERENCES

- 1 Knight GM, McQuaid CF, Dodd PJ, Houben RMGJ. Global burden of latent multidrug-resistant tuberculosis: trends and estimates based on mathematical modelling. *Lancet Infect Dis* 2019;19(8):903-912.
- 2 Marin-Acevedo JA, Chirila RM, Cowart JB. Ocular tuberculosis. *J Gen Intern Med* 2019;34(10):2288-2289.
- 3 Sharma SK, Mohan A, Sharma A. Miliary tuberculosis: a new look at an old foe. *J Clin Tuberc Other Mycobact Dis* 2016;3:13-27.
- 4 Sharma SK, Mohan A. Miliary tuberculosis. *Microbiol Spectr* 2017;5(2).
- 5 Gupta V, Shoughy SS, Mahajan S, Khairallah M, Rosenbaum JT, Curi A, Tabbara KF. Clinics of ocular tuberculosis. *Ocular Immunol Inflamm* 2015;23(1):14-24.
- 6 Rothova A, de Boer JH, ten Dam-van Loon NH, Postma G, de Visser L, Zuurveen SJ, Schuller M, Weersink AJL, van Loon AM, de Groot-Mijnes JDF. Usefulness of aqueous humor analysis for the diagnosis of posterior uveitis. *Ophthalmology* 2008;115(2):306-311.
- 7 Sakai J, Matsuzawa S, Usui M, Yano I. New diagnostic approach for ocular tuberculosis by ELISA using the cord factor as antigen. *Br J Ophthalmol* 2001;85(2):130-133.
- 8 Gupta A, Gupta, Arora SK, Dogra M, Bambery P. PCR-positive tubercular retinal vasculitis: clinical characteristics and management. *Retina* 2001;21(5):435-444.
- 9 Itty S, Bakri SJ, Pulido JS, Herman DC, Faia LJ, Tufty GT, Bennett SR, Falk NS. Initial results of QuantiFERON-TB Gold testing in patients with uveitis. *Eye (Lond)* 2009;23(4):904-909.
- 10 Damato EM, Dawson S, Liu XX, Mukherjee C, Horsburgh J, Denniston AK, Moran E, Dedicoat M, Murray PI. A retrospective cohort study of patients treated with anti-tuberculous therapy for presumed ocular tuberculosis. *J Ophthalmic Inflamm Infect* 2017;7(1):1-6.

- 11 Elangovan S, Govindarajan S, Mayilvakanam L, Gunasekaran N. Clinical profile and treatment response of patients with ocular inflammation due to presumed ocular tuberculosis: a retrospective study. *Turk J Ophthalmol* 2019;49(4):188-193.
- 12 Gupta V, Gupta A, Rao NA. Intraocular tuberculosis—an update. *Surv Ophthalmol* 2007;52(6):561-587.
- 13 Agrawal R, Gunasekaran DV, Grant R, Agarwal A, Kon OM, Nguyen QD, Pavesio C, Gupta V, Collaborative Ocular Tuberculosis Study (COTS)-1 Study Group. Clinical features and outcomes of patients with tubercular uveitis treated with antitubercular therapy in the collaborative ocular tuberculosis study (COTS)-1. *JAMA Ophthalmol* 2017;135(12):1318-1327.
- 14 Agarwal A, Agrawal R, Gunasekaran DV, *et al*. The collaborative ocular tuberculosis study (COTS)-1 report 3: polymerase chain reaction in the diagnosis and management of tubercular uveitis: global trends. *Ocular Immunol Inflamm* 2019;27(3):465-473.
- 15 Cimino L, Herbot CP, Aldigeri R, Salvarani C, Boiardi L. Tuberculous uveitis, a resurgent and underdiagnosed disease. *Int Ophthalmol* 2009;29(2):67-74.
- 16 Bodaghi B, LeHoang P. Ocular tuberculosis. *Curr Opin Ophthalmol* 2000;11(6):443-448.
- 17 Biswas J, Kazi MS, Agarwal VA, Alam MS, Therese KL. Polymerase chain reaction for Mycobacterium tuberculosis DNA detection from ocular fluids in patients with various types of choroiditis in a referral eye center in India. *Indian J Ophthalmol* 2016;64(12):904-907.
- 18 Tabbara KF. Tuberculosis. *Curr Opin Ophthalmol* 2007;18(6):493-501.
- 19 Kee AR, Gonzalez-Lopez JJ, Al-Hity A, Gupta B, Lee CS, Gunasekaran DV, Jayabalan N, Grant R, Kon OM, Gupta V, Westcott M, Pavesio C, Agrawal R. Anti-tubercular therapy for intraocular tuberculosis: a systematic review and meta-analysis. *Surv Ophthalmol* 2016;61(5):628-653.
- 20 Rao NA, Saraswathy S, Smith RE. Tuberculous uveitis: distribution of Mycobacterium tuberculosis in the retinal pigment epithelium. *Arch Ophthalmol Chic Ill* 2006;124(12):1777-1779.
- 21 Zhang MX, Zhang JJ, Liu Y. Clinical presentations and therapeutic effect of presumed choroidal tuberculosis. *Retina* 2012;32(4):805-813.
- 22 Rich A, McCordock H. An enquiry concerning the role of allergy, immunity and other factors of importance in the pathogenesis of human tuberculosis. *Bull John Hopkins Hosp* 1929;44:273.
- 23 Patel SS, Saraiya NV, Tessler HH, Goldstein DA. Mycobacterial ocular inflammation: delay in diagnosis and other factors impacting morbidity. *JAMA Ophthalmol* 2013;131(6):752-758.