

Medical treatment of inflammatory punctual stenosis monitored by anterior segment optical coherence tomography

Hanan Youssef Elalfy¹, Mahmoud A Elsamkary², Ahmed M Shafek Elridy², Tarek M Saad², Saad Mohamed Rashad², Samah M Fawzy²

¹Al Dorra Subspecialty Ophthalmology Centre, Cairo 11751, Egypt

²Department of Ophthalmology, Ain Shams University, Cairo 11471, Egypt

Correspondence to: Samah M Fawzy. Department of Ophthalmology, Ain Shams University, Abbaseya, Cairo 11471, Egypt. samfzy2@hotmail.com

Received: 2019-09-30 Accepted: 2020-02-29

Abstract

• **AIM:** To evaluate the role of medical treatment in the management of inflammatory punctum stenosis guided by spectral domain anterior segment optical coherence tomography (OCT).

• **METHODS:** This prospective study included 60 patients complaining of epiphora due to inflammatory punctual stenosis. They were divided into two groups: Group A (30 patients) treated with a combination of preservative free hydrocortisone sodium phosphate 3.35 mg/mL eye drops, and preservative free artificial tears based on sodium hyaluronate, polyethylene and propylene Glycol; Group B (30 patients) treated with the same preservative free artificial tears only. Thirty normal subjects were included for comparison of pre-treatment anatomical parameters. Before starting treatment, all patients underwent anterior segment assessment including slit lamp examination, measurement of intraocular pressure (IOP), fluorescein dye disappearance test, and measurement of the outer punctum diameter (OPD) by Spectral domain anterior segment OCT. All assessments were repeated at each follow up done at 1 and 3mo later, together with subjective evaluation of patient's satisfaction of the treatment outcome by simple rating questionnaire.

• **RESULTS:** Punctual diameter increased significantly with treatment in both groups ($P < 0.0001$); although the widening was more in Group A as compared to group B (16.2% vs 8% of the original punctual size, mean difference of 28.933 μm , $P = 0.0076$). Subjective satisfaction with treatment outcome was also better in group A (70% vs 40%, Chi-square $P = 0.0397$).

• **CONCLUSION:** A combination of preservative free steroid eye drops and artificial tears causes significant widening of inflamed stenotic punctae and improvement of the associated epiphora.

• **KEYWORDS:** artificial tears; hydrocortisone; inflammatory punctual stenosis; optical coherence tomography; preservatives

DOI:10.18240/ijo.2020.07.09

Citation: Elalfy HY, Elsamkary MA, Elridy AMS, Saad TM, Rashad SM, Fawzy SM. Medical treatment of inflammatory punctual stenosis monitored by anterior segment optical coherence tomography. *Int J Ophthalmol* 2020;13(7):1074-1078

INTRODUCTION

Although epiphora is a common complaint in oculo-plastic practice, punctual stenosis accounts only for 8% of its causes^[1]. The pathogenesis suggested is chronic inflammation of the external punctum leading to gradual fibrotic changes in the ostium, followed by progressive occlusion of the duct^[2-4].

Causes of punctual edema and stenosis can be either infectious or non-infectious. Inflammatory eyelid disorders like chronic blepharitis, ocular surface disease and systemic or topical medications specially after cataract and glaucoma surgery are the most common causes^[5-6]. Punctual stenosis can occur as an isolated disorder or be associated with canalicular or sub-canalicular stenosis, eyelid laxity, and/or malpositions^[5]. Different controlling paradigms were described for the treatment of acquired punctual stenosis. Repeated dilatation of the stenotic punctum is a simple procedure that may provide temporary improvement of the symptoms, but restenosis is common unless additional procedures are performed. Many other methods were used to augment punctual size including 1-snip, 2-snip, 3-snip punctoplasty, supplemented with adding sutures or Mini-Monoka insertion and punch punctoplasty^[7-9]. Most of these approaches show acceptable results, but still they carry the risk of complications especially restenosis^[8], as they

are not targeting the etiology or pathology of the stenosis. In the current study we focused on controlling the inflammatory nature of punctual stenosis by medical treatment and assessing its effect on resolving epiphora and improving punctum size by high resolution anterior segment optical coherence tomography (OCT).

SUBJECTS AND METHODS

Ethical Approval The study was conducted according to the tenets of Declaration of Helsinki and received the approval of the Research Ethical Committee of the Faculty of Medicine, Ain Shams University. All the patients signed a comprehensive written consent prior to participation in the study.

This prospective comparative study was conducted at the Ophthalmology Clinics of Ain Shams University Hospitals in the period between October 2017 to December 2018. It included 60 patients complaining of epiphora caused by inflammatory punctum stenosis within three months of the start of the complaint, and a group of 30 normal subjects for comparisons of pre-treatment anatomical data.

All patients had punctual stenosis classified as grade 2 according to Kashkouli *et al's*^[5] study being defined as just recognizable punctum of less than normal size^[4]. The lower punctum of one eye of each patient was included in the study. Exclusion criteria includes naso-lacrimal duct obstruction, mucocele, pyocele, congenital punctual agenesis, pediatric patients, glaucoma patients and history of surgical interference in lacrimal drainage system.

Patients were divided randomly into 2 groups. Group A: thirty patients that received a preservative free hydrocortisone sodium phosphate eye drops (Zoftacot 3.35 mg/mL eye drops, solution in single-dose container, marketing authorization number P A1107/013/001, France), 3 times daily for 1wk then 2 times daily for another week together with preservative free artificial tears (sodium hyaluronate, polyethylene and propylene glycol based) 3 times/d for 3mo. Group B: thirty patients who used the same type of preservative free artificial tears as in group A for 3mo as 3 times daily.

All patients were asked about history of epiphora, medical conditions, surgeries, topical and systemic drug intake. Patients had comprehensive anterior segment examination with slit lamp, measurement of intraocular pressure (IOP), fluorescein dye disappearance test for diagnosis and follow up once/month for the next 3mo. Spectral domain anterior segment-OCT was used to measure the outer punctum diameter (OPD) before and after treatment by 1 and 3mo. Qualitative evaluation of patients' satisfaction was measured by mini questionnaire of being satisfied, not satisfied or indifferent to treatment outcome after three months of using the eye drops.

Protocol of Image Acquisition by Spectral Domain Anterior Segment-OCT OCT image sets of the determined lower

lacrimal punctum were obtained by the same operator, using Spectralis OCT device, Retina Scan RS-3000 advance (NIDEK Co., Gamagori, Japan). We used a scan speed of 53 000 A-scan/second, high quality images (4 μ m OCT digital resolution) and real-time, high contrast, wide view (40°×30°) confocal scanning laser ophthalmoscope imaging that offers maximum accuracy for OCT scanning. A special anterior segment module was used. Each final single image comprises the average of a set of 2 to 10 automated real time B-scans.

The brightness was set to 25%, and the patient was asked to rest their foreheads against the head-rest with their chins placed on the chin-rest and the lower eyelid margin was everted using a cotton bud placed gently below the punctum to keep the anatomy undistorted and rolled to evert the punctum into a plane perpendicular to the light source. A vertical scan is used to measure the diameter of the outer punctum as the horizontal distance between the highest two points of the punctual papilla.

Statistical Analysis Statistical analysis was performed using the Microsoft Excel, and GraphPad InStat statistical programs. Numerical variables were presented as mean±standard deviation (SD) and intergroup differences between two variables were compared using the independent samples *t*-test. Within-group comparison of multiple variables was done using repeated measure ANOVA test, with post hoc analysis.

Categorical variables were presented as number (%) and in between group differences were compared using the Pearson Chi-squared test. All statistical tests were two-sided and statistical significance was targeted at a $P<0.05$.

RESULTS

The study included 60 eyes of 60 patients suffering from grade 2 inflammatory punctum stenosis^[4], 19 males and 41 females. The lower punctum of the more affected eye in each patient was included in the study. They were divided into two groups: group A (30 patients) treated with preservative free hydrocortisone sodium phosphate 3.35 mg/mL eye drops together with preservative free artificial tears, and group B (30 patients) treated with preservative free artificial tears only. Thirty normal subjects were included for pretreatment anatomical comparisons. There was no statistical difference in age between the two groups: 54.6±5.5y vs 56.8±6.8y respectively ($P=0.1668$).

The OPD was measured by Spectral domain anterior segment OCT before treatment then one and three months after starting the treatment. Means of punctum diameter before treatment in both groups were significantly lesser than that of the normal subjects' mean of 543±111 μ m (95%CI, 501.5-584.5 μ m; mean difference of -172.3 μ m for group A, and -155.2 μ m for group B, $P<0.0001$). The difference between the two groups was not statistically significant (mean difference of -17.2 μ m, $P=0.6244$; Table 1, Figures 1 and 2).

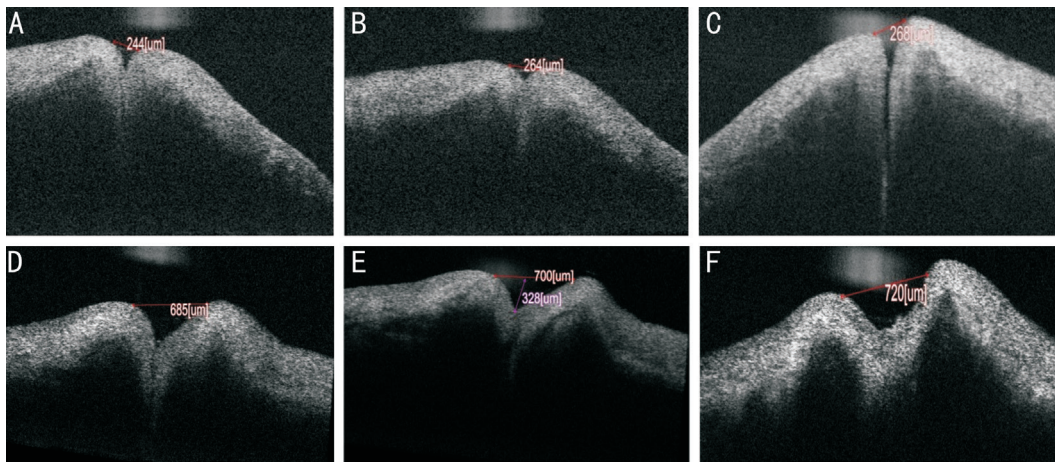


Figure 1 Group A Case 1 (A, B, C); case 2 (D, E, F): punctal diameter before treatment (A, D) with preservative free steroids, 1mo (B, E) and 3mo (C, F) after treatment.

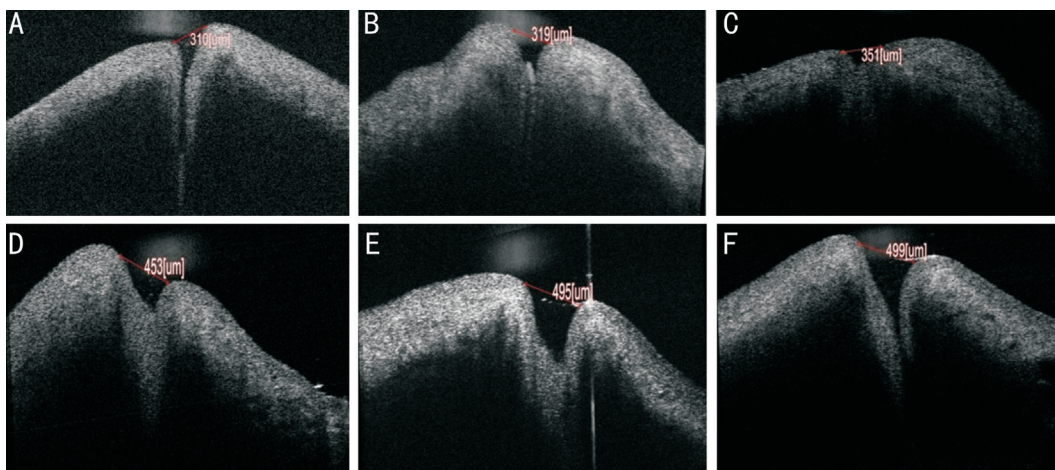


Figure 2 Group B Case 1 (A, B, C); case 2 (D, E, F): punctal diameter before treatment (A, D) with preservative free artificial tears, 1mo (B, E) and 3mo (C, F) after treatment.

Table 1 Average punctum size before and after treatment as measured by AS OCT

Groups	Pre-treatment	1mo post treatment	3mo post treatment	Average improvement	ANOVA test
Group A	370.67±114.21	414.77±115.88	430.23±114.32	59.6±49.4	<i>P</i> <0.0001
Group B	387.77±152.08	409.1±149.23	418.4±150.28	30.6±27.9	<i>P</i> <0.0001

Both groups improved significantly with treatment; (*P*<0.0001). Group A showed more improvement than group B (16.2% vs 8% increase in punctum size); the mean difference was 28.933 μm (*P*=0.0076; Table 1, Figure 3).

In group A: the improvement was statistically significant at the first follow up measure (mean of 44.1 μm, *P*<0.001), but not statistically significant between it and the third month follow up visit (mean of 15.467 μm, *P*>0.05).

The same was noted in group B: improvement was statistically significant at the first follow up measure (mean of 21.333 μm, *P*<0.001), but not statistically significant between it and the 3mo follow up visit (mean of 9.3 μm, *P*>0.05).

Subjective satisfaction with the treatment results was significantly different between the two groups as group A was more satisfied by the outcome (70% vs 40%, Chi-square *P*=0.0397; Figure 4).

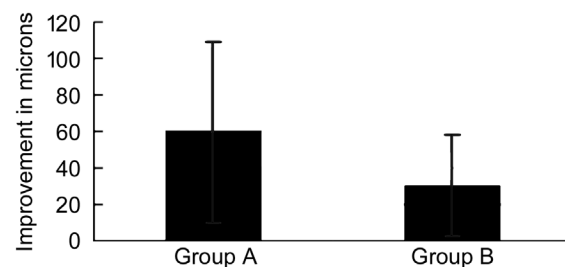


Figure 3 Mean of improvement of punctual size after treatment.

DISCUSSION

Punctal stenosis and epiphora are troublesome findings in ophthalmology. Whether the cause is functional or structural, surgical widening remains the main stay of managements. Although histopathological and electro-microscopical studies proved that all stenotic punctate had evidence of subepithelial and subconjunctival fibrosis, sever inflammation and strong immuno-

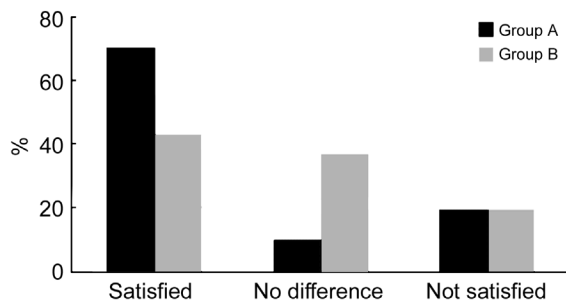


Figure 4 Patients' satisfaction after treatment.

reactivity^[2-4], the role of medical treatment of inflammatory punctual stenosis has not been fully investigated. Medical attempts to control punctual stenosis were mostly confined to adjuvant effect of mitomycin C in surgical procedures^[10], which can itself induce stenosis process^[11] or damage the lacrimal pump and cause canalicular redundancy by decreasing the collagen and elastin in its wall^[12]. The hypothesis of our study is to control subepithelial focal immuno-reactivity by medical treatment in the early inflammatory stages to stop the sequence of chronic inflammation, fibrosis and stenosis.

In our study we treated patients with grade 2 inflammatory punctual stenosis^[4] with either a combination of preservative free steroids and artificial tears or artificial tears only. We found the same risk factors mentioned in previous studies as old age and female gender^[4,13], where the mean age of patient's in our study was 56.8±6.8y and 68% of them were females. We used spectral domain anterior segment-OCT images for visualizing the lacrimal punctual structure *in vivo* and differentiating various causes of epiphora^[14]. Quantitative measurements help us to monitor disease prognosis and assess the efficacy of medical treatment. The mean of OPD of patients in our study was compared before treatment to that of thirty normal subjects who represent our own normative data because of lack of standard values of OPD in literature^[3] and the great variability in OCT based *in vivo* measurements^[14]. The mean OPD in normal subjects of our study was 543±111 μm, which is smaller than OPD in a Korean cohort 614.6±195.6 μm^[14], and a mix of Caucasian/Asian people 646±50^[15], while it was quite larger than that of Indian subjects 214.71±73 μm^[16], UK subjects 247±78 μm^[17], and even a different Egyptian sample 412±16 μm^[18]. This confirms the huge ethnic and individual variation in punctual size, effect of variable machines soft wares, the need of precise landmarks in measuring technique. It also emphasizes the necessity of presence of a control group for each individual study. Highlighted by this great diversity, it should be also noted that inflammatory punctual stenosis is a diagnosis of symptoms and signs rather than anatomical measurements.

Preservative induced inflammatory punctual congestion and stenosis is very common in patients with chronic eye conditions

receiving prolonged multidose therapy as in glaucoma^[19]. Avoidance of preserved eye drops decreases the damage of ocular surface from preservatives like benzalkonium chloride (BAK) which is a quaternary ammonium component that is almost present in all multidose eye drop formulas. Even at low concentrations, BAK induces a marked increase in the quantities of inflammatory cytokines such as interleukin-1, tumor necrosis factor α (TNFα) and C-reactive protein in human corneal epithelial cells that induces lysis of cell membranes and alters the permeability of the ocular surface epithelium. It is degraded into hydrogen peroxide (H₂O₂), which, in even amounts as low as 0.003%, is known to be an ophthalmic irritant and can cause oxidative damage to corneal and conjunctival epithelial cells^[20-21].

Preservative free artificial tears used in our study resulted in partial improvement of the congestion of the punctum and increase in mean diameter of 30.6±27.9 μm in group B. When absorbed, preservative free artificial tears dilute the burden of inflammatory mediators in the subepithelial conjunctival tissues and stops the ongoing edema and cicatrizing process. Their lubricant effect is further augmented by the anti-inflammatory action of preservative free steroids used in group A of our study where the average of widening of punctual diameter increased to 59.6±49.4 μm ($P<0.0001$), average difference of 28.933 μm from group B ($P=0.0076$), and patients' satisfaction increased from 40% to 70% (Chi-square $P=0.0397$).

The hydrocortisone sodium phosphate used in the current study exerts its anti-inflammatory effect in the sub-conjunctival tissues of the ocular surface by affecting the release of substances that modulate inflammation. It inhibits the synthesis and release of pro-inflammatory chemical mediators [such as eicosanoids, platelet activating factor (PAF), TNFα, and lipocortin]. It inhibits the enzyme phospholipase A2 responsible for conversion of phospholipids to arachidonic acid and thus prevent synthesis of prostaglandins, thromboxanes A and prostacyclins^[22]. It aborts the processes of inflammatory oedema, fibroblastic activity and cicatrization. It has lesser penetration to deep ocular tissues thus minimizing the potential hazards of steroids^[23].

In a ninety patients case series, Campagnoli *et al*^[19], identified thirteen patients with BAK preservative-related punctual congestion, stenosis and epiphora secondary to treatment of chronic conjunctivitis. They managed 69% of their patients with non-preserved loteprednol etabonate 0.5% ointment after cessation of all preserved eye drops and reported partial relief of symptoms after 1.6mo which is a little bit delayed than the improvement in our study where maximum improvement occurred in first month and continued to improve till the last follow up after three months, although this further

improvement difference was not significant in the two groups ($P>0.05$).

Control of inflammation in its early stages by medical treatment prevents progression of fibrosis and establishing the stenosis. This saves the patients from undergoing surgeries for widening the punctum, that, although mostly successful, carries the risk of restenosis during the healing process^[8].

Although the patients that improved in our study continued to show some improvement till the three months follow up visit and neither of them deteriorated, we wished to have longer periods of follow up. We also treated patients within three months of the start of their complaint, next studies are recommended to include patients with longer durations of inflammatory stenosis and epiphora.

In conclusion, management of inflammatory punctual stenosis by preservative free hydrocortisone and artificial tears is an effective, symptom relieving treatment, especially if the patient is diagnosed early. Spectral domain anterior segment-OCT is a very helpful and conclusive tool in diagnosing punctual stenosis and monitoring different treatment outcomes.

ACKNOWLEDGEMENTS

Conflicts of Interest: Elalfy HY, None; Elsamkary MA, None; Elridy AMS, None; Saad TM, None; Rashad SM, None; Fawzy SM, None.

REFERENCES

- 1 Mainville N, Jordan DR. Etiology of tearing: a retrospective analysis of referrals to a tertiary care oculoplastics practice. *Ophthalmic Plast Reconstr Surg* 2011;27(3):155-157.
- 2 Reddy AK, Baker MS, Maltry AC, Syed NA, Allen RC. Immunopathology and histopathology of conjunctival biopsies in patients with presumed idiopathic punctal stenosis. *Br J Ophthalmol* 2017;101(2):213-217.
- 3 Port AD, Chen YT, Lelli GJ Jr. Histopathologic changes in punctual stenosis. *Ophthalmic Plast Reconstr Surg* 2013;29(3):201-204.
- 4 Ali MJ, Mishra DK, Baig F, Lakshman M, Naik MN. Punctual stenosis: histopathology, immunology, and electron microscopic features-a step toward unraveling the mysterious etiopathogenesis. *Ophthalmic Plast Reconstr Surg* 2015;31(2):98-102.
- 5 Kashkouli MB, Beigi B, Murthy R, Astbury N. Acquired external punctual stenosis: etiology and associated findings. *Am J Ophthalmol* 2003;136(6):1079-1084.
- 6 Weston BC, Loveless JW. Canalicular stenosis due to topical use of fortified antibiotics. *Can J Ophthalmol* 2000;35(6):334-335.
- 7 Kashkouli MB, Beigi B, Astbury N. Acquired external punctual stenosis: surgical management and long-term follow-up. *Orbit* 2005;24(2):73-78.
- 8 Bukhari AA. Management options of acquired punctual stenosis. *Saudi Med J* 2013;34(8):785-792.
- 9 Park SJ, Noh JH, Park KB, Jang SY, Lee JW. A novel surgical technique for punctual stenosis: placement of three interrupted sutures after rectangular three-snip punctoplasty. *BMC Ophthalmol* 2018;18(1):70.
- 10 Ma'luf RN, Hamush NG, Awwad ST, Nouredin BN. Mitomycin C as adjunct therapy in correcting punctual stenosis. *Ophthalmic Plast Reconstr Surg* 2002;18(4):285-288.
- 11 Kopp ED, Seregard S. Epiphora as a side effect of topical mitomycin C. *Br J Ophthalmol* 2004;88(11):1422-1424.
- 12 Billing K, Karagiannis A, Selva D. Punctual-canalicular stenosis associated with mitomycin-C for corneal epithelial dysplasia. *Am J Ophthalmol* 2003;136(4):746-747.
- 13 Soiberman U, Kakizaki H, Selva D, Leibovitch I. Punctual stenosis: definition, diagnosis, and treatment. *Clin Ophthalmol* 2012;6:1011-1018.
- 14 Sung Y, Park JS, Lew H. Measurement of lacrimal punctum using spectralis domain anterior optical coherence tomography. *Acta Ophthalmol* 2017;95(7):e619-e624.
- 15 Timlin HM, Keane PA, Day AC, Salam T, Abdullah M, Rose GE, Ezra DG. Characterizing the lacrimal punctal region using anterior segment optical coherence tomography. *Acta Ophthalmol* 2016;94(2):154-159.
- 16 Kamal S, Ali MJ, Ali MH, Naik MN. Fourier domain optical coherence tomography with 3D and en face imaging of the punctum and vertical canaliculus: a step toward establishing a normative database. *Ophthalmic Plast Reconstr Surg* 2016;32(3):170-173.
- 17 Wawrzynski JR, Smith J, Sharma A, Saleh GM. Optical coherence tomography imaging of the proximal lacrimal system. *Orbit* 2014;33(6):428-432.
- 18 Allam RS, Ahmed RA. Evaluation of the lower punctum parameters and morphology using spectral domain anterior segment optical coherence tomography. *J Ophthalmol* 2015;2015:591845.
- 19 Campagnoli T, et al. Presumed preservative-related punctual congestion. Presented at: Association for Research in Vision and Ophthalmology annual meeting; May 7-11, 2017; Baltimore.
- 20 Cha SH, Lee JS, Oum BS, Kim CD. Corneal epithelial cellular dysfunction from benzalkonium chloride (BAC) *in vitro*. *Clin Exp Ophthalmol* 2004;32(2):180-184.
- 21 Ohia SE, Opere CA, Leday AM. Pharmacological consequences of oxidative stress in ocular tissues. *Mutat Res* 2005;579(1-2):22-36.
- 22 Abelson MB, Butrus S. Corticosteroids in ophthalmic practice. Albert Jakobiec's Principles Practice of Ophthalmology. Elsevier 2008:249-258.
- 23 Friedman NJ, Kaiser PK. Ocular pharmacology. Essentials of Ophthalmology. Elsevier 2007:25-32.