

Featuring the Nd:YAG laser capsulotomy in the operating room

Veronique Promelle, Sharon Armarnik, Christopher J Lyons

Department of Ophthalmology and Visual Sciences, University of British Columbia, Vancouver V5Z 3N9, Canada

Correspondence to: Veronique Promelle. Department of Ophthalmology and Visual Sciences, University of British Columbia, Vancouver V5Z 3N9, Canada. veronique.promelle@cw.bc.ca

Received: 2019-07-16 Accepted: 2019-11-11

DOI:10.18240/ijo.2020.03.25

Citation: Promelle V, Armarnik S, Lyons CJ. Featuring the Nd:YAG laser capsulotomy in the operating room. *Int J Ophthalmol* 2020;13(3):523-524

Dear Editor,

We read with interest the article of Kinori *et al*^[1] titled 'Pediatric Nd:YAG laser capsulotomy in the operating room: review of 87 cases'. Facilities for laser capsulotomy under general anesthesia are essential for young children and uncooperative patients undergoing cataract surgery. The alternative, secondary surgical capsulotomy with anterior vitrectomy is needlessly invasive and potentially complicated when compared to the quick and safe laser capsulotomy procedure. Dedicated Nd:YAG lasers for this purpose are costly whereas slit-lamp-mounted Nd:YAG lasers are ubiquitous in ophthalmology offices, usually set on mobile height-adjustable tables. Our technique is similar but even simpler. Like Kinori *et al*^[1], we have also found that bringing the office laser into the operating room to be most cost-effective.

The lateral decubitus position they describe is simple and safe when compared to the previously described prone^[2] or sitting^[3-4] positions but we have preferred to position our anesthetized patients supine in dorsal decubitus, secured with straps, with the head turned towards the side of the lasered eye. The operating table is then elevated to its highest position. The chin rest of the laser table is removed and the slit-lamp is positioned under the table to treat the lower eye (Figure 1). The capsulotomy is then performed in the usual way. For bilateral cases, the head of the patient is gently turned to the other side and the laser is moved to that side of the table to perform an

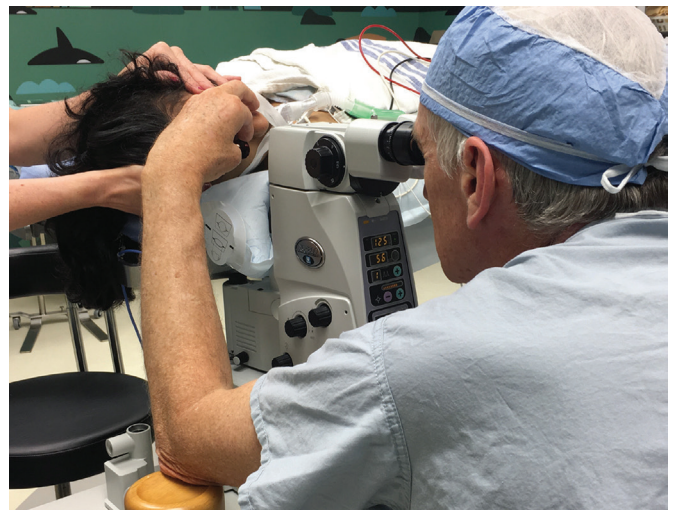


Figure 1 The patient is positioned in dorsal decubitus, head turned towards the side of the treated eye. The operating table is elevated to its highest position, the chin rest of the laser table is removed and the laser is positioned to treat the lower eye.

identical procedure. In our experience, capsular opening has always been achieved without complication.

Compared to the lateral decubitus position, this technique requires minimal manipulation of the patient. The patient and laser positioning are quicker and bilateral treatment is straightforward. The procedure time is approximately 15 to 20min. Although our patients have not experienced any cervical complications, the lateral decubitus position may be preferable for patients with neck instability such as patients with Down syndrome who are prone to atlanto-axial luxation^[5], in whom head and neck must be manipulated with caution.

In conclusion, we agree that adjusting the office slit lamp-based laser for treatment of the supine anesthetized patient is easy and safe. We highlight the differences of our technique which we have used safely for well over 100 children without complication. It has many advantages, requiring minimal patient manipulation, a very short operating time, and avoids the need to purchase expensive and rarely-used dedicated equipment.

ACKNOWLEDGEMENTS

Conflicts of Interest: Promelle V, None; Armarnik S, None; Lyons CJ, None.

REFERENCES

- 1 Kinori M, Jagannathan N, Langguth AM, Sasso MA, Mets MB, Rahmani B, Yoon H, Mets-Halgrimson R, Kurup SP, Zeid JL. Pediatric Nd:YAG laser capsulotomy in the operating room: review of 87 cases. *Int J Ophthalmol* 2019;12(5):779-783.
- 2 Subash M, Horgan SE. Nd:YAG laser capsulotomy in the prone position under general anesthesia. *Ophthalmic Surg Lasers Imaging* 2008;39(3):257-259.
- 3 Longmuir S, Titler S, Johnson T, Kitzmann A. Nd:YAG laser capsulotomy under general anesthesia in the sitting position. *J AAPOS* 2013;17(4):417-419.
- 4 Winter A, DeKoven K, Superstein R, Hamel P. Nd:YAG laser capsulotomy under general anesthesia in the sitting position. *J AAPOS* 2014;18(2):208.
- 5 Bertolizio G, Saint-Martin C, Ingelmo P. Cervical instability in patients with Trisomy 21: the eternal gamble. *Paediatr Anaesth* 2018;28(10):830-833.