

# Long-term effects of pattern scan laser pan-retinal photocoagulation on diabetic retinopathy in Chinese patients: a retrospective study

Chuang-Xin Huang, Kun-Bei Lai, Li-Jun Zhou, Zhen Tian, Xiao-Jing Zhong, Fa-Bao Xu, Ya-Jun Gong, Lin Lu, Chen-Jin Jin

State Key Laboratory of Ophthalmology, Zhongshan Ophthalmic Center, Sun Yat-sen University, Guangzhou 510060, Guangdong Province, China

**Co-first authors:** Chuang-Xin Huang and Kun-Bei Lai

**Correspondence to:** Chen-Jin Jin. State Key Laboratory of Ophthalmology, Zhongshan Ophthalmic Center, Sun Yat-sen University, 54# Xianlien Road, Yuexiu District, Guangzhou 510060, Guangdong Province, China. jinchi@mail.sysu.edu.cn

Received: 2019-03-24 Accepted: 2019-04-19

## Abstract

• **AIM:** To evaluate the long-term effects of pattern scan laser (PASCAL) pan-retinal photocoagulation (PRP) on diabetic retinopathy (DR) in Chinese patients.

• **METHODS:** In this retrospective study, we evaluated clinical data of 29 patients (53 eyes) with severe non-proliferative DR (SNPDR) or proliferative DR (PDR) who received PRP and follow-up at our hospital from 2008 to 2013. Sixteen patients (29 eyes) received PASCAL PRP and 13 patients (24 eyes) received 100-ms conventional laser PRP.

• **RESULTS:** After long-term follow-up (mean, min-max days: 719.8, 290-1666 for PASCAL PRP vs 743.5, 240-1348 for conventional PRP,  $P=0.569$ ), patients receiving PASCAL PRP required fewer photocoagulation sessions than the conventional PRP group ( $2.6\pm 1.0$  vs  $3.9\pm 0.9$ ,  $P<0.01$ ). Best corrected visual acuity (BCVA) was reduced slightly in PASCAL PRP group while reduced significantly in conventional PRP group. At last visit, 24 eyes in the PASCAL group (88.9%) and 21 eyes in the conventional group (91.7%) were improved or stable. Two eyes in PASCAL PRP group (7.4%) and 3 eyes in the conventional PRP group (12.5%) developed vitreous hemorrhage or vitreous fibrovascular proliferation.

• **CONCLUSION:** PASCAL PRP is as effective and may be more conducive to maintaining visual acuity with less treatment sessions for DR treatment compared to conventional laser PRP.

• **KEYWORDS:** proliferative diabetic retinopathy; severe non-proliferative diabetic retinopathy; pattern scan laser; pan-retinal photocoagulation; clinical effect

**DOI:10.18240/ijo.2020.02.06**

**Citation:** Huang CX, Lai KB, Zhou LJ, Tian Z, Zhong XJ, Xu FB, Gong YJ, Lu L, Jin CJ. Long-term effects of pattern scan laser pan-retinal photocoagulation on diabetic retinopathy in Chinese patients: a retrospective study. *Int J Ophthalmol* 2020;13(2):239-245

## INTRODUCTION

Diabetic retinopathy (DR), a chronic retinal vascular disease associated with long-term hyperglycemia, is the main cause of blindness in working-age adults. DR can develop from non-proliferative diabetic retinopathy (NPDR) with microvascular disorders such as exudates or microaneurysm but no neovascularization (NV), to proliferative diabetic retinopathy (PDR) manifested by retinal NV, preretinal hemorrhage or vitreous hemorrhage (VH). NPDR reaching 4-2-1 rule by DRS and ETDRS criteria was considered as severe NPDR (SNPDR) and may progress to PDR soon, which could finally impair the vision markedly if uncontrolled<sup>[1-2]</sup>. Therefore, early detection and treatment is essential. Pan-retinal photocoagulation (PRP) is the standard treatment and widely applied for SNPDR and PDR before severe VH, tractive retinal detachment or secondary neovascular glaucoma occurs, and can substantially reduce the risk of vision loss<sup>[3-7]</sup>. However, 100ms conventional PRP causes inevitable destruction of the fundus, leading to side effects such as aggravated macular edema during the early stage after photocoagulation, long-term narrowing of the visual field, impaired dark vision, and decreased visual acuity<sup>[8-10]</sup>.

Pattern scan laser (PASCAL) photocoagulation is a relatively new modality for ocular treatment that uses short exposure times (10-20ms for macular area, 20-30ms for PRP), and lower laser energy density compared to conventional photocoagulation. PASCAL may reduce each treatment time, improve efficiency of PRP, and induce less damage to the peripapillary retinal nerve fiber layer and macular retinal nerve fiber layer than 100-ms conventional laser PRP<sup>[11-14]</sup>. The Manchester PASCAL study found that the NV regression rate after a single PASCAL PRP session was higher at 3mo

compared to 100-ms conventional laser exposure, while a follow-up retrospective report also found that PASCAL PRP was effective for control of PDR progression in most eyes at about 18mo after treatment<sup>[15-16]</sup>.

According to recent epidemiological surveys, the overall prevalence of diabetes in China may reach 10.9%-11.6%, with 20.2% in people above 60 years old<sup>[17-18]</sup>. Due to the huge Chinese population and rapidly growing number of diabetes patients, DR morbidity is increasing yearly. Therefore, the wider use of PASCAL laser as a relatively rapid treatment mode may be particularly advantageous in China. However, few studies have directly compared PASCAL to conventional laser treatment in Chinese DR patients. Moreover, follow-up in such studies has been relatively brief. Therefore, we reviewed the clinical data from DR patients treated by PASCAL laser or conventional laser in our hospital and subsequently followed-up for at least 6mo to several years. These findings may be useful for ophthalmologists when considering DR treatment with PASCAL or conventional lasers.

## SUBJECTS AND METHODS

**Ethical Approval** This retrospective analysis was approved by the Ethics Committee of the Zhongshan Ophthalmic Center. Informed consent was obtained from all patients.

**Patient Information** All data were derived from the clinical records archived during our previous clinical works. Patients who met the following criteria were included: 1) age greater than 18y; 2) newly diagnosed SNPDR or PDR according to ETDRS criteria at baseline; 3) underwent PRP with PASCAL or conventional laser subsequently; 4) follow-up for at least 6mo. Exclusion criteria were as followed: 1) conditions affecting visual acuity or retinal evaluation results, such as corneal diseases, severe cataract, glaucoma, other retinal vascular diseases, optic diseases and macular diseases; 2) PDR with VH affecting laser photocoagulation, tractive retinal detachment or neovascular glaucoma; 3) previously treated with PRP or vitreous surgery. Diabetic macular edema was not the exclusion criterion in this study. A total of 29 patients (53 eyes) with SNPDR or PDR who underwent laser treatment and were followed up from 2009 to 2013 at Zhongshan Ophthalmic Center were included. Clinical data, including DR grade, treatment history, best corrected visual acuity (BCVA), intraocular pressure (IOP), slit lamp examination results of anterior and posterior segments, fundus images and fundus fluorescein angiography (FFA), were compared between PASCAL and conventional laser treatment groups.

**Treatment Information** A pattern scan laser (Topcon, Japan) was applied for PASCAL PRP treatment, and a 532-nm frequency doubled Nd:YAG laser (Carl Zeiss, Germany) was used for conventional treatment. The PASCAL PRP parameters were 200  $\mu$ m spot size, 20-30ms pulse duration, and power

adjusted from 300 to 1000 mW until a gray-white lesion was observed. With the PASCAL, a 4×4 or 3×3 box pattern was used based on patient condition. Most complete PRP treatments were performed in two sessions, and the total spot number could reach 2500 to more than 3000. The following settings were used for conventional laser treatment: 200  $\mu$ m spot size, 100ms pulse duration, and power increased from 150 mW until a gray-white lesion was attained. Burns were placed one burn width apart. Patients received at least three PRP treatment sessions, and the total laser spot number was about 1500<sup>[19-20]</sup>.

Focal and/or grid photocoagulation was applied for macular edema, with 60-100  $\mu$ m spot size, 10-20ms pulse duration in PASCAL group, and 50-100  $\mu$ m spot size, 100ms pulse duration in conventional group. Greyish lesions were attained in both groups.

**Assessment of Diabetic Retinopathy Progress** The therapeutic effects of laser treatment on DR at last follow-up were classified into four levels: improved, stable, progressed, and deteriorated. "Improved" means reduction of retinal exudation or bleeding, decreased microaneurysm number, partial or complete neovascular regression, and FFA showing that most of the non-perfusion area is covered by laser spots. "Stable" means retinal conditions were generally as baseline, including exudation, bleeding, and non-perfusion area. Patients with DR progression during the treatment, such as VH or vitreous body proliferation, which was controlled before last visit were considered stable. "Progressed" means increased retinal exudation or bleeding, expansion of NV area, or the appearance of VH or vitreous body proliferation. "Deteriorated" means severe VH or vitreous body proliferation requiring pars plana vitrectomy (PPV).

**Proliferative Diabetic Retinopathy Reduction and Progression** The therapeutic effects of laser treatment on PDR at last follow-up were judged according to medical records. The retinal condition was analyzed by FFA results or careful ocular observation. The incidence of complete regression of NV was compared between groups.

**Statistical Analysis** All statistical analyses were performed using the SPSS 16.0 software package. Group means were compared by independent samples *t*-tests. Baseline BCVA was compared to last-visit BCVA within groups using dependent samples *t*-tests. Chi-square test and Fisher's exact test were used to compare non-parametric data or proportions between groups. A *P* value of less than 0.05 (two-tailed) was considered significant for all tests.

## RESULTS

**Patient Characteristics** A total of 29 patients (53 eyes) with SNPDR or PDR were included in this study. Among them, 16 patients (29 eyes) treated with PASCAL PRP were included

**Table 1 Patient characteristics in both treatment groups**

Items	PASCAL	Conventional	<i>n</i> (%)
Patients	16 (100)	13 (100)	0.143
Female	12 (75.0)	6 (46.2)	
Male	4 (25.0)	7 (53.8)	
Age, mean±SD (y)	55.5±9.8	50.7±14.1	0.289
DM duration, mean±SD (y)	10.5±5.7	10.2±5.8	0.458
Follow-up (d), mean, median, min-max	719.8, 583, 290-1666	743.5, 833, 240-1348	0.569
HbA1c, mean±SD (%)	7.53±2.32	8.23±2.43	0.570
Eyes	29 (100)	24 (100)	0.785
OD	15 (51.7)	11 (45.8)	
OS	14 (48.3)	13 (54.2)	
DR grade	29 (100)	24 (100)	0.574
SNPDR	10 (34.5)	11 (45.8)	
PDR	19 (65.5)	13 (54.2)	
Macular status	29 (100)	24 (100)	0.389
DME	13 (44.8)	12 (50.0)	
Non-DME	14 (48.3)	8 (33.3)	
Undefined	2 (6.9)	4 (16.7)	

PASCAL: Pattern scan laser; DM: Diabetes mellitus; DR: Diabetic retinopathy; PDR: Proliferative diabetic retinopathy; SNPDR: Severe non-proliferative diabetic retinopathy; DME: Diabetic macular edema. <sup>a</sup>Comparison between PASCAL group and conventional group.

as the PASCAL PRP group and 13 patients (24 eyes) treated with conventional laser PRP were included as the conventional PRP group. Nine patients in PASCAL group and seven in conventional group received serum glycosylated hemoglobin level (HbA1c) examination.

The overall conditions between the two groups were similar. No difference was found in eye, age, diabetes duration, serum HbA1c and follow-up time between the two groups. Sex proportions were slightly different but not significant between two treatment groups. Similarly, the proportions of SNPDR and PDR cases, and the macular edema status did not differ between groups (Table 1).

**Photocoagulation Sessions** In the PASCAL PRP group, most patients received 2 sessions of laser photocoagulation as complete PRP treatment, while some received 1 or 3 sessions according to condition. In the conventional laser photocoagulation group, all patients received at least 3 laser photocoagulation sessions as complete PRP treatment. In both groups, additional laser photocoagulation was administered during the follow-up if active DR was detected. Patients in the PASCAL group received significantly fewer total photocoagulation sessions than patients in the conventional laser photocoagulation group (Table 2, Figure 1A).

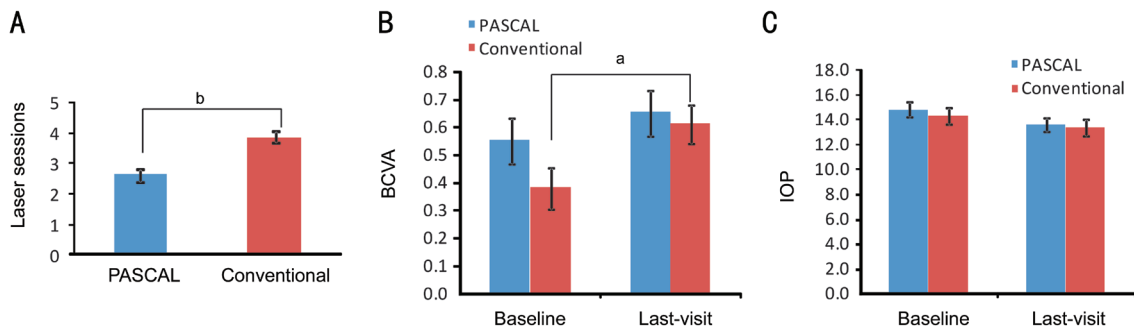
#### Therapeutic Results

**Vision and intraocular pressure** Neither baseline nor last-visit BCVA logMAR value differed significantly between

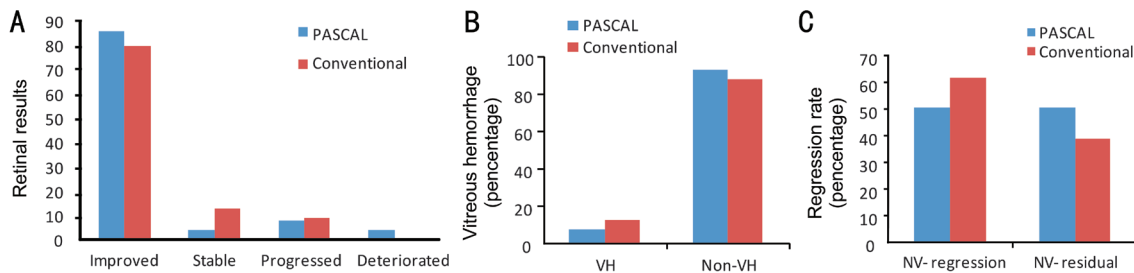
the PASCAL PRP and conventional PRP groups (Table 2, Figure 1B). Both groups demonstrated a modest increase from baseline to last follow-up, indicating slightly reduced visual acuity. However, significant difference was found in conventional groups but not PASCAL group. Similarly, neither baseline nor last-visit IOP differed between groups (Table 2, Figure 1C).

**Progression and complications** One patient (2 eyes, 1 SNPDR, 1 PDR) in the PASCAL PRP group was not included in the retinal outcome results because last visit retinal records were missing. In both groups, the majority of eyes were judged as improved, and there were no significant differences in the proportions of improved, stable, progressed, and deteriorated eyes (Table 3, Figures 2-4). For VH, eyes including SNPDR and PDR cases were counted, and for NV outcomes, only eyes of PDR were counted. In the PASCAL PRP group, 2 eyes (7.4%) exhibited VH or vitreous proliferation (indicating old VH) at last visit. The eye with VH was treated with PPV surgery. In the conventional laser group, 3 eyes (12.5%) exhibited mild VH but no vitreous surgery was needed (Table 3, Figures 2-4). No significant differences were found between PASCAL group and conventional group when comparing the retinal outcomes, including VH complicated or NV outcomes respectively.

**Neovascularization regression rate in proliferative diabetic retinopathy eyes** NV regression rates in both treatment



**Figure 1 Laser sessions, vision and IOP during the long-term follow-up in both treatment groups** A: Significantly fewer laser treatment sessions were required using PASCAL PRP compared to conventional PRP; <sup>b</sup>*P*<0.01; B: BCVA expressed as logMAR value from baseline to last visit in PASCAL and conventional PRP treatment groups; <sup>a</sup>*P*<0.05; C: IOP from baseline to last visit in PASCAL and conventional PRP treatment groups.



**Figure 2 Retinal outcomes at last follow-up for PASCAL and conventional PRP treatment groups** A: The distribution of improved, stable, progressed, and deteriorated cases did not differ between treatment groups; B: The frequency of VH did not differ between groups; C: The regression rate of NV did not differ between groups.

**Table 2 Laser sessions, vision and IOP during the follow up in both treatment groups**

Items	PASCAL	Conventional	mean±SD	<i>P</i> <sup>a</sup>
Laser sessions ( <i>n</i> )	2.6±1.0	3.9±0.9		<0.001
BCVA (logMAR)				
Baseline	0.55±0.43	0.38±0.35		0.135
Last-visit	0.65±0.44	0.61±0.34 <sup>b</sup>		0.745
IOP (mm Hg)				
Baseline	14.8±2.8	14.3±2.6		0.615
Last-visit	13.6±2.7	13.4±3.1		0.858

BCVA: Best corrected visual acuity; IOP: Intraocular pressure.  
<sup>a</sup>Comparison between PASCAL group and conventional group;  
<sup>b</sup>*P*<0.05, last-visit BCVA vs baseline BCVA in conventional group by paired *t*-test.

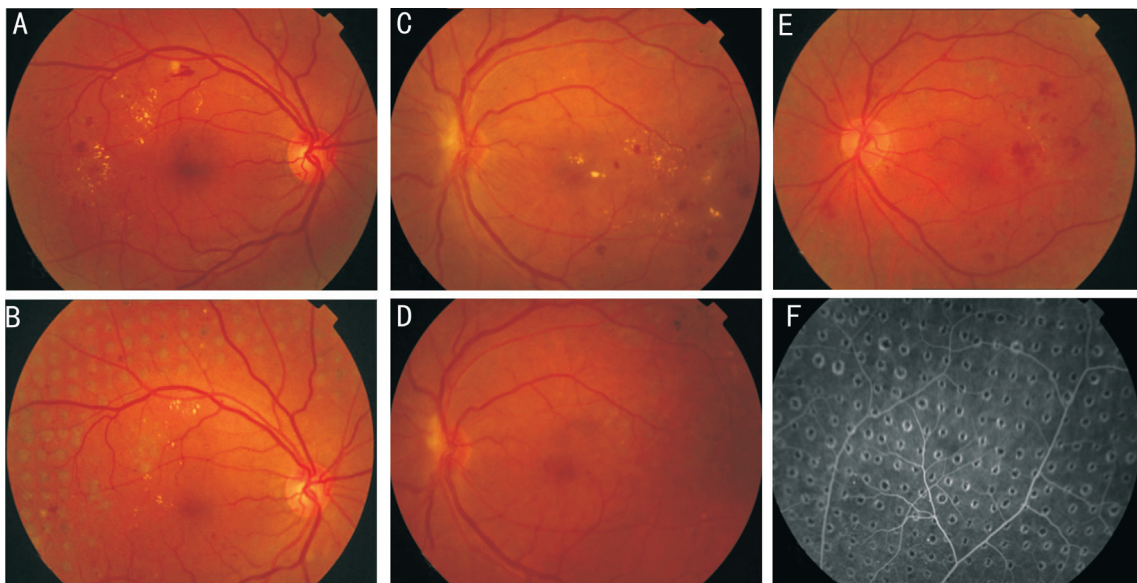
**Table 3 DR outcomes in both PRP treatment groups at last visit**

Items	PASCAL	Conventional	<i>n</i> (%)	<i>P</i> <sup>a</sup>
Retinal outcomes	27(100)	24(100)		0.670
Improved	23 (85.2)	19 (79.2)		
Stable	1 (3.7)	3 (12.5)		
Progressed	2 (7.4)	2 (8.3)		
Deteriorated	1 (3.7)	0 (0)		
VH complicated	27 (100)	24 (100)		0.656
VH	2 (7.4)	3 (12.5)		
Non-VH	25 (92.6)	21 (87.5)		
NV outcomes (PDR only)	18	13		0.717
NV-regression	9 (50)	8 (61.5)		
NV-residual	9 (50)	5 (38.5)		

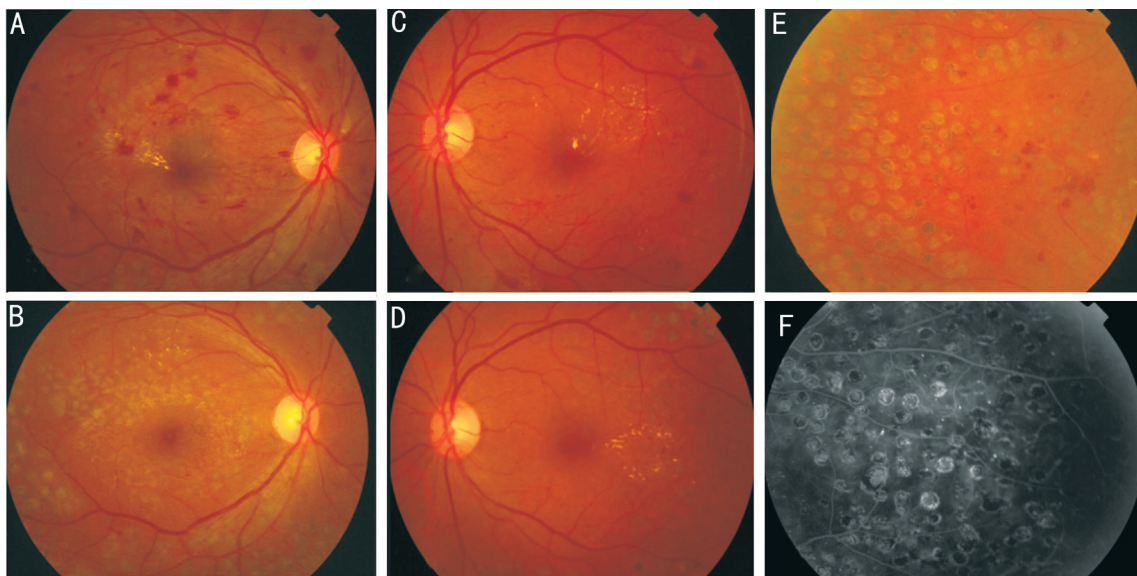
VH: Vitreous hemorrhage; NV: Neovascularization. <sup>a</sup>Comparison between PASCAL group and conventional group.

**DISCUSSION**

PASCAL PRP has been applied for the treatment of DR since 2008<sup>[15-16,21-23]</sup>. In our hospital, we use 20-30ms stimulation, 200 μm spot size, 0.75-1.0 spot spacing, gray-white reaction, and about 2500 points per eye for complete PASCAL PRP, similar to previous reports from other institutions. During follow-up, if signs of progression or active DR were found, such as residual non-perfusion area or NV, additional laser photocoagulation



**Figure 3 Different retinal conditions after PASCAL PRP treatment** A: Before treatment for SNPDR; B: After treatment for SNPDR, regular laser spots were visible, and exudation was decreased; C: Before treatment for PDR; D: After treatment for PDR, exudation and bleeding in the posterior area was absorbed; E: After treatment for PDR, residual NV and bleeding was observed; F: FFA results showed regular PASCAL laser spots.



**Figure 4 Different retinal conditions after conventional laser PRP treatment** A: Before treatment for SNPDR; B: After treatment for SNPDR, bleeding spots, microaneurysm, and exudation in the posterior area were mostly absorbed; C: Before treatment for PDR, bleeding spots, microaneurysm, and exudation in the posterior area were observed; D: After treatment, bleeding and microaneurysm disappeared; slight exudation was found; E: After treatment for PDR, disordered laser spots with residual NV and bleeding were found; F: FFA results showed disordered laser spots and small residual non-perfusion area.

was performed. Our study indicated that although most DR patients required additional laser photocoagulation during the follow up, PASCAL PRP improved the whole treatment efficiency with less total laser sessions than conventional laser. In this present study, baseline BCVA logMAR did not differ between PASCAL PRP and conventional laser PRP treatment. The logMAR value indicated lower visual acuity at last follow-up in the conventional group, while acuity was slightly

more stable in the PASCAL group. BCVA mainly reflects the function of the macula fovea. Conventional laser PRP could induce vision decreased and increase macular thickness from 3 to 24mo after treatment<sup>[24]</sup>. However, PASCAL laser may induce transient macular change at 4wk after treatment which was restored at 3mo, and maintained stable vision at 18mo after PRP compared to pre-treatment<sup>[15-16]</sup>. Further, PASCAL laser did not change macular perfusion in PDR

eyes, and significantly attenuated partial vision damage using electroretinogram evaluation compared to conventional PRP<sup>[25-26]</sup>. The mechanism maybe because that PASCAL laser causes less damage to the retina by using shorter laser exposure which mainly focuses on retinal pigment epithelium and photoreceptors, inducing fewer inflammatory cytokines such as interleukin-6 and monocyte chemoattractant protein-1 and vascular endothelial growth factor compared to conventional laser, and thus reduces the effects on macular area<sup>[27]</sup>. In this study, the baseline macular edema was similar between two groups. Although the effect of PRP or focal/grid photocoagulation on macular edema was not assessed because only a few patients had the macular thickness results. Our present vision results were similar to the previously reported, suggesting moderate stabilization of foveal function by PASCAL PRP.

Retinal condition was improved or stable in most eyes of both treatment groups (improved and stable, 24 eyes, 88.9% in PASCAL group; 22 eyes, 91.7% in conventional group), although 3 eyes in the PASCAL PRP group (11.1%) and 2 in the conventional group (8.3%) progressed or deteriorated after treatment. In addition, a substantial fraction of both groups demonstrated complete regression of PDR NV (50% in the PASCAL PRP group and 61.5% in the conventional laser PRP group). These results confirmed that PASCAL PRP is as effective for most DR eyes as conventional PRP, although it might have a slightly weaker long-term inhibitory effect on PDR NV. At present, there are still disputes regarding the best treatment mode for PDR and the optimal PASCAL settings. Muqit *et al*<sup>[16]</sup> retrospectively analyzed a total of 22 patients (36 eyes) at 18mo after PRP treatment, which showed that in mild, moderate and severe PDR, the PDR reduction rate was 75%, 67% and 43%, with average number of laser spots and laser dosimetry significant increased to achieve complete regression with worsening PDR. Chappelow *et al*<sup>[28]</sup> found that PASCAL using conventional laser settings was less effective than conventional argon laser PRP for lasting regression of retinal NV in previously untreated high-risk PDR patients. Yamakawa *et al*<sup>[29]</sup> found that patients treated by PASCAL PRP exhibited a much higher average number of laser spots (4195) than a conventional laser group, although there were no significant differences in complications and efficacy for prevention of visual loss and central retinal thickening<sup>[29]</sup>. Collectively, our findings and previously published articles suggest that PASCAL PRP has definite efficacy for the treatment of PDR, but that laser parameters need to be optimized for different patients and retinal conditions.

PASCAL PRP has been applied for the treatment of various retinal vascular diseases, such as retinal vein occlusion and DR; however, there were few long-term follow-up results

reported. In this study, the long-term follow-up results showed that 20-30ms PASCAL PRP has an acceptable therapeutic effect in DR patients. PASCAL PRP requires a shorter time for single treatment and fewer treatment sessions than conventional laser PRP. Therefore, we believe that it could be widely applied for DR treatment. For the treatment of PDR, PASCAL PRP might have a slightly weaker long-term therapeutic effect than conventional laser PRP, but this issue also requires further investigation.

Limitations of this study include the retrospective design, which precludes conclusions on causation, and the relatively small sample size. This small sample size is due to frequent comorbidity in DR, which increases the rate of loss during follow-up. Meanwhile, optical coherence tomography results for assessment of macular edema, and visual functional measurement such as perimetry, multifocal-electroretinography, and contrast sensitivity were lack in this study based on the present clinical records. These evaluation methods are very important and should be investigated in the future. Although we found several differences in outcome between PASCAL and conventional laser PRP treatment groups, most did not reach statistical significance due to the small sample size. Therefore, larger-scale prospective studies with more evaluation methods are required to provide more solid evidence on the relative efficacy and safety of PASCAL PRP compared to conventional laser PRP. Further, we must still identify optimal parameters for best PDR treatment outcome.

#### ACKNOWLEDGEMENTS

**Foundations:** Supported by National Natural Science Foundation of China (No.81670866); Sun Yat-Sen University Clinical Research 5010 Project (No.2013007).

**Conflicts of Interest:** Huang CX, None; Lai KB, None; Zhou LJ, None; Tian Z, None; Zhong XJ, None; Xu FB, None; Gong YJ, None; Lu L, None; Jin CJ, None.

#### REFERENCES

- 1 The Diabetic Retinopathy Study Research Group. A modification of the Airlie House classification of diabetic retinopathy. DRS report number 7. *Invest Ophthalmol Vis Sci* 1981; 21(1 Pt 2):210-226.
- 2 Grading diabetic retinopathy from stereoscopic color fundus photographs: an extension of the modified airle house classification ETDRS report number 10. *Ophthalmology* 1991;98(5):786-806.
- 3 Stenkula S. Photocoagulation in diabetic retinopathy. A multicentre study in Sweden. *Acta Ophthalmol Suppl* 1984;162:1-100.
- 4 Fenwick EK, Lamoureux EL. Effect of pan-retinal photocoagulation treatment on vision-related quality of life of patients with proliferative diabetic retinopathy. *Retina* 2013;33(7):1479.
- 5 Yang HS, Kim JG, Cha JB, Yun YI, Park JH, Woo JE. Quantitative analysis of neural tissues around the optic disc after panretinal photocoagulation in patients with diabetic retinopathy. *PLoS One* 2017;12(10):e0186229.

- 6 González-Saldivar G, Rojas-Juárez S, Espinosa-Soto I, Sánchez-Ramos J, Jaurieta-Hinojosa N, Ramírez-Estudillo A. Single-spot yellow laser versus conventional green laser on panretinal photocoagulation: patient pain scores and preferences. *Ophthalmic Surg Lasers Imaging Retina* 2017;48(11):902-905.
- 7 Nikkiah H, Ghazi H, Razzaghi MR, Karimi S, Ramezani A, Soheilian M. Extended targeted retinal photocoagulation versus conventional pan-retinal photocoagulation for proliferative diabetic retinopathy in a randomized clinical trial. *Int Ophthalmol* 2018;38(1):313-321.
- 8 Theodossiadis GP, Boudouri A, Georgopoulos G, Koutsandrea C. Central visual field changes after panretinal photocoagulation in proliferative diabetic retinopathy. *Ophthalmologica* 1990;201(2):71-78.
- 9 Lim MC, Tanimoto SA, Furlani BA, Lum B, Pinto LM, Eliason D, Prata TS, Brandt JD, Morse LS, Park SS, Melo LA Jr. Effect of diabetic retinopathy and panretinal photocoagulation on retinal nerve fiber layer and optic nerve appearance. *Arch Ophthalmol* 2009;127(7):857-862.
- 10 Lee SB, Yun YJ, Kim SH, Kim JY. Changes in macular thickness after panretinal photocoagulation in patients with severe diabetic retinopathy and no macular edema. *Retina* 2010;30(5):756-760.
- 11 Lee DE, Lee JH, Lim HW, Kang MH, Cho HY, Seong M. The effect of pattern scan laser photocoagulation on peripapillary retinal nerve fiber layer thickness and optic nerve morphology in diabetic retinopathy. *Korean J Ophthalmol* 2014;28(5):408-416.
- 12 Park YR, Jee D. Changes in peripapillary retinal nerve fiber layer thickness after pattern scanning laser photocoagulation in patients with diabetic retinopathy. *Korean J Ophthalmol* 2014;28(3):220-225.
- 13 Muqit MM, Marcellino GR, Henson DB, Fenerty CH, Stanga PE. Randomized clinical trial to evaluate the effects of Pascal panretinal photocoagulation on macular nerve fiber layer: Manchester Pascal Study report 3. *Retina* 2011;31(8):1699-1707.
- 14 Mitsch C, Pemp B, Kriechbaum K, Bolz M, Scholda C, Schmidt-Erfurth U. Retinal morphometry changes measured with spectral domain-optical coherence tomography after pan-retinal photocoagulation in patients with proliferative diabetic retinopathy. *Retina* 2016;36(6):1162-1169.
- 15 Muqit MM, Marcellino GR, Henson DB, Young LB, Patton N, Charles SJ, Turner GS, Stanga PE. Single-session vs multiple-session pattern scanning laser panretinal photocoagulation in proliferative diabetic retinopathy: The Manchester Pascal Study. *Arch Ophthalmol* 2010;128(5):525-533.
- 16 Muqit MM, Marcellino GR, Henson DB, Young LB, Turner GS, Stanga PE. Pascal panretinal laser ablation and regression analysis in proliferative diabetic retinopathy: Manchester Pascal Study Report 4. *Eye (Lond)* 2011;25(11):1447-1456.
- 17 Xu Y, Wang L, He J, *et al.* Prevalence and control of diabetes in Chinese adults. *JAMA*. 2013;310(9):948-959.
- 18 Wang LM, Gao P, Zhang M, Huang ZJ, Zhang DD, Deng Q, Li YC, Zhao ZP, Qin XY, Jin DY, Zhou MG, Tang X, Hu YH, Wang LH. Prevalence and ethnic pattern of diabetes and prediabetes in China in 2013. *JAMA* 2017;317(24):2515-2523.
- 19 Seymenoğlu RG, Ulusoy MO, Başer EF. Safety and efficacy of panretinal photocoagulation in patients with high-risk proliferative diabetic retinopathy using pattern scan laser versus conventional YAG laser. *Kaohsiung J Med Sci* 2016;32(1):22-26.
- 20 Muraly P, Limbad P, Srinivasan K, Ramasamy K. Single session of Pascal versus multiple sessions of conventional laser for panretinal photocoagulation in proliferative diabetic retinopathy: a comparative study. *Retina* 2011;31(7):1359-1365.
- 21 Sanghvi C, McLauchlan R, Delgado C, Young L, Charles SJ, Marcellino G, Stanga PE. Initial experience with the Pascal photocoagulator: a pilot study of 75 procedures. *Br J Ophthalmol* 2008;92(8):1061-1064.
- 22 Ye HY, Jin CJ, Zhong XQ, Tian Z, Lin WY. Pattern scan laser photocoagulator on retinopathy: an annual clinical application summary. *Eye Sci* 2011;26(2):70-74.
- 23 Mikoshiba Y, Iwase T, Ueno Y, Yamamoto K, Ra E, Terasaki H. A randomized clinical trial evaluating choroidal blood flow and morphology after conventional and pattern scan laser panretinal photocoagulation. *Sci Rep* 2018;8(1):14128.
- 24 Lee SB, Kwag JY, Lee HJ, Jo YJ, Kim JY. The longitudinal changes of retinal nerve fiber layer thickness after panretinal photocoagulation in diabetic retinopathy patients. *Retina* 2013;33(1):188-193.
- 25 Lorusso M, Milano V, Nikolopoulou E, Ferrari LM, Cicinelli MV, Querques G, Ferrari TM. Panretinal photocoagulation does not change macular perfusion in eyes with proliferative diabetic retinopathy. *Ophthalmic Surg Lasers Imaging Retina* 2019;50(3):174-178.
- 26 Ye HY, Yu MZ, Lu L, Jin CJ, Luo GW. Correction to: Electroretinogram evaluation for the treatment of proliferative diabetic retinopathy by short-pulse pattern scanning laser panretinal photocoagulation. *Lasers Med Sci* 2018;33(5):1103.
- 27 Ito A, Hirano Y, Nozaki M, Ashikari M, Sugitani K, Ogura Y. Short pulse laser induces less inflammatory cytokines in the murine retina after laser photocoagulation. *Ophthalmic Res* 2015;53(2):65-73.
- 28 Chappelov AV, Tan K, Waheed NK, Kaiser PK. Panretinal photocoagulation for proliferative diabetic retinopathy: pattern scan laser versus argon laser. *Am J Ophthalmol* 2012;153(1):137-142.e2.
- 29 Yamakawa M, Nozaki M, Sato R, Morita H, Yoshida M, Ogura Y. Comparison of outcomes of conventional laser versus pascal laser for diabetic retinopathy. *Nippon Ganka Gakkai Zasshi* 2014;118(4):362-367.