

# Unilateral bullous retinal detachment in a child with acute lymphoblastic leukaemia, and hypopyon as the first sign of leukaemic relapse

Sagili Chandrasekhara Reddy<sup>1,2</sup>

<sup>1</sup>Department of Ophthalmology, School of Medicine, University Sains Malaysia, Kubang Kerian, Kelantan 16150, Malaysia

<sup>2</sup>Department of Ophthalmology, Faculty of Medicine and Defence Health, National Defence University of Malaysia, Kuala Lumpur 57000, Malaysia

**Correspondence to:** Sagili Chandrasekhara Reddy. Department of Ophthalmology, Faculty of Medicine and Defence Health, National Defence University of Malaysia, Sungai Besi Campus, Kuala Lumpur 57000, Malaysia. profscreddy@gmail.com

Received: 2018-05-25 Accepted: 2018-07-17

**DOI:10.18240/ijo.2018.10.24**

**Citation:** Reddy SC. Unilateral bullous retinal detachment in a child with acute lymphoblastic leukaemia, and hypopyon as the first sign of leukaemic relapse. *Int J Ophthalmol* 2018;11(10):1726-1729

## Dear Editor,

I report a case of bullous retinal detachment in a child with acute lymphoblastic leukaemia (ALL) at diagnosis of systemic disease and the recurrence of detachment, hypopyon and secondary glaucoma as signs of relapse of leukaemia after chemotherapy remission of systemic disease. All the principles outlined in the Declaration of Helsinki (2008) were followed and an informed consent was taken by father of the child whenever the child was admitted in the ward. A brief review of literature of this disease is also included.

ALL is a malignant neoplasm caused by the proliferation of poorly differentiated precursors of the lymphoid cells (blast cells) and is the most common type of childhood leukaemia. Ocular involvement may occur anytime in the course of the disease, or can be the initial mode of presentation of the disease, or can be the first manifestation of the disease. It may be due to disease related anaemia, thrombocytopenia or hyperviscosity syndrome (flame shaped, dot-blot, white centered and macular haemorrhages), or direct infiltration of ocular tissues (orbit, choroid, retina, optic nerve, iris), or neuro-ophthalmic signs (papilloedema, ocular cranial nerve palsies), or anterior segment involvement (hypopyon, iris

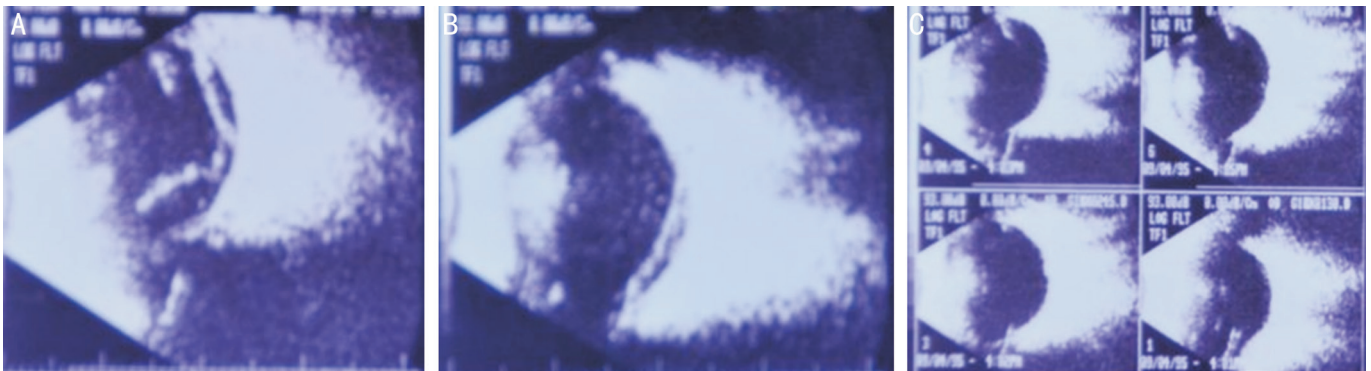
nodules, secondary glaucoma) in relapse cases<sup>[1]</sup>. Occurrence of exudative retinal detachment is rare in leukaemia. Only few isolated cases of exudative retinal detachment at initial presentation of leukaemia in children<sup>[2-4]</sup> and in relapse of leukaemia after chemotherapy remission<sup>[5-9]</sup> have been reported in the literature.

## CASE REPORT

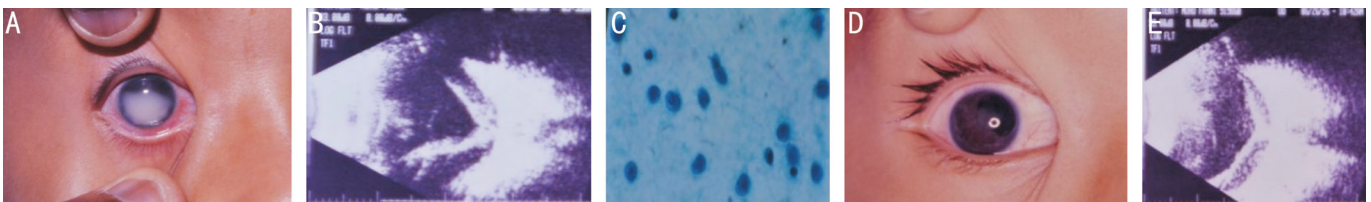
A 2-year-old boy was referred from the paediatric oncology ward to the Ophthalmology Department for white reflex in pupillary area in right eye of two days duration. The child was admitted two days back with reduced level of consciousness, post auricular swelling on the right side for the past one month, intermittent fever, progressive pallor, not gaining weight and loss of appetite, progressive swelling of both testis for the past two months. Child was drowsy, with neck stiffness, and pallor. There were generalized lymphadenopathy, hepatosplenomegaly, bilateral testicular swelling ( $7 \times 5 \text{ cm}^2$ ), and right posterior auricular swelling ( $3 \times 2 \text{ cm}^2$ ). Blood investigations showed Hb 5.5 g/dL, white blood cell  $157 \times 10^9/\text{L}$ , platelets  $25 \times 10^9/\text{L}$ . Peripheral smear showed lymphoid blast cells. He was diagnosed to have ALL, L3 B cell type after bone marrow aspiration. CT scan brain showed no space occupying lesion and no intracranial haemorrhage. The patient was treated with intravenous antibiotics, chemotherapy (French LMB 0128 protocol for ALL), packed cell transfusion, platelets transfusion and testicular irradiation.

Examination of right eye showed mild proptosis, leukocoria. Fundus examination showed bullous retinal detachment, supported by B-scan ultrasonography (Figure 1A). Left eye: anterior segment was normal. Fundus examination showed a subhyaloid haemorrhage in the macular area. The child's parents were explained about the condition of both eyes.

The follow-up examination after two weeks showed red reflex in the upper part of the fundus in the right eye and the retinal detachment started resolving. After two months, fundus examination of right eye showed red reflex was in upper and lower quadrants; B-scan ultrasonography of right eye showed the retina was much flatter than before (Figure 1B). The subhyaloid haemorrhage in the macula was getting absorbed in the left eye; and fresh superficial retinal haemorrhages were seen above and below the macula in the temporal quadrant.



**Figure 1 B-scan ultrasonography of right eye** A: Bullous retinal detachment at presentation; B: Resolution of retinal detachment after two months during chemotherapy; C: Complete resolution of bullous retinal detachment in all the quadrants after six months during chemotherapy.



**Figure 2 Ocular findings in relapse of leukaemia** A: Hypopyon in right eye six months after chemotherapy remission of leukaemia; B: Recurrence of retinal detachment simultaneously with relapse in the anterior segment seen in B-scan ultrasonography; C: Fine needle aspiration of hypopyon showing leukaemic cells; D: Complete resolution of hypopyon in the fourth week during chemotherapy; E: Retinal detachment in resolution process in the eighth week during the chemotherapy seen in B-scan ultrasonography.

The clinical condition improved and bone marrow aspiration done in sixth month showed remission. Right eye: good red reflex was seen in all the quadrants and fundus showed flat retina in all the quadrants in B-scan ultrasonography showed complete resolution of detachment (Figure 1C). Fundus examination of left eye showed the absorption of retinal haemorrhages and subhyaloid haemorrhage.

Six months after remission, the boy presented with pain, redness and whiteness in the right eye of two weeks duration. Right eye showed circumcorneal congestion, clear cornea and total hypopyon (Figure 2A). Small portion of iris was seen in the upper part only. Intraocular pressure (IOP) with tonopen was 36 mm Hg. Fundus could not be seen. Intravenous acetazolamide 100 mg was given to reduce IOP. The child was admitted in the eye ward and treated with dexamethasone 2 hourly, homatropine three times daily, timolol eye drops two times daily in the right eye and oral acetazolamide (20 mg/kg·d in three divided doses). On the next day, B-scan ultrasonography showed recurrence of retinal detachment (Figure 2B).

After IOP was controlled, fine needle aspiration cytology was done under general anaesthesia and the aspirate was positive for leukaemic cells (Figure 2C). The diagnosis of anterior segment relapse (iritis and secondary glaucoma) with recurrence of retinal detachment in the right eye was made. Left eye: anterior segment, IOP and fundus were normal.

The child was transferred to paediatric oncology ward for investigations. Peripheral smear and bone marrow aspiration showed no evidence of leukemia. Chemotherapy (Berlin-

Frankfurt-Munstor protocol for relapse of leukemia) was started. Three days after eye treatment, IOP was 26 mm Hg; hypopyon was less, but pupil was not visible. One week later, slit lamp examination showed rubeosis iridis with irregular pupil; hypopyon was minimal. Fundus showed faint red reflex. IOP was 20 mm Hg. Topical dexamethasone was reduced to 4 hourly in right eye, and other medicines were continued.

Child developed lagophthalmos in the right eye in third week after admission. Lumbar puncture was done and the cerebrospinal fluid showed blast cells indicating central nervous system (CNS) relapse and intrathecal chemotherapy was also given.

In the fourth week, hypopyon absorbed completely (Figure 2D), iris surface appeared smooth with thin exudate in the pupil and posterior synechiae. IOP was 18 mm Hg. Fundus examination showed faint red reflex, B-scan ultrasonography showed no change in the retinal detachment. Oral acetazolamide was stopped and the topical eye medications were continued.

In the eighth week, IOP was same; B-scan ultrasonography showed the retinal detachment was resolving (Figure 2E). The child was discharged on dexamethasone eye drops three times daily timolol eye drops two times daily and homatropine eye drops once daily in the right eye. After three months (during the course of chemotherapy), child died at home.

#### DISCUSSION

In leukemia, the most frequently affected ocular structure clinically is the retina (retinopathy) and histologically the choroid infiltration by leukaemic cells<sup>[1]</sup>. Exudative retinal

**Table 1 Demographic data, exudative retinal detachment with other ocular findings reported in the literature in isolated cases of childhood leukaemia**

Authors	Country	Age (y)	Gender	Type of leukaemia	Type of RD and other ocular findings
Khaja <i>et al</i> <sup>[2]</sup>	USA	2	Girl	AML	Bilateral leukaemic infiltrates of orbits and choroid, with an exudative RD in the right eye (at initial presentation of leukaemia)
Kiratli <i>et al</i> <sup>[3]</sup>	Turkey	9	Girl	ALL	Unilateral exudative RD, with simultaneous conjunctival, uveal and orbital infiltration (at initial presentation of leukaemia)
Stewart <i>et al</i> <sup>[4]</sup>	USA	-	Boy	ALL	Unilateral exudative RD and visual loss (at initial presentation of leukemia)
Hung and Kuo <sup>[5]</sup>	Taiwan, China	12	Boy	ALL	Unilateral optic nerve infiltration and exudative RD (in CNS relapse of leukaemia)
Azik <i>et al</i> <sup>[6]</sup>	Turkey	8	Boy	ALL	Bullous RD with intraocular mass (in relapse of leukaemia)
Subramanyam <i>et al</i> <sup>[7]</sup>	India	5	Boy	ALL	Bilateral subretinal leukaemic infiltrates and exudative RD (as isolated ocular relapse of leukaemia)
Yoshida <i>et al</i> <sup>[8]</sup>	Japan	4	Boy	ALL	Bilateral bullous exudative RD (in relapse of leukaemia)
Primack <i>et al</i> <sup>[9]</sup>	USA	3.5	Boy	ALL	Unilateral total RD with glaucoma (as isolated ocular relapse of leukaemia)
Present case	Malaysia	2	Boy	ALL	Unilateral bullous RD in the right eye and subhyaloid haemorrhage in macula in the left eye (at initial presentation of leukaemia). Hypopyon, glaucoma, RD and lagophthalmos in the right eye (in relapse of leukaemia)

AML: Acute myeloblastic leukaemia; ALL: Acute lymphoblastic leukaemia; RD: Retinal detachment; CNS: Central nervous system.

detachment is a rare manifestation of leukaemia. The mechanism of this type retinal detachment is thought to be due to infiltration of the choroid by leukaemic cells which decrease blood flow in choriocapillaries and cause ischemia of the overlying retinal pigment epithelium resulting in disruption of the intercellular tight junctions and retinal detachment<sup>[4]</sup>. Only few cases of exudative retinal detachment (at initial presentation of leukaemia or as a sign of relapse during chemotherapy remission of the disease) have been reported from different countries in children with acute leukaemia in the literature (Table 1).

In the present case, the retinal detachment occurred in haematological remission following chemotherapy, along with hypopyon (leukaemic cells in the anterior chamber). The probable reason could be that few cells of leukaemic infiltration in the choroid and retina escaped the effects of chemotherapy and increased in number rapidly after completion of chemotherapy. It is difficult to reach inside the eye completely for these drugs because of blood retinal barrier. The treatment for exudative retinal detachment is systemic chemotherapy because it is often due to infiltration by leukaemic cells. Extramedullary locations of ALL are mostly CNS, testis and eyes. The management is difficult in these cases and therefore, it is suggested that ophthalmic examination including fundus, at the time of diagnosis is crucial for all leukaemia patients, especially for those with very high white blood cell count<sup>[8]</sup>.

Anterior segment is an uncommon site of extramedullary relapse and it is most frequently seen in ALL patients. The reported anterior segment ocular presenting features of relapse

in childhood ALL include iritis with hypopyon<sup>[10-14]</sup>, iritis and heterochromia iris, prominent iris vessels<sup>[10]</sup>, signs of iritis, diffusely thickened iris, solid white mass in the anterior chamber with multiple deposits on the iris, anisocoria, corneal edema, glaucoma, panuveitis<sup>[11]</sup>, recurrent anterior uveitis, conjunctival tumour<sup>[15]</sup>. These cases suggest that any child with a prior history of ALL treatment presents with ocular symptoms, high index of the possibility of relapse should be kept in mind and diagnostic tests (aspiration of hypopyon/iris biopsy/biopsy of the mass in the eye) should be performed in addition to routine haematological evaluation. The mechanism of anterior segment relapse is not clear. Migration of leukemic cells along the posterior ciliary vessels in the subarachnoid space surrounding the optic nerve had been proposed as a mechanism linking the CNS and the anterior segment of the eye<sup>[16]</sup>. Systemic chemotherapy and local radiotherapy will result in rapid improvement of the eye condition<sup>[11]</sup>.

In the present case, the presenting symptoms and signs in the right eye were suggestive of ocular relapse of the systemic disease and the presence of blast cells in the anterior chamber aspirate confirmed the diagnosis of relapse of leukaemia. Moreover, the onset of lagophthalmos in the right eye indicated CNS relapse which was confirmed by the presence of blast cells in the cerebrospinal fluid.

In summary, this case illustrates that retinal detachment is a rare presenting feature in ALL in addition to other fundus findings in the eyes. The possibility of relapse of leukaemia should be ruled out whenever a child with prior chemotherapy for leukaemia presents with ocular symptoms and signs by

performing appropriate investigations and should be treated accordingly.

#### ACKNOWLEDGEMENTS

**Conflicts of Interest:** Reddy SC, None.

#### REFERENCES

- 1 Kincaid MC, Green WR. Ocular and orbital involvement in leukaemia. *Surv Ophthalmol* 1983;27(4):211-232.
- 2 Khaja WA, Pogrebniac AE, Bolling JP. Combined orbital proptosis and exudative retinal detachment as initial manifestation of acute myeloid leukemia. *J AAPOS* 2015;19(5):479-482.
- 3 Kiratli H, Bilgic S, Emec S. Simultaneous conjunctival, uveal and orbital infiltration as the initial sign of acute lymphoblastic leukemia. *Jpn J Ophthalmol* 2007;51(2):139-141.
- 4 Stewart MW, Gitter KA, Cohon G. Acute leukaemia presenting as a unilateral exudative retinal detachment. *Retina* 1989;9(2):110-114.
- 5 Hung K, Kuo H. Unilateral optic nerve leukemic infiltration and exudative retinal detachment as initial manifestation of central nervous system relapse in acute lymphoblastic leukemia of children. *J Clin Exp Ophthalmol* 2014;5:329.
- 6 Azik FM, Akinci A, Sayli TR, Culha YK, Teberik K, Teke MY, Gurbuz F. Unilateral exudative retinal detachment as the sole presentation of relapsing acute lymphoblastic leukemia. *Turk J Haematol* 2012;29(2):181-184.
- 7 Subramanyam A, Phatak S, Chandalia S, Kane SV, Banavali SD. Ocular biopsy through external needle drainage for isolated bilateral ocular relapse of childhood acute lymphoblastic leukemia. *Retin Cases Brief Rep* 2011;5(4):333-335.
- 8 Yoshida K, Hasegawa D, Takusagawa A, Kato I, Ogawa C, Echizen N, Ohkoshi K, Yamaguchi T, Hosoya R, Manabe A. Bullous exudative retinal detachment due to infiltration of leukemic cells in a child with acute lymphoblastic leukemia. *Int J Haematol* 2010;92(3):535-537.
- 9 Primack JD, Smith ME, Tychsen L. Retinal detachment in a child as a first sign of leukemic relapse: histopathology, MRI findings, treatment and tumour-free follow up. *J Pediatr Ophthalmol Strabismus* 1995;32(4):253-256.
- 10 MacLean H, Clarke MP, Strong NP, Kernahan J, Ashraf S. Primary ocular relapse in acute lymphoblastic leukaemia. *Eye (Lond)* 1996;10(Pt 6):719-722.
- 11 Novakovic P, Kellie SJ, Taylor D. Childhood leukaemia: relapse in the anterior segment. *Br J Ophthalmol* 1989;73(5):354-359.
- 12 Bunin N, Rivera G, Goode F, Hustu HO. Ocular relapse in the anterior chamber in childhood acute lymphoblastic leukemia. *J Clin Oncol* 1987;5(2):299-303.
- 13 Wadhwa N, Vohra R, Shrey D, Iyer VK, Garg S. Unilateral hypopyon in a child as a first and sole presentation of relapsing acute lymphoblastic leukemia. *Indian J Ophthalmol* 2007;55(3):223-224.
- 14 Lakhtakia R, Sinha A, Anand SK, Dhar AK, Thakur PK, Mehta A. Acute bilateral hypopyon in acute lymphocytic leukaemia. *Med J Armed Forces India* 2008;64(2):177-178.
- 15 Chocron IM, Morrison DG, Friedman DL, Desai NA, Donahue SP. Ophthalmic manifestations of relapsing acute childhood leukemia. *J AAPOS* 2015;19(3):284-286.
- 16 Decker EB, Burnstine RA. Leukemic relapse presenting as acute unilateral hypopyon in acute lymphoblastic leukemia. *Ann Ophthalmol* 1993;25(9):346-349.