

Visual impairment with possible macular changes after a high dose of sildenafil in a healthy young woman

Yun-Yun Li¹, Ya-Jie Yu¹, Xi-Pu Liu², Ning-Pu Liu¹

¹Beijing Tongren Eye Center, Beijing Tongren Hospital, Capital Medical University, Beijing 100730, China

²Sekwa Institute of Medicine, Beijing 100035, China

Correspondence to: Ning-Pu Liu. Beijing Tongren Eye Center, Beijing Tongren Hospital, Capital Medical University, No.1 Dong Jiao Min Xiang, Beijing 100730, China. nliu001@yeah.net

Received: 2017-03-08 Accepted: 2017-08-25

DOI:10.18240/ijo.2018.02.27

Citation: Li YY, Yu YJ, Liu XP, Liu NP. Visual impairment with possible macular changes after a high dose of sildenafil in a healthy young woman. *Int J Ophthalmol* 2018;11(2):340-342

Dear Editor,

Sildenafil citrate (Viagra[®]; Pfizer Pharmaceuticals, New York, NY, USA), a selective inhibitor of phosphodiesterase type 5 (PDE-5), is widely used for erectile dysfunction. Its clinical recommended dosage is 25 to 100 mg per day. The most common ocular side-effects are blurred vision and impaired blue/green colour discrimination^[1-3]. Mild and transient visual disturbances are often ignored by patients taking the recommended dose or resolve before the patient sees a doctor. Moreover, little attention has been paid to side-effects in patients who have overdosed sildenafil citrate. Herein, we report a case in a female patient with binocular visual disturbance, possibly due to outer retina damage in the foveal area, following consumption of a high dose (2000 mg) of sildenafil citrate. The case study was approved by the Ethics Committee of Beijing Tongren Hospital. Written informed consent was obtained from the patient.

A 32-year-old woman was referred to our outpatient clinic with a chief complaint of blurry vision in both eyes for 1d. Her history was insignificant except for having taken 2000 mg of sildenafil. One day before, she had taken 2000 mg of sildenafil impulsively after quarrelling with her husband. Sixty minutes later, symptoms began to manifest, including flushing, dizziness, colour vision defects, and blurred vision. One day later, her symptoms had resolved with the exception of blurred vision. Comprehensive ocular examinations were performed in our hospital. Best-corrected visual acuity (BCVA) was 0.7 in the right eye and 0.8 in the left eye. Intraocular pressure

and anterior segment were normal in both eyes. There was no obvious abnormality in the fundus, but mild pigment alteration was present in the fovea (Figure 1A, 1B). Fundus autofluorescence did not show abnormal signs in either eye (Figure 1C, 1D). Optical coherent tomography (OCT) revealed abnormal hyporeflectivity of the ellipsoid zone, the outer segments of photoreceptors and the interdigitation zone in the binocular foveal area (Figure 1E, 1F).

Seventeen days after the drug was taken, BCVA was 0.8 in right eye and 0.9 in left eye. Fluorescence fundus angiography (FFA) did not reveal abnormal signs in either eye (Figure 2A, 2B). The abnormal hyporeflectivity of the ellipsoid zone in the binocular foveal area had evidently improved, however, damage to the outer segments of photoreceptors and the interdigitation zone was still present (Figure 2C, 2D). Thirty-eight days after the drug was taken, in a telephone interview, we were informed that her visual acuity was recovered completely without any intervention. However, she refused to come back for further follow-up and examination.

Sildenafil was originally intended for treatment of erectile dysfunction. The pharmacological mechanism of action blocks the degradation pathway of cGMP by inhibiting PDE-5 selectively, and as a result, increased levels of cGMP induce relaxation of the smooth muscle of the corpus cavernosum, causing an inflow of blood to facilitate an erection. Notably, it also has approximately 10% effectiveness on the inhibition of PDE-6^[4]. PDE-6, a critical enzyme of the photoreceptor transduction cascade, regulates the Na⁺ channels in the outer segment of photoreceptors^[5]. Thus, concerns about its potential toxic effect on the retina have been widely raised^[1-2,4-9]. In this case, our observations are consistent with PDE inhibitor-associated retinal toxicity, characterized by damage to the photoreceptor^[5,10].

Previous studies have evaluated the impact of sildenafil on human visual function after a single^[6-7,11] or chronic^[8] large doses using electrophysiological techniques. However, the results have been contradictory. As previously reported, the incidence of vision disturbance is dose-dependent: approximately 3% of men taking 25 mg, up to 11% taking 100 mg, 50% taking 200 mg, and 100% of men taking 600 and 800 mg of sildenafil experienced visual disturbances^[3]. Preclinical animal studies conducted by Pfizer, Inc. also showed that sildenafil did not have a significant effect on electroretinogram

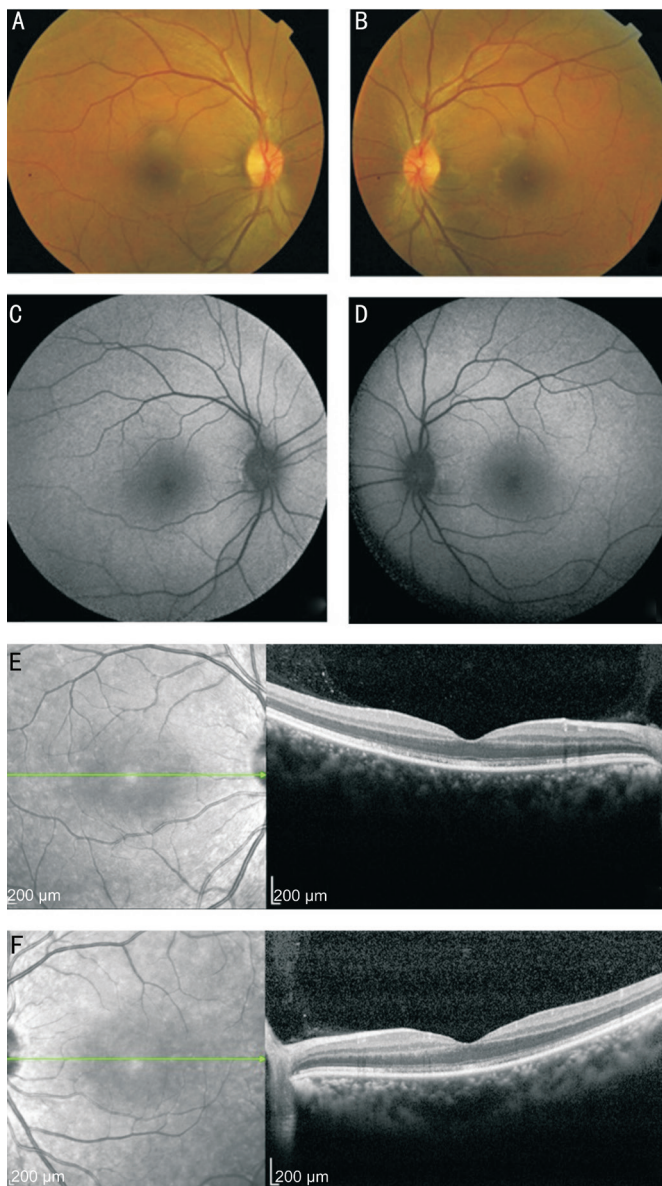


Figure 1 The ocular examinations of a healthy, 32-year-old woman 1d after a single overdose of sildenafil (2000 mg) A: Colour fundus photography of the right eye; B: Colour fundus photography of the left eye; C: Fundus autofluorescence of the right eye; D: Fundus autofluorescence of the left eye; E: OCT of the right eye; F: OCT of the left eye. There was no obvious abnormality in the fundus except mild pigment alteration in the fovea (A, B). Fundus autofluorescence did not reveal abnormal signs in either eye (C, D). OCT revealed an abnormal hyporeflectivity of the ellipsoid zone, the outer segments of photoreceptors and the interdigitation zone in the binocular foveal area. Choroidal thickness appeared to be thicker than usual (E, F).

(ERG) parameters until the dosage reached nearly 10 times that of the recommended dose^[6]. In this patient, the dosage of sildenafil was much higher than the recommended dose, and the visual disturbances may be attributed to two effects. Firstly, partial inhibition of PDE-6, an important enzyme that is involved in the activation and modulation of the phototransduction cascade^[5], could result in the colour vision defects and blurred vision. Secondly, PDE-5 inhibition increases nitric oxide

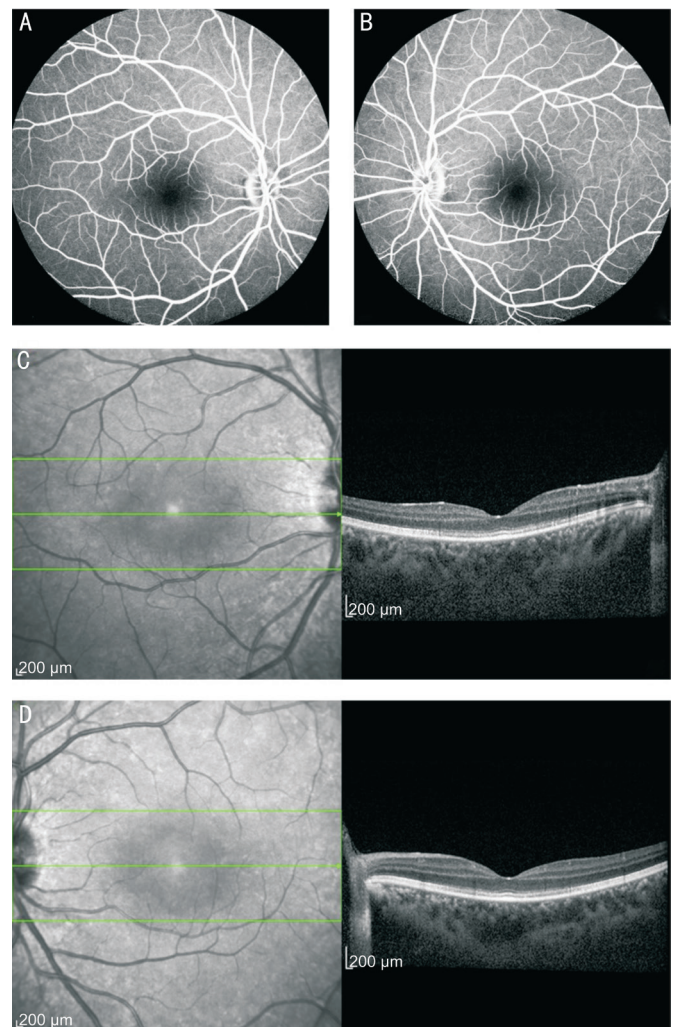


Figure 2 The ocular examinations of a healthy, 32-year-old woman 17d after a single overdose of sildenafil (2000 mg) A: Fluorescence fundus angiography (FFA) of the right eye; B: FFA of the left eye. No abnormal signs were found from the above examinations (A, B). C: OCT of the right eye; D: OCT of the left eye. OCT revealed that the abnormal hyporeflectivity of the ellipsoid zone in the binocular foveal area had evidently improved, but damage to the outer segments of photoreceptors and to the interdigitation zone still presented. Choroidal thickness still appeared to be thicker than usual (C, D).

levels and potentiates the vasodilation effect^[12], consequently, acute changes in ocular perfusion pressure could result in retinal damage^[10]. The peak plasma concentration of sildenafil occurs at approximately 30-60min, and elimination half-time is approximately 3-5h when administered within the therapeutic dosage^[6]. The early disappearance of general symptoms and colour vision disturbances may be closely related to the drug metabolism, and the delayed improvement of visual acuity may be attributed to the chronic recovery of the photoreceptors' structure. The later telephone interview seems to confirm that the ocular side-effects can be reversible. Longer-term follow-up, however, is required to make any statement regarding whether the changes noted were reversible or not. Moreover, as shown by OCT, choroidal thickness

appears to be thicker than usual. Given that choroidal thickness can be affected by multiple factors and was not measured at baseline, a vasodilatory effect of sildenafil on the choroidal circulation^[13-14] is uncertain in this case.

In summary, we firstly reported a female case of binocular visual disturbance possibly due to outer retina damage in the foveal area following consumption of an overdose of sildenafil. Patients should be warned about the visual side-effects in cases of misuse.

ACKNOWLEDGEMENTS

Conflicts of Interest: Li YY, None; Yu YJ, None; Liu XP, None; Liu NP, None.

REFERENCES

- 1 Vobig MA, Klotz T, Staak M, Bartz-Schmidt KU, Engelmann U, Walter P. Retinal side-effects of sildenafil. *Lancet* 1999;353(9150):375.
- 2 McCulley TJ, Lam BL, Marmor MF, Hoffiman KB, Luu JK, Feuer WJ. Acute effects of sildenafil (viagra) on blue-on-yellow and white-on-white Humphrey perimetry. *J Neuroophthalmol* 2000;20(4):227-228.
- 3 Gabrieli CB, Regine F, Vingolo EM, Rispoli E, Fabbri A, Isidori A. Subjective visual halos after sildenafil (Viagra) administration: Electroretinographic evaluation. *Ophthalmology* 2001;108(5):877-881.
- 4 Estrade M, Grondin P, Cluzel J, Bonhomme B, Doly M. Effect of a cGMP-specific phosphodiesterase inhibitor on retinal function. *Eur J Pharmacol* 1998;352(2-3):157-163.
- 5 Zhang X, Feng Q, Cote RH. Efficacy and selectivity of phosphodiesterase-targeted drugs in inhibiting photoreceptor phosphodiesterase (PDE6) in

- retinal photoreceptors. *Invest Ophthalmol Vis Sci* 2005;46(9):3060-3066.
- 6 Luu JK, Chappelov AV, McCulley TJ, Marmor MF. Acute effects of sildenafil on the electroretinogram and multifocal electroretinogram. *Am J Ophthalmol* 2001;132(3):388-394.
- 7 Jagle H, Jagle C, Serey L, Yu A, Rilk A, Sadowski B, Besch D, Zrenner E, Sharpe LT. Visual short-term effects of Viagra: double-blind study in healthy young subjects. *Am J Ophthalmol* 2004;137(5):842-849.
- 8 Zoumalan CI, Zamanian RT, Doyle RL, Marmor MF. ERG evaluation of daily, high-dose sildenafil usage. *Doc Ophthalmol* 2009;118(3):225-231.
- 9 Kinoshita J, Iwata N, Shimoda H, Kimotsuki T, Yasuda M. Sildenafil-induced reversible impairment of rod and cone phototransduction in monkeys. *Invest Ophthalmol Vis Sci* 2015;56(1):664-673.
- 10 Coscas F, Coscas G, Zucchiatti I, Bandello F, Soubrane G, Souied E. Optical coherence tomography in tadalafil-associated retinal toxicity. *Eur J Ophthalmol* 2012;22(5):853-856.
- 11 Jagle H, Jagle C, Serey L, Sharpe LT. Dose-dependency and time-course of electrophysiologic short-term effects of VIAGRA: a case study. *Doc Ophthalmol* 2005;110(2-3):247-254.
- 12 Pache M, Meyer P, Prünke C, Orgül S, Nuttli I, Flammer J. Sildenafil induces retinal vasodilatation in healthy subjects. *Br J Ophthalmol* 2002;86(2):156-158.
- 13 Lee WJ, Seong M. Sildenafil citrate and choroidal thickness. *Retina* 2011;31(8):1742; author reply 1742-1743.
- 14 Vance SK, Imamura Y, Freund KB. The effects of sildenafil citrate on choroidal thickness as determined by enhanced depth imaging optical coherence tomography. *Retina* 2011;31(2):332-335.