

Altered perception of floaters in dementia causing self-inflicted injuries

Will Griffeth, Steven Kane, Syed Khurshid Gibran

Department of Ophthalmology, University of Florida, Gainesville, FL 32608, USA

Correspondence to: Syed Khurshid Gibran. Department of Ophthalmology, University of Florida, 1600 SW Archer road, Gainesville, FL 32608, USA. syedgibran@yahoo.com

Received: 2016-02-05 Accepted: 2017-04-13

DOI:10.18240/ijo.2017.07.27

Griffeth W, Kane S, Gibran SK. Altered perception of floaters in dementia causing self-inflicted injuries. *Int J Ophthalmol* 2017; 10(7):1181-1182

Dear Editor,

A 74 years old male patient with history of Parkinson disease and vascular dementia presented to the eye clinic with his wife, who is his primary caregiver. The patient reported a multiple year history of complaining of “flies” around his head, which were a source of considerable agitation. He was so bothered by constantly seeing these flies that he carried a custom flyswatter with him (Figure 1) at all times. His wife had fashioned this with padded edges after he sustained multiple self-inflicted corneal abrasions while swatting the “flies.” No other injuries were reported or examined during his clinic visits. He had also recently obtained a can of bug spray, which his wife was fortunately able to take before he sprayed himself in the face. He wore a patch over the right eye, which he reported helped with the flies.

The patient had a known history of vitreous floaters, and had been evaluated by multiple ophthalmologists in the years prior to his presentation in our clinic. The patient’s dementia led him to misinterpret his vitreous floaters as a constant barrage of insects, which added significant morbidity to his mental illness. He and his wife had been told that vitreous floaters were the likely cause of his symptoms, but that there were no safe and effective options for eliminating them. When they presented to our clinic, the patient’s wife reported that the patient’s agitation regarding the flies was worsening and adding to her already significant challenges as his primary caregiver.

Exam showed best corrected visual acuity of 20/60 OD and 20/40 OS. The remainder of exam was significant only for pseudophakia and posterior vitreous detachment with Weiss ring of both eyes, and vitreous condensations (right greater

than left). A discussion of the risks and benefits of pars plana vitrectomy for removal of floaters was conducted with the patient and his wife, who both agreed to proceed with surgery. After obtaining informed consent, consecutive uneventful pars plana vitrectomies were performed, first on the right eye and then six weeks later on the left when symptoms persisted. Large central vitreous condensations in the visual axis of both eyes were noted intraoperatively (Figure 2).

At postoperative one month from the second eye, the patient reported complete relief of symptoms. He still preferred to hold his flyswatter occasionally but his wife explained this was more of “security blanket” and that he no longer swatted at himself. The patient reported his vision was improved enough that he could now “see out of both eyes” and he no longer needed to patch the right eye. His wife reported considerable reduction in his overall agitation. Visual acuity without

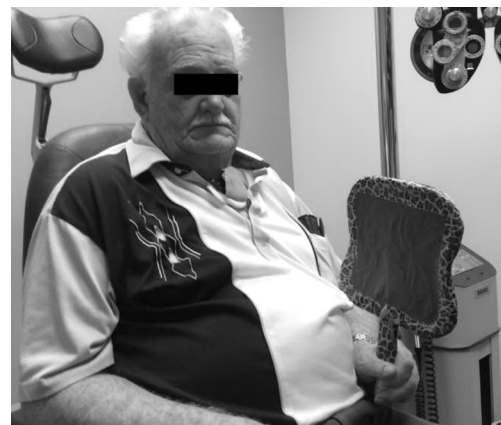

Figure 1 Preoperative picture of the patient carrying his flyswatter.

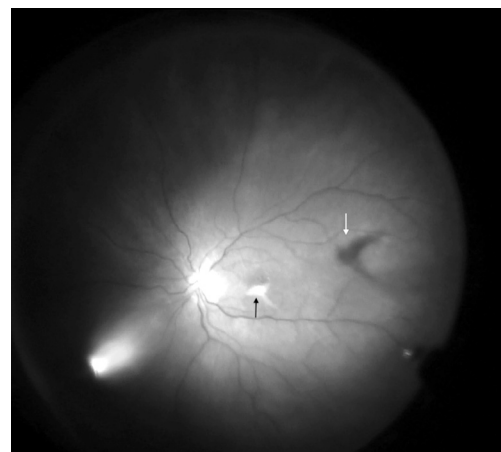


Figure 2 The 25g light pipe illuminates a central vitreous condensation directly over the fovea (black arrow). The shadow cast by the light source is visible on the temporal macula (white arrow).

correction was improved to 20/30 in the right eye, 20/40 in the left eye.

At 3mo follow up, the patient had stopped holding his flyswatter, visual acuity maintained at the same level and wife expressed her satisfaction and gratitude to improve their quality of life immensely.

Our case represents an interesting variation of an exceedingly common presentation of vitreous floaters, and illustrates a shift in management of symptomatic vitreous opacities. Vitreous floaters are entoptic phenomenon, causing visual symptoms by casting shadows onto the retina. These symptoms, called myodesopsia, are among the more common symptoms reported to eye doctors, but generally prompt little interest beyond investigation for new posterior vitreous detachment and associated retinal pathology. To our knowledge, there are no published reports of similar symptoms attributable to floaters, which might be described in this case as a type of persistent delusion.

Recent work has cast increasing light on the morbidity associated with floaters^[1]. Concurrently, the evolution of safer vitrectomy techniques has changed the risk profile

for “floaterectomy” procedures, which are increasingly being incorporated into modern vitreoretinal practice^[2]. Patient selection is of paramount importance in the surgical management of floaters, and this case presented a particular challenge due to the impaired reasoning capacity of the patient. In this patient, the benefit of surgical removal of his vitreous opacities outweighed the risk of operative complication, especially when considering the added risk of self-inflicted injury and the impact on this patient’s quality of life. This case highlights the importance of recognizing when patients with mental illness may also have treatable underlying conditions. In this case, both patient and care giver appear to have benefited immensely from the operations.

ACKNOWLEDGEMENTS

Conflicts of Interest: **Griffeth W**, None; **Kane S**, None; **Gibran SK**, None.

REFERENCES

- 1 Wagle AM, Lim WY, Yap TP, Neelam K, Au Eong KG. Utility values associated with vitreous floaters. *Am J Ophthalmol* 2011;152(1):60-65.e1.
- 2 Wa C, Sebag J. Safety of vitrectomy for floaters. *Am J Ophthalmol* 2011;152(6):1077; author reply 1077-1078.