

# Diabetic macular edema in proliferative stage treated with anti-vascular endothelial growth factor agent and triamcinolone acetonide by laser-based strategies

Gang Qiao<sup>1,2,3</sup>, Wan-Jiang Dong<sup>2</sup>, Yan Dai<sup>3</sup>, Zhen-Hua Jiang<sup>3</sup>, Hai-Ke Guo<sup>1</sup>

<sup>1</sup>Department of Ophthalmology, Guangdong General Hospital Affiliated to Southern Medical University, Guangzhou 510515, Guangdong Province, China

<sup>2</sup>Department of Ophthalmology, Mianyang Wan-Jiang Eye Hospital, Mianyang 621000, Sichuan Province, China

<sup>3</sup>Department of Ophthalmology, Mianyang Central Hospital, Mianyang 621000, Sichuan Province, China

**Correspondence to:** Hai-Ke Guo. Department of Ophthalmology, Guangdong General Hospital Affiliated to Southern Medical University, Guangzhou 510515, Guangdong Province, China. qiaogang3@163.com; guohaike@hotmail.com

Received: 2016-09-08 Accepted: 2017-02-13

## Abstract

• **AIM:** To appraise the effect of treatment for diabetic macular edema (DME) in proliferative stage with sufficient panretinal photocoagulation (PRP) therapy and intravitreal injections (IV) Conbercept and posterior subtenon's triamcinolone acetonide (STTA) sequential therapy.

• **METHODS:** This prospective clinical randomized controlled trial of cross-over design was conducted in three phases. The participants included cases of DME in proliferative stage. They were divided into two groups and treated with PRP before enrollment. Group A were treated with IV-Conbercept 0.5 mg for one month in the 1<sup>st</sup> phase. Group B were treated with STTA 40 mg (twice per two weeks). The interventions were exchanged in the second phase (2mo) between the two groups. In the third phase (3-6mo) no other treatment was given. Best corrected visual acuity (BCVA), central macular thickness (CMT) measured by OCT and complications were compared.

• **RESULTS:** After phase I: in Group A, BCVA improved from 0.201±0.17 to 0.37±0.24 ( $F=5.88$ ,  $P=0.004$ ). CMT changed from 449±155.10 to 304.1±84.70 μm ( $F=14.9$ ,  $P<0.01$ ). In Group B, BCVA changed from 0.195±0.19 to 0.26±0.20 ( $F=0.76$ ,  $P=0.41$ ) while CMT changed from 463.82±152.92 to 366.00±115.40 μm ( $F=3.70$ ,  $P<0.03$ ). The improvement of BCVA was better in Group A ( $P<0.05$ ). After phase II: in Group A, BCVA raised to 0.47±0.27 ( $F=0.26$ ,  $P<0.01$ ), CMT reduced to 260.67±62.97 μm ( $F=-188.3$ ,  $P<0.01$ ); in Group B, BCVA raised to 0.51±0.26 ( $F=0.31$ ,  $P<0.01$ ), CMT reduced to 261.93±50.15 μm

( $F=-201.9$ ,  $P<0.01$ ). But there were no difference between two groups ( $P>0.05$ ). After phase III: in Group A, BCVA maintained 0.42±0.25 ( $F=0.22$ ,  $P=0.001$ ), CMT maintained 267.8±58.34 μm, ( $F=-0.27$ ,  $P<0.01$ ); in Group B, BCVA was 0.47±0.25 ( $F=-0.27$ ,  $P<0.01$ ), CMT was 272.71±49.16 μm ( $F=-191.1$ ,  $P<0.01$ ). No serious complications happened in all phases.

• **CONCLUSION:** PRP+Conbercept is better than PRP+STTA in DME with proliferative stage but PRP+Conbercept+STTA sequential therapy may be a wiser choice for persistent effectiveness on anatomical as well as functional status.

• **KEYWORDS:** Conbercept; sequential therapy; cross-over design; diabetic macular edema

DOI:10.18240/ijo.2017.07.15

Qiao G, Dong WJ, Dai Y, Jiang ZH, Guo HK. Diabetic macular edema in proliferative stage treated with anti-vascular endothelial growth factor agent and triamcinolone acetonide by laser-based strategies. *Int J Ophthalmol* 2017;10(7):1113-1119

## INTRODUCTION

Diabetes mellitus (DM) is not only epidemic in developed country but also in developing country<sup>[1]</sup>. At present, there are 110 million diabetic persons in China, which are the most cases in a developing country<sup>[2]</sup>. Diabetic retinopathy (DR), a microvascular complication of diabetes, is more than 35% of diabetes<sup>[3]</sup>. The average rate of proliferative diabetic retinopathy (PDR), one of serious complications of DR, is 3.3%-7.4%. Diabetic macular edema (DME), another serious complication of DR, occurs with a large proportion in DR also<sup>[4]</sup>. The two main serious complications of DR constitute the major causes of visual loss in diabetics in China.

When DME occur in stage of proliferative retinopathy, treatment becomes more difficult<sup>[5-6]</sup>. The main treatment modalities are panretinal or focal laser treatment, intravitreal injections of anti-vascular endothelial growth factor (VEGF) or triamcinolone acetonide (TA) and pars plana vitrectomy (PPV)<sup>[7-8]</sup>. Although management of DME has country specific preferred practice pattern (PPP)<sup>[9]</sup>, management protocols for DME in PDR after panretinal photocoagulation (PRP) treatment is debatable.

Conbercept, a new medicine of China, has been demonstrated an excellent antiangiogenic effect for choroidal neovascularization caused by age-related macular degeneration compared with other imported anti-VEGF drugs such as Lucentis or Afibercept<sup>[10-12]</sup>. But the effect on DME in PDR has not been previously reported.

So, a clinical research was designed to explore this problem by laser-based strategies and intravitreal injections (IV) Conbercept combined with posterior subtenon's triamcinolone acetonide (STTA) sequential therapy.

**SUBJECTS AND METHODS**

**Study Design** The study was a prospective, single-center, randomized controlled clinical trial by cross-over design. It included Chinese patients with DME in PDR stage from Mianyang Central Hospital in Mianyang, China. Written informed consent was obtained from all participants. The study was approved by the Institutional Review Board of the hospitals. The sample size were estimated by SPSS Statistical Package. The cross-over scheme were designed for every patient who could accept the same treatment after the clinical trial in accordance with the tenets of the Declaration of Helsinki and following the principles of minimally invasive, low cost and easy processing. This clinical trial was divided into three phases: PRP+Conbercept and PRP+STTA were contrasted in phase I, the effect of sequential therapies were compared in phase II and the persistent effects were observed in phase III.

**Subjects** The study population consisted of patients aged ≥18y with type 1 or 2 DM, hemoglobin (Hb) A1c ≤10%. Inclusion criteria were as follows: 1) patients with PDR who were treated with PRP, and not having PPV surgery in last six months; 2) DME detected on slit lamp biomicroscopy according to ETDRS criteria, leakage confirmed by intravenous fundus fluorescein angiography (FFA; TOPCOM-TRC 50DX, Japan), central macular thickness (CMT) ≥250 μm on optical coherence tomography (OCT; TOPCOM-3D OCT-2000, Japan).

Exclusion criteria were as follows: 1) rubeosis, glaucoma [intraocular pressure (IOP) greater than 29 mm Hg], significant cataract (which does not allow complete ocular examination and proposed measurements) and any condition that might interfere with assessment of the progression of macular oedema; 2) other retinal vascular diseases; 3) impaired renal function demonstrated by receiving dialysis or uncontrolled hypertension showing values of blood pressure (BP) greater than 90 mm Hg (diastolic BP) or 165 mm Hg (systolic BP); 4) patients who had received any investigational drug or device prior to screening; 5) subjects who had suffered PPV for vitreous hemorrhage or tractional retinal detachment ≤6mo; 6) any contraindication for intravitreal or subtenon's injections.

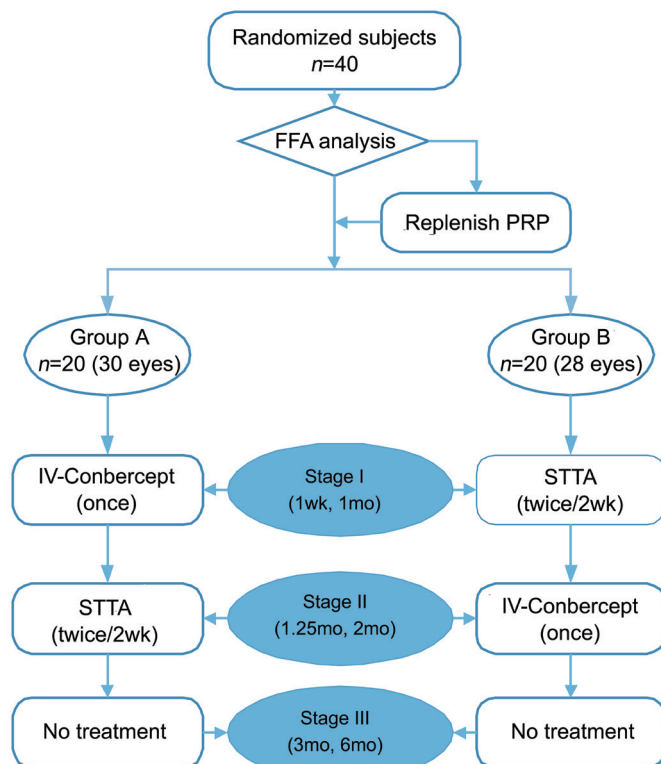


Figure 1 Flow diagram of cross-over design clinical research.

**Intervention** We randomised the eyes into two treatment groups (A and B) by using a randomisation table. A flow diagram of patient progress in different phases of the study is shown in Figure 1. An eye was subjected to PRP treatment if leakage or capillary non-perfusion was confirmed by FFA before ocular injections commenced.

Patients were examined before commencing intervention (baseline), at phase I (1wk, 1mo), at phase II (1.25mo, 2mo) and phase III (3mo, 6mo). At each visit, best corrected visual acuity (BCVA) was noted using the international visual chart (decimal), CMT were measured by OCT. In addition, refraction, slit-lamp examination, tonometry and ophthalmoscopy were carried out. FFA, measurement of BP and HbA1c tests at baseline and at follow-ups.

In the first phase, patients in Group A were treated with IV-Conbercept 0.5 mg and patients in Group B were treated with STTA 40 mg (twice, per two weeks). In the second phase (sequential therapy), the therapeutic schemes were switched between groups. In the third phase no other treatment was given and patients were monitored.

**Treatment Technique** In all patients, intraocular injections were performed under sterile conditions in the surgery unit following standardized procedures. A volume of 0.05 mL containing Conbercept 0.5 mg (KH902; Chengdu Kanghong Biotech Co., Ltd., Sichuan Province, China) was injected at 3.5-mm distance from the limbus through the inferotemporal pars plana.

For posterior STTA injection under topical anesthesia, 40 mg TA (Kenacort A, 40 mg/mL; Bristol Myers Squibb Srl, Italy)

**Table 1 Clinical characteristics of the groups** mean±SD

Characteristics	Group A	Group B	<i>t</i>	<i>P</i>
Age (a)	61.9±6.1	61.8±5.8	0.09	0.93
Duration of DM (a)	6.3±2.8	6.63±2.61	-0.50	0.62
HbA1c (%)	7.5±1.3	7.50±1.22	0.02	0.98
BCVA (median, 25% quartile)	0.20±0.17 (0.18, 0.02)	0.19±0.19 (0.18, 0.02)	0.12	0.91
CMT (μm)	449±155.1	463.8±152.9	-0.37	0.72
IOP (mm Hg)	17.6±3.1	17.4±2.7	0.33	0.74
PPV suffered (eyes)	7	9	-	-
PRP replenished (eyes)	6	5	-	-

**Table 2 Comparison of BCVA and CMT for groups in the first phase** mean±SD

Phase I		Group A	Group B	<i>t</i>	<i>P</i>
BCVA (median, 25% quartile)	Baseline	0.20±0.17 (0.18, 0.02)	0.195±0.19 (0.18, 0.02)	0.12	0.91
	1wk	0.38±0.25 (0.35, 0.18)	0.23±0.22 (0.18, 0.07)	2.25	0.03
	1mo	0.37±0.24 (0.35, 0.14)	0.26±0.20 (0.23, 0.10)	1.84	0.07
Compared with baseline	<i>F</i>	5.88	0.76	-	-
	<i>P</i>	0.004	0.47	-	-
CMT (μm)	Baseline	449±155	464±153	-0.37	0.72
	1wk	310.20±96.6	404±136	-3.06	0.003
	1mo	304.1±84.7	366.0±115.4	-2.34	0.02
Compared with baseline	<i>F</i>	14.9	3.70	-	-
	<i>P</i>	<0.01	0.03	-	-

in a 1-mL volume was injected into the inferotemporal quadrant using a 27-gauge cannula through a conjunctival opening.

**Statistical Analysis** Statistical analysis was performed using the statistical package Statistical Package for Social Sciences (SPSS) Version 20 (SPSS, Chicago, IL, USA). Data were expressed in frequency, percentage, mean ± standard deviation, median and 25% quartile as applicable. Analysis of variance (ANOVA) was used to compare between groups and paired *t*-test was used to compare with each group. A two tailed *P* value of less than 0.05 was considered significant.

## RESULTS

**Baseline Characteristics** Preoperative clinical characteristics of patients in both groups are given in Table 1. Of the 40 patients (58 eyes), 23 were men and 17 were women, and all of them completed the 6mo follow-up. The mean age was 61.9 (SD 5.9) (range 52 to 73)y. The mean duration of diabetes was 6.44 (SD 2.69) (range 4 to 15)y. The mean HbA1c at baseline visit was 7.5% (SD 1.3%). Before treatment, the mean BCVA was similar in two groups (0.20 in Group A and 0.19 in Group B). Mean CMT was also similar (449 μm in Group A and 464 μm in Group B).

**Outcomes of the First Phase** Group A was effective in BCVA (*F*=5.88, *P*=0.004) and CMT (*F*=14.9, *P*<0.01). Group B was effective in CMT (*F*=3.70, *P*=0.03). BCVA of Group A (0.38±0.25) was different from Group B (0.23±0.22) after treatment 1wk (*t*=2.25, *P*=0.03). CMT of Group A

(310.20±96.60 μm) was also different from Group B after treatment 1wk (*t*=-3.06, *P*=0.003) (Table 2). It indicated that IV-Conbercept was better in visual improvement and promoting macular edema absorption in early stage. After treatment 1mo, there were no difference (*t*=1.84, *P*=0.07) in BCVA between Group A (0.37±0.24) and Group B (0.26±0.20). But there were different (*t*=-2.34, *P*=0.02) in CMT between Group A (304.1±84.7 μm) and Group B (366.0±115.4 μm). It indicated IV-Conbercept was better in promoting macular edema absorption in this phase than STTA, but not better in visual improvement.

**Outcomes of the Second Phase** Both Group A and Group B had continuous improvement in BCVA and CMT. In the last follow-up visit of this phase, BCVA of Group A (0.47±0.27) was different from baseline BCVA (*F*=0.26, *P*<0.01). CMT of Group A (260.67±62.97 μm) was different from baseline CMT (*F*=-188.3, *P*<0.01). BCVA of Group B (0.51±0.26) was different from baseline BCVA (*F*=0.31, *P*<0.01). CMT of Group B (261.93±50.15 μm) was different from baseline CMT (*F*=-201.9, *P*<0.01). It indicated that both two therapeutic schedules made visual improvement and promoting macular edema absorption. There were no difference (*P*>0.05) between two groups. It indicated that the difference of two therapeutic schedule affect BCVA and CMT little in this phase. Both Group A and Group B were effective, there were no difference either firstly using anti-VEGF or firstly using TA in this sequential therapy (Table 3).

**Table 3 Comparisons of BCVA and CMT for groups in the second phase**

Phase II		Group A	Group B	<i>t</i>	<i>P</i>	mean±SD
BCVA (median, 25% quartile)	1.25mo	0.43±0.28 (0.40, 0.15)	0.46±0.25 (0.40, 0.30)	-0.34	0.74	
	2mo	0.47±0.27 (0.50, 0.19)	0.51±0.26 (0.50, 0.30)	-0.61	0.55	
Compared with baseline	<i>F</i>	0.26	0.31	-	-	
	<i>P</i>	<0.01	<0.01	-	-	
CMT (µm)	1.25mo	281.73±81.89	269.36±60.10	0.65	0.52	
	2mo	260.67±62.97	261.93±50.15	-0.08	0.93	
Compared with baseline	<i>F</i>	-188.3	-201.9	-	-	
	<i>P</i>	<0.01	<0.01	-	-	

**Table 4 Comparisons of BCVA and CMT for groups in the third phase**

Phase III		Group A	Group B	<i>t</i>	<i>P</i>	mean±SD
BCVA (median, 25% quartile)	3mo	0.45±0.28 (0.40, 0.18)	0.48±0.26 (0.50, 0.30)	-0.41	0.69	
	6mo	0.42±0.25 (0.45, 0.14)	0.47±0.25 (0.50, 0.30)	-0.75	0.45	
Compared with baseline	<i>F</i>	0.22	-0.27	-	-	
	<i>P</i>	0.001	<0.01	-	-	
CMT (µm)	3mo	265.23±55.93	268.14±48.0	-0.21	0.83	
	6mo	267.8±58.34	272.71±49.16	-0.35	0.73	
Compared with baseline	<i>F</i>	-181.2	-191.1	-	-	
	<i>P</i>	<0.01	<0.01	-	-	

**Outcomes of the Third Phase** In follow-up 3 and 6mo, BCVA of Group A and Group B were both better than baseline data ( $F=0.22, P=0.001; F=-0.27, P<0.01$ ). CMT of the two groups were thinner than baseline data ( $F=-181.2, P<0.01; F=-191.1, P<0.01$ ). It indicated that the effect of laser-based strategies (sufficient PRP therapy)+IV-Conbercept+STTA sequential therapy could lasted to 6mo after treatment (Table 4).

**Trend Charts Analysis** According to the analysis of trend charts for two therapeutic schedules (Figures 2, 3), it indicated that use of Conbercept in Group A could improve vision and macular edema got absorbed quickly. The sequential therapy of STTA in phase II could maintain this therapy effect to the last visit 6mo later. If STTA was used first the therapy effect was relatively sluggish, but the sequential therapy of IV-Conbercept in phase II rapidly improved the outcomes and this trend was maintained till the last visit also. However, there was no difference in the final effect between two groups. PRP+IV-Conbercept+STTA sequential therapy could still be effective in the third phase without any other treatment.

**Complications** Each patient was given only one IV-Conbercept and twice STTA injections. This resulted in low and not severe complications. The main complications included: subconjunctival hemorrhage (7 eyes in Group A, 6 eyes in Group B), intraocular hypertension in short period (8 eyes in Group A, 10 eyes in Group B). The subconjunctival hemorrhage got absorbed spontaneously in one or two weeks. The intra ocular pressure was controlled in one or two days with or without anti-glaucoma drugs.

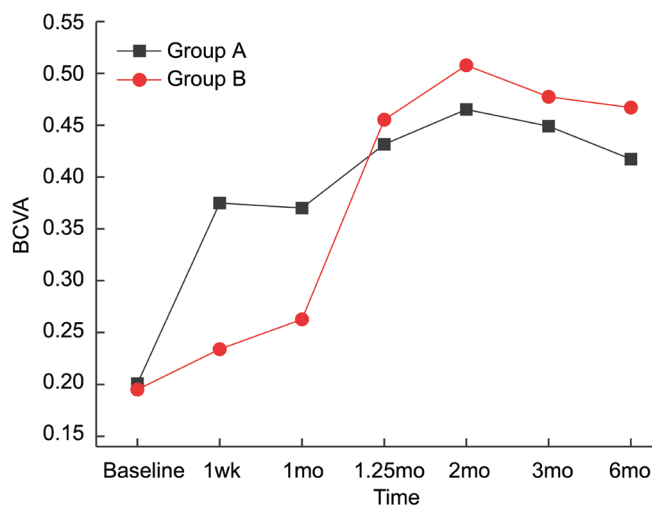


Figure 2 Trend chart of BCVA of Group A and Group B.

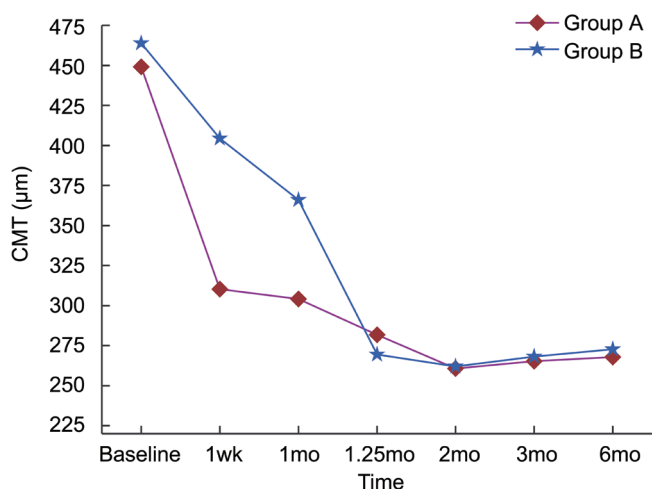


Figure 3 Trend chart of CMT of Group A and Group B.

## DISCUSSION

Macular edema can occur in any stage of DR, either nonproliferative or proliferative retinopathy<sup>[6]</sup>. It is difficult to deal with when DME in PDR stage<sup>[13-15]</sup>, particularly in PDR having been treated with PRP<sup>[16]</sup>. This kind of DME sometimes was called refractory DME<sup>[17]</sup>. We designed this clinical research with laser-based strategies (sufficient PRP therapy) and IV-Conbercept+STTA sequential therapy to explore a minimally invasive, low cost and easy processing new therapy for this kind of DME.

Firstly, sufficient PRP therapy is the base of all the treatment in PDR, including PDR after PPV<sup>[18]</sup>. There is improved oxygen supply to areas of inner retina that had become oxygen-deprived because of poor perfusion of inner retinal vessels after PRP<sup>[19]</sup>. As a result, there is a decreasing number of viable hypoxic cells in the inner retina producing VEGF and other growth factors. The new vessels generally regress and may disappear altogether, without continuous production of VEGF, although stabilization of the neovascularization with no further growth also may occur<sup>[20]</sup>. DME may occur before or after PRP in PDR, even worsen in some cases after panretinal treatment<sup>[21]</sup>. So pharmacotherapy with anti-VEGF or glucocorticoids sequential therapy should be used to alleviate macular edema.

VEGF inhibitors are powerful means for DME. It was hypothesized that alternative or adjunct therapies using VEGF inhibitors could be beneficial in reversing vision loss from macular edema, as observing that VEGF intraocular levels are increased in DME<sup>[7,11]</sup>. The VEGF family consists of VEGF-A, VEGF-B, VEGF-C, VEGF-D and placental growth factor (PlGF). They are potent vasopermeability factors and play key roles in pathogenesis of DME<sup>[22-23]</sup>.

Although there are several anti-VEGF drugs that target the VEGF molecule, such as direct inhibitors of the VEGF molecule including the anti-VEGF aptamer pegaptanib (Macugen; OSI Pharmaceuticals, Long Island, NY, USA)<sup>[24]</sup>, the monoclonal antibody fragment ranibizumab (Lucentis; Genentech, South San Francisco, CA, USA)<sup>[25]</sup>, and the full-length antibody bevacizumab (Avastin; Genentech)<sup>[26]</sup>. Other anti-VEGF molecules include soluble VEGF receptor analogs, VEGF-Trap (Regeneron, Tarrytown, NY, USA)<sup>[27]</sup>, and small interfering RNAs bevasiranib (Opko Health, Miami, FL, USA) and rapamycin (Sirolimus, MacuSight, Union City, CA, USA). Soluble protein that contains extracellular VEGFR-1, VEGFR-2 sequences fused to the Fc domain of a human immunoglobulin-G1 molecule including Aflibercept (Eylea; Regeneron, Tarrytown, NY, USA; and Bayer, Leverkusen, Germany)<sup>[28-30]</sup> and Conbercept (KH902; Chengdu Kanghong Biotech Co., Ltd., Sichuan, China)<sup>[29]</sup>. But only Conbercept is a new medicine of China. The effect of it on DME in PDR has not been previously reported.

We choose Conbercept to treat DME because of not only its antiangiogenic effect and but also its low price in China. It is a humanized, soluble, VEGFR protein which comprises extracellular domain 2 of VEGFR-1 and extracellular domains 3 and 4 of VEGFR-2, all of which are combined with the Fc region of human immunoglobulin G1 simultaneously<sup>[31]</sup>. The structural difference between Conbercept and Aflibercept is that Conbercept also contains the fourth binding domain of VEGFR-2. This fourth domain is essential for receptor dimerization and enhances the association rate of VEGF to the receptor<sup>[32]</sup>. Previous studies have demonstrated that extracellular domain 4 of VEGFR-2 can enhance the three-dimensional structure and efficiently advance dimerization<sup>[33-35]</sup>. Also, preclinical studies have presented higher affinity of Conbercept for VEGF than bevacizumab<sup>[36]</sup>. Moreover, recent phase 1 (HOPE)<sup>[37]</sup> and phase 2 (AURORA)<sup>[38]</sup> studies have shown an antiangiogenic effect of KH902 for choroidal neovascularization caused by age-related macular degeneration.

Another drug for DME in our research was TA, which is a long-acting corticosteroid. The corticosteroids are anti-inflammatory agents that stabilize retinal capillaries and tend to reduce their permeability by enhancing the activity or density of the tight junctions in the retinal capillary endothelium<sup>[4,13]</sup>. In addition, they inhibit and downregulate the metabolic VEGF pathway to decrease the leakage of plasma proteins into the interstitial tissue compartment and to help restore the osmotic gradient between blood and tissue compartments, which eventually resolves the edema<sup>[39]</sup>. Subtenon's capsule injection of corticosteroids is an established method for the treatment of various inflammatory eye diseases and offers a good therapeutic response and ocular tolerance. Its prolonged therapeutic effect has provided ophthalmologists with an alternative tool for the treatment of different diseases. There are several recent reports on the effectiveness of intravitreal or posterior STTA treatment for reducing macular thickness in DME<sup>[14,40]</sup>. We choose the way of posterior subtenon's injection in order to avoid the main drawbacks of IV injections, which are potential retinal toxicity, invasive characteristics of the treatment, need for recurrent injections, and risk of endophthalmitis, cataract progression, and elevated IOP<sup>[41]</sup>.

Both PRP with only anti-VEGF and PRP with only glucocorticoids may give help for DME, but the therapeutic effect can not last long. These points have been discussed in documents. In this cross-over designed randomized controlled trial (RCT), we have further demonstrated that PRP+only anti-VEGF was better than PRP+only STTA in phase I: IV-Conbercept was better in promoting macular edema absorption than STTA.

Furthermore, PRP+anti-VEGF+STTA sequential therapy showed an excellently persistent effectiveness on anatomical

as well as functional status for DME in phase II and phase III. This sequential therapy, abiding by minimally invasive principle, every patient accepted only once IV and twice subtenon's injections, the rate of complications was low, and no serious complication happened. The deficiencies of two drugs were remedied and the merits were strengthened by each other. All of the above made the final therapeutic effect enhanced and side effect reduced. In last two phases, the difference of two therapeutic schedule became little, both groups had continuous improvement in BCVA and CMT. In follow up to 6mo, compared with baseline data, BCVA of IV-Conbercept were  $0.42 \pm 0.25$  ( $F=0.22$ ,  $P=0.001$ ). CMT of IV-Conbercept  $267.8 \pm 58.34 \mu\text{m}$  ( $F=-181.2$ ,  $P<0.01$ ); BCVA of STTA were  $0.47 \pm 0.25$  ( $F=-0.27$ ,  $P<0.01$ ). CMT of STTA  $272.71 \pm 49.16 \mu\text{m}$  ( $F=-191.1$ ,  $P<0.01$ ).

The pathophysiology of DME is complex, involving VEGF and other inflammatory mediators<sup>[42]</sup>. Corticosteroids decrease inflammatory cytokines and have a modest anti-VEGF effect, while anti-VEGF agents have a modest anti-inflammatory effect. Using a corticosteroid in combination with an anti-VEGF agent allows the patient to benefit with increased efficacy as well as increased duration of effect<sup>[5]</sup>. The sequential therapy reduced DME with both anti-VEGF and anti-inflammatory effect. The progress of PDR was inhibited by PRP treatment and macular edema was improved by reducing permeability of retinal capillary endothelium with Conbercept and TA. In this RCT, PRP+IV-Conbercept+STTA sequential therapy could maintain effective even in the third phase without any other treatment.

So we can draw a conclusion that the strategy meets the requirements of minimally invasive, low cost and easy processing principles. It made visual improvement and promoting macular edema absorption, and no serious complication happened. As relative less patients and short follow-up time, more long term multi-center RCTs are needed to confirm our conclusions.

#### ACKNOWLEDGEMENTS

**Foundation:** Supported by the Health and Family Planning Commission of Sichuan Province (No:17PJ536).

**Conflicts of Interest:** Qiao G, None; Dong WJ, None; Dai Y, None; Jiang ZH, None; Guo HK, None.

#### REFERENCES

- 1 Lee R, Wong TY, Sabanayagam C. Epidemiology of diabetic retinopathy, diabetic macular edema and related vision loss. *Eye Vis (Lond)* 2015;2:17.
- 2 Ting DS, Cheung GC, Wong TY. Diabetic retinopathy: global prevalence, major risk factors, screening practices and public health challenges: a review. *Clin Exp Ophthalmol* 2016;44(4):260-277.
- 3 Nentwich MM, Ulbig MW. Diabetic retinopathy-ocular complications of diabetes mellitus. *World J Diabetes* 2015;6(3):489-499.
- 4 Gardlik R, Fusekova I. Pharmacologic therapy for diabetic retinopathy.

- Semin Ophthalmol* 2015;30(4):252-263.
- 5 Singer MA, Kermany DS, Waters J, Jansen ME, Tyler L. Diabetic macular edema: it is more than just VEGF. *F1000Res* 2016;5.
- 6 Das A, McGuire PG, Rangasamy S. Diabetic macular edema: Pathophysiology and novel therapeutic targets. *Ophthalmology* 2015; 122(7):1375-1394.
- 7 Mehta H, Gillies MC, Fraser-Bell S. Combination of vascular endothelial growth factor inhibitors and laser therapy for diabetic macular oedema: a review. *Clin Exp Ophthalmol* 2016;44(4):335-339.
- 8 Ruiz-Moreno JM. New perspectives in the approach to diabetic macular edema. Aflibercept therapy. *Arch Soc Esp Ophthalmol* 2015;90 Suppl 1:24-28.
- 9 Au A, Singh RP. A multimodal approach to diabetic macular edema. *J Diabetes Complicat* 2016;30(3):545-553.
- 10 Romero-Aroca P. Is laser photocoagulation treatment currently useful in diabetic macular edema? *Med Hypothesis Discov Innov Ophthalmol* 2015;4(1):5-8.
- 11 Lally DR, Shah CP, Heier JS. Vascular endothelial growth factor and diabetic macular edema. *Surv Ophthalmol* 2016;61(6):759-768.
- 12 Barquet LA. Role of VEGF in diseases of the retina. *Arch Soc Esp Ophthalmol* 2015;90 Suppl 1:3-5.
- 13 Yang Y, Bailey C, Loewenstein A, Massin P. Intravitreal corticosteroids in diabetic macular edema: pharmacokinetic considerations. *Retina* 2015;35(12):2440-2449.
- 14 Yolcu U, Ilhan A. Effect of posterior subtenon injection of 40 mg of triamcinolone acetonide on glycemic control and serum cortisol and adrenocorticotropic hormone in diabetic patients. *Eur Rev Med Pharmacol Sci* 2015;19(1):1.
- 15 Sharma T, Fong A, Lai TY, Lee V, Das S, Lam D. Surgical treatment for diabetic vitreoretinal diseases: a review. *Clin Exp Ophthalmol* 2016;44(4):340-354.
- 16 Hussain RM, Ciulla TA. Treatment strategies for refractory diabetic macular edema: switching anti-VEGF treatments, adopting corticosteroid-based treatments, and combination therapy. *Expert Opin Biol Ther* 2016;16(3):365-374.
- 17 Martidis A, Duker JS, Greenberg PB, Rogers AH, Puliafito CA, Reichel E, Bauman C. Intravitreal triamcinolone for refractory diabetic macular edema. *Ophthalmology* 2002;109(5):920-927.
- 18 Bressler NM, Beck RW, Ferris FL 3rd. Panretinal photocoagulation for proliferative diabetic retinopathy. *N Engl J Med* 2011;365(16):1520-1526.
- 19 Park YG, Kim EY, Roh YJ. Laser-based strategies to treat diabetic macular edema: history and new promising therapies. *J Ophthalmol* 2014;2014:769213.
- 20 Romero-Aroca P, Reyes-Torres J, Baget-Bernaldiz M, Blasco-Sune C. Laser treatment for diabetic macular edema in the 21st century. *Curr Diabetes Rev* 2014;10(2):100-112.
- 21 Mitchell P, Wong TY. Management paradigms for diabetic macular edema. *Am J Ophthalmol* 2014;157(3):505-513.
- 22 Lazic R, Lukic M, Boras I, Draca N, Vlasic M, Gabric N, Tomic Z. Treatment of anti-vascular endothelial growth factor-resistant diabetic macular edema with dexamethasone intravitreal implant. *Retina* 2014;34(4):719-724.

- 23 Nepomuceno AB, Takaki E, Paes de Almeida FP, Peroni R, Cardillo JA, Siqueira RC, Scott IU, Messias A, Jorge R. A prospective randomized trial of intravitreal bevacizumab versus ranibizumab for the management of diabetic macular edema. *Am J Ophthalmol* 2013;156(3):502-510.
- 24 Sultan MB, Zhou D, Loftus J, Dombi T, Ice KS. A phase 2/3, multicenter, randomized, double-masked, 2-year trial of pegaptanib sodium for the treatment of diabetic macular edema. *Ophthalmology* 2011;118(6):1107-1118.
- 25 Zhang H, Liu ZL, Sun P, Gu F. Intravitreal bevacizumab for treatment of macular edema secondary to central retinal vein occlusion: Eighteen-month results of a prospective trial. *J Ocul Pharmacol Ther* 2011;27(6):615-621.
- 26 Wahab S, Ahmed J. Management of cataract with macular oedema due to diabetes mellitus type-II and hypertension with grid laser prior to surgery and intra-vitreous bevacizumab (Avastin) peroperatively. *J Pak Med Assoc* 2010;60(10):836-839.
- 27 Do DV, Schmidt-Erfurth U, Gonzalez VH, Gordon CM, Tolentino M, Berliner AJ, Vitti R, Ruckert R, Sandbrink R, Stein D, Yang K, Beckmann K, Heier JS. The DA VINCI Study: Phase 2 primary results of VEGF Trap-Eye in patients with diabetic macular edema. *Ophthalmology* 2011;118(9):1819-1826.
- 28 Sarwar S, Clearfield E, Soliman MK, Sadiq MA, Baldwin AJ, Hanout M, Agarwal A, Sepah YJ, Do DV, Nguyen QD. Aflibercept for neovascular age-related macular degeneration. *Cochrane Database Syst Rev* 2016;2:CD011346.
- 29 Su L, Ren X, Wei H, Zhao L, Zhang X, Liu J, Su C, Tan L, Li X. Intravitreal conbercept (KH902) for surgical treatment of severe proliferative diabetic retinopathy. *Retina* 2016;36(5):938-943.
- 30 Schwartz SG, Flynn HW Jr, Scott IU. Emerging drugs for diabetic macular edema. *Expert Opin Emerg Drugs* 2014;19(3):397-405.
- 31 Wang Q, Li T, Wu Z, Wu Q, Ke X, Luo D, Wang H. Novel VEGF decoy receptor fusion protein conbercept targeting multiple VEGF isoforms provide remarkable anti-angiogenesis effect in vivo. *PLoS One* 2013;8(8):e70544.
- 32 Wu Z, Zhou P, Li X, Wang H, Luo D, Qiao H, Ke X, Huang J. Structural characterization of a recombinant fusion protein by instrumental analysis and molecular modeling. *PLoS One* 2013;8(3):e57642.
- 33 Wang F, Bai Y, Yu W, Han N, Huang L, Zhao M, Zhou A, Zhao M, Li X. Anti-angiogenic effect of KH902 on retinal neovascularization. *Graefes Arch Clin Exp Ophthalmol* 2013;251(9):2131-2139.
- 34 Chen X, Li J, Li M, Zeng M, Li T, Xiao W, Li J, Wu Q, Ke X, Luo D, Tang S, Luo Y. KH902 suppresses high glucose-induced migration and sprouting of human retinal endothelial cells by blocking VEGF and PIGF. *Diabetes Obes Metab* 2013;15(3):224-233.
- 35 Li Y, Deng YP, Zhang M, Tang J, Meng D. An experimental study on inhibition effects of KH902 on rat corneal neovascularization. *Sichuan Da Xue Xue Bao Yi Xue Ban* 2013;44(1):64-67.
- 36 Nguyen TT, Guymer R. Conbercept (KH-902) for the treatment of neovascular age-related macular degeneration. *Expert Rev Clin Pharmacol* 2015;8(5):541-548.
- 37 Zhang M, Zhang J, Yan M, Luo D, Zhu W, Kaiser PK, Yu DC. A phase 1 study of KH902, a vascular endothelial growth factor receptor decoy, for exudative age-related macular degeneration. *Ophthalmology* 2011;118(4):672-678.
- 38 Li X, Xu G, Wang Y, Xu X, Liu X, Tang S, Zhang F, Zhang J, Tang L, Wu Q, Luo D, Ke X. Safety and efficacy of conbercept in neovascular age-related macular degeneration: results from a 12-month randomized phase 2 study: AURORA study. *Ophthalmology* 2014;121(9):1740-1747.
- 39 Ozkurt YB, Akkaya S, Aksoy S, Evciman T, Haboglu M. Posterior subtenon's capsule triamcinolone acetonide injection for the treatment of diabetic macular edema. *J Ocul Pharmacol Ther* 2015;31(8):455-460.
- 40 Oshitari T, Nonomura S, Arai M, Takatsuna Y, Sato E, Baba T, Yamamoto S. Effects of sub-Tenon's capsule triamcinolone acetonide injection combined with microaneurysm photocoagulation on diabetic macular edema. *Int Med Case Rep J* 2015;8:321-326.
- 41 O'Day RF, Barthelmes D, Zhu M, Wong TY, McAllister IL, Arnold JJ, Gillies MC. Intraocular pressure rise is predictive of vision improvement after intravitreal triamcinolone acetonide for diabetic macular oedema: a retrospective analysis of data from a randomised controlled trial. *BMC Ophthalmol* 2014;14:123.
- 42 Schwartz SG, Flynn HW Jr, Scott IU. Intravitreal corticosteroids in the management of diabetic macular edema. *Curr Ophthalmol Rep* 2013;1(3).