

Incidence of cystoid macular edema after Descemet's stripping automated endothelial keratoplasty

Eduard Pedemonte-Sarrias^{1,2,3}, Toni Salvador Playà¹, Irene Sassot Cladera¹, Oscar Gris^{3,4}, Joan Ribas Martínez⁵, José García-Arumí^{3,4,6}, Núria Giménez^{7,8}

¹Ophthalmology Department, Hospital Universitari MútuaTerrassa, Fundació Docència i Recerca MútuaTerrassa, Universitat de Barcelona, Terrassa 08221, Spain

²Ophthalmology Department, Hospital Universitari Germans Trias i Pujol, Health Sciences Research Institute Germans Trias i Pujol Foundation, Badalona 08930, Spain

³Surgery Department, Universitat Autònoma de Barcelona, Barcelona 08035, Spain

⁴Instituto de Microcirugía Ocular (IMO), Barcelona 08035, Spain

⁵Ophthalmology Department, Hospital Sant Antoni Abat, Vilanova i la Geltrú 08800, Spain

⁶Ophthalmology Department, Hospital Universitari Vall d'Hebron, Universitat Autònoma de Barcelona, Barcelona 08035, Spain

⁷Research Unit, Fundació Docència i Recerca MútuaTerrassa, Universitat de Barcelona, Terrassa 08221, Spain

⁸Laboratory of Toxicology, Universitat Autònoma de Barcelona, Bellaterra 08193, Spain

Correspondence to: Eduard Pedemonte-Sarrias. Ophthalmology Department, Hospital Universitari MútuaTerrassa, Pl. Doctor Robert 5, Terrassa, Barcelona 08221, Spain. eduard@pedemontesarrias.com

Received: 2017-03-03 Accepted: 2017-03-31

Abstract

• **AIM:** To determine the incidence of cystoid macular edema (CME) after Descemet's stripping automated endothelial keratoplasty (DSAEK).

• **METHODS:** This study included all consecutive patients operated in a Spanish tertiary reference hospital over a period of four years. A total of 55 eyes from 47 patients matched the selection criteria. CME was diagnosed clinically at the slit-lamp and confirmed by optical coherence tomography.

• **RESULTS:** Six cases of CME were diagnosed postoperatively, which represented an incidence of 11%. Three patients had previously undergone DSAEK alone (7%; 3/41) and the other three, DSAEK combined with phacoemulsification (21%; 3/14). Five out of six patients with CME responded to standard therapy.

• **CONCLUSION:** CME is a possible complication after DSAEK and can be treated with standard therapy. CME appears more frequently when DSAEK is combined with phacoemulsification and posterior chamber (PC) intraocular lens (IOL) implantation. Intraoperative damage to the corneal endothelial cells might play a role in the pathogenesis of CME. As long as the causes remain unclear, we recommend administering prophylaxis when risk factors are present or when combined surgery is planned.

• **KEYWORDS:** Descemet membrane endothelial keratoplasty; Descemet stripping automated endothelial keratoplasty combined with phacoemulsification; Descemet stripping endothelial keratoplasty; macular edema; postoperative complications

DOI:10.18240/ijo.2017.07.10

Pedemonte-Sarrias E, Salvador Playà T, Sassot Cladera I, Gris O, Ribas Martínez J, García-Arumí J, Giménez N. Incidence of cystoid macular edema after Descemet's stripping automated endothelial keratoplasty. *Int J Ophthalmol* 2017;10(7):1081-1087

INTRODUCTION

Descemet's stripping automated endothelial keratoplasty (DSAEK) and Descemet membrane endothelial keratoplasty (DMEK) are currently considered the standard treatment for cases of endothelial compromise or failure. DSAEK can also be associated to other procedures, most commonly phacoemulsification^[1-2]. The most commonly reported complications after DSAEK are: graft dislocation^[3-5], graft rejection^[3], graft failure^[3,6] and pupillary block^[3]. Most cases are related to the graft or the anterior segment of the eye. Few complications involving the posterior segment have been reported. Postoperative cystoid macular edema (CME) has been rarely reported as a complication of DSAEK alone^[4-5,7] or combined with transscleral intraocular lens (IOL) suture^[8], but not as a primary complication of DSAEK associated to phacoemulsification^[1-2]. The incidence of postoperative CME has been assessed for penetrating keratoplasty (PKP), deep anterior lamellar keratoplasty (DALK)^[9] and DMEK^[10-12], alone or combined; and very recently after DSAEK^[8,13].

The main purpose of this study is to determine the incidence of CME after DSAEK. Secondly, we aim to compare the incidence of CME after DSAEK alone and combined with phacoemulsification.

SUBJECTS AND METHODS

Protocol The series included all consecutive patients who had undergone DSAEK surgery at a cornea reference tertiary hospital between February 2008 and December 2012. During this period, DSAEK was the surgery of choice for most of the eyes with corneal endothelial pathology at our hospital. Exclusion criteria were: previous intraocular surgery other than phacoemulsification with posterior chamber (PC) IOL implantation, prior keratoplasty and previous history of ocular trauma, uveitis, congenital glaucoma and/or macular cystoid edema. Macular pathology was screened biomicroscopically before surgery, when possible. Fifty-five eyes (47 patients) matched the criteria.

Clinical registers from all patients were reviewed in order to collect the following data, when available: age, sex, pathological and ocular history, previous visual acuity (VA), intraoperative and postoperative complications, postoperative medical treatment, appearance of postoperative CME, suture removal time, postoperative best-corrected visual acuity (BCVA), reject events and follow-up time. VA was measured using the Snellen optotypes chart. All cases of CME after surgery were diagnosed clinically at the slit-lamp and confirmed by optical coherence tomography (OCT; Cirrus; Carl Zeiss Meditec AG, Jena, Germany). The present study was done in accordance with the Review Board and Ethics Committee of Hospital Universitari MútuaTerrassa (Terrassa, Barcelona, Spain) and the Declaration of Helsinki of 2013, and registered at clinicaltrials.gov (NCT02470793).

Surgical Technique All surgery was performed consecutively at Hospital Universitari MútuaTerrassa, both solo or assisted, by two cornea specialist surgeons (Salvador Playà T; Sassot Cladera I) following the same standard procedures. When possible, the eyes underwent an Nd:YAG laser inferior iridotomy at least one month prior to surgery. If not, a peripheral iridectomy (PI) was done at the beginning of the surgery.

All donor tissues were large corneoscleral rims supplied by the regional tissue bank (Banc de Sang i Teixits, Barcelona, Spain) or the Banc d'Ulls (Clínica Barraquer, Barcelona, Spain). The donor tissue had been stored under conservation solution EUSOL-C (Alchimia Srl; Ponte San Nicolò, Italy). Before the incision, the donor's endothelial side was protected by 2.4% Hypromellose (Medio Clear 2.4%; Medio-Haus Medizinprodukte GmbH, Kiel, Germany). When planned, phacoemulsification was initially performed using 1.2% Sodium Hyaluronate (Amvisc; Bausch & Lomb Inc.; Rochester, NY, USA) for the entire procedure and a PC

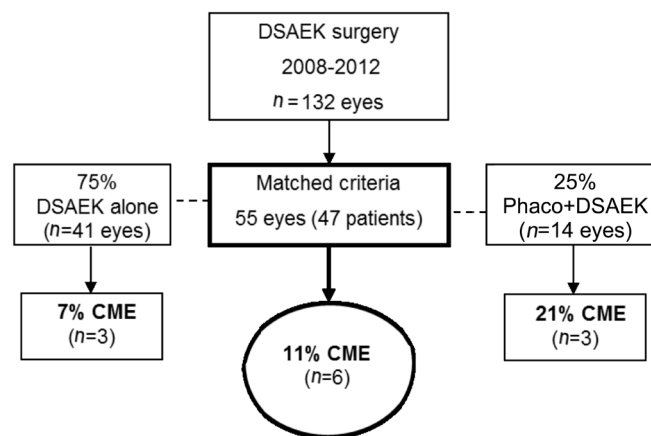


Figure 1 Cystoid macular edema incidence flowchart.

IOL was implanted into the capsular bag (EC-1 HPI; Aaren Scientific Inc.; Ontario, CA. or Akreos Adapt Bausch & Lomb Inc.).

Different microkeratome heads were used depending on the donor cornea pachymetry. The 350 μm head was used in 88% of the cases (300 μm , 2%; 250 μm , 10%). In all cases, the graft was implanted using Ringer lactate solution (Grifols SA; Parets del Vallès, Spain) with the pull-through technique.

Postoperative Care Patients remained in supine position for an hour after surgery and were instructed to face up as long as possible until the next day. They instilled a topical association of dexamethasone 1 mg/mL and tobramycin 3 mg/mL (Tobradex; Alcon Cusí, El Masnou, Spain) every four hours daily, which was tapered progressively. One month after surgery, tapering was continued with prednisolone 10 mg/mL (Pred-Forte; Allergan; Tres Cantos, Spain).

Statistical Analysis Qualitative variables were expressed as number and percentage; whereas quantitative variables were expressed as mean and standard deviation (SD) or as median and range, if they followed a non-parametrical distribution. For qualitative variable comparison, the Chi-squared test or Fisher's exact test was used. For mean comparison, the Student's *t*-test or its non-parametrical equivalent, the Mann-Whitney *U* test, was used. Statistical significance was predetermined at a *P*-value smaller than 0.05 (two-tailed). Statistical analysis was performed using SPSS 17.0 (SPSS Inc., Chicago, IL, USA).

RESULTS

As shown in Figure 1, 55 eyes (from 47 patients) out of the 132 eyes operated of DSAEK between 2008 and 2012, matched the selection criteria. The incidence of CME was 11% ($n=6$). The subgroup analysis revealed a 7% incidence after DSAEK alone, and a 21% after combined DSAEK.

Population main characteristics, the diagnosis indicating surgery and follow-up data are displayed on Table 1. Statistically significant differences in age and sex were found between the patients operated of DSAEK alone or combined DSAEK.

Table 1 Population characteristics, diagnosis and follow-up

Parameters	Total (n=55)	DSAEK (n=41)	Phaco+DSAEK (n=14)	n (%)
Characteristics				
Eyes	55 (100)	41 (75)	14 (25)	
Right eye,	31 (56)	25 (61)	6 (43)	
Patients, n	47	37	11	
Age (a, mean±SD ¹)	74±10	76±10	69±9	
Men ¹	20 (36)	18 (44)	2 (14)	
Diagnosis				
Fuchs' endothelial dystrophy	37 (67)	24 (59)	13 (93)	
Pseudophakic bullous keratopathy	13 (24)	13 (32)	-	
Unclassified endothelial decompensation	3 (6)	2 (5)	1 (7)	
Posterior polymorphous dystrophy	1 (2)	1 (2)	-	
Iridocorneal endothelial syndrome	1 (2)	1 (2)	-	
Follow-up (wk)				
Minimum	8	9	8	
Mean	58±40	58±41	57±37	
No. of follow-up controls	8±3	8±3	8±3	
Suture extraction	6±6	6±5	8±11	
BCVA measurement time	23±20	20±17	30±25	
Time between suture extraction and BCVA measurement	16±21	13±16	26±32	

Total: All eyes included; DSAEK: PC pseudophakic eyes operated of DSAEK alone; Phaco+DSAEK: Eyes operated of DSAEK concurrent with phacoemulsification and PC IOL implantation; -: None; BCVA: Best corrected visual acuity; SD: Standard deviation. ¹Statistically significant differences.

Table 2 Preoperative and postoperative BCVA

BCVA	Total (n=55)		DSAEK (n=41)		Phaco+DSAEK (n=14)	
	Preop.	Postop.	Preop.	Postop.	Preop.	Postop.
BCVA (mean±SD)	0.23±0.18	0.49±0.28	0.22±0.17	0.44±0.25	0.28±0.22	0.66±0.30
BCVA intervals						
BCVA≤0.05	29%	11%	29%	12%	29%	7%
0.05 <BCVA≤0.32	44%	18%	47%	22%	35%	7%
0.32 <BCVA≤0.5	23%	33%	22%	37%	29%	22%
0.5 <BCVA≤0.7	4%	16%	2%	14%	7%	21%
0.7 <BCVA≤1.0	-	22%	-	15%	-	43%

Total: All eyes included; DSAEK: PC pseudophakic eyes operated of DSAEK alone; Phaco+DSAEK: Eyes operated of DSAEK concurrent with phacoemulsification and PC IOL implantation; Preop.: Preoperative; Postop.: Postoperative; BCVA: Best corrected visual acuity; SD: Standard deviation; -: None.

Fuchs' endothelial dystrophy was the most frequent diagnosis. Pseudophakic bullous keratopathy was the second most frequent indication for DSAEK alone. There was a minimum of 8wk follow-up, with a mean of 8 controls during more than a year (58wk).

Table 2 shows mean preoperative and postoperative BCVA, as well as the percentage of eyes in each BCVA interval. A total of 73% of the eyes had a BCVA less than 0.32 preoperatively; whereas after surgery, 71% were above 0.32 and 38% above 0.5. Table 3 registers intraoperative and postoperative complications. None of the eyes with intraoperative complications developed CME. Two eyes with postoperative complications developed

CME (Table 4, eyes No. 4 and 6). Two cases of rejection were registered. One patient was treated with subtenon triamcinolone 40 mg/mL (Trigon depot; Bristol-Myers Squibb; Madrid, Spain) and resolved one month later. The other patient needed a new DSAEK.

The diagnosis time, treatment and evolution of the CME cases are shown in Table 4. CME was diagnosed between the second week and the third month postoperatively. Eye No.4 had previously undergone a rebubbling and eye No.6 had developed a pupillary membrane. CME became chronic only in eye No.3. The rest were resolved between three weeks and six months.

Cystoid macular edema after DSAEK

Table 3 Intraoperative and postoperative registered complications

Complication	<i>n (%)</i>			
	All eyes (<i>n</i> =55)	DSAEK (<i>n</i> =41)	Phaco+DSAEK (<i>n</i> =14)	CME (<i>n</i> =6)
Intraoperative				
Irregular microkeratome cut	1 (1.8)	-	1	-
Peripheral button hole in donor graft	1 (1.8)	1	-	-
High graft manipulation	3 (5.5)	2	1	-
Incomplete graft unfolding	1 (1.8)	1	-	-
Iris-graft contact	1 (1.8)	1	-	-
Iris damage/haemorrhage ¹	3 (5.5)	3	-	-
Early graft detachment+Interface liquid drainage	1 (1.8)	1	-	-
Subtotal	11 (20)	9	2	-
Postoperative				
High IOP	3 (5.5)	3	-	-
Graft detachment (rebubbling)	5 (9.1)	4	1	1
Graft decentration	1 (1.8)	-	1	-
Acute conjunctivitis	1 (1.8)	1	-	-
Pupillary block	1 (1.8)	1	-	-
Pupillar membrane	1 (1.8)	-	1	1
Macular haemorrhage	1 (1.8)	1	-	-
Primary graft failure	2 (3.6)	1	1	-
Rejection	2 (3.6)	2	-	-
Subtotal	17 (30.9)	13	4	2

All eyes: Eyes that had the complication; DSAEK: PC pseudophakic eyes operated of DSAEK alone; Phaco+DSAEK: Eyes operated of DSAEK concurrent with phacoemulsification and PC IOL implantation; CME: Number of eyes which had the complication and developed cystoid macular edema; -: None; Subtotal: Number of eyes with complications for each category (*i.e.* intraoperative or postoperative). ¹In one case, interface blood.

Table 4 Cystoid macular edema diagnosis time, treatment and evolution

Patients No.	DSAEK			Phaco+DSAEK		
	1	2	3	4	5	6
Preoperative diagnosis	Fuchs' dystrophy	Pseudophakic bullous keratopathy	Fuchs' dystrophy	Fuchs' dystrophy	Fuchs' dystrophy	Fuchs' dystrophy
Diagnosis (days after surgery)	29	64	15	15	29	90
Treatment	Topical NSAID ^a	Topical NSAID ^c	Topical NSAID ^{a,c} Topical CS ^b Subtenon CS ^d	Topical NSAID ^e Topical CS ^b	Subtenon CS ^e	Topical NSAID ^a Subtenon CS ^d
Resolution (weeks after diagnosis)	12	3	- (×3) PPV	24	7	4

DSAEK: PC pseudophakic eyes operated of DSAEK alone; Phaco+DSAEK: Eyes operated of DSAEK concurrent with phacoemulsification and PC IOL implantation; Total: All eyes included; NSAID: Non-steroidal anti-inflammatory drug; CS: Corticosteroid; PPV: Pars plana vitrectomy. ^aKetorolac 5 mg/mL (Acular; Allergan; Tres Cantos, Spain); ^bPrednisolone 10 mg/mL (Pred-Forte; Allergan; Tres Cantos, Spain); ^cBromfenac 0.9 mg/mL (Yellox; Croma-Pharma; Leobendorf, Austria); ^dTriamcinolone 40 mg/mL (Trigon depot; Bristol-Myers Squibb; Madrid, Spain); ^eDiclofenac 1 mg/mL (Dicloabak; Théa; Clermont-Ferrand, France).

DISCUSSION

To our knowledge, this is the second time that the incidence of CME after DSAEK was specifically assessed^[13]. It is the first time, to our knowledge, that CME has been reported following DSAEK concurrent with phacoemulsification and its incidence

compared to DSAEK alone.

Until recently, CME as a complication of DSAEK had been rarely reported in published series (2%-5%)^[4-5]. Unfortunately, the authors did not specify if the eyes which developed CME had undergone any other concurrent procedure apart from

DSAEK. In both series, corticosteroids were applied four times daily after surgery and were progressively tapered, which is equivalent to our postoperative care. These results are close to our 7% results after DSAEK alone, but they are less than half our global 11% incidence, mainly due to a higher incidence in the eyes with concurrent phacoemulsification.

More recently, Kitazawa *et al*^[13] have reported an incidence of CME of 12.7% after DSAEK alone, which was higher in glaucoma-related eyes (20.4%). In a retrospective series where they assessed the clinical outcomes and complications of DSAEK combined with transscleral IOL suture, Yazu *et al*^[8] reported an incidence of 1.4% after DSAEK alone and 11% after DSAEK combined with transscleral IOL suture.

Our data indicated that the incidence of clinical CME after DSAEK alone in previously PC pseudophakic eyes (7%) was higher than following modern uncomplicated phacoemulsification, which was likely to range from 0.1% to 2.35%^[14-15], and PKP^[9]. It has been proposed that the principal cause of pseudophakic CME, also called Irvine-Gass syndrome^[16], is inflammation induced by surgical manipulation, although the exact pathogenesis remains uncertain. Although investigating the cause of CME after DSAEK was not the aim of our study, we considered that the pathophysiology of CME after DSAEK was probably similar to Irvine-Gass syndrome.

When DSAEK was associated to phacoemulsification, CME was three-fold more frequent and much more frequent than expected after plain phacoemulsification. This suggests phacoemulsification promotes the development CME, as other authors have proved^[17-18], and that the higher incidence of CME after DSAEK might be related to some of the stages in endothelial transplantation: descemetorhexis, graft implantation and air tamponade.

When present, all cases of CME but one responded to standard therapy for pseudophakic CME^[19]. The poor response to the treatment of one of the eyes suggests that CME might have been present prior to the surgery. In that particular case, the macula could not be evaluated preoperatively due to corneal opacity. Six eyes where an increased risk of developing CME was suspected received pharmacological prophylaxis intra- and/or postoperatively. Two eyes belonged to diabetic patients, another had developed CME after DSAEK in the fellow eye and the others received it according to surgeon's criteria. The administered drugs were topical non-steroidal anti-inflammatory drugs (NSAID) and/or subconjunctival methylprednisolone. Although it was administered to very few eyes, prophylaxis against CME^[20] proved to be effective, as recently suggested by other authors^[8,12].

Our study has some limitations. In this retrospective study, all eyes with previous macular pathology were excluded. Nevertheless, the effect of previous phacoemulsification on central macular thickness (CMT) in pseudophakic eyes cannot

be completely excluded. Most of the CME were diagnosed after clinical suspicion and in many cases, macular OCT was performed because the VA was lower than expected. As there was no OCT screening for all patients, some clinically irrelevant cases could have resolved unnoticed and the incidence of CME could be actually higher. Only fourteen eyes with combined DSAEK matched selection criteria. Although this rendered the samples asymmetrical, we consider the results of the alone versus combined DSAEK comparison are still valuable. The difference in age between the two groups was expected beforehand, as the evolution of senile cataract and subsequent need for phacoemulsification correlate with age. The VA improvement in our series is similar to other authors, but we had a lower rate of graft detachment, primary graft failure and pupillary block^[1,3-6]. It would have been useful to have conducted a larger prospective series with OCT measurements and controls. Nevertheless, this study provides a first approach to the study of CME as a postoperative complication of DSAEK, which we aim to expand in the future.

The closest procedure to DSAEK is DMEK. They differ in the graft preparation and a more challenging graft unfolding in DMEK. Despite these differences, we consider the incidence of CME after DSAEK should be similar to DMEK's. Recently, the incidence of CME after DMEK has been specifically assessed; alone (7.5%-12.5%)^[10-11] and associated to phacoemulsification (0-13.3%)^[10,12]. No cases were found when hourly topical prednisolone was administered for the first postoperative week^[12]. Heinzelmann *et al*^[10] reported an incidence of 13% for all eyes, which is very close to our 11%. Conversely, they found no differences with the eyes with concurrent cataract surgery. They pointed that the manipulation on the iris under intracameral air may be the cause of the high incidence of CME. In their series, they performed a PI at the end of surgery on all patients. Although most of our patients underwent an Nd:YAG laser iridotomy one month prior to surgery, the incidence of CME was similar. Furthermore, the data available indicate a lower impact on CMT of other surgeries with a higher impact on the iris, *via* an iridectomy (such as trabeculectomy^[21]) or pressure on the iris by gas (such as primary rhegmatogenous retinal detachment repair^[22]). The reason behind this difference remains unclear and suggests that iris damage might not be the main reason for the high rate of CME after endothelial keratoplasty. Moreover, some authors have described CME or a significant increase in CMT following DALK^[9,23], while other authors found no changes^[24]. These changes in CMT might be related to endothelial cell injury through Descemet's membrane during the surgery, due to its limited intraocular manipulation.

We hypothesize that corneal endothelial cell damage during three key steps of DSAEK might play a role in the pathogenesis of CME. First, the descemetorhexis provokes a

mechanical damage in the endothelial cell monolayer. Second, approximately 29%-37%^[25-26] of donor endothelial cells are lost during graft implantation. These cells are also transplanted within the graft and free cellular detritus and inflammatory substances into the receptor's aqueous humour. Finally, the exposure to air for more than six hours has a toxic effect for human corneal endothelial cells^[27]. The tamponade with air has shown a higher decrease in central endothelial cells density than the use of 20% sulphur hexafluoride (SF₆)^[28]. Future studies will confirm if this finding also correlates with a lower rate of postoperative CME when using 20% SF₆.

In summary, CME is a possible complication after DSAEK and responds to standard therapy for pseudophakic syndrome. It appears to be more frequent when concurrent with phacoemulsification and PC IOL implantation. As long as the causes remain unclear, we recommend providing prophylaxis when risk factors are present or when combined surgery is planned.

ACKNOWLEDGEMENTS

The authors thank Patricia Vigués Frantzen and Richard Medeiros-Rouen University Hospital Medical Editor, for their valuable help in revising the manuscript.

Presented at the 28th Congress of the Sociedad Española de Cirugía Ocular Implanto-Refractiva, May 15-18, 2013, Barcelona, Spain and the 32nd Congress of the European Society of Cataract and Refractive Surgery, September 13-17, 2014, London, United Kingdom.

Finalist of Primer Premi Resident Investigador (Resident's Research Award), Hospital Universitari MútuaTerrassa.

Authors' Contributions: Eduard Pedemonte-Sarrias: main investigator, literature search, study design, data gathering, statistical analysis, data interpretation, manuscript preparation, editing and submission; Toni Salvador Playà: study coordination, literature search, study design, surgery, data interpretation and manuscript revision; Irene Sassot Cladera: literature search, study design, surgery and manuscript revision; Oscar Gris: literature search, data interpretation and manuscript revision; Joan Ribas Martínez: literature search, data gathering and manuscript revision; José García-Arumí: literature search, data interpretation and manuscript revision; Núria Giménez: study coordination, study design, statistical analysis revision, data interpretation and manuscript revision.

Conflicts of Interest: Pedemonte-Sarrias E, None; Salvador Playà T, None; Sassot Cladera I, None; Gris O, None; Ribas Martínez J, None; García-Arumí J, None; Giménez N, None.

REFERENCES

1 Covert DJ, Koenig SB. New triple procedure: Descemet's stripping and automated endothelial keratoplasty combined with phacoemulsification and intraocular lens implantation. *Ophthalmology* 2007;114(7):1272-1277.

2 Terry MA, Shamie N, Chen ES, Phillips PM, Shah AK, Hoar KL, Friend DJ. Endothelial keratoplasty for Fuchs' dystrophy with cataract: complications and clinical results with the new triple procedure. *Ophthalmology* 2009;116(4):631-639.

3 Terry MA, Shamie N, Chen ES, Hoar KL, Friend DJ. Endothelial keratoplasty a simplified technique to minimize graft dislocation, iatrogenic graft failure, and pupillary block. *Ophthalmology* 2008;115(7):1179-1186.

4 Suh LH, Yoo SH, Deobhakta A, Donaldson KE, Alfonso EC, Culbertson WW, O'Brien TP. Complications of Descemet's stripping with automated endothelial keratoplasty: survey of 118 eyes at One Institute. *Ophthalmology* 2008;115(9):1517-1524.

5 Phillips PM, Phillips LJ, Much JW, Maloney C. Descemet stripping endothelial keratoplasty: six-month results of the first 100 consecutive surgeries performed solo by a surgeon using 1 technique with 100% follow-up. *Cornea* 2012;31(12):1361-1364.

6 Koenig SB, Covert DJ, Dupps WJ Jr, Meisler DM. Visual acuity, refractive error, and endothelial cell density six months after Descemet stripping and automated endothelial keratoplasty (DSAEK). *Cornea* 2007;26(6):670-674.

7 Kontadakis GA, Palioura S, Yoo SH. Wavelike interface opacities after Descemet-stripping automated endothelial keratoplasty: 7-year follow-up. *Eye Contact Lens* 2015.

8 Yazu H, Yamaguchi T, Dogru M, Ishii N, Satake Y, Shimazaki J. Descemet-stripping automated endothelial keratoplasty in eyes with transscleral-sutured intraocular lenses. *J Cataract Refract Surg* 2016;42(6):846-854.

9 Genevois O, Benzerroug M, Gardea E, Brasseur G, Muraine M. Macular edema after corneal graft: a prospective study by optical coherence tomography. *Cornea* 2007;26(6):683-684.

10 Heinzlmann S, Maier P, Bohringer D, Huther S, Eberwein P, Reinhard T. Cystoid macular oedema following Descemet membrane endothelial keratoplasty. *Br J Ophthalmol* 2015;99(1):98-102.

11 Flanary WE, Vislisis JM, Wagoner MD, Raecker ME, Aldrich BT, Zimmerman MB, Goins KM, Greiner MA. Incidence of cystoid macular edema after descemet membrane endothelial keratoplasty as a staged and solitary procedure. *Cornea* 2016;35(8):1040-1044.

12 Hoerster R, Stanzel TP, Bachmann BO, Siebelmann S, Felsch M, Cursiefen C. Intensified topical steroids as prophylaxis for macular edema after posterior lamellar keratoplasty combined with cataract surgery. *Am J Ophthalmol* 2016;163:174-179.e2.

13 Kitazawa K, Kayukawa K, Wakimasu K, Yokota I, Inatomi T, Hieda O, Mori K, Sotozono C, Kinoshita S. Cystoid macular edema after Descemet's stripping automated endothelial keratoplasty. *Ophthalmology* 2017;124(4):572-573.

14 Yonekawa Y, Kim IK. Pseudophakic cystoid macular edema. *Curr Opin Ophthalmol* 2012;23(1):26-32.

15 Lobo C. Pseudophakic cystoid macular edema. *Ophthalmologica* 2012;227(2):61-67.

16 Chu CJ, Johnston RL, Buscombe C, Sallam AB, Mohamed Q, Yang YC; United Kingdom Pseudophakic Macular Edema Study Group. Risk

- factors and incidence of macular edema after cataract surgery: a database study of 81984 eyes. *Ophthalmology* 2016;123(2):316-323.
- 17 Minnella AM, Savastano MC, Zinzanella G, Mazzone G, Federici M, Gari M, Falsini B, Balestrazzi E. Spectral-domain optical coherence tomography in Irvine-Gass syndrome. *Retina* 2012; 32(3):581-587.
- 18 Gharbiya M, Cruciani F, Cuzzo G, Parisi F, Russo P, Abdolrahimzadeh S. Macular thickness changes evaluated with spectral domain optical coherence tomography after uncomplicated phacoemulsification. *Eye (Lond)* 2013;27(5):605-611.
- 19 Guo S, Patel S, Baumrind B, Johnson K, Levinsohn D, Marcus E, Tannen B, Roy M, Bhagat N, Zarbin M. Management of pseudophakic cystoid macular edema. *Surv Ophthalmol* 2015;60(2):123-137.
- 20 Kessel L, Tendal B, Jorgensen KJ, Erngaard D, Flesner P, Andresen JL, Hjortdal J. Post-cataract prevention of inflammation and macular edema by steroid and nonsteroidal anti-inflammatory eye drops: a systematic review. *Ophthalmology* 2014;121(10):1915-1924.
- 21 Sesar A, Cavar I, Sesar AP, Geber MZ, Sesar I, Laus KN, Vatavek Z, Mandić Z. Macular thickness after glaucoma filtration surgery. *Coll Antropol* 2013;37(3):841-845.
- 22 Lv Z, Li Y, Wu Y, Qu Y. Surgical complications of primary rhegmatogenous retinal detachment: a meta-analysis. *PLoS One* 2015; 10(3):e0116493.
- 23 Koytak A, Kubaloglu A, Sari ES, Atakan M, Culfa S, Ozerturk Y. Changes in central macular thickness after uncomplicated corneal transplantation for keratoconus: penetrating keratoplasty versus deep anterior lamellar keratoplasty. *Cornea* 2011;30(12):1318-1321.
- 24 Acar BT, Muftuoglu O, Acar S. Comparison of macular thickness measured by optical coherence tomography after deep anterior lamellar keratoplasty and penetrating keratoplasty. *Am J Ophthalmol* 2011;152(5): 756-761.e2.
- 25 Terry MA, Shamie N, Chen ES, Phillips PM, Hoar KL, Friend DJ. Precut tissue for Descemet's stripping automated endothelial keratoplasty: vision, astigmatism, and endothelial survival. *Ophthalmology* 2009; 116(2):248-256.
- 26 Price MO, Fairchild KM, Price DA, Price FW, Jr. Descemet's stripping endothelial keratoplasty five-year graft survival and endothelial cell loss. *Ophthalmology* 2011;118(4):725-729.
- 27 Tsaousis KT, Kopsachilis N, Tsinoopoulos IT, Dimitrakos SA, Kruse FE, Welge-Luessen U. Time-dependent morphological alterations and viability of cultured human trabecular cells after exposure to Trypan blue. *Clin Exp Ophthalmol* 2013;41(5):484-490.
- 28 Acar BT, Muftuoglu O, Acar S. Comparison of sulfur hexafluoride and air for donor attachment in Descemet stripping endothelial keratoplasty in patients with pseudophakic bullous keratopathy. *Cornea* 2014;33(3): 219-222.