

Changes in retinal vessel diameters in migraine patients during attack-free period

Metin Unlu¹, Duygu Gulmez Sevim¹, Murat Gultekin², Recep Baydemir², Cagatay Karaca¹, Ayse Oner¹

¹Ophthalmology Department, School of Medicine, Erciyes University, Kayseri 38039, Turkey

²Neurology Department, School of Medicine, Erciyes University, Kayseri 38039, Turkey

Correspondence to: Metin Unlu. Ophthalmology Department, School of Medicine, Erciyes University, Kayseri 38039, Turkey. drunlumetin@hotmail.com

Received: 2016-07-01 Accepted: 2016-09-04

Abstract

• **AIM:** To evaluate the retinal vessel diameters in patients with migraine by optical coherence tomography (OCT).

• **METHODS:** In this cross-sectional study, 124 eyes of 62 patients with a diagnosis of unilateral migraine during attack-free period and 42 age- and sex-matched control subjects were included. Migraine patients were divided into the ≤ 2 migraine attacks per month group and the ≥ 5 migraine attacks per month group. All subjects underwent complete ophthalmological and neurological examinations before measurements. Retinal vessel diameters and choroidal thickness were examined with the Spectralis OCT.

• **RESULTS:** The mean diameters of the arteries in the eyes on the headache side of control group, ≥ 5 migraine attacks per month and ≤ 2 migraine attacks per month group at 480 μm from the optic disk (Raster 3) were 119.54 ± 46.69 , 136.68 ± 25.93 and 119.34 ± 31.75 μm respectively with a steady decline to 105.57 ± 32.15 , 118.18 ± 31.87 and 108.05 ± 38.77 μm at 1440 μm (Raster 7), the last measurement point, respectively. The retinal artery diameter measurements were significantly increased in ≥ 5 migraine attacks per month patients at four out of five measured points compared to control group ($P < 0.05$). There were no statistical differences at any of the points of vein measurements. The choroidal thickness measurements were significantly decreased in ≥ 5 migraine attacks per month patients at all measured points compared to control group ($P < 0.05$).

• **CONCLUSION:** The retinal artery diameter is found to increase significantly and the choroidal thickness is found to decrease in the eyes on the headache side in ≥ 5 migraine attacks per month patients compared to control group.

• **KEYWORDS:** migraine; optical coherence tomography; retinal vessel diameter; choroidal thickness

DOI:10.18240/ijo.2017.03.18

Unlu M, Sevim DG, Gultekin M, Baydemir R, Karaca C, Oner A. Changes in retinal vessel diameters in migraine patients during attack-free period. *Int J Ophthalmol* 2017;10(3):439-444

INTRODUCTION

Migraine is a chronic neurovascular disorder characterized by attacks of headaches, often unilateral and pulsating, and associated with nausea and/or photophobia and phonophobia. Two competing theories are being suggested for migraine pathogenesis^[1]. First one, the vasogenic theory claims migraine as a form of vascular dysregulation and migraine headache is caused by a rebound vasodilatation that results in a mechanical depolarization of nociceptive neurons within the walls of intra- and extra-cerebral vessels^[2-3]. Second, the neurogenic theory suggests migraine as a cranial disorder and assumes vascular changes are the result of neuronal dysfunction^[4-5].

Changes in the thickness of choroid may help understanding the choroidal blood flow which receives approximately 95% of all of the ocular blood supply^[6]. There are several studies evaluating the choroidal thickness with spectral domain optical coherence tomography (OCT) in migraine patients in the literature^[7-11]. Retinal vasculature system was not evaluated in patients with migraine in the current literature.

The retinal blood vessels are the only part of the central circulation system that can be directly and noninvasively visualized. The diameters of retinal blood vessels are considered as an important indicator of both cardiovascular and cerebrovascular diseases and the diameter measurement has become a subject of extensive research^[12-16].

To the best of our knowledge, there are no previous studies in the literature evaluating retinal vessel diameter in migraine by spectral domain OCT. The purpose of the current study was to evaluate the retinal vessel diameters in patients with migraine and compare them with that of healthy controls.

SUBJECTS AND METHODS

This observational, cross-sectional study involved 124 eyes of 62 patients with a diagnosis of migraine with or without aura during attack-free period (at least 7d without migraine attack) according to the criteria of the Headache International Society^[17] were recruited from the Neurology Clinic at the Erciyes University Hospital. Forty-two age- and sex-matched control subjects without systemic or ocular disease or any type

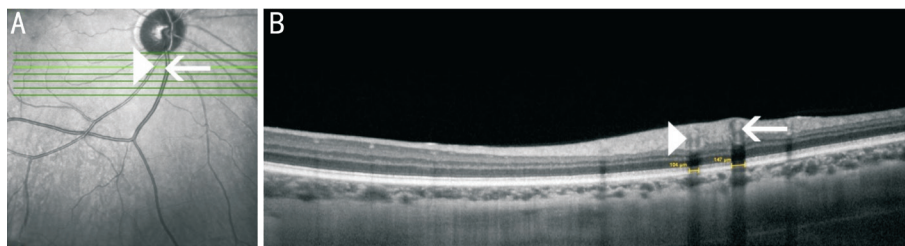


Figure 1 Image of the retinal vessels in patients with migraine A: A cube scan composed of seven horizontal rasters with a 240- μm interscan interval including the inferior temporal retinal vessels. The first raster is located at the inferior edge of the optic disk; B: The arrow and arrow head indicate the retinal veins and retinal arteries, respectively.

were included. The study was performed in adherence with the tenets of the Declaration of Helsinki and was approved by the local Ethics Committee. Informed consent was obtained from all of the study participants.

Migraine patients were divided into the ≤ 2 migraine attacks per month group and the ≥ 5 migraine attacks per month group. The age of onset, duration (year), attack frequency (per/month), predominant side of headache, presence or absence of aura were recorded. None of the migraine patients were receiving a specific therapy for migraine except for simple analgesics. Subjects with neurological diseases other than migraines or with other types of migraine (that is, hemiplegic migraine and retinal migraine) were excluded.

All subjects underwent complete ophthalmological examinations including: best-corrected visual acuity, refraction, slit-lamp biomicroscopy, intraocular pressure measurement with Goldmann applanation tonometry, and fundus examination. Patients were excluded if they had a history of ocular surface disorder, refractive disorders greater than ± 1.0 D, evidence of glaucoma and poor image due to cataract or unstable fixation, previous ocular surgery, or ocular injury; if they had a history of any systemic disease that could affect choroidal circulation (such as hypertension, diabetes, vasculitis, or renal failure). All of the subjects were non-smokers. All measurements were taken at the same time of day (between 10:00 a.m. and 4:00 p.m.) and at least 2h after wakeup time to avoid the effects of diurnal variation in choroidal thickness and retinal vessel diameters.

Retinal Vessel Diameter Measurements A cube scan consisting of 7 horizontal scans were placed at the inferior border of the disk to include the large retinal vessels originating from the disk (inferior temporal retinal arcades) (Figure 1). The scans were 20° or 30° in size and of high resolution, 100 automatic real time (ART) for maximal quality and resolution, and had a 240- μm interscan interval. Because the cube was placed at the optic disk border, each raster (from 1 to 7) was placed at a known constant distance from the optic disk border (Rasters 1-7 were at distances of 0, 240, 480, 720, 960, 1200, and 1440 μm , respectively). The eye-tracking system and the averaging technique (both unique features of the Spectralis) were used to ensure high quality and reduction of noise speckles. Each measurement was carried out on each of the OCT raster

images from the hyper reflective signal inferiorly to the hyper reflective signal superiorly (*i.e.* lumen plus vessel walls) as described previously^[18] (Figure 1). Difficulties in identifying the border of the retinal vessels at the first and second raster line (*i.e.* at the optic disk border and at 240 μm) led to the exclusion of those 2 rasters. Therefore, the statistical analysis was conducted only on the measurements of lines 3 to 7 inferiorly (480-1440 μm from the optic disk border). Vessels in which these landmarks were not distinguishable were excluded from analysis. The mean diameter of the arteries and veins was then calculated separately for each of the rasters and each of the measurements. Masked retinal specialists independently (Sevim DG and Unlu M) measured vessel diameters on each OCT scan.

Choroidal Thickness Measurements The choroidal thickness was measured with Heidelberg Spectralis-OCT (Spectralis; Heidelberg Engineering, Heidelberg, Germany). Choroidal thickness, defined as the distance between the outer portion of the hyperreflective line that corresponds to the retinal pigment epithelium and the inner surface of the sclera, was measured manually by the trained observer in a masked fashion. Five measurements perpendicular to the retina pigment epithelial layer were obtained for each scan: one at the fovea; two at 1000 and 1500 μm nasal; and two located at 1000 and 1500 μm temporal to the fovea.

Statistical Analysis Statistical analyses were performed using SPSS V.20.0 (SPSS Inc., IBM Corp, Chicago, IL, USA). The normal distribution of the data was checked using the Kolmogorov-Smirnov test. The difference between in choroidal thickness and retinal vessel diameter was calculated by Kruskal-Wallis test. Mann-Whitney *U* test was used for the pairwise comparisons of the groups. The correlation between choroidal thickness, retinal vessel diameter and migraine parameters were evaluated by Spearman's correlation coefficient. Statistical significance was defined as $P < 0.05$.

RESULTS

One hundred and twenty-four eyes of 62 subjects in the migraine group during attack-free period and 84 eyes of 42 subjects in control group were evaluated. In the study group, 31 patients suffered ≤ 2 migraine attacks per month and 31 patients had ≥ 5 migraine attacks per month. Demographic

Table 1 Systemic and ocular characteristics of study subjects

Parameters	$\bar{x} \pm s$ (range)			
	Migrain attacks ≥ 5 ($n=31$)	Migrain attacks ≤ 2 ($n=31$)	Control group ($n=42$)	<i>P</i>
Age (a)	36.3±8.26	38.2±8.42	35.5±7.96	0.24
Sex (M/F)	5/26	6/25	6/36	0.15
Intraocular pressure (mm Hg)	13.6±2.04	14.1±2.26	13.8±2.41	0.45
Refractive error (diopters)	0.0±1.8	0.0±2.1	0.0±1.9	0.36
Headache side (R/L)	15/16	13/18	-	0.42
Disease duration (a)	10.8±7.5	10.4±5.6	-	0.31
No. of attacks (per month)	6.8±4.2 (5-9)	1.3±0.4 (1-2)	-	0.002
Aura (+/-)	4/27	4/27	-	0.25

R: Right; L: Left.

Table 2 Retinal artery diameter measurements of unilateral migraine subjects and controls

Measurement points	$\bar{x} \pm s$, μm							¹ <i>P</i>
	Migrain attacks ≥ 5 ($n=62$ eyes)			Migrain attacks ≤ 2 ($n=62$ eyes)			Control group ($n=84$ eyes)	
	Headache side eye	Contralateral eye	<i>P</i>	Headache side eye	Contralateral eye	<i>P</i>		
Raster 3	136.68±25.93	120.14±22.56	0.02	119.34±31.75	119.76±30.45	0.52	119.54±46.69	0.03
Raster 4	136.50±30.01	119.25±28.75	0.02	115.63±34.65	116.09±31.22	0.61	117.16±34.60	0.02
Raster 5	133.81±25.14	116.26±25.14	0.03	116.63±33.86	115.54±32.78	0.45	113.28±33.40	0.02
Raster 6	130.76±34.64	113.18±32.18	0.03	110.28±32.49	110.48±30.04	0.42	113.09±30.22	0.03
Raster 7	118.18±31.87	109.42±30.12	0.21	108.05±38.77	109.12±32.52	0.41	105.57±32.15	0.12

¹Kruskal-Wallis test comparison of 3 groups.

Table 3 Retinal vein diameter measurements of unilateral migraine subjects and controls

Measurement points	$\bar{x} \pm s$, μm							¹ <i>P</i>
	Migrain attacks ≥ 5 ($n=62$ eyes)			Migrain attacks ≤ 2 ($n=62$ eyes)			Control group ($n=84$ eyes)	
	Headache side eye	Contralateral eye	<i>P</i>	Headache side eye	Contralateral eye	<i>P</i>		
Raster 3	156.58±34.53	154.75±30.74	0.72	155.83±30.95	157.78±28.45	0.12	151.90±33.34	0.82
Raster 4	157.28±33.24	156.26±30.28	0.36	160.02±31.10	161.23±30.36	0.48	151.72±34.37	0.55
Raster 5	153.52±26.19	153.28±24.14	0.12	161.81±28.13	160.23±27.12	0.31	157.36±29.70	0.33
Raster 6	146.59±33.67	143.12±30.21	0.25	150.28±32.00	151.24±31.01	0.21	148.03±29.42	0.80
Raster 7	148.17±34.13	147.15±36.12	0.12	151.13±34.27	153.10±32.14	0.12	139.21±29.13	0.28

¹Kruskal-Wallis test comparison of 3 groups.

data of migraine and control groups are shown in Table 1. All migraine patients had unilateral headaches. There were no differences between participants in the migraine and control groups with respect to age or gender ($P>0.05$).

Retinal Artery Diameter Measurements The mean diameters of the arteries in the eyes on the headache side of control group, ≥ 5 migraine attacks per month and ≤ 2 migraine attacks per month group at 480 μm from the optic disk (Raster 3) were 119.54±46.69, 136.68±25.93, and 119.34±31.75 μm respectively with a steady decline to 105.57±32.15, 118.18±31.87, and 108.05±38.77 μm at 1440 μm (Raster 7), the last measurement point, respectively (Table 2).

The retinal artery diameter measurements in the eyes on the headache side were significantly increased in ≥ 5 migraine attacks per month patients at four out of five measured points compared to control group ($P<0.05$) (Table 2). However, retinal artery diameter measurements were similar in all measured points between ≤ 2 migraine attacks per month and control group ($P>0.05$).

Retinal Vein Diameter Measurements The mean diameters of the veins in the eyes on the headache side of control group, ≥ 5 migraine attacks per month and ≤ 2 migraine attacks per month group at 480 μm from the optic disk (Raster 3) in the eyes on the headache side were 151.90±33.34, 156.58±34.53, and 155.83±30.95 μm respectively with a steady decline to 139.21±29.13, 148.17±34.13, and 151.13±34.27 μm at 1440 μm (Raster 7), the last measurement point, respectively (Table 3). Table 3 displays the results of comparisons between the mean diameters of the veins between control and migraine groups. There were no statistical differences for either of these comparisons at any of the points of measurement in control group, ≥ 5 migraine attacks per month, and ≤ 2 migraine attacks per month group ($P>0.05$).

Choroidal Thickness Measurements The mean foveal choroidal thickness in the eyes on the headache side was 356.50±37.25 μm in the control group versus 317.98±38.72 and 350.52±33.69 μm in ≥ 5 migraine attacks per month and ≤ 2 migraine attacks per month groups, respectively (Table 4). The

Table 4 The mean choroidal thickness measurements of unilateral migraine subjects and controls

Measurement points	Migrain attacks ≥ 5 ($n=62$ eyes)			Migrain attacks ≤ 2 ($n=62$ eyes)			Control group ($n=84$ eyes)	$\bar{x} \pm s$, μm	1P
	Headache side eye	Contralateral eye	P	Headache side eye	Contralateral eye	P			
N-1500	252.96 \pm 38.65	283.75 \pm 34.23	0.03	288.00 \pm 30.42	284.13 \pm 37.15	0.14	287.14 \pm 38.47	0.04	
N-1000	281.40 \pm 38.97	312.24 \pm 37.45	0.04	315.02 \pm 38.47	314.11 \pm 32.24	0.18	317.50 \pm 31.92	0.01	
F	317.98 \pm 38.72	352.45 \pm 37.12	0.03	350.52 \pm 33.69	352.23 \pm 32.16	0.23	356.50 \pm 37.25	0.04	
T-1000	301.46 \pm 36.77	333.52 \pm 36.23	0.03	331.30 \pm 30.23	333.15 \pm 37.78	0.42	337.78 \pm 37.74	0.03	
T-1500	289.38 \pm 31.64	316.72 \pm 30.02	0.02	316.77 \pm 31.19	316.12 \pm 34.12	0.83	318.97 \pm 34.35	0.04	

N-1500: Choroidal thickness at 1500 μm nasal to the fovea; N-1000: Choroidal thickness at 1000 μm nasal to the fovea; F: Choroidal thickness at fovea; T-1000: Choroidal thickness at 1000 mm temporal to the fovea; T-1500: Choroidal thickness at 1500 μm temporal to the fovea. 1 Kruskal-Wallis test comparison of 3 groups.

choroidal thickness measurements in the eyes on the headache side were significantly decreased in ≥ 5 migraine attacks per month patients at all measured points compared to control group ($P < 0.05$) (Table 4). However, choroidal thickness was similar in all measured points between ≤ 2 migraine attacks per month and control group ($P > 0.05$).

DISCUSSION

Migraine is the most prevalent neurological disorder and the millions of people suffer from it in the world^[19]. Despite recent advances, the mechanisms underlying migraine pathogenesis still remain elusive. The role of vasogenic and neurogenic theories has been a topic of intense debate^[1]. The vasogenic theory of vasodilatation as causative for migraine pain dominated migraine research for most of the 20th century^[3]. Recently, the neurogenic theory has received increasing support. It was suggested that, migraine pain is caused by abnormal central interpretation of normal sensory input in the trigeminal sensory system^[20-21].

The major finding of the present study was the existence of an association between migraine attacks and retinal artery dilatation. Patients with unilateral migraine had significant dilatation of retinal artery only on the side with symptoms. To best of our knowledge, this is the first study evaluating the retinal vessel diameters in migraine patients by spectral domain OCT. Additionally, there are several OCT studies with conflicting findings of the relation between migraine and choroidal thickness. In the acute phase of migraine increased choroidal thickness due to rebound vasodilatation is clear; whereas in the attack-free period choroidal attenuation due to vasoconstrictive/ischemic nature is obvious. Because the literature lacks studies regarding the effects of attack frequencies of migraine among retinal vessel diameters, the study groups in this study was formed related to the attack frequencies and then the comparisons were made within the groups and with the control group.

Asghar *et al*^[22] induced delayed migraine attacks and they reported that the migraine attacks were associated with dilatation of both extra- and intracranial vessels. Patients with unilateral migraine pain had dilatation of the extracranial

middle meningeal artery (MMA) and intracranial middle cerebral artery (MCA) on the pain side but not on the pain-free side. In patients with bilateral migraine pain, they recorded bilateral dilatation of both the MMA and MCA. In the current study, the retinal artery diameter measurements in the eyes on the headache side were significantly increased in ≥ 5 migraine attacks per month patients at four out of five measured points compared to control group. However, retinal artery diameter measurements were similar in all measured points between ≤ 2 migraine attacks per month and control group. Additionally, there were no statistical differences for either of these comparisons at any of the points of retinal vein measurement of control group, ≥ 5 migraine attacks per month, and ≤ 2 migraine attacks per month group. According to neurogenic inflammation theory, some unknown stimulus triggers cortical spreading depression (CSD) in the brain. CSD creates a domino effect that leads to trigeminal activation, mast cell degranulation, vasodilatation and an increase in endothelial permeability^[23]. The vasogenic theory which viewed migraine as a form of vascular dysregulation assumes that migraine headache was caused by a rebound vasodilatation of cranial vessels after a transient vasoconstriction^[5]. Thus, we can conclude that persistent dynamic vascular changes may occur in patients with ≥ 5 migraine attacks per month compared to ≤ 2 migraine attacks per month and control group.

In our study, we evaluated 62 unilateral migraine patients (31 patients ≤ 2 migraine attacks per month and 31 patients ≥ 5 migraine attacks per month) and compared their results with 42 control subjects during attack-free period and found the statistically significant decrease in choroidal thickness in patients ≥ 5 migraine attacks per month in the eyes on the headache side. Karaca *et al*^[24] assessed choroidal thicknesses of 32 migraine patients during attack-free period. They found that, the choroidal thickness was significantly decreased not only in migraine patients with aura but also in those without aura. They concluded that migraine headache induces choroidal attenuation by vasoconstriction and ischemia in the attack-free period. Karalezli *et al*^[8] assessed choroidal thicknesses of 20 newly diagnosed migraine patients. They showed a significant

decrease in median choroidal thickness between the migraine patients (277 μm) and controls (301 μm). They suggested that the decreased choroidal thickness might be related to the vascular dysregulation. Additionally, 101 migraine patients were assessed during headache-free periods with fingertip photoplethysmography and they concluded that migraine was a vasoconstrictive disorder even in the peripheral vascular structures in the attack-free period^[25]. In the current study the mean foveal choroidal thickness was $356.5 \pm 37.25 \mu\text{m}$ in the control group versus $350.52 \pm 33.69 \mu\text{m}$ and $317.98 \pm 38.72 \mu\text{m}$ in ≤ 2 migraine attacks per month and ≥ 5 migraine attacks per month group in the eyes on the headache side, respectively. We think that, choroidal attenuation and vascular dysregulation may play a role in the decreased choroidal thickness in patients with ≥ 5 migraine attacks per month.

In the acute phase of headache, there are contradictory results in the literature. Karalezli *et al*^[7] evaluated choroidal thickness in 46 acute migraine patients and found significant thickening at all measurement points compared to healthy controls. They concluded that rebound vasodilatation in the acute attack period might be responsible for increased choroidal thickness of migraine patients. In another study, Dadaci *et al*^[11] reported choroidal thickening during the attack period in the eyes on the headache side of patients with bilateral or unilateral migraine compared to basal levels. They concluded that presumed neurogenic inflammation can occur in choroid and may result in increased choroidal thickness during attack period. However, Dervisogullari *et al*^[10] evaluated choroidal thickness and ocular pulse amplitude (OPA) measurements during the acute attack period in migraine patients. They found significantly decreased choroidal thickness in unilateral migraine patients compared to control group. Prospective clinical studies with larger acute migraine patients are needed to shed light on these controversial findings.

To best of our knowledge, this is the first study in the literature evaluating the retinal vessel diameters by OCT in migraine patients. Our study had limitations in terms of a small sample size. Additionally, migraine patients were not evaluated during the acute migraine attack. Important data about mechanism of acute disease might have been obtained if cases with acute migraine had been included. Moreover we did not measure the actual cross-section area of vessels, but their shadow width on the IS/OS line. Additionally, measurement of small vessel diameters is more difficult as the margin of underlying shadow is less sharp than larger vessels. Choosing the ONH as the superior border of OCT scans allows the selection of comparable points from each vessel's minimal topographical variations.

In conclusion, we found that the retinal artery diameter measurements in the eyes on the headache side were significantly increased in ≥ 5 migraine attacks per month patients compared to control group. We also showed that the choroidal thickness

in the eyes on the headache side was significantly decreased in ≥ 5 migraine attacks per month patients compared to ≤ 2 migraine attacks per month and control group. These findings may be supported by further data and may provide further insights into the pathogenesis of migraine.

ACKNOWLEDGEMENTS

Conflicts of Interest: Unlu M, None; Sevim DG, None; Gultekin M, None; Baydemir R, None; Karaca C, None; Oner A, None.

REFERENCES

- 1 Eadie MJ. The pathogenesis of migraine -17th to early 20th century understandings. *J Clin Neurosci* 2005;12(4):383-388.
- 2 Panconesi A, Bartolozzi ML, Guidi L. Migraine pain: reflections against vasodilatation. *J Headache Pain* 2009;10(5):317-325.
- 3 Brennan KC, Charles A. An update on the blood vessel in migraine. *Curr Opin Neurol* 2010;23(3):266-274.
- 4 Charles A. Vasodilation out of the picture as a cause of migraine headache. *Lancet Neurol* 2013;12(5):419-420.
- 5 Lauritzen M. Cerebral blood flow in migraine and cortical spreading depression. *Acta Neurol Scand Suppl* 1987;113:1-40.
- 6 Cioffi GA, Granstam E, Alm A. Ocular Circulation. Kaufman PL, Alm A, editors. *Adler's Physiology of the Eye*. 10th ed. St. Louis: Mosby; 2003: 747-784.
- 7 Karalezli A, Simsek C, Celik G, Eroglu FC. Evaluation of choroidal thickness using spectral-domain optical coherence tomography in migraine patients during acute migraine attacks: a comparative study. *Eye (Lond)* 2014;28(12):1477-1481.
- 8 Karalezli A, Celik G, Koktekir BE, Kucukerdonmez C. Evaluation of choroidal thickness using spectral-domain optical coherence tomography in patients with migraine: a comparative study. *Eur J Ophthalmol* 2015;25(4):338-342.
- 9 Ekinci M, Ceylan E, Cağatay HH, Keleş S, Hüseyinoğlu N, Tanyildiz B, Cakici O, Kartal B. Retinal nerve fibre layer, ganglion cell layer and choroid thinning in migraine with aura. *BMC Ophthalmol* 2014;14:75.
- 10 Dervisogullari MS, Totan Y, Gencler OS. Choroid thickness and ocular pulse amplitude in migraine during attack. *Eye (Lond)* 2015;29(3):452.
- 11 Dadaci Z, Doganay F, Oncel Acir N, Aydin HD, Borazan M. Enhanced depth imaging optical coherence tomography of the choroid in migraine patients: implications for the association of migraine and glaucoma. *Br J Ophthalmol* 2014;98(7):972-975.
- 12 Mendrinis E, Mangioris G, Papadopoulou DN, Donati G, Pournaras CJ. Long-term results of the effect of intravitreal ranibizumab on the retinal arteriolar diameter in patients with neovascular age-related macular degeneration. *Acta Ophthalmol* 2013;91(3):e184-e190.
- 13 Nagel E, Vilser W. Autoregulative behavior of retinal arteries and veins during changes of perfusion pressure: a clinical study. *Graefes Arch Clin Exp Ophthalmol* 2004;42(1):13-17.
- 14 Nagel E, Vilser W, Lanzl I. Age, blood pressure, and vessel diameter as factors influencing the arterial retinal flicker response. *Invest Ophthalmol Vis Sci* 2004;45(5):1486-1492.
- 15 Schuster AK, Fischer JE, Vossmerbaeumer C, Vossmerbaeumer U.

Retinal vessel diameters in migraine patients

Optical coherence tomography-based retinal vessel analysis for the evaluation of hypertensive vasculopathy. *Acta Ophthalmol* 2015;93(2):e148-e153.

16 Kumagai K, Tsujikawa A, Muraoka Y, Akagi-Kurashige Y, Murakami T, Miyamoto K, Yamada R, Yoshimura N. Three-dimensional optical coherence tomography evaluation of vascular changes at arteriovenous crossings. *Invest Ophthalmol Vis Sci* 2014;55(3):1867-1875.

17 Classification and diagnostic criteria for headache disorders, cranial neuralgias and facial pain. Headache Classification Committee of the International Headache Society. *Cephalalgia* 1988;8(Suppl 7):1-96.

18 Goldenberg D, Shahar J, Loewenstein A, Goldstein M. Diameters of retinal blood vessels in a healthy cohort as measured by spectral domain optical coherence tomography. *Retina* 2013;33(9):1888-1894.

19 Stovner Lj, Hagen K, Jensen R, Katsarava Z, Lipton R, Scher A, Steiner T, Zwart JA. The global burden of headache: a documentation of headache prevalence and disability worldwide. *Cephalalgia* 2007;27(3):193-210.

20 Bahra A, Matharu MS, Buchel C, Frackowiak RS, Goadsby PJ.

Brainstem activation specific to migraine headache. *Lancet* 2001;357(9261):1016-1017.

21 May A, Goadsby PJ. The trigeminovascular system in humans: pathophysiologic implications for primary headache syndromes of the neural influences on the cerebral circulation. *J Cereb Blood Flow Metab* 1999;19(2):115-127.

22 Asghar MS, Hansen AE, Amin FM, van der Geest RJ, Koning Pv, Larsson HB, Olesen J, Ashina M. Evidence for a vascular factor in migraine. *Ann Neurol* 2011;69(4):635-645.

23 Markowitz S, Saito K, Moskowitz MA. Neurogenically mediated leakage of plasma protein occurs from blood vessels in dura mater but not brain. *J Neurosci* 1987;7(12):4129-4136.

24 Karaca EE, Kocer EB, Ozdek S, Akçam HT, Ercan MB. Choroidal thickness measurements in migraine patients during attack-free period. *Neurol Sci* 2016;37(1):81-88.

25 Komatsu K, Fukutake T, Hattori T. Fingertip photoplethysmography and migraine. *J Neurol Sci* 2003;216(1):17-21.