

# Long-term follow-up of vitrectomy in patients with pathologic myopic foveoschisis

Ting Zhang<sup>1</sup>, Ying Zhu<sup>2</sup>, Chun-Hui Jiang<sup>1</sup>, Ge-Zhi Xu<sup>1,3</sup>

<sup>1</sup>Department of Ophthalmology and Visual Science, Eye, Ear, Nose, and Throat Hospital, Shanghai Medical School, Fudan University, Shanghai 200031, China

<sup>2</sup>Department of Ophthalmology, Xiangya Hospital, Central South University, Changsha 410008, Hunan Province, China

<sup>3</sup>Shanghai Key Laboratory of Visual Impairment and Restoration, Fudan University, Shanghai 200031, China

**Co-first authors:** Ting Zhang and Ying Zhu

**Correspondence to:** Ge-Zhi Xu. Department of Ophthalmology and Visual Science, Eye, Ear, Nose, and Throat Hospital, 83 Fenyang Rd, Shanghai 200031, China. xugezhimf@163.com

Received: 2016-07-22 Accepted: 2016-11-08

## Abstract

• **AIM:** To report the long-term surgical outcomes of pathologic myopic foveoschisis (MF) following vitrectomy.

• **METHODS:** We performed a retrospective case series analysis of 50 consecutive patients diagnosed with MF who experienced vision loss due to progression of foveoschisis. The 50 patients (67 eyes) were treated in our hospital with vitrectomy with internal limiting membrane (ILM) peeling from December 2004 to September 2010. Best corrected visual acuity (BCVA), refractive error, optical coherence tomography (OCT), and routine examination results were analysed. The changes of BCVA, foveal anatomical features on OCT scan, and complications were the main outcome measures.

• **RESULTS:** The mean follow-up duration was 42±17mo (range 24 to 93mo). BCVA improved significantly postoperatively (0.76±0.65 logMAR) compared with preoperative baselines (1.31±0.78 logMAR,  $P<0.0001$ ), and in 53 eyes (79%) including 3 lines gain in 44 eyes (66%) at the last follow-up visit. OCT scans showed that central retinal thickness decreased from 580.0±270.0 µm preoperatively ( $n=67$ ) to 179.7±84.7 µm postoperatively ( $n=58$ ,  $P<0.0001$ ). Total resolution of foveoschisis occurred in 41 eyes (61%). Preoperative BCVA correlated well with postoperative BCVA, whereas other factors such as age, axial length, and refractive error were not correlated. The most common complications were cataract and full-thickness macular hole formation in 14 and 9 cases, respectively.

• **CONCLUSION:** Patients with progressive vision loss due to MF who were treated with vitrectomy with ILM peeling

show favourable outcomes. In most eyes, visual acuity and foveal structure remain stable during long-term observation.

• **KEYWORDS:** pathologic myopia; myopic foveoschisis; vitrectomy; internal limiting membrane peeling

**DOI:10.18240/ijo.2017.02.16**

Zhang T, Zhu Y, Jiang CH, Xu GZ. Long-term follow-up of vitrectomy in patients with pathologic myopic foveoschisis. *Int J Ophthalmol* 2017;10(2):277-284

## INTRODUCTION

Pathologic myopia is characterized by a refractive error of the spherical equivalent of -6.0 dioptres or more and an axial length of the eye of more than 26.5 mm. Pathologic myopia can be complicated by conditions like posterior staphyloma or macular atrophy, and it cannot be fully corrected with lenses. It affects almost 2% of the general population aged 12 to 54y in the United States<sup>[1]</sup>, with a higher prevalence of about 9% in Asian countries<sup>[2]</sup>. Pathologic myopia is the fifth cause of low vision or blindness in Japan<sup>[3]</sup> and the second most frequent cause of low vision or blindness in people older than 40y in China<sup>[4]</sup>. Myopic foveoschisis (MF), also called myopic retinoschisis, was once considered to be a split in the layers at the macular area<sup>[5-6]</sup> in eyes with pathologic myopia. It is now more accepted that MF represents stretched retinal layers, and these are present in about 9% to 34% of patients with pathologic myopia<sup>[7-8]</sup>. In some patients, MF is stable for many years, but most patients experience vision deterioration as the result of the progression of foveoschisis<sup>[6,9-11]</sup>. The cause of foveoschisis is not fully understood; vitreous traction of premacular vitreous cortex<sup>[12]</sup>, rigidity of the internal limiting membrane (ILM)<sup>[13]</sup>, stiffness of retinal vessels<sup>[7]</sup>, progressive choroid atrophy<sup>[14]</sup>, and posterior staphyloma<sup>[5]</sup> have all been proposed as mechanisms for the pathogenesis of foveoschisis. At present, options to treat MF include vitrectomy with or without ILM peeling<sup>[10,15-23]</sup>, macular buckling<sup>[24-26]</sup>, a single injection of perfluoroethane<sup>[27]</sup>, and a recently newly introduced suprachoroidal buckling technique<sup>[28]</sup>. Vitrectomy is considered to be the treatment of choice for most retina specialists because of familiarity and availability. Several authors have reported favourable results of vitrectomy from relatively short-term follow-up in samples of limited size<sup>[16-17,20,22-23,29-30]</sup>. Because

myopic maculopathy progresses in about 40% of patients with high myopia<sup>[11]</sup>, it is important to know whether vitrectomy for MF could lead to stable visual acuity and macular structure over a long period postoperatively. There have been some reports about long-term surgery outcomes for macular holes in highly myopic eyes<sup>[31]</sup>, but only two groups<sup>[10,19]</sup> have reported promising results from long-term follow-up after vitrectomy for MF, but the sample sizes were small, and postoperative anatomical information from optical coherence tomography (OCT) imaging was limited. Here we report our long-term results of vitrectomy for MF, with a large sample size and the help of spectral-domain OCT (SD-OCT), which enabled more detailed investigation of surgical outcomes.

### SUBJECTS AND METHODS

**Subjects** We retrospectively reviewed the medical records of consecutive patients who underwent vitrectomy for MF performed by one experienced surgeon (Xu GZ from December 2004 to September 2010 at the Eye, Ear, Nose and Throat Hospital, Shanghai). Inclusion criteria were pathologic myopia with refractive error of more than -6.0 dioptres, axial length of more than 26.5 mm, MF demonstrated by OCT, and symptoms of progressive vision deterioration for at least three months due to progression of MF as assessed with OCT. Patients who completed more than two years of follow-up were included. Exclusion criteria were obvious epiretinal membrane other than MF, choroidal neovascularization (CNV), retinal tear, glaucoma, and macular hole or other retinchoroidal diseases such as choroiditis. Patients with no obvious complaint of vision loss and stable macular anatomical features assessed with OCT did not receive vitrectomy. Written informed consent was obtained from all patients before surgery. Approval from the Institutional Review Board of the Eye, Ear, Nose and Throat Hospital was obtained, and this study adhered to the tenets of the Declaration of Helsinki.

**Surgical Techniques** A three-port conventional pars plana vitrectomy was carried out in all eyes, with either 20-gauge (ACCURUS, Alcon, Fort Worth, Texas, USA) or 23-gauge with trocars open (Constellation Vision System, Alcon, USA). Core vitrectomy was performed, followed by an injection of triamcinolone acetonide (0.2 mL of a 20 mg/mL solution) into the vitreous cavity to visualize the vitreous cortex. Aspiration was applied around the optic disc to induce detachment of the posterior vitreous, and then peripheral vitrectomy was carried out. Residual vitreous cortex adherent on the inner retinal surface was removed with fine forceps. An injection of 0.1 mL brilliant blue G (0.05%) or indocyanine green (0.1%) was given to assist with the peeling of the ILM at the posterior pole within the vascular arcade. Finally, fluid-air exchange and tamponade, using 20% sulphur hexafluoride (SF<sub>6</sub>), 14% octafluoropropane (C<sub>3</sub>F<sub>8</sub>), or silicone oil (5000 centistokes), was performed at the surgeon's discretion. Phacoemulsification

with posterior chamber intraocular lens implantation was performed simultaneously on eyes with cataracts. Patients were encouraged to maintain a face-down position for 6 to 8h per day for at least 2wk postoperatively. For patients with silicone oil tamponade, removal of silicone oil was scheduled 3 to 6mo after the first operation.

**Examination** Preoperative and postoperative Snellen best corrected visual acuity (BCVA) was documented and converted to the logarithm of the minimum angle of resolution (logMAR) BCVA for analysis. As in the study of Roberts *et al*<sup>[32]</sup>, values of Snellen 20/8000 (logMAR=2.6), Snellen 20/10 000 (logMAR=2.7), Snellen 20/12 000 (logMAR=2.8), and Snellen 20/16 000 (logMAR=2.9) were used to represent visual ability of counting fingers, hand movement, light perception, and no light perception, respectively. Postoperative visits were scheduled every three to six months. Slit-lamp examination, indirect fundus biomicroscopy, and intraocular pressure measurements with applanation tonometry were carried out upon each visit. Choroid-retinal pigment epithelium (RPE) atrophy was based on indirect fundus biomicroscopy showing minimal atrophy, lacquer cracks, diffuse atrophy, patchy atrophy, or macular atrophy, as previously described<sup>[11]</sup>. Axial length of the eye was measured with A-ultrasonography. The presence of posterior staphyloma was determined with B-scan ultrasonography. Multiple types of OCT were used, including stratus OCT (Carl Zeiss Meditec, Dublin, California, USA) and Spectralis SD-OCT (Heidelberg Engineering, Heidelberg, Germany). The macula was scanned in the horizontal and vertical meridians using the standard crosshair pattern, with a scan length of 6 mm (Stratus OCT) or 8 mm (Spectralis OCT) centred through the fovea. The OCT scan was performed at least twice preoperatively and then at least every 6mo postoperatively.

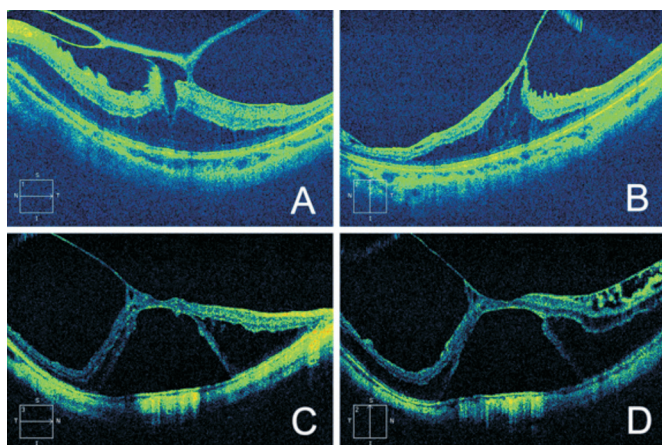
**Main Outcome Measures** Postoperative BCVA, changes in BCVA, proportion of eyes with final Snellen BCVA of 20/50 or better, and percentage of eyes with three lines of BCVA improvement were documented.

Foveal anatomical characteristics were evaluated from OCT results in a masked fashion by two authors (Zhang T and Zhu Y). The two authors were given a list of patients' admission numbers, without any other information such as patients' names, visual acuity or operation details. Preoperatively, eyes were categorized into eyes with foveoschisis (FS) only and eyes with foveoschisis with fovea detachment (FD) (Figure 1). Central retinal thickness (CRT), defined as the vertical distance from the centre of the inner surface of the sensory retina to the RPE, was manually measured on the horizontal OCT scan in the OCT software. Postoperative resolution of foveoschisis and ellipsoid zone status were also inspected. Ellipsoid zone defect was defined as an interruption of the hyperreflective line above the RPE within 500 µm around the foveola. As pathologic

**Table 1 Baseline characteristics in patients who underwent vitrectomy for high MF**

| Parameters  | $\bar{x} \pm s$ (range)       |
|---|-------------------------------|
| No. of patients (eyes)                                    | 50 (67)                       |
| Age (a)   | 57.4±10.7 (31 to 74)          |
| Sex (F/M)   | 33/17                         |
| Follow-up period (mo)                                     | 42±17 (24 to 93)              |
| Axial length (mm)   | 28.89±1.60 (26.53 to 33.68)   |
| Refractive error (D)                                      | -14.55±4.69 (-7.50 to -28.00) |
| Preoperative BCVA (logMAR)                                | 1.31±0.78 (0.2 to 2.8)        |
| BCVA at last visit (logMAR)                               | 0.76±0.65 (2.9 to -0.1)       |
| Preoperative choroidal atrophy, eyes (%)                  |                               |
| Minimal atrophy   | 4 (6)                         |
| Lacquer cracks  | 3 (4)                         |
| Diffuse atrophy   | 33 (49)                       |
| Patchy atrophy  | 24 (36)                       |
| Macular atrophy   | 3 (4)                         |
| Posterior staphyloma, eyes (%)                            |                               |
| Yes   | 65 (97)                       |
| No  | 2 (3)                         |
| Preoperative foveoschisis w/o foveal detachment, eyes (%) |                               |
| FS  | 45 (67)                       |
| FD  | 22 (33)                       |

SD: Standard deviation; D: Diopter; BCVA: Best corrected visual acuity; logMAR: Logarithm of the minimum angle of resolution; FS: Foveoschisis only; FD: Foveoschisis with foveal detachment.



**Figure 1 Representative OCT images of MF** A, B: FS in both horizontal (A) and vertical (B) OCT scans. Outer retinal layers are stretched, with obvious adhesion of posterior vitreous cortex on the inner retinal surface; C, D: FD in both horizontal (C) and vertical (D) scans. There is retinoschisis in both the outer and inner retina.

foveoschisis could be complicated with other vitreomacular interface conditions, such as epiretinal membrane and macular hole, any discrepancy on the primary diagnosis and classification was resolved from detailed discussion with the other authors (Jiang CH and Xu GZ), both of whom have more than ten-year experience of treating macular diseases.

Postoperative complications were recorded.

**Statistical Analysis** Continuous data are presented in the form of mean±standard deviation. Statistical analysis was

performed using SPSS for Macintosh (version 21, SPSS Inc., Chicago, IL, USA). The preoperative and postoperative BCVA was compared using the non-parametric Wilcoxon signed rank test. The BCVA of two groups were compared using the Mann-Whitney *U* test. The BCVA of more than two groups were compared using the Kruskal-Wallis test. Continuous data between two groups was compared with the non-paired Student's *t*-test. Continuous data between four groups was compared with the one-way ANOVA test. The association between preoperative factors and postoperative BCVA was evaluated with multiple linear regression analysis. A two-tailed *P* value <0.05 was considered to indicate statistical significance in all tests.

## RESULTS

**Baseline Characteristics** Sixty-seven eyes of 50 patients were included in the study. The demographic features of the patients are presented in Table 1.

Brilliant blue G was used in 19 eyes (28%) and indocyanine green in 48 eyes (72%) in the process of ILM peeling. Thirty-eight eyes (57%) received a C<sub>3</sub>F<sub>8</sub> tamponade, 26 eyes (39%) an SF<sub>6</sub> tamponade, and the remaining three eyes (4%) a silicone oil tamponade. Six eyes first treated with vitrectomy and C<sub>3</sub>F<sub>8</sub> tamponade underwent a second operation with silicone oil tamponade, due to detachment of the macula following the first operation. Phacoemulsification with intraocular lens implantation was done simultaneously with vitrectomy in 42

eyes (63%). For the remaining 25 eyes, the clear lens remained undamaged during the operation.

**Visual Acuity Outcomes** The mean preoperative BCVA was 1.31±0.78 logMAR (range 0.2 to 2.8 logMAR), equivalent to Snellen 20/400. The mean postoperative BCVA at the last visit was 0.76±0.65 logMAR (range -0.1 to 2.9 logMAR), equivalent to Snellen 20/125. There was significant improvement in the final BCVA compared with the preoperative BCVA ( $P<0.0001$ , non-parametric Wilcoxon signed rank test).

At the last follow-up visit, 79% of eyes showed improvement in BCVA (Table 2). Twelve eyes (18%) had vision decrease, and two eyes had no change of vision. Among the eyes with postoperative vision deterioration, two eyes had secondary glaucoma, two eyes had a severe nuclear cataract, three eyes had residual foveoschisis, two eyes had full-thickness macular holes (FTMH), and three eyes had obvious progressive macular atrophy.

We grouped the eyes into four categories based on the different endotamponades used ( $C_3F_8$ ,  $SF_6$ , primary surgery with silicone oil, and second surgery with silicone oil; Table 3). There was no statistically significant difference in age, axial length, refractive error, or preoperative BCVA in these four groups. However, postoperative BCVA was statistically different among these four groups ( $P=0.006$ , Kruskal-Wallis test). Eyes treated with  $C_3F_8$  and  $SF_6$  tamponade had better visual acuity outcomes than eyes with silicone oil tamponade (primary or secondary), with  $P$  values of 0.02, 0.01, 0.03, 0.005 (Kruskal-Wallis test), respectively. Postoperative BCVA was not statistically different between groups treated with  $C_3F_8$  and  $SF_6$  tamponade ( $P=0.34$ , Kruskal-Wallis test).

Preoperative OCT imaging identified 45 eyes with FS and 22 eyes with FD (basic demographics shown in Table 4, with no statistically significant differences). The preoperative mean BCVAs were 1.24±0.74 logMAR for FS and 1.45±0.85 logMAR for FD ( $P=0.36$ , Mann-Whitney  $U$  test). Postoperatively, BCVA in the FS group was better than BCVA in the FD group (0.64±0.58 logMAR and 0.99±0.73 logMAR, respectively,  $P=0.01$ , Mann-Whitney  $U$  test).

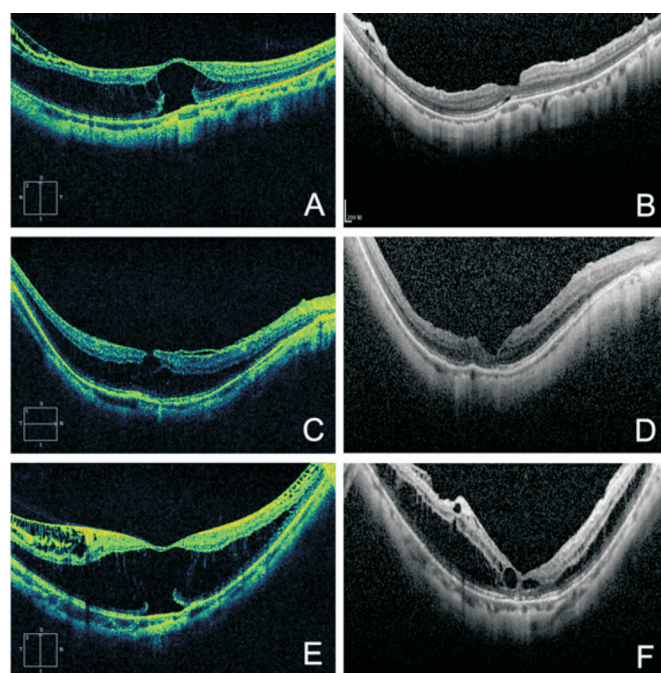
The postoperative mean BCVA was 0.91±0.68 logMAR for eyes with ellipsoid zone defect (49 eyes) and 0.35±0.32 logMAR for eyes with ellipsoid zone integrity (18 eyes).

**Macular Morphology** The mean preoperative CRT was 580.0±270.0  $\mu$ m ( $n=67$ ). Postoperatively, mean CRT in eyes without FTMH was 179.7±84.7  $\mu$ m ( $n=58$ ), which was significantly smaller ( $P<0.0001$ , non-paired Student's  $t$ -test). In 41 eyes (61%), total resolution of foveoschisis was achieved. Various types of foveoschisis remained in 26 eyes (15 eyes in the outer retina and 11 eyes in both inner and outer retina). Representative OCT imaging with different residual foveoschisis is shown in Figure 2.

**Table 2 Change of BCVA in patients who underwent vitrectomy for high MF**

| Parameters                  | Preoperative | Postoperative |
|-----------------------------|--------------|---------------|
| Snellen BCVA                |              | <i>n</i> (%)  |
| ≥20/50                      | 6 (9)        | 28 (42)       |
| 20/50 to 20/200             | 26 (39)      | 26 (39)       |
| <20/200                     | 35 (52)      | 13 (19)       |
| Change of BCVA              |              |               |
| Improvement in BCVA         | 53 (79)      |               |
| 3 lines improvement in BCVA | 44 (66)      |               |
| No change in BCVA           | 2 (3)        |               |
| Deterioration in BCVA       | 12 (18)      |               |

BCVA: Best corrected visual acuity.



**Figure 2 Typical OCT images of residual postoperative foveoschisis**  
 A: Preoperative foveoschisis in the outer retina with foveal detachment; B: The foveoschisis and foveal detachment seen in A resolved completely 24mo after the operation. The BCVA improved from Snellen 20/160 to Snellen 20/40; C: Preoperative foveoschisis in the outer retina; D: The foveoschisis seen in C partially resolved 27mo after the operation, with residual outer retinoschisis. The BCVA improved from Snellen 20/500 to Snellen 20/63; E: Preoperative foveoschisis in both outer and inner retina, with foveal detachment; F: The foveoschisis seen in E partially resolved 39mo after the operation, with residual retinoschisis in the outer and inner retina. The foveal detachment in E also resolved, and the BCVA improved from Snellen 20/160 to Snellen 20/100.

Preoperative BCVA was highly correlated with postoperative BCVA ( $P<0.001$ , multiple linear regression analysis), whereas age, axial length, refractive error, CRT, phacoemulsification, and choroid atrophy were not correlated with final visual outcome (Table 5).

**Representative Cases** Case 1: a 50-year-old woman with foveoschisis in her left eye (Figure 3) received vitrectomy with

**Table 3 Characteristics of patients treated with different tamponades**

| Parameters                | C <sub>3</sub> F <sub>8</sub> (n=32) | SF <sub>6</sub> (n=26) | Silicone oil (n=3) | Silicone oil, second surgery (n=6) | $\bar{x} \pm s$<br>P |
|---------------------------|--------------------------------------|------------------------|--------------------|------------------------------------|----------------------|
| Age (a)                   | 57.0±9.8                             | 53.9±11.9              | 61.0±4.3           | 65.0±5.1                           | 0.09                 |
| Sex (M/F, eyes)           | 13/25                                | 10/16                  | 0/3                | 1/5                                |                      |
| Axial length (mm)         | 28.9±1.6                             | 28.9±1.8               | 30.4±1.5           | 28.3±0.9                           | 0.35                 |
| Refractive error (D)      | 14.5±4.5                             | 14.5±5.1               | 18.8±4.7           | 12.8±2.9                           | 0.35                 |
| CRT (μm)                  | 557.3±256.7                          | 588.7±277.3            | 449.0±306.0        | 730.0±300.6                        | 0.43                 |
| Preoperative logMAR BCVA  | 1.37±0.80                            | 1.08±0.64              | 2.10±0.87          | 1.60±0.92                          | 0.16                 |
| Postoperative logMAR BCVA | 0.69±0.52                            | 0.55±0.47              | 1.60±0.87          | 1.58±0.98                          | 0.006                |

CRT: Central retinal thickness; logMAR: Logarithm of the minimum angle of resolution; BCVA: Best corrected visual acuity.

**Table 4 Demographics of patients and eyes in the FS and FD groups**

| Parameters                 | FS (n=45 eyes) | FD (n=22 eyes) | $\bar{x} \pm s$<br>P |
|----------------------------|----------------|----------------|----------------------|
| Age (a)                    | 56.7±10.7      | 57.7±10.5      | 0.719                |
| Gender (eyes)              |                |                |                      |
| F                          | 28             | 16             |                      |
| M                          | 17             | 6              | <sup>1</sup> 0.428   |
| Axial length (mm)          | 29.0±1.7       | 28.8±1.4       | 0.634                |
| Refractive error (diopter) | 14.8±5.0       | 14.1±4.1       | 0.571                |
| CRT (μm)                   | 477.91±228.86  | 789.0±226.27   | 0.592                |
| Preoperative logMAR BCVA   | 1.24±0.74      | 1.45±0.85      | 0.36                 |
| Postoperative logMAR BCVA  | 0.64±0.58      | 0.99±0.73      | 0.01                 |

FS: Foveoschisis only; FD: Foveoschisis with foveal detachment; CRT: Central retinal thickness; logMAR: Logarithm of the minimum angle of resolution; BCVA: Best-corrected visual acuity. <sup>1</sup>Fisher's test.

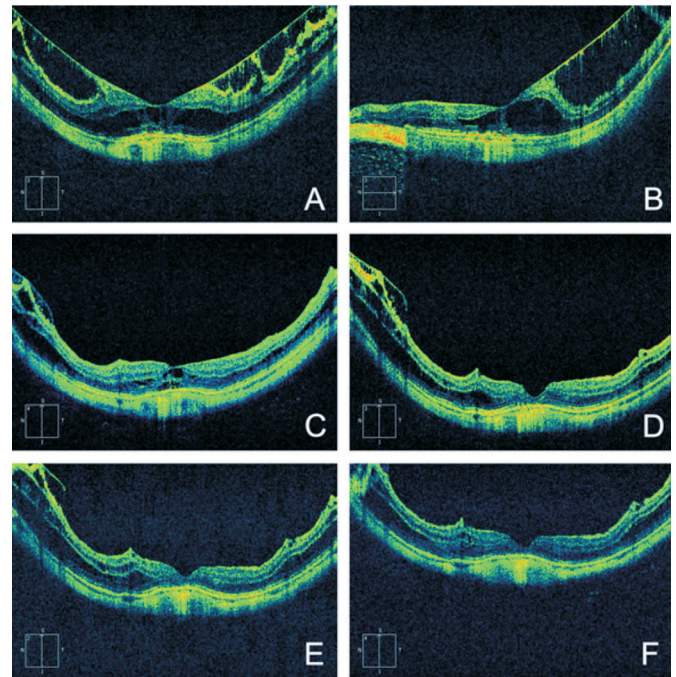
**Table 5 Correlation between preoperative factors and final post-operative BCVA in patients who underwent vitrectomy for high MF**

| Preoperative factors | P                   | β      |
|----------------------|---------------------|--------|
| Age                  | 0.720               | 0.044  |
| Axial length         | 0.691               | -0.049 |
| Refractive error     | 0.744               | -0.041 |
| Preoperative BCVA    | <sup>1</sup> <0.001 | 0.536  |
| CRT                  | 0.720               | 0.045  |
| Phacoemulsification  | 0.794               | -0.033 |
| Choroid atrophy      | 0.331               | 0.123  |

BCVA: Best-corrected visual acuity; CRT: Central retinal thickness. <sup>1</sup>Statistically significant (multiple linear regression, stepwise).

ILM peeling and C<sub>3</sub>F<sub>8</sub> tamponade in March 2009. The axial length was 28.88 mm and preoperative BCVA was Snellen 20/400. During the follow-up of 42mo, BCVA in the left eye improved to Snellen 20/50, and the foveal structure was slowly restored.

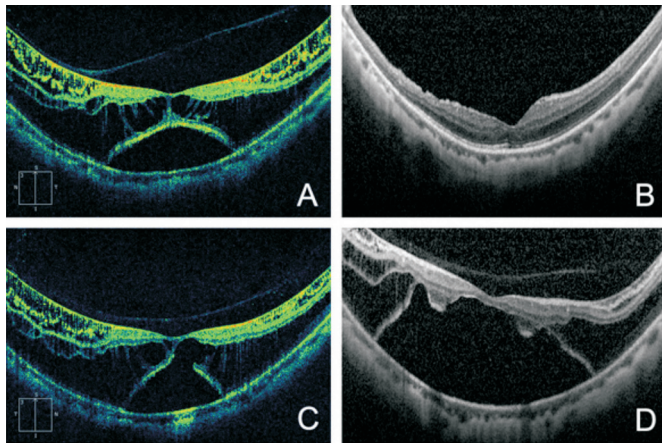
Case 2: a 60-year-old man presented with foveoschisis with FD in both eyes (Figure 4). The axial length was 27.91 mm OD and 27.84 mm OS. He was treated with vitrectomy with ILM peeling and C<sub>3</sub>F<sub>8</sub> tamponade and simultaneous cataract removal in June 2009 in the left eye, and 41mo after the operation, the postoperative BCVA in the left eye was improved from



**Figure 3 Representative long-term follow-up of a patient with foveoschisis** A: Vertical OCT scan shows preoperative foveoschisis in the outer and inner retina; B: Horizontal OCT scan shows preoperative foveoschisis in the outer and inner retina; C: One month after vitrectomy, an OCT scan shows partial restoration of the foveal structure; D: At one-year follow-up, an OCT scan shows nearly full restoration of the foveal structure. Residual extrafoveal retinoschisis is still present; E, F: Follow-up OCT scans at three (E) and four (F) years reveal stable anatomy of the fovea and gradual resolution of schisis.

preoperative Snellen 20/63 to Snellen 20/40. However, for financial reasons, the patient did not undergo surgery in his right eye. The foveoschisis and foveal detachment worsened during the following years, and the BCVA in the right eye decreased from Snellen 20/40 to Snellen 20/200 during the follow-up period.

**Complications** The short-term complications (within three months postoperatively) were FTMH in nine eyes (13%), with postoperative BCVA of 1.06±0.32 logMAR. These nine eyes did not develop retinal detachment or progression of the macular hole in the long-term follow-up. Other short-term complications included retinal detachment in six eyes (9%),



**Figure 4** Representative case of a patient with high MF in both eyes A: Foveoschisis with foveal detachment in the left eye with preoperative BCVA of Snellen 20/80; B: Forty-one months after vitrectomy, OCT image shows restoration of the foveal structure. The BCVA improved to Snellen 20/40; C: Foveoschisis with foveal detachment in the right eye, with BCVA of Snellen 20/40; D: The right eye suffered a progression of foveoschisis and the BCVA decreased to Snellen 20/200 forty-one months later without surgery.

each of which was treated with a second surgery with silicone oil tamponade, and secondary glaucoma in two eyes (3%), which was controlled with anti-glaucoma medication.

The long-term complications (more than three months postoperatively) were nuclear cataract and CNV. Cataract affected 14 of 25 eyes (56%) with preoperative clear lens; five of these affected eyes underwent cataract removal during the follow-up period, and the remaining nine eyes are still under observation. CNV occurred in three eyes (4%) and was treated with intravitreal injections of anti-vascular endothelium growth factor (anti-VEGF).

## DISCUSSION

This study of the long-term outcomes of vitrectomy showed a favourable result in a large sample. Our data confirmed that vitrectomy can improve visual acuity, with improvements seen in about 80% of eyes that received vitrectomy and ILM peeling for MF. The anatomical macular structures also remained stable over more than two years of follow up. Other long-term results of vitrectomy for MF were reported by Gaucher *et al*<sup>[10]</sup> in 2007 and Kumagai *et al*<sup>[19]</sup> in 2010, in studies that included 11 eyes and 39 eyes, respectively. Together, their work and ours strengthen the evidence supporting the necessity and efficacy of vitrectomy for eyes with MF.

Eyes in our study were treated with vitrectomy with various tamponade methods. Eyes treated with gas tamponade gained better vision during recovery than eyes treated with silicone oil. This result may have been affected by preoperative factors, because longer-action tamponade was used more frequently in eyes with severe choroid-RPE atrophy. We also found that eyes treated with silicone oil tamponade tended to develop more complications, such as cataract and glaucoma, than

eyes treated with gas tamponade. In our study, one eye with primary silicone oil tamponade had secondary glaucoma, and of six eyes treated with silicone oil tamponade during a second surgery because of macular detachment after the first operation, four developed postoperative FTMH after macular reattachment, and the remaining two eyes had persistent macular detachment. Because these complications and preoperative conditions such as choroid-RPE atrophy might be the reasons for poorer vision outcomes with silicone oil tamponade, we cannot conclude that gas tamponade is superior to silicone oil in treating MF. Indeed, silicone oil tamponade might be needed to overcome complications such as macular detachment and macular hole when the gas tamponade fails in the primary surgery. Studies comparing gas tamponade with silicone oil tamponade are needed. Recently there have been several studies advocating vitrectomy with no endotamponade as effective in treating MF<sup>[22,33]</sup>, whereas others believed that endotamponade could facilitate the anatomical resolution of foveoschisis<sup>[34]</sup>. Further investigation is needed to determine the role of tamponade in managing MF.

The necessity of ILM peeling has long been debated. Several studies reported that vitrectomy is effective in the treatment of MF<sup>[16,19-20]</sup>. The results of our retrospective study were consistent with these findings in that, of all eyes treated with traditional ILM peeling, visual acuity improved in 79%. Others have suggested that ILM peeling might contribute to the incidence of FTMH, and that vitrectomy without ILM peeling could be effective as well<sup>[29,35-37]</sup>, because in eyes with pathologic myopia, the ILM tends to be more fragile and fragmented, and the foveola is very thin, making ILM peeling extremely challenging. In our study, nine eyes (13%) developed FTMH, consistent with previously reported rates of FTMH with traditional ILM peeling (10% to 20%)<sup>[15]</sup>. Recently Shimada *et al*<sup>[38]</sup> proposed a new technique of fovea-sparing ILM peeling with no MH formation. Future investigation into the surgery technique to improve the restoration of the macular structure is still needed.

In our study, 40% of eyes had persistent residual foveoschisis in the long-term follow-up, which was higher than rate reported in other studies. Several authors have shown that foveoschisis resolved completely in more than 80% of their patients within one year after vitrectomy<sup>[15,17]</sup>. In the long-term follow-up of Gaucher *et al*<sup>[10]</sup>, schisis partially resolved in four of 11 eyes, but the duration of follow-up after vitrectomy was not mentioned. In the study by Kumagai *et al*<sup>[19]</sup>, all foveoschisis reportedly resolved, but information from OCT was still limited at that time. The reasons that residual schisis might persist remain uncertain. In our study endotamponade was used in all eyes, and schisis remained in about 40% of them more than two years after the operation. This discrepancy may be related to the demographic features of the patients,

because, in our study, posterior staphyloma was present in 97% eyes, and 40% of eyes had choroid patchy atrophy or macular atrophy. The percentage of eyes with choroid atrophy or staphyloma was not mentioned in the previous studies<sup>[15,17]</sup>, which makes it difficult to investigate these conditions as reasons for the residual foveoschisis.

We found that, in the long term, eyes with FS achieved better postoperative BCVA than eyes with FD, which is not consistent with the results of others<sup>[17,19]</sup>. Ikuno *et al*<sup>[17]</sup> proposed that the reattachment of photoreceptors in FD could be more beneficial. Thus, the ellipsoid zone integrity (previously IS/OS integrity), rather than the presence of FD, may be a predictive factor for postoperative vision improvement. Consistent with this and other reports<sup>[23,39]</sup>, in our study postoperative BCVA of eyes with ellipsoid zone integrity was better than the postoperative BCVA of eyes with ellipsoid zone interruption, indicating that ellipsoid zone status is important for visual gain after vitrectomy.

Other complications after vitrectomy in our patients included cataract, retinal detachment, secondary glaucoma, and CNV. The cataracts were surgically managed with satisfactory results. The retinal detachment and secondary glaucoma also needed to be dealt with promptly to rescue the patients' poor vision. CNV developed in three eyes (5%) in our study. Because CNV may develop in about 10% of patients with pathologic myopia<sup>[40]</sup>, we do not consider the long-term complication of CNV in our study to be related to the operation. However, in our study, a patient suffered a newly developed CNV after three years of regular follow-up, and the BCVA deteriorated from 20/30 to 20/400 immediately. Thus, the progression of cataracts postoperatively and the possibility of other complications highlight the importance of long-term follow-up, because both cataracts and CNV are manageable with relatively good prognosis, and active treatment of retinal detachment and glaucoma could help preserve vision.

**Limitations** First, our study was retrospective and did not include controls. Second, because this is a long-term study, the criteria for recommending undergo vitrectomy may have been subtly different in the early years in the practice of the surgeon. In the early years, the surgeon was inclined to operate on eyes with obvious choroid atrophy or macular atrophy in an attempt to rescue poor eyesight; this may have resulted in a higher incidence of complications such as retinal detachment and macular holes. However, we did not do analysis to see whether complications were higher in early years than in later years, because analysis could be biased from different baseline of patients and surgical techniques. Third, about 63% of eyes had cataract removal at the same time as vitrectomy, which might have contributed to the improvement of postoperative visual acuity. However, the correlation between phacoemulsification and postoperative BCVA was not statistically significant, consistent with the report of Kumagai *et al*<sup>[19]</sup>.

In summary, our study showed that vitrectomy with ILM peeling was an effective way to treat MF. Long-term follow-up results showed that visual acuity and foveal structures remained stable in patients who underwent vitrectomy for MF, even in eyes with postoperative FTMH. Possible long-term complications should be followed to prevent deterioration of the already relatively poor sight in patients with pathologic myopia.

#### ACKNOWLEDGEMENTS

**Foundation:** Supported by the National Key Basic Research Program of China (No.2013CB967503).

**Conflicts of Interest:** Zhang T, None; Zhu Y, None; Jiang CH, None; Xu GZ, None.

#### REFERENCES

- 1 Vitale S, Sperduto RD, Ferris FL 3rd. Increased prevalence of myopia in the United States between 1971-1972 and 1999-2004. *Arch Ophthalmol* 2009;127(12):1632-1639.
- 2 Wong TY, Foster PJ, Hee J, Ng TP, Tielsch JM, Chew SJ, Johnson GJ, Seah SK. Prevalence and risk factors for refractive errors in adult Chinese in Singapore. *Invest Ophthalmol Vis Sci* 2000;41(9):2486-2494.
- 3 Iwase A, Araie M, Tomidokoro A, Yamamoto T, Shimizu H, Kitazawa Y. Prevalence and causes of low vision and blindness in a Japanese adult population: the Tajimi Study. *Ophthalmology* 2006;113(8):1354-1362.
- 4 Xu L, Wang Y, Li Y, Wang Y, Cui T, Li J, Jonas JB. Causes of blindness and visual impairment in urban and rural areas in Beijing: the Beijing Eye Study. *Ophthalmology* 2006;113(7):1134.e1-11.
- 5 Takano M, Kishi S. Foveal retinoschisis and retinal detachment in severely myopic eyes with posterior staphyloma. *Am J Ophthalmol* 1999;128(4):472-476.
- 6 Panozzo G, Mercanti A. Optical coherence tomography findings in myopic traction maculopathy. *Arch Ophthalmol* 2004;122(10):1455-1460.
- 7 Ikuno Y, Gomi F, Tano Y. Potent retinal arteriolar traction as a possible cause of myopic foveoschisis. *Am J Ophthalmol* 2005;139(3):462-467.
- 8 Todorich B, Scott IU, Flynn HW Jr, Chang S. Macular retinoschisis associated with pathologic myopia. *Retina* 2013;33(4):678-683.
- 9 Shimada N, Ohno-Matsui K, Baba T, Futagami S, Tokoro T, Mochizuki M. Natural course of macular retinoschisis in highly myopic eyes without macular hole or retinal detachment. *Am J Ophthalmol* 2006;142(3):497-500.
- 10 Gaucher D, Haouchine B, Tadayoni R, Massin P, Erginay A, Benhamou N, Gaudric A. Long-term follow-up of high myopic foveoschisis: natural course and surgical outcome. *Am J Ophthalmol* 2007;143(3):455-462.
- 11 Hayashi K, Ohno-Matsui K, Shimada N, Moriyama M, Kojima A, Hayashi W, Yasuzumi K, Nagaoka N, Saka N, Yoshida T, Tokoro T, Mochizuki M. Long-term pattern of progression of myopic maculopathy: a natural history study. *Ophthalmology* 2010;117(8):1595-1611.
- 12 Matsumura N, Ikuno Y, Tano Y. Posterior vitreous detachment and macular hole formation in myopic foveoschisis. *Am J Ophthalmol* 2004;138(6):1071-1073.
- 13 Sayanagi K, Ikuno Y, Tano Y. Tractional internal limiting membrane detachment in highly myopic eyes. *Am J Ophthalmol* 2006;142(5):850-852.

- 14 Fujiwara T, Imamura Y, Margolis R, Slakter JS, Spaide RF. Enhanced depth imaging optical coherence tomography of the choroid in highly myopic eyes. *Am J Ophthalmol* 2009;148(3):445-450.
- 15 Kobayashi H, Kishi S. Vitreous surgery for highly myopic eyes with foveal detachment and retinoschisis. *Ophthalmology* 2003;110(9):1702-1707.
- 16 Ikuno Y, Sayanagi K, Ohji M, Kamei M, Gomi F, Harino S, Fujikado T, Tano Y. Vitrectomy and internal limiting membrane peeling for myopic foveoschisis. *Am J Ophthalmol* 2004;137(4):719-724.
- 17 Ikuno Y, Sayanagi K, Soga K, Oshima Y, Ohji M, Tano Y. Foveal anatomical status and surgical results in vitrectomy for myopic foveoschisis. *Jpn J Ophthalmol* 2008;52(4):269-276.
- 18 Fang X, Weng Y, Xu S, Chen Z, Liu J, Chen B, Wu P, Ni H, Yao K. Optical coherence tomographic characteristics and surgical outcome of eyes with myopic foveoschisis. *Eye (Lond)* 2009;23(6):1336-1342.
- 19 Kumagai K, Furukawa M, Ogino N, Larson E. Factors correlated with postoperative visual acuity after vitrectomy and internal limiting membrane peeling for myopic foveoschisis. *Retina* 2010;30(6):874-880.
- 20 Zheng B, Chen Y, Zhao Z, Zhang Z, Zheng J, You Y, Wang Q, Shen L. Vitrectomy and internal limiting membrane peeling with perfluoropropane tamponade or balanced saline solution for myopic foveoschisis. *Retina* 2011;31(4):692-701.
- 21 Jo Y, Ikuno Y, Nishida K. Retinoschisis: a predictive factor in vitrectomy for macular holes without retinal detachment in highly myopic eyes. *Br J Ophthalmol* 2012;96(2):197-200.
- 22 Lim SJ, Kwon YH, Kim SH, You YS, Kwon OW. Vitrectomy and internal limiting membrane peeling without gas tamponade for myopic foveoschisis. *Graefes Arch Clin Exp Ophthalmol* 2012;250:1573-1577.
- 23 Shin JY, Yu HG. Visual prognosis and spectral-domain optical coherence tomography findings of myopic foveoschisis surgery using 25-gauge transconjunctival sutureless vitrectomy. *Retina* 2012;32(3):486-492.
- 24 Ripandelli G, Coppe AM, Fedeli R, Parisi V, D'Amico DJ, Stirpe M. Evaluation of primary surgical procedures for retinal detachment with macular hole in highly myopic eyes: a randomized comparison of vitrectomy versus posterior episcleral buckling surgery. *Ophthalmology* 2001;108(12):2258-2264.
- 25 Ward B, Tarutta EP, Mayer MJ. The efficacy and safety of posterior pole buckles in the control of progressive high myopia. *Eye (Lond)* 2009;23(12):2169-2174.
- 26 Zhu Z, Ji X, Zhang J, Ke G. Posterior scleral reinforcement in the treatment of macular retinoschisis in highly myopic patients. *Clin Experiment Ophthalmol* 2009;37(7):660-663.
- 27 Gili P, Yanguela J, Martin JC. Intraocular gas treatment for myopic foveoschisis. *Eur J Ophthalmol* 2010;20(2):473-475.
- 28 EI Rayes EN. Supra choroidal buckling in managing myopic vitreoretinal interface disorders: 1-year data. *Retina* 2014;34(1):129-135.
- 29 Kwok AK, Lai TY, Yip WW. Vitrectomy and gas tamponade without internal limiting membrane peeling for myopic foveoschisis. *Br J Ophthalmol* 2005;89(9):1180-1183.
- 30 Hwang JU, Joe SG, Lee JY, Kim JG, Yoon YH. Microincision vitrectomy surgery for myopic foveoschisis. *Br J Ophthalmol* 2013;97(7):879-884.
- 31 Chuang LH, Chen YP, Wang NK, Yeung L, Chen KJ, Hwang YS, Wu WC, Chen TL, Lai CC. Macular hole repair by vitrectomy and internal limiting membrane peeling in highly myopic eyes. *Retina* 2014;34(10):2021-2027.
- 32 Roberts MF, Fishman GA, Roberts DK, Heckenlively JR, Weleber RG, Anderson RJ, Grover S. Retrospective, longitudinal, and cross sectional study of visual acuity impairment in choroideaemia. *Br J Ophthalmol* 2002;86(6):658-662.
- 33 Uchida A, Shinoda H, Koto T, Mochimaru H, Nagai N, Tsubota K, Ozawa Y. Vitrectomy for myopic foveoschisis with internal limiting membrane peeling and no gas tamponade. *Retina* 2014;34(3):455-460.
- 34 Panozzo G, Mercanti A. Vitrectomy for myopic traction maculopathy. *Arch Ophthalmol* 2007;125(6):767-772.
- 35 Spaide RF, Fisher Y. Removal of adherent cortical vitreous plaques without removing the internal limiting membrane in the repair of macular detachments in highly myopic eyes. *Retina* 2005;25(3):290-295.
- 36 Yeh SI, Chang WC, Chen LJ. Vitrectomy without internal limiting membrane peeling for macular retinoschisis and foveal detachment in highly myopic eyes. *Acta Ophthalmol* 2008;86(2):219-224.
- 37 Ho TC, Chen MS, Huang JS, Shih YF, Ho H, Huang YH. Foveola nonpeeling technique in internal limiting membrane peeling of myopic foveoschisis surgery. *Retina* 2012;32(3):631-634.
- 38 Shimada N, Sugamoto Y, Ogawa M, Takase H, Ohno-Matsui K. Fovea-sparing internal limiting membrane peeling for myopic traction maculopathy. *Am J Ophthalmol* 2012;154(4):693-701.
- 39 Wakabayashi T, Fujiwara M, Sakaguchi H, Kusaka S, Oshima Y. Foveal microstructure and visual acuity in surgically closed macular holes: spectral-domain optical coherence tomographic analysis. *Ophthalmology* 2010;117(9):1815-1824.
- 40 Ohno-Matsui K, Yoshida T, Futagami S, Yasuzumi K, Shimada N, Kojima A, Tokoro T, Mochizuki M. Patchy atrophy and lacquer cracks predispose to the development of choroidal neovascularisation in pathological myopia. *Br J Ophthalmol* 2003;87(5):570-573.