

Assessment of contrast sensitivity loss after intrastromal femtosecond laser and LASIK procedure

Elsa L. C. Mai¹, Ie-Bin Lian², David C. K. Chang³

¹Far Eastern Memorial Hospital, Taipei 100, Taiwan, China

²National Changhua University of Education, Changhua 500, Taiwan, China

³Taiwan Nobel Eye Institute, Taipei 100, Taiwan, China

Correspondence to: David C. K. Chang. Taiwan Nobel Eye Institute, #13 Gongyuan Rd. Taipei 100, Taiwan, China. chaokai@nobelgroup.com.tw

Received: 2016-02-02 Accepted: 2016-06-12

Abstract

• **AIM:** To assess the loss of contrast sensitivity (CS) function for INTRACOR or intrastromal femtosecond laser presbyopia procedure to conventional LASIK procedures.

• **METHODS:** Patients were recruited from a refractive surgery center for either INTRACOR or conventional LASIK. INTRACOR was performed on 8 eyes and LASIK was performed for 40 eyes in an overlapping period. Pre-operative evaluation and post-operative follow up for up to three months was done. Drops of CS in 4 spatial frequency (3 cpd, 6 cpd, 12 cpd and 18 cpd) right before and 3mo after the surgery were compared by Wilcoxon signed ranks test.

• **RESULTS:** For INTRACOR, CS threshold showed significant drop at both glare and non-glare condition, the drop was seen in all 4 spatial frequency. The averaged loss over the 4 spatial frequencies 3mo after surgery was 1.18 for non-glare and 0.71 for glare. For LASIK the CS threshold drop was most significant in 12 cpd for glare.

• **CONCLUSION:** INTRACOR procedure produces a gain of near vision for presbyopia patients but also introduces a high loss of contrast sensitivity plus worsen of vision quality. Pre-surgical patient selection and advise should be given with specific regards to night driving and glare conditions.

• **KEYWORDS:** INTRACOR; LASIK; contrast sensitivity; intrastromal femtosecond laser

DOI:10.18240/ijo.2016.12.16

Mai ELC, Lian IB, Chang DCK. Assessment of contrast sensitivity loss after intrastromal femtosecond laser and LASIK procedure. *Int J Ophthalmol* 2016;9(12):1798–1801

INTRODUCTION

In the era of myopia and hyperopia cornea refractive surgery, presbyopia remains an unsolved issue, surgeons move from cornea treatment to lens treatment with multifocal lens to compensate for near reading requirements. Laser cornea treatment with monovision is also available. Multifocality laser cornea treatment is on the market, sclera implants or sclera laser anterior ciliary incision (Laser ACE)^[1] to relax the sclera and to provide more accommodation power is also tried. Corneal inlays, Supracor and laser blended vision are all ways to manage presbyopia. But all these ways involve compromise of one or another entity of the vision; for example, in multifocal IOLs^[2], the risk of an intra ocular surgery has to be taken. The bifocal or trifocal IOL produce a line of focus with trade-offs compare to monovision, with the lowering of the optimistic best corrected visual acuity (BCVA). In the micro-monovision method, it is a trade-off between stereopsis and focal distant vision. It was consider that a difference of less then 1.5 D is the maximum symptom free allowance for stereopsis^[3-4]. Cornea inlays, although relatively easy and precise with the femtosecond laser assisted mode, involve insertion of an artificial material into the cornea stroma with the aim of constriction of pupil to elongate the depth of field; therefore, producing a simulated near vision. Also similar is the presby LASIK or laser bland vision, both induce a multifocality on the cornea with the trade-off of contrast sensitivity, which is an important measure for assessing surgery^[5-6].

With the introduction of femtosecond laser technology, INTRACOR procedure with intrastromal vertical and concentric cornea cuts can be produced^[7]. These laser incision changes the biomechanical force of the cornea, leading to a change in cornea curvature^[8] and subsequently improve of near visual acuity^[9-10]. These intrastromal procedure are without external epithelial wounds and was deem to be efficient and without serious adverse effect after a 3y follow up study^[11]. But review shows a case report of keratectasia after INTRACOR^[12], another study with modified INTRACOR pattern show a median lose of one line of corrected distance visual acuity (CDVA)^[13]. With a bilateral INTRACOR study, it was found to have a 2 line loss of CDVA in 5.9% of the patients^[14]. With these controversial results and the poor popularity of this procedure among our patients prompt us to investigate further^[15]. Our study presents

Table 1 Demographic and clinical characters of 8 INTRACOR patients and 20 LASIK patients

Parameters	INTRACOR	LASIK	¹ P
Age (95% CI) (a)	54.87 (52.29, 57.45)	31.25 (28.45, 34.05)	<0.001
Male/Female	3/5	6/14	0.320
Initial contrast sensitivity			
Glare	C-3	5.78 (5.08, 6.48)	0.760
	C-6	5.67 (4.99, 6.36)	0.398
	C-12	6.01 (5.18, 6.84)	0.200
	C-18	5.68 (5.42, 5.94)	<0.001
Non-glare	C-3	5.13 (4.18, 6.07)	0.421
	C-6	4.63 (3.54, 5.71)	0.510
	C-12	5.00 (3.82, 6.18)	0.688
	C-18	4.63 (2.90, 6.35)	0.680

¹P: *t*-test.

Table 2 Comparison of the contrast sensitivity threshold change between INTRACOR and LASIK patients

Groups	Cycle per degree	INTRACOR (95% CI) (n=8)	¹ P	LASIK (95% CI) (n=40)	² P
Non-glare	C-3	-1.01 (-2.42, 0.39)	0.086	0.35 (-0.15, 0.85)	0.069
	C-6	-1.37 (-2.30, -0.44)	0.008	0.23 (-0.46, 0.91)	0.331
	C-12	-1.06 (-2.74, 0.63)	0.148	-0.63 (-1.24, -0.01)	0.024
	C-18	-1.26 (-2.51, -0.02)	0.039	-0.40 (-1.11, 0.31)	0.167
	Average	-1.18		-0.11	
Glare	C-3	-0.66 (-1.70, 0.39)	0.086	-0.28 (-0.73, 0.18)	0.173
	C-6	-0.14 (-1.42, 1.15)	0.453	-0.70 (-1.26, -0.14)	0.007
	C-12	-1.05 (-2.17, 0.07)	0.031	-0.93 (-1.52, -0.33)	0.002
	C-18	-0.97 (-2.04, 0.09)	0.031	-0.18 (-0.81, 0.46)	0.387
	Average	-0.71		-0.52	

¹P: One-sided Wilcoxon signed ranks test; ²P: Two sample *t*-test.

the use of INTRACOR procedures on our hyperopia patients aiming for an emmetropia target vision and to investigate the contrast sensitivity (CS) loss after this procedure.

SUBJECTS AND METHODS

Patients were recruited from refractive surgery center for both INTRACOR or conventional LASIK from Aug. 2011 to Aug. 2012. All patients were given informed consent prior to the enrollment. Inclusion criteria for INTRACOR were presbyopia patients with less than +1.0 diopter of hyperopia and a minimum near add of +2.00 diopter at 40 cm for best correct near vision. Inclusion criteria for conventional LASIK procedure without wavefront guidance were done for both hyperopia and myopia patients. Patients who had not been followed-up for more than three months were excluded. INTRACOR procedure (Technolas 520F femtosecond laser-Technolas Perfect Vision GmbH, Munich, Germany) was performed on 8 eyes. Conventional LASIK was performed for 40 eyes overlapping the INTRACOR procedures. Pre-operative evaluation and post-operative follow up for one day, one month, and three months. Evaluation parameters included as below, uncorrected visual acuity (UCVA) for near and far, best corrected visual acuity (BCVA) for near and far, auto-refraction, Topo/Orbscan, wavescan aberrometer, pupilometer, pachymeter, CS test evaluation

was done with CSV-1000E Vector Vision with and without glare stimulus.

Statistical Analysis CS threshold was measured at 4 spatial frequencies (SF) (3 cpd, 6cpd, 12 cpd and 18 cpd) before and after surgery. Two-sample *t*-test was applied to compare the demographic and clinical characters between INTRACOR and LASIK groups. Wilcoxon signed ranks test was applied to examine if there was significant drop of CS after procedure. A 5% level of significance was used for all the tests.

All the authors and data manager had received Good Clinical Practice Training, and the principles outlined in the Declaration of Helsinki was followed.

RESULTS

Table 1 shows that the LASIK patients group were significantly younger than the INTRACOR patients. However both groups has similar sex-ratio, and similar initial CS at 3 cpd, 6 cpd and 12 cpd three SF under both glare and non-glare conditions. The only exception is 18 cpd under glare condition, at which the INTRACOR patients had higher initial CS than the LASIK patients (5.68 vs 4.68).

In Table 2, the comparison between the pre- and post-operative CS after INTRACOR surgery shows drop of CS under both glare and non-glare condition, and the drop

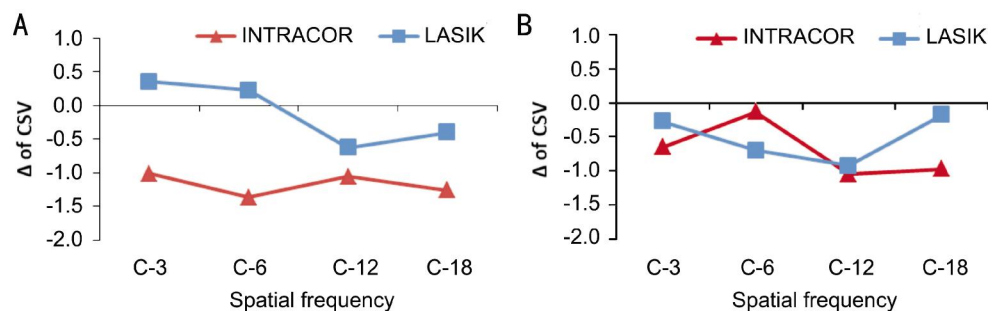


Figure 1 Comparing the magnitude of CS drop between INTRACOR and LASIK under (A) glare and (B) non-glare conditions.

was significant at 12 cpd and 18 cpd under glare and at 6 cpd and 18 cpd under non-glare. For LASIK procedures the CS threshold drop was most significant at 6 cpd and 12 cpd SF under glare and at 12 cpd SF under non-glare. Figure 1 compares the magnitude of CS drop between INTRACOR and LASIK under glare (A) and non-glare (B) condition. A more severe drop of CS threshold for INTRACOR was observed at 3 cpd and 6 cpd SF, of which the difference has reached statistical significance under non-glare condition with *P*-values 0.031 and 0.047 respectively.

DISCUSSION

There are many ways to manage presbyopia, INTRACOR is one proposed way [16-17]. The mechanism of the treatment is to do intrastromal, perpendicular incision with a femtosecond laser. Due to the specific principle of this laser, no superficial wounds were induced, the treatment time is short and effective, with no disruption to patient's working schedule. Recent published data [11] shows a stable refraction result for a follow up of three years. Post-operative no significant loss of endothelial cell count was found [18]. However, a study published in 2012 showed loss in mesopic CS after INTRACOR [19]. Another study [20] showed a case report with severe loss of BCVA and quality of vision after consecutive procedure of hyperopia LASIK and INTRACOR.

In our hands, although the results for visual acuity are somewhat similar with effective results for the low hyperopes group, resultant high CS loss in the patients eye degrades the satisfactory rate of the patients. This render the procedure to be unpopular in our clinic. The possibility of the high contrast sensitivity loss may be due to multifocality in the cornea or overly decrease spherical aberration with induce high order aberration. The fluctuation of vision was not seen in our small series, but remains an issue with the cornea being weakened by the five ring cuts 90% deep into the cornea, producing an iatrogenic ectasia of the central cornea. A limitation of the study is the lack of matching control between INTRACOR and LASIK groups; however, Table 1 shows that the initial CS of these two groups are quite similar. This study suggests that INTRACOR procedure can produce a gain of near vision for presbyopia patients but also introduce a higher lost of CS plus worsen of vision quality.

The averaged loss over the 4 SFs 3mo after surgery is 1.18 for non-glare and 0.71 for glare. On the other hand, the loss of CS for conventional LASIK procedure is mainly for glare, with average 0.52 over the 4 SFs. Pre-surgical patient selection and inform consent should be given with specific regards to night driving and glare conditions. Due to the small cohort of patients we have, we urge for further work to look at aberration and CS of this method.

ACKNOWLEDGEMENTS

Conflicts of Interest: Mai ELC, None; Lian IB, None; Chang DCK, None.

REFERENCES

- Swartz TS, Rocha KM, Jackson M, Ma DH, Goldberg D, Hipsley A. Restoration of accommodation: new perspectives. *Arg Bras Oftalmol* 2014; 77(1):V-VII.
- Rabsilber TM, Holzer MP, Auffarth GU. Cataract surgery after Intracor and Supracor. *Cataract & Refractive Surgery Today Europe* Sep 2012: cover story.
- Fernández EJ, Schwarz C, Prieto PM, Manzanera S, Artal P. Impact on stereo-acuity of two presbyopia correction approaches: monovision and small aperture inlay. *Biomed Opt Express* 2013;4(6):822-830.
- Gong XH, Zheng QX, Wang N, Chen D, Zhao J, Li J, Zhao YE. Visual and optical performance of eyes with different corneal spherical aberration implanted with aspheric intraocular lens. *Int J Ophthalmol* 2012;5 (3): 323-328.
- Akdemir MO, Kandemir B, Sayman IB, Selvi C, Kamil Dogan O. Comparison of contrast sensitivity and visual acuity between deep anterior lamellar keratoplasty and penetrating keratoplasty in patients with keratoconus. *Int J Ophthalmol* 2012;5(6):737-741.
- Li JH, Feng YF, Zhao YE, Zhao YY, Lin L. Contrast visual acuity after multifocal intraocular lens implantation: aspheric versus spherical design. *Int J Ophthalmol* 2014;7(1):100-103.
- Bohac M, Gabric N, Anticic M, Draca N, Dekaris I. First results of Intracor procedure in Croatia. *Coll Antropol* 2011;35(Suppl 2):161-166.
- Trinh L, Francoz M, Chong-Sit D, Labbé A, Dupont-Monod S, Baudouin C. Corneal imaging of intrastromal femtosecond laser treatment for presbyopia (Intracor®). *J Fr Ophthalmol* 2013;36(8):669-676.
- Holzer MP, Knorz MC, Tomalla M, Neuhann TM, Auffarth GU. Intrastromal femtosecond laser presbyopia correction: 1-year results of a multicenter study. *J Refract Surg* 2012;28(3):182-188.
- Joshaghani M, Aghazadeh-Amiri M, Mirzaei M. Evaluation of INTRACOR surgery effect on visual acuity and refractive error of presbyopic people. *J Rehab Med* 2014;3(2):39-45.
- Khoramnia R, Fitting A, Rabsilber TM, Thomas BC, Auffarth GU, Holzer MP. Intrastromal femtosecond laser surgical compensation of

- presbyopia with six intrastromal ring cuts: 3-year results. *Br J Ophthalmol* 2015;99(2):170-176.
- 12 Taneri S, Oehler S. Keratectasia after treating presbyopia with INTRACOR followed by SUPRACOR enhancement. *J Refract Surg* 2013; 29(8):573-576.
- 13 Thomas BC, Fitting A, Auffarth GU, Holzer MP. Femtosecond laser correction of presbyopia (INTRACOR) in emmetropes using a modified pattern. *J Refract Surg* 2012;28(12):872-878.
- 14 Khoramnia R, Holzer MP, Fitting A, Auffarth GU, Rabsilber TM. Functional results after bilateral intrastromal femtosecond laser correction of presbyopia. *Ophthalmologe* 2013;110(12):1163-1170.
- 15 Arba Mosquera S, Alió JL. Presbyopic correction on the cornea. *Eye Vis* 2014;1:5.
- 16 Ruiz LA, Cepeda LM, Fuentes VC. Intrastromal correction of presbyopia using a femtosecond laser system. *J Refract Surg* 2009;25(10):847-854.
- 17 Holzer MP, Mannsfeld A, Ehmer A, Auffarth GU. Early outcomes of INTRACOR femtosecond laser treatment for presbyopia. *J Refract Surg* 2009;25(10):855-861.
- 18 Menassa N, Fitting A, Auffarth GU, Holzer MP. Visual outcomes and corneal changes after intrastromal femtosecond laser correction of presbyopia. *J Cataract Refract Surg* 2012;38(5):765-773.
- 19 Fitting A, Menassa N, Auffarth GU, Holzer MP. Effect of intrastromal correction of presbyopia with femtosecond laser (INTRACOR) on mesopic contrast sensitivity. *Ophthalmologe* 2012;109(10):1001-1007.
- 20 Saad A, Grise-Dulac A, Gatinel D. Bilateral loss in the quality of vision associated with anterior corneal protrusion after hyperopic LASIK followed by intrastromal femtolaser-assisted incisions. *J Cataract Refract Surg* 2010;36(11):1994-1998.