

# Comparison of the anti-inflammatory effects of fluorometholone 0.1% combined with levofloxacin 0.5% and tobramycin/dexamethasone eye drops after cataract surgery

Pei-Qing Chen<sup>1</sup>, Xue-Mei Han<sup>2</sup>, Ya-Nan Zhu<sup>1</sup>, Jia Xu<sup>1</sup>

<sup>1</sup>Eye Center, the Second Affiliated Hospital of Zhejiang University School of Medicine, Hangzhou 310009, Zhejiang Province, China

<sup>2</sup>Zhejiang Hospital of Traditional Chinese Medicine, Hangzhou 310006, Zhejiang Province, China

**Correspondence to:** Pei-Qing Chen. Eye Center, the Second Affiliated Hospital of Zhejiang University School of Medicine, Hangzhou 310009, Zhejiang Province, China. qingqinghz@163.com

Received: 2015-11-09 Accepted: 2016-04-28

## Abstract

• **AIM:** To compare the combination of fluorometholone 0.1% and levofloxacin 0.5% to tobramycin/dexamethasone eye drops in controlling inflammation and preventing infection after phacoemulsification with an intraocular lens implantation.

• **METHODS:** Sixty eyes from 60 patients undergoing cataract phacoemulsification were randomized into two groups; half of the patients were treated with fluorometholone (6 times/d) combined with levofloxacin (4 times/d), while the other half were treated with tobramycin/dexamethasone (4 times/d) eye drops for one week. Preoperative and postoperative intraocular pressure, aqueous flare, corneal thickness, and signs and symptoms were recorded before the operation and 1wk following treatments.

• **RESULTS:** There were no statistically significant differences between the two groups in corneal thickness ( $P \geq 0.629$ ), aqueous flare ( $P \geq 0.398$ ), and signs and symptoms scores ( $P \geq 0.350$ ) at each time point. Ocular hypertension was only observed in two eyes in the tobramycin/dexamethasone group.

• **CONCLUSION:** Fluorometholone combined with levofloxacin treatment shows comparable efficacy but without the tendency to increase intraocular pressure; thus, it might be a better regimen for postoperative use.

• **KEYWORDS:** fluorometholone; levofloxacin; tobramycin/dexamethasone; phacoemulsification; inflammation

DOI:10.18240/ijo.2016.11.13

Chen PQ, Han XM, Zhu YN, Xu J. Comparison of the anti-inflammatory effects of fluorometholone 0.1% combined with levofloxacin 0.5% and tobramycin/dexamethasone eye drops after cataract surgery. *Int J Ophthalmol* 2016;9(11):1619-1623

## INTRODUCTION

Cataracts are a leading cause of vision impairment in older people [1-2]. Since phacoemulsification surgery has become the most frequently employed method of cataract extraction, cataract surgery outcomes have improved significantly, while the extent of ocular injuries has decreased [3]. However, ocular inflammatory reactions, which may be induced by surgical trauma, have not been eliminated, and the inflammation may cause unwanted complications including corneal edema, cystoid macular edema, and excessive cicatrization [4]. Furthermore, perioperative incision infections or endophthalmitis are serious complications with cataract surgery due to their devastating consequences.

Topical corticosteroids are used to prevent or suppress postoperative inflammation, and antibiotic ophthalmic solution administration is a standard treatment in prophylactic regimens for wound infection or endophthalmitis [5]. As a topical steroid/antibiotic fixed combination, tobramycin/dexamethasone (TobraDex) ophthalmic drops have been used effectively to control inflammation and prevent infection [6]. However, dexamethasone may cause certain side effects including corticosteroid-induced ocular hypertension (OHT) and secondary glaucoma [7].

There is a significant need for topical anti-inflammatory agents with comparable efficacy but without a significant tendency to increase intraocular pressure (IOP). It has been reported that treatment with fluorometholone results in a significantly attenuated IOP increase compared to dexamethasone treatment [8]. The mean increase in IOP was 8.58 mm Hg with dexamethasone 0.1% four-times daily for 6wk as compared to 2.96 mm Hg with fluorometholone 0.1% ( $P < 0.001$ ), which was administered similarly. The percentage of patients treated with dexamethasone or fluorometholone who experienced IOP increases of  $\geq 10$  mm Hg were 45.8% and 4.2%, respectively.

In a previous study, fluorometholone was not as potent as commonly used steroids in reducing post-operative inflammation [9], but other inconsistent results have been reported [10-11]. Therefore, the efficacy of fluorometholone in reducing inflammation after phacoemulsification is unclear.

In this study, we determined the differences in the treatment effects of tobramycin/dexamethasone and fluorometholone combined with levofloxacin, a broad-spectrum antibiotic drug, on postsurgical inflammation suppression and infection prevention.

## **SUBJECTS AND METHODS**

**Subjects** The Institutional Review Board approval was obtained for this study. All patients were informed about the study design and provided their written informed consent. The study protocol was approved by the Central Ethics Committee (Ethics Committee of the Second Affiliated Hospital of Zhejiang University School of Medicine). Sixty male or female age-related cataract patients undergoing phacoemulsification with posterior chamber intraocular lens (IOL) implantation between October 2013 and January 2014 were enrolled. Preoperatively, all patients underwent a routine ophthalmological examination, *i.e.* slit-lamp examination, measurement of best corrected visual acuity (BCVA), IOP, funduscopy, and a complete medical history. The cataracts were graded by LOCS III classification. They were all xanthoderm Han Chinese People, aged 53-84y (mean age:  $70.38 \pm 7.71$ y). Their preoperative visual acuity ranged from hand movements to 0.4 (E chart), they also had age-related cataracts with a nuclear density degree of III to IV. After the cataract surgery, the patients were randomly assigned into two groups (group A and group B) using a list created by a random number generator. Group A was administered fluorometholone ophthalmic solution 0.1% at a dosage of one drop six times daily and one drop of levofloxacin ophthalmic solution 0.5% four times a day for 1wk ( $n=30$ ). Group B was administered tobramycin/dexamethasone ophthalmic solution one drop four times a day for 1wk ( $n=30$ ). Patients excluded from this study included: 1) patients who were suffering from any ocular diseases that would interfere with the assessment, such as corneal disease, uveitis, glaucoma, retinal detachment, or optic neuropathy; 2) patients who were suffering from any systemic diseases that might affect treatment responses or evaluations, including diabetes mellitus; 3) patients who had taken systemic or topical anti-inflammatory agents within the previous 30d; 4) patients who had suffered from surgical complications, such as posterior capsule rupture; 5) patients with special diseases that could affect eye surgery, such as limitations in pupil dilation.

**Surgical Technique** A continuous curvilinear capsulorhexis and phacoemulsification was performed by a small incision with the Bausch & Lomb Stellaris system. An acrylic

foldable IOL was then implanted in the capsular bag. All operations were performed by one surgeon (Chen PQ).

**Trial Drugs** The dosage of ophthalmic solutions was fluorometholone 0.1% (Santen Pharmaceutical Co., Ltd.) administered at one drop in the treated eye six times per day, one drop of levofloxacin 0.5% (Santen Pharmaceutical Co., Ltd.) four times per day, and, in the other group, tobramycin/dexamethasone (tobramycin 0.3% and dexamethasone 0.1%, S.A. ALCON-COUVREUR N.V.) was administered one drop four times per day. The pharmacological treatments were performed along with conventional postsurgical therapy for the first postoperative week.

All patients received pranoprofen (Senju Pharmaceutical Co., Ltd.) eye drops to prevent long-term cystoid macular edema and sodium hyaluronate 0.3% (Santen Pharmaceutical Co., Ltd.) eye drops to prevent postoperative dry eye.

**Clinical Assessments** All measurements were performed by the same technician during the preoperative period, on the first postoperative day (day 1), and on postoperative day 7. Tables 1 and 2 show the scoring systems for the signs and symptoms. The IOP was measured by the same non-contact IOP gauge (NT-2000, Nidek) and the results were the average of three measurements. OHT was defined as an  $IOP \geq 21$  mm Hg. The aqueous flare was measured with the same laser flare-cell photometer (FC-2000; Kowa Co., Ltd.) with dilated pupils. The corneal thickness was measured with an Orbscan II (Bausch & Lomb, Rochester, NY, USA). Each result of aqueous flare or corneal thickness was determined based on the mean of five measurements.

**Statistical Analysis** Statistical analysis was performed using the Statistical Package for the Social Sciences (SPSS Inc., V. 17, Chicago, IL, USA). Data were expressed as means  $\pm$  standard error (SE) of the means. The independent sample *t*-test was used to detect differences in corneal thickness, IOP, and aqueous flare between the two groups at each time point. Mann-Whitney *U*-tests were used to analyze differences in signs and symptoms scores between the two groups at different time points. Differences were defined as significant at  $P < 0.05$ .

**Adverse Event Reporting** Adverse events were collected through reports provided by the subjects or observations made by the investigative staff. No drug-related adverse events were identified.

## **RESULTS**

In total, 60 patients were enrolled in this study and were randomized into two groups of 30. All of the patients completed both the study and the follow-up period. The patients in both groups had similar lens nuclear density and mean energy used during the surgery. The effective phacoemulsification time (EPT) of the two groups were  $9.41 \pm 1.37$ s (group A) and  $9.57 \pm 1.39$ s (group B), respectively.

**Table 1 Symptom grading standard**

Symptoms	Scores				
	0	1	2	3	4
Phengophobia	No	Mild	Medium	Severe	Very severe
Tearing	No	Mild	Medium	Severe	Very severe
Forein body sensation	No	Mild	Medium	Severe	Very severe
Painful	No	Mild	Medium	Severe	Very severe
Itching	No	Mild	Medium	Severe	Very severe

**Table 2 Sign grading standard**

Signs	Scores				
	0	1	2	3	4
Conjunctival congestion	No	Mild	To the palpebral fissure	To the fornix	All of the conjunctiva
Conjunctival oedema	No	Mild	Medium	Severe	Very severe
Ciliary congestion	No	Width≤2	2<width≤3	Width>3	To the fornix
Fibrinoid pupil	No	1≤quadrant<2	2≤quadrant<3	3≤quadrant<4	Quadrant≥4
Posterior synechia	No	1≤quadrant<2	2≤quadrant<3	3≤quadrant<4	Quadrant≥4

**Table 3 Mean corneal thickness at various visits** μm

Groups	Preoperative	1d	1wk
A	539.93±45.56	631.50±102.98	585.10±77.88
B	547.83±41.85	702.07±134.02	580.63±60.94
<i>P</i>	0.716	0.080	0.629

**Table 4 IOP (mm Hg) comparison between groups over time**

Groups	Preoperative	1d	1wk
A	14.68±3.08	15.89±4.90	13.24±3.23
B	14.21±2.45	15.61±3.87	13.86±3.23
<i>P</i>	0.404	0.378	0.590

**Table 5 Aqueous flare comparison between groups over time** p/msec

Groups	Preoperative	1d	1wk
A	7.35±3.73	16.11±10.35	11.94±6.34
B	8.34±3.08	16.44±10.80	11.68±5.36
<i>P</i>	0.090	0.402	0.398

**Corneal Thickness** There were no significant differences between the two groups in corneal thickness at the three time points ( $P=0.716$  for preoperative assessments;  $P=0.080$  for postoperative day 1; and  $P=0.629$  for postoperative day 7; Table 3, Figure 1).

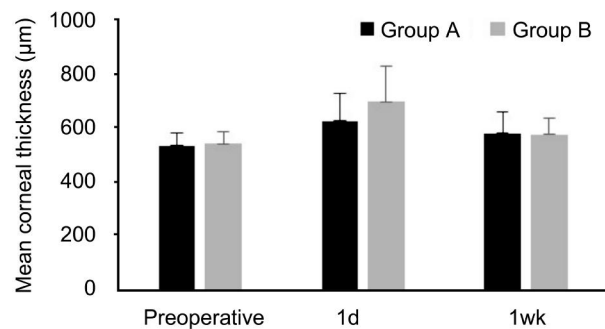
**Intraocular Pressure** The mean IOP at each time point is shown in Table 4 and Figure 2. There were no significant differences in IOP between the two groups at all time points.  $P$  values of the between-group differences before the operation, and 1, 7d post-surgery, were 0.404, 0.378, and 0.590, respectively. Two patients (6.67%) developed OHT during the first week after the operation in group B; however, none of the eyes presented with OHT in group A.

**Aqueous Flare** The aqueous flare at each time point is shown in Table 5 and Figure 3. There were no significant differences in aqueous flare between the two groups ( $P>0.05$ ).

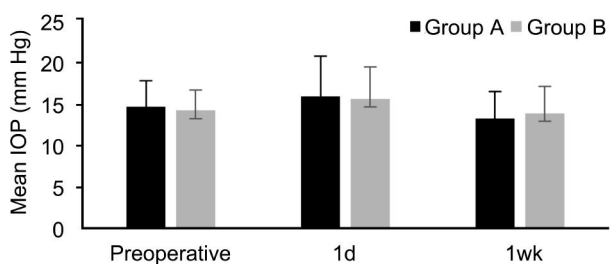
**Signs and Symptoms** The results of the signs and symptoms scores are shown in Table 6. The signs and symptoms scores were similar in the two groups at all time

**Table 6 Symptoms and signs scores at various postoperative visits**

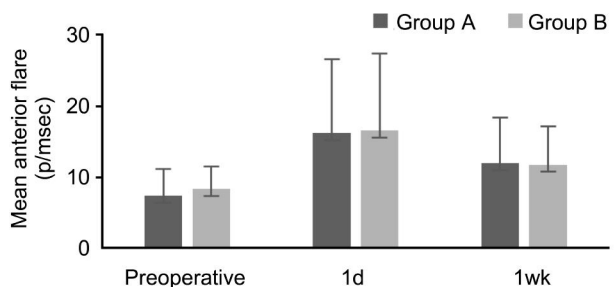
Groups	Preoperative	1d	1wk
A	-	4.11±1.35	3.03±1.34
B	-	4.44±1.80	3.08±1.36
<i>z</i>	-	-0.418	-0.35



**Figure 1 Corneal thickness at various visits (μm).**



**Figure 2 IOP comparison between groups over time.**



**Figure 3 Aqueous flare comparison between groups over time.**

points. At postoperative day 1 and 7,  $z$  values of the Mann-Whitney  $U$  test were -0.418 and -0.350, respectively.

**DISCUSSION**

It is widely accepted that surgical trauma of the ocular surface can induce an inflammatory response that may include the release of prostaglandins and the recruitment of neutrophils and macrophages. This process culminates in the production of chemical inflammatory mediators including proteolytic enzymes, oxygen-free radicals, and cyclooxygenase and lipoxygenase metabolites of arachidonic acid, leading to the observation of inflammation-related signs including corneal edema, conjunctival hyperemia, and anterior chamber flare and cells [10,12-13]. Several studies have confirmed the significant role of corticosteroids in the reduction of inflammation after cataract surgery through the inhibition of the cyclooxygenase pathway and the lipoxygenase pathway of the arachidonic acid cascade [14-15]. Wound infections and endophthalmitis are also potentially vision-threatening complications of cataract surgery. Endophthalmitis is a severe inflammation of the anterior and/or posterior chambers of the eye and may be associated with infections [1,16].

The therapy for the prevention of postoperative inflammation and infection after phacoemulsification includes standard treatments with corticosteroids and antibiotics, which have been reported in a previous study [17]. It has been reported that the administration of tobramycin/dexamethasone four times per day for 21 postoperative days prevented post-surgical inflammation following cataract extraction [18]. Tobramycin/dexamethasone eye drops have been used in ophthalmology since 1983, and it is a well-accepted ophthalmic solution used extensively in the prevention of infection and post-surgical inflammation [8].

In the present study, fluorometholone 0.1% and tobramycin/dexamethasone eye drops had similar effects on aqueous flare, corneal thickness, and signs and symptoms scores. Our findings indicate that fluorometholone 0.1% combined with levofloxacin 0.5% also offered protection against postoperative inflammation and infection.

Although a single administration of a combination drug might lead to better compliance and patient comfort, dexamethasone is associated with side effects, such as increased IOP and the potential for steroid-induced glaucoma [19-20]. Fluorometholone has been shown to have a substantially lower tendency to raise IOP than dexamethasone in previous studies. Our study also identified two patients with OHT in the tobramycin/dexamethasone treatment group, but not in the fluorometholone group; thus, providing further support for the relative advantage of fluorometholone with regard to IOP. However, we cannot prove the IOP increase was due to dexamethasone due to the short study period. These two patients had high myopia, a condition that is thought to be steroid-sensitive. Therefore, even without enough evidence, we think dexamethasone

should be the first cause to consider. The mechanism concerning topical corticosteroids producing increases in IOP is not fully understood. Since the glucocorticoid receptor is involved in multiple and diverse signaling pathways, it is thought that steroid-induced IOP elevations may be due to the sensitive corticosteroid receptors in "steroid responders". The reason for the different IOP elevations between dexamethasone and fluorometholone is unclear. A previous study has speculated that the chemical structure of fluorometholone might be responsible for this effect [8].

Among ophthalmic antibiotics, the most prescribed are aminoglycosides and fluoroquinolones, as they provide excellent coverage against most Gram-positive and Gram-negative organisms [21]. Levofloxacin, a third-generation fluoroquinolone, has a low rate of bacterial resistance compared with other commonly used antibiotics, and its antibacterial activity is two-fold greater than that of ofloxacin [22]. The effect of ophthalmic antibiotics depends largely on the antibiotic permeability of the eyes. Stuart Elborn *et al* [23] found that ofloxacin has better aqueous penetration in human eyes compared with tobramycin; thus, this report suggests that ofloxacin could be the better choice for the prevention and treatment of endophthalmitis. There were no infections observed in either group in our study, and the results support the idea that levofloxacin is a better antibiotic in cataract surgery.

Transient corneal edema with faint folds of Descemet's membrane is a relatively common finding following phacoemulsification cataract surgery. The etiology of early postoperative corneal edema is probably the result of inflammation or endothelial injury during cataract surgery, which may include ultrasound damage, direct mechanical trauma, or toxicity from irrigation solutions. Several studies have reported the inhibition of glucocorticoids, including dexamethasone in corneal edema [24-25]. There were no significant differences in corneal thickness between the two groups in our study. This indicates that both fluorometholone 0.1% and dexamethasone 0.1% effectively inhibit corneal edema. Interestingly, although statistical significance could not be reached, the mean central corneal thickness of group B on day 1 was higher than that of group A. Whether fluorometholone is better at reducing corneal edema than dexamethasone at the very early postoperative stages needs further study.

In the present study, we found that a combined medication, fluorometholone 0.1% combined with levofloxacin 0.5% , had a comparable efficacy, but possibly a lower tendency to increase IOP, when compared to tobramycin/dexamethasone. However, this study has some limitations. First, due to the small sample size, the statistical power was limited. Second, due to the short follow-up time, we cannot compare the effect on IOP modifications of the two steroids under

long-term administration. Additional studies with fluorometholone 0.1% combined with levofloxacin 0.5% , including long-term follow-up periods and more patient participation, will provide greater insight into designing effective pharmacological treatments for inflammation and infection prevention following cataract surgery.

#### ACKNOWLEDGEMENTS

**Conflicts of Interest:** Chen PQ, None; Han XM, None; Zhu YN, None; Xu J, None.

#### REFERENCES

- 1 Cho H, Wolf KJ, Wolf EJ. Management of ocular inflammation and pain following cataract surgery: focus on bromfenac ophthalmic solution. *Clinical Ophthalmology* 2009;3:199-210.
- 2 Wang QW, Yao K, Xu W, Chen PQ, Shentu XC, Xie X, Weng Y, Zhang L, Jin CF, Wu W, Zhu YN, Yu YH. Bromfenac sodium 0.1% , fluorometholone 0.1% and dexamethasone 0.1% for control of ocular inflammation and prevention of cystoid macular edema after phacoemulsification. *Ophthalmologica* 2013;229(4):187-194.
- 3 Jaycock P, Johnston RL, Taylor H, Adams M, Tole DM, Galloway P, Canning C, Sparrow JM; UK EPR User Group. The Cataract National Dataset electronic multi-centre audit of 55,567 operations: updating benchmark standards of care in the United Kingdom and internationally. *Eye (Lond)* 2009;23(1):38-49.
- 4 El-Harazi SM, Feldman RM. Control of intra-ocular inflammation associated with cataract surgery. *Curr Opin Ophthalmol* 2001;12(1):4-8.
- 5 Yang C, Chen A, Wang Y, Fang X, Ye R, Lin J. Prevention and control of perioperative incision infection in patients undergoing day cataract surgery. *Eye Sci* 2014;29(3):182-185.
- 6 Pianini V, Passani A, Rossi GC, Passani F. Efficacy and safety of netilmycin/dexamethasone preservative-free and tobramycin/dexamethasone-preserved fixed combination in patients after cataract surgery. *J Ocul Pharmacol Ther* 2010;26(6):617-621.
- 7 Fan BJ, Wang DY, Tham CC, Lam DS, Pang CP. Gene expression profiles of human trabecular meshwork cells induced by triamcinolone and dexamethasone. *Invest Ophthalmol Vis Sci* 2008;49(5):1886-1897.
- 8 Akingbehin AO. Comparative study of the intraocular pressure effects of fluorometholone 0.1% versus dexamethasone 0.1%. *Br J Ophthalmol* 1983; 67(10):661-663.
- 9 Guzey M, Karadede S, Dogan Z, Satici A. Ketorolac-tobramycin combination vs fluorometholone-tobramycin combination in reducing inflammation following phacoemulsification cataract extraction with scleral tunnel incision. *Ophthalmic Surg Lasers* 2000;31(6): 451-456.
- 10 van Endt JJ, Veraart HG, Kramer R, Janssen AG, Sunder Raj P. A comparison of two ophthalmic steroid-antibiotic combinations after cataract surgery. *Eur J Ophthalmol* 1997;7(2):144-148.
- 11 Trinavarat A, Atchaneeyasakul LO, Surachatkumtonekul T, Kosrirukvongs P. Comparison of topical prednisolone acetate, ketorolac tromethamine and fluorometholone acetate in reducing inflammation after phacoemulsification. *J Med Assoc Thai* 2003;86(2):143-150.
- 12 Chatziralli IP, Papazisis L, Sergentanis TN. Ketorolac plus tobramycin/dexamethasone versus tobramycin/dexamethasone after uneventful phacoemulsification surgery: a randomized controlled trial. *Ophthalmologica* 2011;225(2):89-94.
- 13 Sahu S, Ram J, Bansal R, Pandav SS, Gupta A. Effect of topical ketorolac 0.4% , nepafenac 0.1% , and bromfenac 0.09% on postoperative inflammation using laser flare photometry in patients having phacoemulsification. *J Cataract Refract Surg* 2015;41(10):2043-2048.
- 14 Becker B, Ramsey CK. Plasma cortisol and the intraocular pressure response to topical corticosteroids. *Am J Ophthalmol* 1970;69(6):999-1003.
- 15 McGhee CN, Watson DG, Midgley JM, Noble MJ, Dutton GN, Fern AI. Penetration of synthetic corticosteroids into human aqueous humour. *Eye (Lond)* 1990;4(Pt 3):526-530.
- 16 Comesasca FI, Bianchi C, Beltrame G, Caporossi A, Piovella M, Rapisarda A, Tassinari G, Zeppa L; Italian Betamethasone-Chloramphenicol vs Dexamethasone-Tobramycin Combination Study Group. Control of inflammation and prophylaxis of endophthalmitis after cataract surgery: a multicenter study. *Eur J Ophthalmol* 2007;17 (5): 733-742.
- 17 Saari KM, Nelimarkka L, Ahola V, Loftsson T, Stefansson E. Comparison of topical 0.7% dexamethasone-cyclodextrin with 0.1% dexamethasone sodium phosphate for postcataract inflammation. *Graefes Arch Clin Exp Ophthalmol* 2006;244(5):620-626.
- 18 Notivol R, Amin D, Whiting A, Wells D, Kennedy M, Cockrum PC; International TobraDex Study Group. Prophylactic effectiveness of tobramycin-dexamethasone eye drops compared with tobramycin/vehicle eye drops in controlling post-surgical inflammation in cataract patients : prospective, randomised, double-masked, two-arm, parallel-group, placebo-controlled, multicentre study. *Clin Drug Investig* 2004;24 (9): 523-533.
- 19 Whitlock NA, McKnight B, Corcoran KN, Rodriguez LA, Rice DS. Increased intraocular pressure in mice treated with dexamethasone. *Invest Ophthalmol Vis Sci* 2010;51(12):6496-6503.
- 20 Qin Y, Lam S, Yam GH, Choy KW, Liu DT, Chiu TY, Li WY, Lam DS, Pang CP, Fan DS. A rabbit model of age-dependant ocular hypertensive response to topical corticosteroids. *Acta Ophthalmol* 2012;90(6):559-563.
- 21 Ozbek B, Otuk G. Post-antibiotic effect of levofloxacin and tobramycin alone or in combination with cefepime against pseudomonas aeruginosa. *Chemotherapy* 2009;55(6):446-450.
- 22 Ernst ME, Ernst EJ, Klepser ME. Levofloxacin and trovafloxacin: the next generation of fluoroquinolones? *Am J Health Syst Pharm* 1997;54(22): 2569-2584.
- 23 Stuart Elborn J, Geller DE, Conrad D, Aaron SD, Smyth AR, Fischer R, Kerem E, Bell SC, Loutit JS, Dudley MN, Morgan EE, VanDevanter DR, Flume PA. A phase 3, open-label, randomized trial to evaluate the safety and efficacy of levofloxacin inhalation solution (APT-1026) versus tobramycin inhalation solution in stable cystic fibrosis patients. *J Cyst Fibros* 2015;14(4):507-514.
- 24 Hatou S, Yamada M, Mochizuki H, Shiraishi A, Joko T, Nishida T. The effects of dexamethasone on the Na,K-ATPase activity and pump function of corneal endothelial cells. *Curr Eye Res* 2009;34(5):347-354.
- 25 Hos D, Saban DR, Bock F, Regenfuss B, Onderka J, Masli S, Cursiefen C. Suppression of inflammatory corneal lymphangiogenesis by application of topical corticosteroids. *Arch Ophthalmol* 2011;129(4):445-452.