

Visual function alterations in cavernous hemangioma of the orbital apex after surgery

Kang Xue, Min Wang, Jiang Qian

Department of Ophthalmology, Eye, Ear, Nose and Throat Hospital of Fudan University, Shanghai 200031, China

Correspondence to: Jiang Qian. Department of Ophthalmology, Eye, Ear, Nose and Throat Hospital of Fudan University, Shanghai Key Laboratory of Visual Impairment and Restoration, 83 Fenyang Road, Shanghai 200031, China. qianjiang58@hotmail.com

Received: 2016-03-18 Accepted: 2016-04-25

DOI:10.18240/ijo.2016.10.27

Xue K, Wang M, Qian J. Visual function alterations in cavernous hemangioma of the orbital apex after surgery. *Int J Ophthalmol* 2016;9(10):1528–1531

Dear Editor,

I am Dr. Kang Xue, from the Department of Ophthalmology at the Eye, Ear, Nose and Throat Hospital of Fudan University in Shanghai, China. I am writing to present three case reports of the removal of visual function alterations in cavernous hemangioma of the orbital apex after surgery.

Cavernous hemangioma is a relatively common primary benign orbital tumor in adults^[1]. Although histopathologically benign, a cavernous hemangioma may often cause proptosis and interfere with optic nerve function, necessitating surgical intervention^[2]. Patients should be followed with serial imaging and visual field testing to carefully evaluate whether surgery is needed^[3]. In a previous work, we introduced a new technique called multifocal visual evoked potential (mfVEP), which allows for the objective topographical assessment of the visual field in unilateral compressive optic neuropathy secondary to orbital tumors^[4]. The aim of our study was to investigate visual function alterations in cavernous hemangioma of the orbital apex after surgery. We have also tried to discover whether mfVEP technology is effective in evaluating cavernous hemangioma of the orbital apex and in evaluating progress in the recovery of visual function. We are also interested in approaches to tumor removal.

The records of three patients with a diagnosis of cavernous hemangioma of the orbital apex seen at the Eye, Ear, Nose and Throat Hospital of Fudan University between January, 2013 and December, 2013 were reviewed retrospectively. The Humphrey Visual Field Program 30-2 (Humphrey

Systems, Dublin, California, USA) was used to perform static automated perimetry. The mfVEP technology has been described in detail elsewhere^[4]. Briefly, two minute recordings from each eye were averaged for analysis. Three channels were derived mathematically using customized software as described by Hood *et al*^[5]. The analyses were done with programs written in MATLAB using the mfVEP processing program.

Three eyes of three patients with unilateral cavernous hemangioma of the orbital apex were studied. Each of the patients underwent surgery, and for each patient case we obtained a pathological diagnosis that confirmed the presence of cavernous hemangioma. The investigations of visual function were repeated postoperatively at one month and six months follow-up visits (Tables 1, 2).

Case 1: A 49-year-old woman complained of a slow decrease in vision in the right eye for two years. The B scan of the orbit failed to detect the mass due to its small volume and its deep position in the orbital apex. CT imaging demonstrated a well-circumscribed intraconal tumor abutting the superior and lateral aspect of the apical optic nerve (Figure 1). The static automated visual field showed a diffuse decrease in central sensitivity. Figure 2 shows the reduction of amplitudes and prolongation of latency of the mfVEP response, especially in the central and inferior region. The tumors were completely removed through a sub-brow superior fornix incision and a subperiosteal dissection approach. At one month, the visual field showed dramatic recovery, but reduction of amplitudes and prolongation of latency of the mfVEP response was still be significantly observed interocularly in the central region. Central vision improved to 20/25+2, and the RAPD resolved. At six months, both the visual field and the reduction in the amplitude of the mfVEP response showed a complete recovery. Central vision improved to 20/20. However, the prolongation of latency of the mfVEP response was still significant in the central region.

Case 2: In a 54-year-old female patient, a tumor was discovered by chance during an examination of another part of the head. The static automated visual field was almost normal. The CT scan indicated an inferomedial intraconal tumor deep in the orbital apex compressing the optical nerve laterally and superiorly (Figure 3). Figure 4 shows the reduction of amplitudes and prolongation of latencies of the

Table 1 The relevant clinical information, visual acuity and other details of the patients

Case No.	Age (a)/sex	Affected eye	VA			Fundus changes
			Preoperative	1mo follow-up	6mo follow-up	
1	49/F	OD	20/40	20/25+2	20/20	Normal
2	54/F	OS	20/20-2	20/20	20/20+2	Normal
3	39/F	OD	20/100	20/20-2	20/20	Disc pallor

Table 2 Average delay of responses for interocular analyses preoperatively, at 1, 6mo follow-up

Case No.	Average interocular latency (ms)		
	Preoperative	1mo follow-up	6mo follow-up
1	14.58	7.50	5.00
2	9.17	6.67	5.25
3	5.80	3.33	3.15

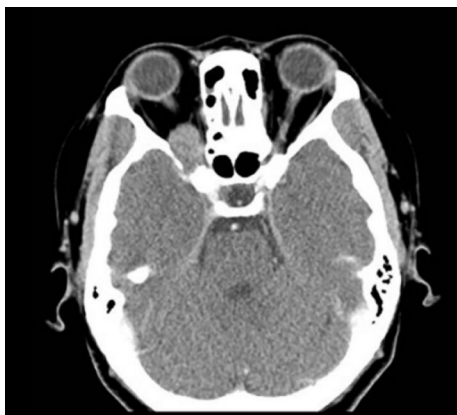

Figure 1 CT image demonstrating a well-circumscribed intraconal tumor about 19 × 15 –mm² in size abutting the superior and lateral aspect of the apical optic nerve. The lesion extends through an expanded sphenoidal fissure to the middle cranial fossa.

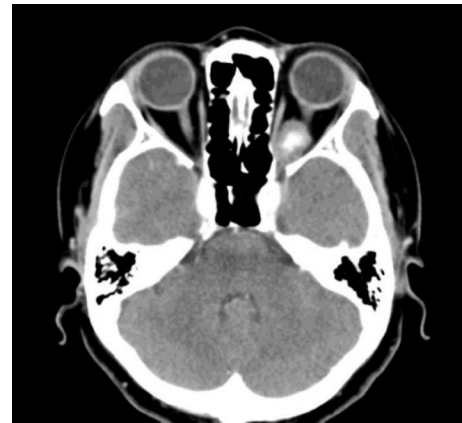

Figure 3 The CT scan indicated an inferomedial intraconal tumor about 14 × 17 –mm² in size located deep in the orbital apex compressing the optic nerve laterally and superiorly.

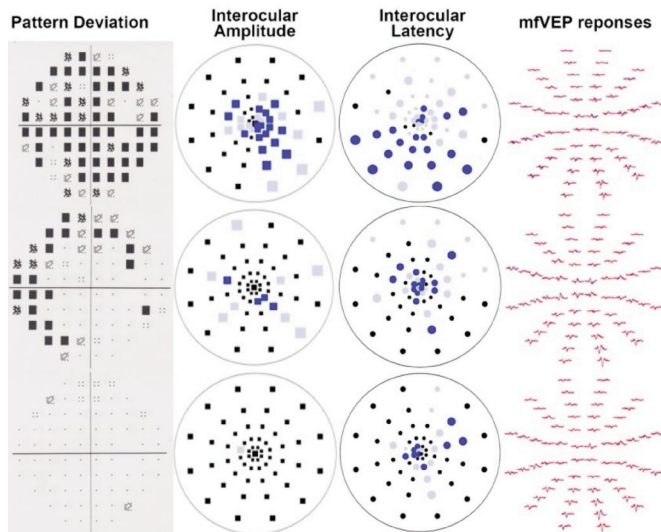


Figure 2 mfVEP data of case 1. The colored squares (right eye: blue; left eye: red) indicate that there were significant differences between the affected eye and normal eyes either at the $P < 0.05$ (desaturated color) or the $P < 0.01$ (saturated color) level. The region showing reduced amplitude and prolongation of latency of the mfVEP response preoperatively (top line). One month and six months after surgical excision (middle line and bottom line).

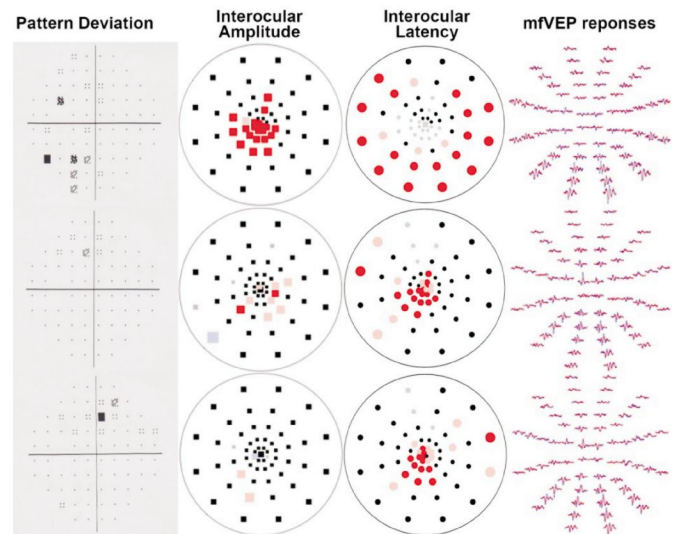


Figure 4 mfVEP data and responses for case 2 at pre-operation and at 1, 6mo post-operation (top line, middle line, and bottom line, respectively).

mfVEP response in the central region. The lesion was approached with a lower fornix incision and subperiosteal dissection. At one month, the visual field was normal, and mfVEP showed a recovery to some degree, but significant reduction of amplitudes and prolongation of the latency of the mfVEP response were still observed in the central region. The RAPD resolved, and motility remained normal. At six months, both the visual field and the reduction in the amplitude of mfVEP showed a complete recovery. However, the prolongation of the latency of the mfVEP response was still significant in the central region.

Case 3: A 39-year-old woman complained of visual impairment in her right eye. The fundus showed disc pallor. Because the B scan of the orbit failed to detect the mass due to its small volume and its deep position in the orbital apex, the patient was first diagnosed with optic atrophy. A neurosurgeon at another hospital failed to extirpate the tumor through a transcranial approach. When the patient presented to our hospital, CT imaging demonstrated changes as a result of transcranial surgery and an inferior intraconal tumor deep in the orbital apex (Figure 5). The static automated visual field showed advanced vision defects. Figure 6 shows the reduction of amplitudes and prolongation of latency of the mfVEP response in the whole region. The lesion was approached with a transconjunctival anterior orbitotomy. At one month and at six months, central vision dramatically improved to 20/20 despite the persistence of disc pallor. Advanced vision defects were still observed, but the foveal sensitivity was resolved. The mfVEP response implied advanced reduction of amplitudes and prolongation of latency even in the foveal region.

The management of small hemangiomas lodged deep in the orbital apex has remained a challenge; these lesions may cause progressive functional defects, and even minor incremental growth can have a major impact in this densely packed region [3,6]. Patients can be followed with serial imaging and visual field testing. The latter may be the more sensitive indicator because slight enlargement in the crowded apex is not easily appreciated in serial CT or magnetic resonance studies [3]. However, imaging studies will remain the gold standard in diagnosing and managing such patients.

In our research, we used the objective method of mfVEP to assist in the early diagnosis and follow-up monitoring of compressive optic neuropathy secondary to cavernous hemangioma of the orbital apex. In cases 1 and 3, the changes in measures of mfVEP proved the visual field changes. Thus, when the visual field results are unreliable, mfVEP technology may be helpful. In case 2, the visual field was within normal limits, but the changes in the mfVEP response were significant when the affected eye was compared with the patient's healthy eye. In other words, mfVEP may be able to identify subtle defects that are undetectable through examination of the visual field. These findings are particularly important to the evaluation of cavernous hemangioma of the orbital apex. For the patients whose mfVEP response are normal, the risks of surgery may outweigh any theoretical benefit; for the patients whose mfVEP response shows a reduction of amplitudes and prolongation of latency, surgery may be considered to avoid further damage to visual function.

All tumors were completely removed. In all cases, postoperative visual acuity was improved at one month and was quite close to the VA at six months. However, at one

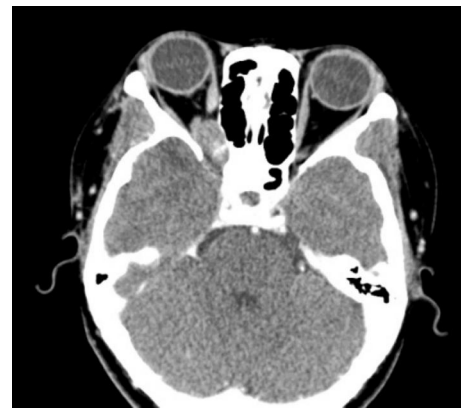

Figure 5 CT imaging demonstrated an inferior intraconal tumor deep in the orbital apex about 11×15–mm² in size, and changes as a result of transcranial surgery were also observed.

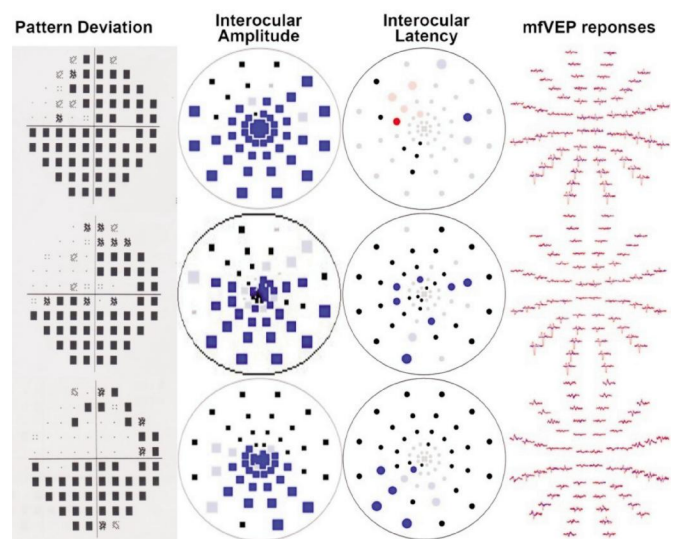


Figure 6 mfVEP data and responses for case 3 at pre-operation and at 1, 6mo post-operation (top line, middle line, and bottom line, respectively).

month, the mfVEP response still showed a significant reduction of amplitudes and prolongation of latencies. In cases 1 and 2, we observed at six months that after amplitude recordings and visual fields had normalized, increased latency persisted in the central regions. Hood *et al* [5-6] concluded that mfVEP can be used to monitor localized optic nerve damage after unilateral optic neuritis. They noted that even after amplitude recordings had normalized, increased latency persisted in many regions. The latency data allowed us to identify defects in eyes with amplitude or asymmetry abnormalities. Our finding with cavernous hemangioma of the orbital apex showed persisting increased latency which was similar to theirs.

The transcranial route is typically used to remove tumors located in the deep medial orbital compartment. We also report on three patients with apical orbital cavernous hemangioma using various orbitotomy approaches, including the sub-brow superior fornix approach and the lower fornix and transconjunctival anterior orbitotomy. Rather than using

a craniotomy approach, an orbitotomy approach was chosen according to the position of the tumor. All of the patients functionally improved, and this improvement was confirmed by visual field and mfVEP testing.

In addition, we note that for cavernous hemangioma of the orbital apex, a B scan may be inappropriate due to the small volume of the tumor and its deep position in the orbital apex. B scan failed to detect the lesion in two out of the three patients in our study. Routine CT scanning or MRI may better reveal an orbital lesion in the orbital apex. For patients with optic atrophy, a CT scan or MRI must be done to exclude the presence of a lesion in the orbital apex.

In our opinion, our results demonstrate that mfVEP could be considered for use as an objective early diagnosis and follow-up tool for compressive optic neuropathy of cavernous hemangioma in the orbital apex. Orbitotomy approaches may provide an alternative to the surgical approach.

ACKNOWLEDGEMENTS

Foundations: Supported by the National Health and Family

Planning Commission of Shanghai (No.20144Y0264); the Science and Technology Commission of the Shanghai Municipality (No.14411961800).

Conflicts of Interest: Xue K, None; Wang M, None; Qian J, None.

REFERENCES

- 1 Shields JA, Shields CL, Eagle RC. Cavernous hemangioma of the orbit. *Arch Ophthalmol* 1987;105(6):853.
- 2 Scheuerle AF, Steiner HH, Kolling G, Kunze S, Aschoff A. Treatment and long-term outcome of patients with orbital cavernomas. *Am J Ophthalmol* 2004;138(2):237-244.
- 3 Harris GJ. Cavernous hemangioma of the orbital apex: pathogenetic considerations in surgical management. *Am J Ophthalmol* 2010;150(6):764-773.
- 4 Xue K, Wang M, Qian J, Yuan Y, Zhang R. Multifocal visual evoked potentials in unilateral compressive optic neuropathy secondary to orbital tumors. *Eur J Ophthalmol* 2013;23(4):571-577.
- 5 Hood DC, Odel JG, Winn BJ. The multifocal visual evoked potential. *J Neuroophthalmol* 2003;23(4):279-289.
- 6 Hood DC, Odel JG, Zhang X. Tracking the recovery of local optic nerve function after optic neuritis: a multifocal VEP study. *Invest Ophthalmol Vis Sci* 2000;41(12):4032-4038.