

# Macular hole closure following anti-vascular endothelial growth factor injection in an eye with myopic choroidal neovascularization

Cheolmin Yun, Seong-Woo Kim, Kuhl Huh, Jaeryung Oh

Department of Ophthalmology, Korea University College of Medicine, Seoul 02841, Korea

**Correspondence to:** Jaeryung Oh. Department of Ophthalmology, Korea University College of Medicine, 126-1 Anam-dong 5-ga, Sungbuk-gu, Seoul 02841, Korea. ojr4991@yahoo.co.kr

Received: 2015-02-23 Accepted: 2015-07-02

**DOI: 10.18240/ijo.2016.09.24**

Yun C, Kim SW, Huh K, Oh J. Macular hole closure following anti-vascular endothelial growth factor injection in an eye with myopic choroidal neovascularization. *Int J Ophthalmol* 2016;9(9):1364–1366

## Dear Editor,

I am Cheolmin Yun, from the Department of Ophthalmology, Korea University College of Medicine. I write to present a case report of a female patient with a myopic patient suffering from atrophic choroidal neovascularization (CNV) and a full thickness macular hole (FTMH), who was treated with an intravitreal anti-vascular endothelial growth factor (VEGF) injection without vitrectomy.

A FTMH in an eye with high myopia has been suggested to have a poorer anatomical and visual prognosis than in an eye without high myopia<sup>[1]</sup>. FTMHs were reported in 6.26% of highly myopic eyes, but cases with a CNV and a FTMH in the same eye were not common<sup>[2]</sup>. Shimada *et al*<sup>[3]</sup> presented cases with a FTMH associated with chorioretinal atrophy adjacent to myopic CNV. They suggested that eyes at the atrophic stage of myopic CNV have a higher risk of developing a FTMH, and recommended periodic optical coherence tomography (OCT) examinations for a FTMH. However, the best therapy for these patients has not been determined.

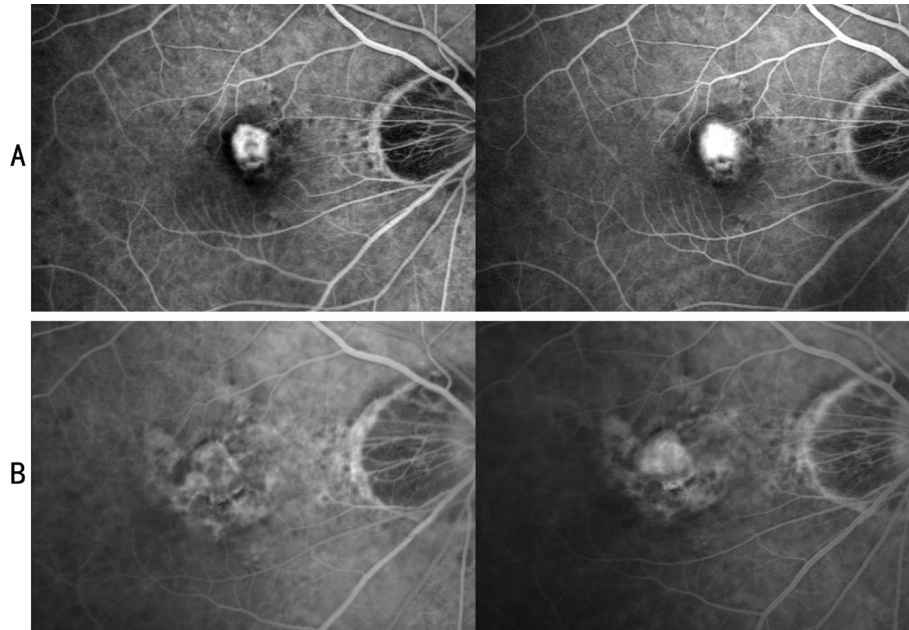
A 68-year-old female presented with a ten-day history of decreased visual acuity OD. Her vision was 1.52 logMAR OD. The anterior segment was normal. The axial length of right eye was 28.71 mm. Fundoscopic examination of the right eye showed a subretinal hemorrhage. Fluorescein angiography (FA) indicated a type 2 CNV located close to the fovea with leakage (Figure 1). The patient underwent

spectral-domain optical coherence tomography (SD-OCT, 3D OCT-1000 Mark II, Topcon Corp., Tokyo, Japan) examination using three-dimensional scanning protocols with 128 B-scans (512 A-scans per B-scan with a length of 6 mm). The SD-OCT revealed vitreomacular adhesion (Figure 2), and the patient was diagnosed with myopic CNV.

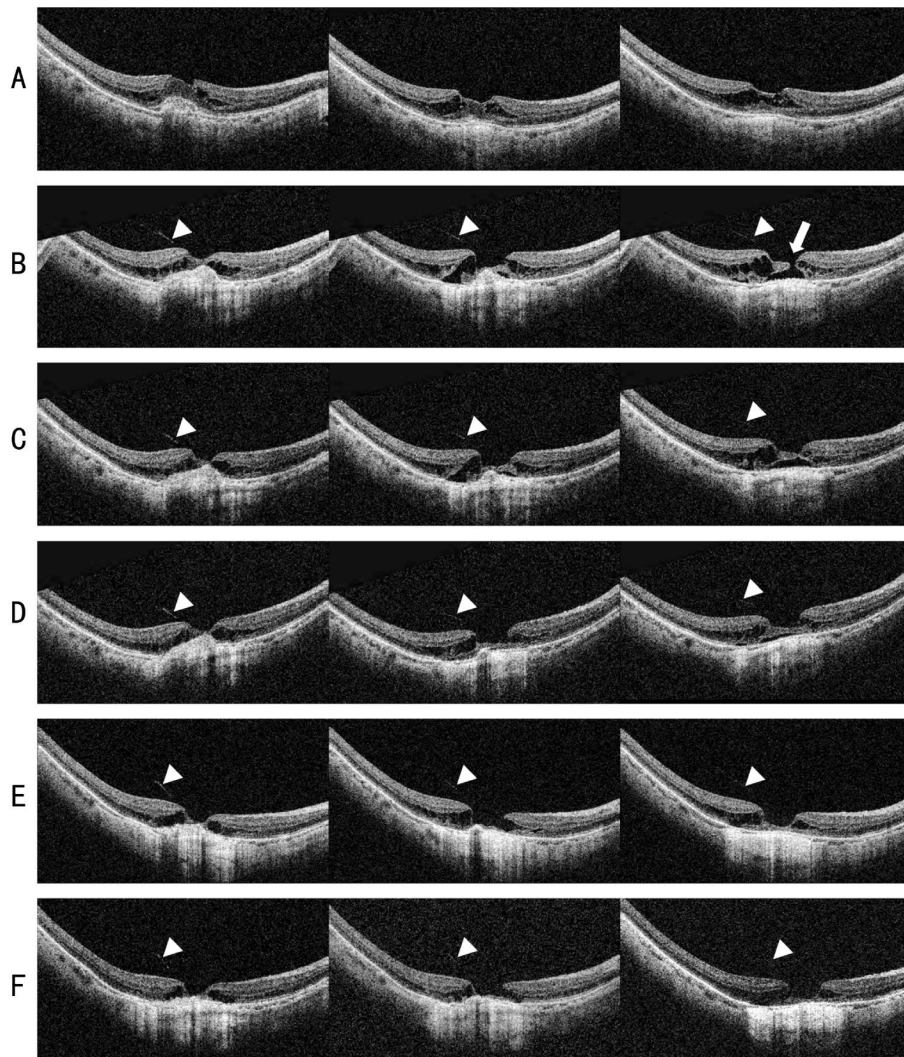
Photodynamic therapy (PDT) was performed with verteporfin (Visudyne; Novartis AG, Bülach, Switzerland). On the SD-OCT scan obtained ten months after the treatment for CNV, retinoschisis and macular detachment were noted adjacent to the previous CNV lesion. She had no visual symptoms and her vision was 1.52 logMAR. Seventeen months after PDT, the patient presented with visual dimness. Her vision was decreased to 2.00 logMAR. SD-OCT demonstrated a FTMH at the location of the previous macular detachment. However, FA did not show apparent leakage from the CNV.

Pars plana vitrectomy was recommended. However, the patient refused the surgery. Three weeks after initial diagnosis of the FTMH, a SD-OCT scan revealed that the FTMH had not resolved. After obtaining informed consent, she underwent intravitreal injection of bevacizumab (Avastin; Genentech, South San Francisco, CA, USA). Five days after the intravitreal injection of bevacizumab, closing of the FTMH was observed on SD-OCT examination. SD-OCT images obtained six weeks after the intravitreal injection showed that the macular edema and subretinal fluid were further decreased. Vitreomacular adhesion, which had been observed on SD-OCT before the anti-VEGF injection, was unchanged after closure of the FTMH. FA did not show any change in the CNV. SD-OCT images obtained three months after the intravitreal injection showed that the macular edema and subretinal fluid were further decreased. The patient's vision recovered to 1.70 logMAR. The macular hole remained closed until twenty months after the intravitreal injection.

In our case, the FTMH eventually developed adjacent to the atrophic CNV that had been treated with PDT. Shrinkage and regression of CNV at the atrophic stage were suggested to induce a FTMH by centrifugal and tangential stretching of the extremely thin atrophic retina at the edge of the CNV<sup>[3]</sup>. The traction force must be one of the reasons for the



**Figure 1 Fluorescein angiography in a 68-year-old female with high myopia** A: Myopic CNV with leakage was located in the juxtafoveal area; B: Seventeen month after photodynamic therapy, CNV membrane was noted on fluorescein angiography with a window defect from new onset full thickness macular hole.



**Figure 2 SD-OCT** A: CNV in the juxtafoveal area was treated with PDT; B: Seventeen months after PDT, SD-OCT revealed a FTMH (arrow); C: Five days after an intravitreal injection of anti-vascular endothelial growth factor, bridging formation on the FTMH was observed; Three (D), six (E) and twenty months (F) after the injection, SD-OCT showed decreased subretinal fluid and a closed macular hole. Partial posterior vitreous detachment (arrowhead) was not changed.

development of the FTMH in our case. We observed vitreomacular adhesion on SD-OCT, and this could have contributed to the development of the FTMH in our patient because the size of FTMH was very small and macular detachment and retinoschisis existed at the time of intravitreal injection<sup>[4]</sup>. However, it is not sufficient to explain how the FTMH closed just after the intravitreal injection of anti-VEGF without vitrectomy. Changes of vitreomacular adhesion were not detected on the volume scans of SD-OCT for twenty months after the intravitreal injection. This finding cannot suggest that the mechanism underlying the closure of the FTMH *via* intravitreal injection of anti-VEGF was associated with the resolution of the vitreomacular adhesion in our case. However, because vitreomacular adhesions not detected on SD-OCT might be present, long term follow-up would be needed to elucidate the role of vitreomacular traction.

Macular edema has been suggested to one of the factors inducing a FTMH<sup>[5]</sup>. The presence of exudates or fluid due to edema may result in microcystoid degeneration, which can progress to macular retinoschisis (cyst) and even partial or complete macular hole formation<sup>[6]</sup>. Recurrence of the CNV might have induced the formation of her FTMH. However, FA obtained just before and after the anti-VEGF injection was not sufficient to support this assumption. The leakage from the CNV was not apparent before the injection. We were not able to detect a definite change in leakage after the injection. However, apart from the CNV in an eye with age-related macular degeneration, myopic CNV could have minimal leakage even when it is active<sup>[7]</sup>. Resolution of low-grade inflammation in myopic CNV might be achieved after intravitreal anti-VEGF injection.

Spontaneous closure of a FTMH is an uncommon, but well-documented phenomenon<sup>[8]</sup>. In our case, the closure of the FTMH may be assumed to have been spontaneous. The possible mechanism underlying the spontaneous closure of a macular hole may include relief of vitreoretinal traction or glial proliferation from the retinal or epiretinal tissue. However, in our case we were not able to detect any relief of vitreoretinal traction even with SD-OCT. The closure of the FTMH was observed five days after the intravitreal injection of anti-VEGF, even though the FTMH was not closed during the observation period three weeks before the injection.

Vitrectomy has been accepted as the first treatment option in myopic macular hole. In our case, we recommended vitrectomy for the treatment of myopic macular hole. However, we were not able to perform the surgery due to the patient's refusal. The possibility of a small visual gain due to previous myopic degeneration and the CNV lesion prompted the patient to refuse the more invasive pars plana vitrectomy and prone positioning treatment. Fortunately, the MH eventually closed after only an anti-VEGF injection without vitrectomy. However, further studies are required to elucidate the best treatment option for FTMH associated with previous myopic CNV. In conclusion, we encountered a myopic FTMH that was successfully closed after intravitreal anti-VEGF injection without vitrectomy in an eye with myopic CNV.

### ACKNOWLEDGEMENTS

**Conflicts of Interest:** Yun C, None; Kim SW, None; Huh K, None; Oh J, None.

### REFERENCES

- 1 Qu J, Zhao M, Jiang Y, Li X. Vitrectomy outcomes in eyes with high myopic macular hole without retinal detachment. *Retina* 2012;32 (2): 275–280.
- 2 Coppé AM, Ripandelli G, Parisi V, Varano M, Stirpe M. Prevalence of asymptomatic macular holes in highly myopic eyes. *Ophthalmology* 2005; 112(12):2103–2109.
- 3 Shimada N, Ohno-Matsui K, Yoshida T, Futagami S, Tokoro T, Mochizuki M. Development of macular hole and macular retinoschisis in eyes with myopic choroidal neovascularization. *Am J Ophthalmol* 2008;145 (1):155–161.
- 4 Koizumi H, Spaide RF, Fisher YL, Freund KB, Klancnik JM Jr, Yannuzzi LA. Three-dimensional evaluation of vitreomacular traction and epiretinal membrane using spectral-domain optical coherence tomography. *Am J Ophthalmol* 2008;145(3):509–517.
- 5 Kwon YH, Chung H, Kim JG, Yoon YH. Macular hole closure following intravitreal triamcinolone injection in a previously vitrectomized diabetic eye. *Acta Ophthalmol* 2009;87(1):111–112.
- 6 Yanoff M, Fine BS. Ocular pathology. 5th ed. Philadelphia: Mosby; 2002; 586–589.
- 7 Keane PA, Liakopoulos S, Chang KT, Heussen FM, Ongchin SC, Walsh AC, Sadda SR. Comparison of the optical coherence tomographic features of choroidal neovascular membranes in pathological myopia versus age-related macular degeneration, using quantitative subanalysis. *Br J Ophthalmol* 2008;92(8):1081–1085.
- 8 Smiddy WE, Flynn HW Jr. Pathogenesis of macular holes and therapeutic implications. *Am J Ophthalmol* 2004;137(3):525–537.