

Ultrasound comparison of diffusion of local anesthetic solution after a peribulbar and a sub-Tenon's block: a pilot study

Emile Calenda¹, Marc Muraine²

¹Department of Anesthesiology, Rouen University Hospital, Institute for Biomedical Research, Rouen 76031, France

²Department of Ophthalmology, Rouen University Hospital, Institute for Biomedical Research, Rouen 76031, France

Correspondence to: Emile Calenda. Department of Anesthesiology, Rouen University Hospital, Institute for Biomedical Research, 1 rue de Germont, Rouen 76031, France. emile.calenda@chu-rouen.fr

Received: 2014-07-22 Accepted: 2015-05-04

DOI:10.18240/ijo.2016.04.28

Calenda E, Muraine M. Ultrasound comparison of diffusion of local anesthetic solution after a peribulbar and a sub-Tenon's block: a pilot study. *Int J Ophthalmol* 2016;9(4):638-639

Dear Sir,

I am Dr. Emile Calenda, from the Department of Anesthesiology in Ophthalmology, Rouen University Hospital, Institute for Biomedical Research, Rouen, France. I write to present ultrasound visualization of local anesthetic spread after a sub-Tenon's anesthesia (3 patients) and after a peribulbar anesthesia (3 patients).

Ultrasonounds are newly introduced in regional anesthesia^[1]. But very few studies reported the use of ultrasonounds to perform a sub-Tenon's block or a peribulbar anesthesia^[2-3]. The aim of that prospective study was to show with ultrasonography the location of the local anesthetic solution with two routes of injection that is to say a sub-Tenon's block performed by the surgeon (3 patients) and a peribulbar block performed by the anesthesiologist (3 patients). The hypothesis was that these two different routes of injection are able to provide analgesia then should lead to the same space of diffusion that is to say the periscleral space.

We usually use in our institution a sub-Tenon's anesthesia to relieve postoperative pain in patient scheduled for ophthalmic procedure with general anesthesia^[4]. A 40-year-old female, weighing 55 kg, ASA I status, a 28-year-old female, weighing 45 kg, ASA I status and a 35-year-old male, weighing 85 kg, ASA I status were scheduled for a cataract surgery with general anesthesia and gave their written consent to perform the ultrasonography. The Helsinki

declaration has been respected and our local ethic comity gave approval for this report. After a surgical disinfection the surgeon performed the sub-Tenon's block with the help of the microscope. The surgeon introduced a blunt cannula in the sub-Tenon's space (temporal lateral quadrant of the globe) in order to inject 2.5 mL of lidocaine 2% without epinephrine. Ultrasonography was performed at the end of the surgery through closed eyelids in sterile conditions. The phacoemulsification and general anesthesia were performed without problems. A 75-year-old man, weighing 80 kg, ASA II status, a 85-year-old man, weighing 65 kg, ASA III and A 70-year-old female, weighing 60 kg, ASA III status, all scheduled for vitrectomy with peribulbar block were included. The local anesthetic chosen was ropivacaine 7.5 mg/mL. The 3 patients respectively received 9, 8 and 11 mL. Patients gave their oral consent to receive a peribulbar anesthesia performed by the anesthesiologist with the help of ultrasonography. No compression was applied after the peribulbar block.

We chose a Logic E from General Electric Healthcare (USA) with following settings: soft tissu thermal index (TIS)< 1 (0.8 in our machine) and mechanical index (MI)<0.2 to prevent from eye damages. The probe was a linear 12 Hertz frequency with the cross bean system.

Image passing by the major axis of the optic nerve was fixed as a reference. The same ophthalmic surgeon injected the three sub-Tenon's group of patients and the same anesthesiologist did all the three injections in the peribulbar group.

At the end of the surgery (phacoemulsification of the lens) the surgeon injected 2.5 mL of lidocaine in the sub-Tenon's space. From either side of the optic nerve surrounding the eye globe behind the equator an hypoechoic edging was visible (Figure 1). This is the witness of a perfect spread of the local anesthetic solution in both sides of the optic nerve in the periscleral area called sub-Tenon's space. The 3 patients had similar images equivalent to a T-sign.

In the peribulbar group the spread of the local anesthetic solution appeared in the peribulbar, in the retrobulbar and astonishingly enough in the sub-Tenon's space, similar in the three patients. A T sign was also observed (Figure 2).

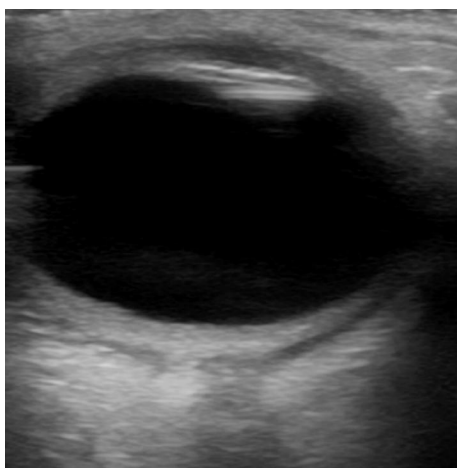


Figure 1 Diffusion of the local anesthetic solution in the sub-Tenon's space after a sub-Tenon's block.

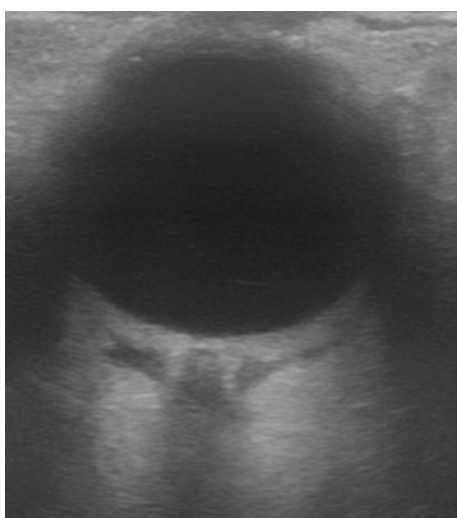


Figure 2 Diffusion of the local anesthetic solution in the peribulbar, in the retrobulbar and in the sub-Tenon's spaces after a peribulbar block.

The advent of ultrasonography will probably change the consideration of the efficacy because we will be able to follow in real time the spread of the local anesthetic solution in different spaces^[5]. Magnetic resonance imaging showed that after a combined peribulbar and retrobulbar block the volume of local anesthetic solution spread throughout the globe, and after a retrobulbar and a sub-Tenon's block, the local anesthetic solution accumulates behind the globe^[6-7]. Authors determined the distribution of anesthetic fluid during 3 regional anesthetic techniques (sub-Tenon's, peribulbar, and retrobulbar) routinely used for phacoemulsification. After a sub-Tenon's injection the fluid around the optic nerve developed a characteristic T sign. In the retrobulbar technique the fluid was localized within the cone and with a peribulbar administration the fluid was seen in the extraconal fat. They did not notice a characteristic T sign after a peribulbar or a retrobulbar^[8].

Whatever the route of injection a T sign occurred in our pilot study. That is probably due to the high volume injected or the different peribulbar technique used or a coincidence in relation to few number of patients.

The peribulbar injection reached the episcleral space and that ascertainment is probably one element of the analgesia obtained by a peribulbar injection. That pilot study with few patients is not able to affirm that the spread of the anesthetic solution in the sub-Tenon's space (T-sign) is permanently present after a peribulbar block. We can notice that the Figures 1 and 2 are strictly stackable. The local anesthetic solution has spread in contact with the sclera and in each side of the optic nerve in both figures.

Ultrasonography showed that a peribulbar block led to a diffusion in the peribulbar, in the retrobulbar and strangely in the sub-Tenon's space. A prospective study including much more patients is in progress to confirm these preliminary pilot results.

ACKNOWLEDGEMENTS

We would like to particularly thank Anne-Genevieve Borione, Shaker Heights, Ohio, USA, for spelling and grammar corrections.

Conflicts of Interest: Calenda E, None; Muraine M, None.

REFERENCES

- 1 Hamdani M, Chassot O, Fournier R. Ultrasound-guided continuous interscalene block: the influence of local anesthetic background delivery method on postoperative analgesia after shoulder surgery: a randomized trial. *Reg Anesth Pain Med* 2014;39(5):387-393.
- 2 Gayer S, Palte H, Kumar C. Real-time visualization of ultrasound-guided retrobulbar blockade: an imaging study. *Br J Anaesth* 2009;102 (4): 561-562.
- 3 Palte HD, Gayer S. Ultrasound-guided eye blocks. *Reg Anesth Pain Med* 2012;37(6):677-678.
- 4 Calenda E, Muraine M, Quintyn JC, Brasseur G. Sub-Tenon infiltration or classical analgesic drugs to relieve postoperative pain. *Clin Experiment Ophthalmol* 2004;32(2):154-158.
- 5 Luyet C, Eng KT, Kertes PJ, Avila A, Muni RH, McHardy P. Real-time evaluation of diffusion of the local anesthetic solution during peribulbar block using ultrasound imaging and clinical correlates of diffusion. *Reg Anesth Pain Med* 2012;37(4):455-459.
- 6 Niemi-Murola L, Krootila K, Kivisaari R, Kangasmaki A, Kivisaari L, Maunukela EL. Localization of local anesthetic solution by magnetic resonance imaging. *Ophthalmology* 2004;111(2):342-347.
- 7 Almeida DR, Belliveau MJ, Enright T, Islam O, El-Defrawy SR, Gale J. Anatomic distribution of gadolinium contrast medium by high-resolution magnetic resonance imaging after peribulbar and retrobulbar injections. *Arch Ophthalmol* 2012;130(6):743-748.
- 8 Winder S, Walker SB, Atta HR. Ultrasonic localization of anesthetic fluid in sub-Tenon's, peribulbar, and retrobulbar techniques. *J Cataract Refract Surg* 1999;25(1):56-59.