

Elevated urine formaldehyde in elderly patients with primary open angle glaucoma

Ying Cui^{1,2}, Tao Su³, Shao-Dan Zhang^{1,2}, Ping Huang^{1,2}, Ying-Ge He³, Ying Liu³, Chun Zhang^{1,2}, Robert Ritch⁴, Rong-Qiao He³

¹Department of Ophthalmology, Peking University Third Hospital, Beijing 100191, China

²Key Laboratory of Vision Loss and Restoration, Ministry of Education, Beijing 100191, China

³State Key Laboratory of Brain and Cognitive Science, Institute of Biophysics, Chinese Academy of Sciences, Beijing 100101, China

⁴Einhorn Clinical Research Center, New York Eye and Ear Infirmary of Mount Sinai, New York, NY 10003, USA

Co-first authors: Ying Cui and Tao Su

Correspondence to: Ying Liu. State Key Laboratory of Brain and Cognitive Science, Institute of Biophysics, Chinese Academy of Sciences, Beijing 100101, China. liuy@moon.ibp.ac.cn; Chun Zhang. Department of Ophthalmology, Peking University Third Hospital, Beijing 100191, China. zhangcl@yahoo.com

Received: 2015-05-14 Accepted: 2015-08-05

Abstract

• **AIM:** To investigate the risk factor of primary open angle glaucoma (POAG), which is the leading cause of irreversible blindness worldwide. An abnormally high level of endogenous formaldehyde (FA) has recently been found correlated with cell death and neurodegenerative disease, raising the possibility of a putative correlation of abnormal endogenous FA with POAG.

• **METHODS:** Thirty-four elderly patients with POAG and sixteen healthy controls were enrolled. Glaucomatous visual defects were present at both the functional (visual field) and structural [retinal nerve fiber layer (RNFL) thickness] levels. Morning urine samples were obtained and were analyzed by high-performance liquid chromatography (HPLC) to detect the endogenous FA level in a double blind manner.

• **RESULTS:** Patients with POAG ($P < 0.05$) had significantly higher urine FA levels. The urine FA level of patients with severe visual field defects [mean deviation (MD) ≥ 12 dB] was significantly ($P < 0.001$) greater than that of patients with mild to moderate defects (MD < 12 dB). By optical coherence tomography (OCT), the superior and inferior RNFL thickness of POAG group was significantly ($P < 0.001$) thinner than in controls. Furthermore, the

superior and inferior thinning of the RNFL was correlated with the elevation of urine FA concentration.

• **CONCLUSION:** Endogenous FA level is positively correlated with the neuronal defects of POAG.

• **KEYWORDS:** primary open angle glaucoma; urine formaldehyde; Alzheimer's disease

DOI:10.18240/ijo.2016.03.15

Cui Y, Su T, Zhang SD, Huang P, He YG, Liu Y, Zhang C, Ritch R, He RQ. Elevated urine formaldehyde in elderly patients with primary open angle glaucoma. *Int J Ophthalmol* 2016;9(3):411-416

INTRODUCTION

Glaucoma is the leading cause of irreversible blindness worldwide, particularly among the elderly [1]. It is an optic neuropathy characterized by retinal ganglion cell (RGC) death, axon loss and an excavated appearance of the optic nerve head [2]. However, a subset of patients with primary open angle glaucoma (POAG) develops damage without ever manifesting elevated intraocular pressure (IOP). Normal-tension glaucoma (NTG) is an increasingly recognized cause of POAG, and risk factors other than IOP play an important role in its pathogenesis. It is important to discover biomarkers of POAG which can be conveniently applied to clinical diagnosis and to reveal the mechanism(s) of the optic neuropathy.

Alzheimer's disease (AD) is also a neurodegenerative disorder, and is one of the leading causes of dementia worldwide. It gradually affects all aspects of cognition, including short and long-term memory, thinking and behavior. Growing evidence suggests a link between POAG and AD. There is an increased occurrence rate of POAG in AD patients [3-4]. Patients with AD exhibit axonal degeneration in the optic nerves, loss of RGCs and reduced RNFL thickness [5-6]. Increased cup-to-disc ratio and cup volume, and decreased disc rim area, were observed among AD patients, and these variables correlated significantly with Alzheimer's disease Assessment Scale and duration of disease [7]. Activation of caspases and abnormal processing of amyloid precursor protein (APP) are important events in the pathogenesis of AD and were also demonstrated in RGCs of a rat glaucoma model [8]. These data imply a common mechanism, in at least part, of POAG and AD.

Recent studies have shown that excess endogenous formaldehyde (FA) not only leads to formation of DNA-protein cross-links^[9], but also promotes hyperphosphorylation and polymerization of tau protein, accompanied by cellular dysfunction and even apoptosis^[10-14]. FA treatment induced oxidative damage of frontal cortex and hippocampal tissue in rats^[15]. Elevated FA in urine has recently been found in AD patients, while significant elevation of endogenous FA in the brain occurred simultaneously with the onset of cognitive impairment in a senile dementia animal model^[16-17]. Postoperative cognitive dysfunction is correlated with urine formaldehyde in elderly noncardiac surgical patients^[18]. The aging-associated excess FA leads to spatial memory deficits in rats^[19-20]. These findings suggest that excess endogenous FA is an indicator and a putative risk factor related to neurodegeneration.

Methanol intoxication can cause severe visual dysfunction and the key derivatives of methanol leading to ocular toxicity include FA^[21]. Cases of methanol-induced optic atrophy together with glaucoma-like cupping of the optic discs have been reported^[22-24]. Considering the high sensitivity of the optic nerve to methanol and the possible link between AD and POAG, we postulated that excess endogenous FA may also be a putative risk factor for POAG.

SUBJECTS AND METHODS

Participants The study is a case control study. It was approved by the Ethics Committee of Peking University Third Hospital and adhered to the provisions of the Declaration of Helsinki for research involving human subjects. All participants signed informed consent.

Thirty-four POAG patients and 16 age-matched normal controls were recruited from older patients who visited the Department of Ophthalmology, Peking University Third Hospital, China. All participants underwent a standardized clinical assessment, including medical history, physical and neurological examination together with mini-mental state examination (MMSE). They also received a complete ophthalmic examination including visual acuity, IOP, slit lamp examination, gonioscopy and ophthalmoscopy. Stereophotography was performed to record neuroretinal rim thinning of POAG patients. A Goldmann applanation tonometer was used to measure IOP.

The inclusion criteria for both POAG patients and controls were having signed informed consent; ≥ 60 years of age, of either gender; refractive error < 5 diopters of sphere; IOP < 21 mm Hg (the POAG patients were treated). The exclusion criteria included alcohol addiction, hepatic or renal disease, malignant tumor, surgery within 6 months, neurodegenerative disorder such as AD, Parkinson disease and multiple sclerosis. Patients with severe eye diseases other than POAG or mild age-related cataract were also excluded. Participants with hypertension and diabetes were not excluded because

previous studies have shown that hypertension and diabetes do not influence urine FA levels^[16].

POAG patients were included if they had typical glaucomatous optic neuropathy (focal or diffuse neuroretinal rim thinning, RNFL defect or an inter-eye vertical difference of cup-to-disk ratio > 0.2) and characteristic glaucomatous visual field loss. Control subjects included normal subjects and patients with mild dry eye or mild age-related cataract. Participants with best corrected visual acuity $< 20/40$, IOP > 21 mm Hg, cup-to-disk ratio > 0.5 , vertical difference of cup-to-disk ratio > 0.2 , disk hemorrhage, localized RNFL defect or abnormal visual field were excluded as controls. One eye of each control subject was randomly selected for analysis.

Visual fields were recorded by a standard automated perimeter [Humphrey Field Analyzer (HFA) II 750, Carl Zeiss Meditec, Dublin, CA, USA] using Swedish Interactive Threshold Algorithm Standard 24-2 program. Reliable visual fields were set at $< 33\%$ false negatives or false positives and $< 20\%$ fixation loss. A glaucomatous visual field defect was taken as the consistent presence of a minimum of three clustered points on the pattern deviation plot with significantly depressed sensitivity ($P < 0.05$, of which at least one had a significance of $P < 0.01$); or a glaucoma hemifield test result outside normal limits. At least two reliable consistent visual field results were required for diagnosis. For each POAG patient, data from the eye with the more severe glaucoma visual field defect was selected for analysis.

POAG patients were divided by disease severity into two groups according to visual field mean deviation (MD). MD higher than 12 dB was defined as a severe defect. MD lower than 12 dB was defined as a mild to moderate defect.

RNFL analysis was performed with a Cirrus HD-OCT system (software version 5.0.0.326, Carl Zeiss Meditec, Inc.) using the Optic Disk Cube 200 \times 200 protocol. This protocol positions the cube scan on the optic nerve head and is designed to be used for glaucoma analysis. The basic principle of the Cirrus HD-OCT and Optic Disk Cube protocol has been described previously^[25-26]. Peripapillary RNFL average thickness and RNFL thickness in four quadrants (inferior, superior, nasal and temporal) were measured. One technician performed all the image acquisitions. Only good-quality scans (signal strength > 6) were used for analysis.

Urine Samples Collection To avoid dilution, morning urine samples were taken at the hospital before the subjects had eaten breakfast or drunk any water. Participants arrived at Peking University Third Hospital after arising in the morning. They were instructed to collect midstream urine with urine cups and then to transfer it into 5 mL air-proof test tubes. The urine samples were stored at -80°C within 1 h after collection.

Formaldehyde Level Detection Urine FA levels were determined as previously described [27]. FA in the urine samples was reacted with 2,4-dinitrophenylhydrazine (DNPH) and analyzed using HPLC (LC-20A, Shimadzu, Japan). The FA-DNPH derivative was eluted from the HPLC column at a retention time of 7min. Laboratory analysis was carried out in a double-blind manner.

Data Analysis Quantitative and categorical data were compared between different groups using Student's *t*-test, rank sum test and Chi-square test for clinical characteristics. The urine FA level was compared between groups using Student's *t*-test and analysis of variance (ANOVA). Linear regression was applied for the correlation analysis. Statistical analysis was conducted with SPSS 17.0 for Windows. Data was expressed as mean ±SEM or median (minimum, maximum). Differences were considered to be significant when *P* <0.05.

RESULTS

Clinical Characteristics of Patients with Primary Open Angle Glaucoma and Controls The clinical characteristics of POAG patients and controls are listed in Table 1. No significant difference was observed between POAG patients and controls in age, gender, height, body weight, systemic hypertension or diabetes (*P* >0.05). The IOP of the POAG group shown in Table 1 represents treated IOP, which varied from 8.50 to 18.50 mm Hg (within the normal range <21 mm Hg). 53% of POAG patients had maximally recorded IOP <21 mm Hg prior to initiation of treatment. The cognitive condition of all participants was normal by their MMSE scores (>27).

Urine Formaldehyde Levels in Primary Open Angle Glaucoma Patients and Their Relationship to Visual Field Defect Severity As shown in Figure 1A, the mean urine FA concentration of the POAG group (18.77±1.10 μmol/L) was significantly greater (*P* =0.025) than in the control group (14.60±1.18 μmol/L). To further analyze the correlation of the urine FA level with visual field defect, the POAG patients were divided into mild to moderate POAG (MD<12 dB) and severe POAG (MD ≥12 dB), according to MD, a value indicating the functional defect of the neural retina. As shown in Figure 1B, the mean FA values of both the mild to moderate (16.00±1.14 μmol/L) and severe (21.89±1.66 μmol/L) POAG groups were greater than that of the control group (14.60±1.18 μmol/L), and the urine FA level of patients with severe visual field defects was significantly (*P* =0.003) greater than that of patients with mild to moderate defects. Although the difference in urine FA concentration was not significant between the mild to moderate POAG and control groups, the urine FA level of patients with severe visual field defects was significantly (*P* <0.001) elevated compared to controls.

Table 1 Clinical characteristics of POAG patients and controls

Parameters	POAG (n=34)	Control (n=16)	<i>P</i>
Age	73.26±1.21	71.94±1.61	0.527
Gender (M/F)	22/12	7/9	0.161
Height (cm)	163.65±1.14	165.06±2.38	0.598
Weight (kg)	62.31±1.46	65.19±2.12	0.269
Hypertension	18/34	10/16	0.525
Diabetes	4/34	1/16	0.920 ^a
IOP (mm Hg) ^b	14.50 (8.50, 18.50)	13.50 (8.50, 18.05)	0.544
MMSE score ^c >27	34	16	—

^aContinuity correction; ^bIOP: Intraocular pressure; ^cMMSE: Mini mental state examination, the score indicates the degree of dementia: 27-30 as normal cognition, less than 27 are considered to be dementia^[28]. Quantitative variables were shown as mean±SEM or median (minimum, maximum).

Urine Formaldehyde Levels in Primary Open Angle Glaucoma Patients Related to Retinal Nerve Fiber Layer Defects

Reduced RNFL thickness, especially in the superior and inferior parapapillary areas, is the earliest indication of POAG and a direct structural marker of the neural defect [26]. RNFL thinning in POAG due to RGC loss and detected by optical coherence tomography (OCT) is also a clinical feature corresponding to visual field defects. In this study, the mean superior and inferior RNFL thickness in severe POAG (70.94 ±4.96 μm and 59.13 ±2.64 μm, respectively) were significantly thinner than the mean thickness in mild to moderate POAG (90.83±4.34 μm and 77.61 ±4.43 μm, respectively) (*P* =0.003 and *P* =0.001, respectively), which were significantly thinner than that of the control group 105.00 ±4.19 μm and 115.44 ±3.50 μm, respectively (*P* =0.030 and *P* <0.001, respectively) (Figure 2), showing a good structure-function correlation of the retinal defects in the POAG patients, as previously described [25]. As shown in Figure 3, linear correlation was applied to analyze the relationship between the MD value and RNFL thickness. The superior and inferior RNFL thickness highly correlated with MD value (*R*²=0.384; *P* <0.001 and *R*²=0.429 *P* <0.001, respectively) (Figure 3A, 3B). Furthermore, significant negative correlations were also found between the superior or inferior RNFL thickness and FA concentration by the same statistical analysis (*R*²=0.092; *P* =0.032 and *R*² = 0.135; *P* =0.009, respectively) (Figure 3C, 3D). The results show that patients with a higher urine FA level have thinner RNFL especially in the superior and inferior quadrants of the RNFL.

DISCUSSION

Some of the known risk factors for POAG include IOP, age, genes and race^[29-30]. Medications, laser and surgery can all be used to treat POAG by lowering IOP. However, a proportion of patients develop glaucoma and continue to progress despite low IOP^[31]. Equally, a proportion of patients with

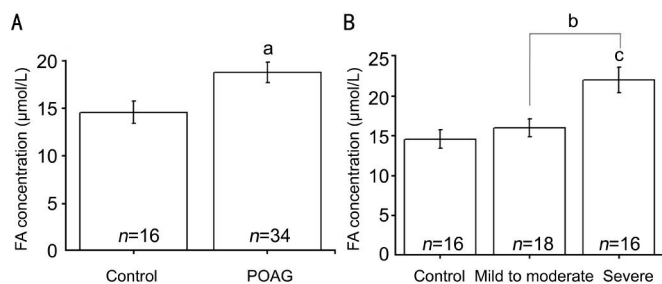


Figure 1 Elevated FA level of patients with POAG and visual field defect A: Urine FA levels in POAG and control group; B: The distribution of urine FA levels in the control, mild to moderate and severe POAG groups. POAG patients were divided into mild to moderate and severe groups according to the visual field defects (mild to moderate defect, MD<12dB; severe defect, MD ≥ 12 dB). Data was expressed as means±SEM. ^a *P*<0.05, ^b *P*<0.01, ^c *P*<0.001 by *t*-test and ANOVA.

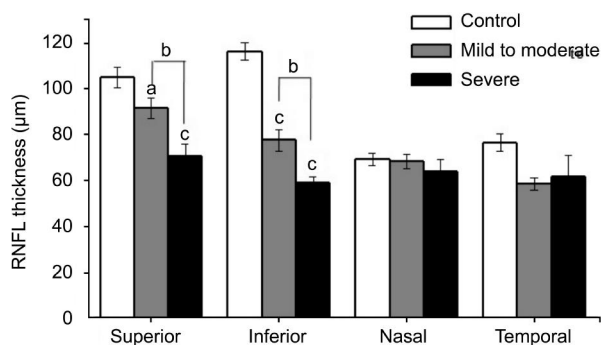


Figure 2 RNFL thickness of POAG and control groups detected by optical coherence tomography at superior, inferior, nasal and temporal quadrants of optic disc Total numbers of enrolled people were 50, including control group (*n* = 16), mild to moderate POAG (*n* =18) and severe POAG (*n* =16). ^a *P*<0.05, ^b *P*<0.01, ^c *P*<0.001 by ANOVA.

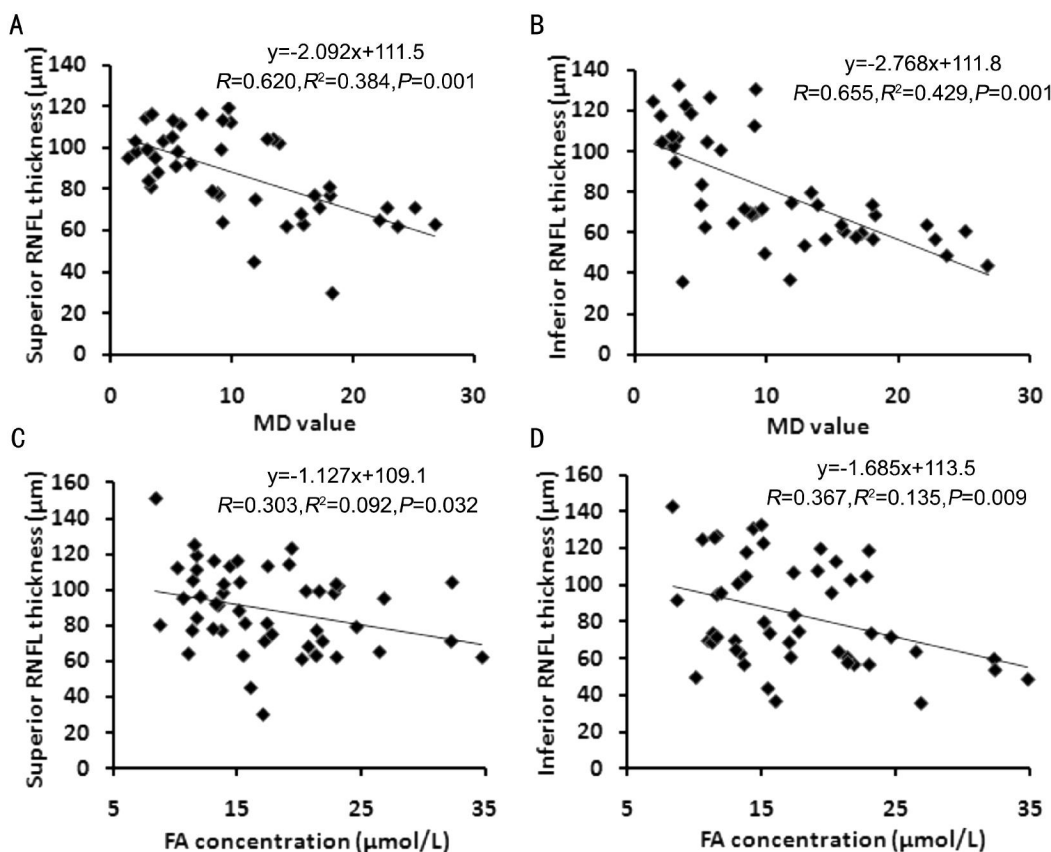


Figure 3 Defect of RNFL correlated with MD value and FA concentration Scattergrams showing linear regression analysis between MD value and RNFL thickness of superior quadrant (A) and inferior quadrant (B), respectively. Scattergrams showing linear regression analysis between urine FA concentration and RNFL thickness of superior quadrant (C) and inferior quadrant (D), respectively.

elevated IOP never develop POAG. Mechanisms other than IOP involved in glaucoma include low blood pressure, low cerebrospinal fluid pressure, obstructive sleep apnea syndrome, and peripheral vascular dysfunction. A greater understanding of these and other risk factors and searches for easily detectable biomarkers is needed to facilitate the diagnosis and monitoring of the effects of treatment of POAG.

Until now, no convenient biomarker has been available for the diagnosis of POAG, which requires assessment of the

patient's history pertaining to risk factors, fundus examinations and reliable visual field results. The recent findings about elevated urine FA in AD patients [16] and the association of the increased urinary 8-OHdG/creatinine with the progression of normal-tension glaucoma [32] bring the possibility to apply urine examination as a non-invasive adjunct in the diagnosis or follow-up of patients with POAG. In analyzing the urine FA level of participants aged >60y, we found that urine FA levels were elevated in POAG patients compared to those without POAG, and the significance of the

elevation is positively correlated to the severity of the glaucomatous defects. These results imply that excess endogenous FA may play a role in POAG, and suggest a new parameter for further investigation.

In this study, the enrolled participants are restricted to no less than 60y is because 1) the risk of developing POAG increases with age; and 2) under physiological conditions, the urine FA level in elderly over 60s is significant higher than young (22-28 years old)^[33]. Furthermore, the metabolic efficiency of old people begins to slow down, and the scavenging capacity of excess endogenous formaldehyde may decline in the old population^[33]. Therefore the risk of excessive FA toxicity by abnormal FA metabolism would be much higher to elderly people. Considering a much less percentage of elderly patients than that of young would be included for the exclusion criteria on the aging-related diseases, in this exploratory clinic trial, small samples were enrolled to study the risk factor of formaldehyde in POAG. Further analysis will be necessary to conduct with a larger number of samples, and to check if this correlation is also present in young POAGs, if the non-POAGs with abnormal high FA level will get a higher probability to develop POAGs.

The relationship between urine levels of FA and POAG needs further examination. Elevated levels of FA appear to be associated with both POAG and AD, and AD has been reported to be associated with POAG. To exclude the interference of senile dementia, patients with MMSE score less than the normal limit (MMSE<27) were excluded, as the urine FA of these patients is significant higher than in healthy controls and correlated with the cognitive impairment measured by MMSE^[16]. Our study found that urine FA level of POAG patients was still significantly higher than that of controls ($P < 0.01$), though the MMSE score of each participant was within the normal scope (Table 1). This indicates that the correlation between the abnormally high levels of urine FA with POAG is independent of AD, supporting our hypothesis that excess endogenous FA may be a common risk factor for or marker of neurodegeneration in both POAG and AD. In the POAG patients with abnormal high level of FA but no other diseases, the excessive FA is more like the cause than the result, as the severe POAG patients showed a mean level of urine FA around 1/3 greater than that of the control, which is unlikely to be induced just by the changes in eye. The FA level in the mild to moderate POAG was in fact also elevated though not significant, increasing the patient number in the future analysis would help to show the significance. It'll be interesting to see if the visual defect could be an earlier/sensitive indicator than the decrease of MMSE score to excess endogenous FA. Further investigations are necessary to compare cognitive status of POAG patients with varying severities of damage with

elevated urine FA, and to determine if AD patients with elevated urine FA have a greater prevalence of glaucomatous neurodegeneration.

There are multiple sources of cellular FA, including endogenous methylamine deamination, histone demethylation, methanol oxidation and exogenous intaking of the environmental formaldehyde. Also multiple pathways are involved in cellular formaldehyde disposal; thus the local FA levels could be different, between urine and retina, for the differential distribution of FA producing and metabolizing enzymes^[33-34]. Indeed, this difference has been detected between urine, blood, brain, and even between the different regions (hippocampus and cortex) of the brain^[19-20,35-36]. This difference between individuals might be a reason why some participants with abnormally high urine FA level have not developed POAG or AD. On the other hand, for the POAGs with high urine FA level, it would be helpful to consider the factors involved in abnormal accumulation of endogenous FA in the candidates of the causes. Resveratrol, a natural antioxidant with potential in glaucoma treatment^[37-38] has been shown to act as formaldehyde scavenger and attenuate FA-induced cognitive impairment in mice^[16]. Further investigation will be worthy to see if the anti-FA treatment^[39] will be helpful to against the progression of neural defect in FA-related POAGs.

Our study provides the first evidence that urine FA level is elevated in the elderly patients with POAG. Furthermore, the neural defects in POAG patients are positively correlated with the urine FA level. Examination of the urine FA levels may be useful as a non-invasive adjunct in the diagnosis or follow-up of patients with POAG.

ACKNOWLEDGEMENTS

We are grateful to Prof. Kwok-fai So (Department of Anatomy, The University of Hong Kong) for the helpful suggestions and discussions.

Foundations: Supported by National Basic Research Program of China (973 Program, No. 2012CB911004); the National Natural Science Foundation of China (No. 81041008; No. 30772376).

Conflicts of Interest: Cui Y, None; Su T, None; Zhang SD, None; Huang P, None; He YG, None; Liu Y, None; Zhang C, None; Ritch R, None; He RQ, None.

REFERENCES

- 1 Tsolaki F, Gogaki E, Tiganita S, Skatharoudi C, Lopatzizi C, Topozis F, Tsolaki M. Alzheimer's disease and primary open-angle glaucoma: is there a connection? *Clin Ophthalmol* 2011;5:887-890.
- 2 McKinnon SJ. Glaucoma: ocular Alzheimer's disease? *Front Biosci* 2003; 8:s1140-1156.
- 3 Tsilis AG, Tsilidis KK, Pelidou SH, Kitsos G. Systematic review of the association between Alzheimer's disease and chronic glaucoma. *Clin Ophthalmol* 2014;8:2095-2104.
- 4 Bayer AU, Ferrari F, Erb C. High occurrence rate of glaucoma among patients with Alzheimer's disease. *Eur Neurol* 2002;47(3):165-168.

- 5 Hinton DR, Sadun AA, Blanks JC, Miller CA. Optic-nerve degeneration in Alzheimer's disease. *N Engl J Med* 1986;315(8):485-487.
- 6 Polo V, Garcia-Martin E, Bambo MP, Pinilla J, Larrosa JM, Satue M, Otin S, Pablo LE. Reliability and validity of Cirrus and Spectralis optical coherence tomography for detecting retinal atrophy in Alzheimer's disease. *Eye (Lond)* 2014;28(6):680-690.
- 7 Tsai CS, Ritch R, Schwartz B, Lee SS, Miller NR, Chi T, Hsieh FY. Optic nerve head and nerve fiber layer in Alzheimer's disease. *Arch Ophthalmol* 1991;109(2):199-204.
- 8 McKinnon SJ, Lehman DM, Kerrigan-Baumrind LA, Merges CA, Pease ME, Kerrigan DF, Ransom NL, Tahzib NG, Reitsamer HA, Levkovich-Verbin H, Quigley HA, Zack DJ. Caspase activation and amyloid precursor protein cleavage in rat ocular hypertension. *Invest Ophthalmol Vis Sci* 2002;43(4):1077-1087.
- 9 Solomon MJ, Varshavsky A. Formaldehyde-mediated DNA-protein crosslinking: a probe for in vivo chromatin structures. *Proc Natl Acad Sci U S A* 1985;82(19):6470-6474.
- 10 Nie CL, Zhang W, Zhang D, He RQ. Changes in conformation of human neuronal tau during denaturation in formaldehyde solution. *Protein Pept Lett* 2005;12(1):75-78.
- 11 Nie CL, Wei Y, Chen X, Liu YY, Dui W, Liu Y, Davies MC, Tendler SJ, He RG. Formaldehyde at low concentration induces protein tau into globular amyloid-like aggregates in vitro and in vivo. *PLoS Onc* 2007;2(7):e629.
- 12 Liu F, Liang Z, Gong CX. Hyperphosphorylation of tau and protein phosphatases in Alzheimer disease. *Paininerva Med* 2006;48(2):97-108.
- 13 Lu J, Miao JY, Su T, Liu Y, He RQ. Formaldehyde induces hyperphosphorylation and polymerization of Tau protein both in vitro and in vivo. *Biochim Biophys Acta* 2013;1830(8):4102-4116.
- 14 Lu J, Li T, He R, Bartlett PF, Gotz J. Visualizing the microtubule-associated protein tau in the nucleus. *Sci China Life Sci* 2014;57(4):422-431.
- 15 Gurel A, Coskun O, Armutcu F, Kanter M, Ozen OA. Vitamin E against oxidative damage caused by formaldehyde in frontal cortex and hippocampus: biochemical and histological studies. *J Chem Neuroanat* 2005;29(3):173-178.
- 16 Tong ZQ, Zhang J, Luo W, Wang W, Li F, Li H, Luo H, Lu J, Zhou J, Wan Y, He R. Urine formaldehyde level is inversely correlated to mini mental state examination scores in senile dementia. *Neurobiol Aging* 2011;32(1):31-41.
- 17 Yu J, Su T, Zhou T, He Y, Lu J, Li J, He R. Uric formaldehyde levels are negatively correlated with cognitive abilities in healthy older adults. *Neurosci Bull* 2014;30(2):172-184.
- 18 Wang J, Su T, Liu Y, Yue Y, He R. Postoperative cognitive dysfunction is correlated with urine formaldehyde in elderly noncardiac surgical patients. *Neurochem Res* 2012;37(10):2125-2134.
- 19 Tong Z, Han C, Luo W, Wang X, Li H, Luo H, Zhou J, Qi J, He R. Accumulated hippocampal formaldehyde induces age-dependent memory decline. *Age (Dordr)* 2012;35(3):583-596.
- 20 Tong ZQ, Han CS, Luo W, Li H, Luo H, Qiang M, Su T, Wu B, Liu Y, Yang X, Wan Y, Cui D, He RQ. Aging-associated excess formaldehyde leads to spatial memory deficits. *Sci Rep* 2013;3:1807.
- 21 Sharma M, Volpe NJ, Dreyer EB. Methanol-induced optic nerve cupping. *Arch Ophthalmol* 1999;117(2):286.
- 22 Cursiefen C, Bergua A. Acute bilateral blindness caused by accidental methanol intoxication during fire "eating". *Br J Ophthalmol* 2002;86(9):1064-1065.
- 23 Stelmach MZ, O'Day J. Partly reversible visual failure with methanol toxicity. *Aust NZ J Ophthalmol* 1992;20(1):57-64.
- 24 Shin YW, Uhm KB. A case of optic nerve atrophy with severe disc cupping after methanol poisoning. *Korean J Ophthalmol* 2011;25(2):146-150.
- 25 Mwanza JC, Oakley JD, Budenz DL, Anderson DR; Cirrus Optical Coherence Tomography Normative Database Study Group. Ability of cirrus HD-OCT optic nerve head parameters to discriminate normal from glaucomatous eyes. *Ophthalmology* 2011;118(2):241-248 e1.
- 26 Na JH, Sung KR, Lee JR, Lee KS, Baek S, Kim HK, Sohn YH. Detection of glaucomatous progression by spectral-domain optical coherence tomography. *Ophthalmology* 2013;120(7):1388-1395.
- 27 Su T, Wei Y, He RQ. Assay of brain endogenous formaldehyde with 2, 4-dinitrophenylhydrazine through UV-HPLC. 2011;38(12):1171-1177.
- 28 Cooper JK, Mungas D, Weiler PG. Relation of cognitive status and abnormal behaviors in Alzheimer's disease. *J Am Geriatr Soc* 1990;38(8):867-870.
- 29 Fan BJ, Leung YF, Wang N, Lam SC, Liu Y, Tam OS, Pang CP. Genetic and environmental risk factors for primary open-angle glaucoma. *Chin Med J (Engl)* 2004;117(5):706-710.
- 30 Gong WF, Chiang SW, Chen LJ, Tam PO, Jia LY, Leung DY, Geng YQ, Tham CC, Lam DS, Ritch R, Wang N, Pang CP. Evaluation of LOXL1 polymorphisms in primary open-angle glaucoma in southern and northern Chinese. *Mol Vis* 2008;14:2381-2389.
- 31 Pascale A, Drago F, Govoni S. Protecting the retinal neurons from glaucoma: lowering ocular pressure is not enough. *Pharmacol Res* 2012;66(1):19-32.
- 32 Yuki K, Tsubota K. Increased urinary 8-hydroxy-2'-deoxyguanosine (8-OHdG)/creatinine level is associated with the progression of normal-tension glaucoma. *Curr Eye Res* 2013;38(9):983-988.
- 33 He R, Lu J, Miao JY. Formaldehyde stress. *Sci China Life Sci* 2010;53(12):1399-1404.
- 34 Tulpule K, Dringen R. Formaldehyde in brain: an overlooked player in neurodegeneration? *J Neurochem* 2013;127(1):7-21.
- 35 Bartlett PF, He R. Introduction to the thematic issue "From brain function to therapy". *Sci China Life Sci* 2014;57(4):363-365.
- 36 Chen J, Sun M, Wang X, Lu J, Wei Y, Tan Y, Gotz J, He R, Hua Q. The herbal compound geniposide rescue formaldehyde-induced apoptosis in N2a neuroblastoma cells. *Sci China Life Sci* 2014;57(4):412-421.
- 37 Mozaffarieh M, Grieshaber MC, Orgul S, Flammer J. The potential value of natural antioxidative treatment in glaucoma. *Surv Ophthalmol* 2008;53(5):479-505.
- 38 Luna C, Li G, Liton PB, Qiu J, Epstein DL, Challa P, Gonzalez P. Resveratrol prevents the expression of glaucoma markers induced by chronic oxidative stress in trabecular meshwork cells. *Food Chem Toxicol* 2009;47(1):198-204.
- 39 Gong C. From brain function to therapy. *Sci China Life Sci* 2014;57(4):467-468.