

Long-term results of viscocanalostomy and phacoviscocanalostomy: a twelve-year follow-up study

Uzeyir Gunenc, Taylan Ozturk, Gul Arikan, Nilufer Kocak

Department of Ophthalmology, Dokuz Eylul University School of Medicine, Inciralti, Izmir 35340, Turkey

Correspondence to: Taylan Ozturk. Department of Ophthalmology, Dokuz Eylul University School of Medicine, Inciralti, Izmir 35340, Turkey. ataylan6@yahoo.com

Received: 2014-07-22

Accepted: 2014-11-04

• **KEYWORDS:** glaucoma; non-penetrating glaucoma surgery; phacoviscocanalostomy; viscocanalostomy

DOI:10.3980/j.issn.2222-3959.2015.06.15

Gunenc U, Ozturk T, Arikan G, Kocak N. Long-term results of viscocanalostomy and phacoviscocanalostomy: a twelve-year follow-up study. *Int J Ophthalmol* 2015;8(6):1162-1167

Abstract

• **AIM:** To evaluate the long-term efficacy and safety results of viscocanalostomy and phacoviscocanalostomy.

• **METHODS:** The charts of 49 glaucoma patients who underwent viscocanalostomy or phacoviscocanalostomy surgery between February 1999 and August 2004 were reviewed retrospectively. Thirty-one eyes of 21 glaucoma patients who underwent filtering procedure with a postoperative follow-up of at least 5y were included in the study. Results of complete ophthalmologic examinations were recorded and statistically analyzed. Long-term surgical outcome was defined as an overall success when intraocular pressure (IOP) was found as ≤ 20 mm Hg with or without antiglaucomatous medication at the last follow-up visit, while it was defined as a complete success when IOP was measured ≤ 20 mm Hg without antiglaucomatous medication.

• **RESULTS:** Mean age was 68.1 ± 9.6 y (range: 32-81y). Mean follow-up time was 101.5 ± 27.3 mo (range: 60-144mo). Visccanalostomy was performed in 8 eyes (25.8%) and phacoviscocanalostomy was performed in 23 eyes (74.2%). The mean preoperative IOP was 23.1 ± 7.6 mm Hg with 2.1 ± 1.0 medications, while mean IOP was 16.8 ± 3.8 mm Hg with 0.9 ± 1.1 medication at the last follow-up visit. Both the IOP decrease and the reduction in the antiglaucomatous medication were statistically significant ($P < 0.001$ and $P < 0.001$). No case required further glaucoma surgery. Overall success and complete success were found as 87.1% and 51.6%, respectively. Complete success rate was statistically higher in phacoviscocanalostomy group compared with the visccanalostomy group ($P = 0.031$), however there was no significant difference in overall success rate between two groups ($P = 0.072$).

• **CONCLUSION:** Both visccanalostomy and phacoviscocanalostomy provide good IOP reduction in the long-term period.

INTRODUCTION

Glaucoma is an optic neuropathy characterized by progressive retinal ganglion cell death. Elevated intraocular pressure (IOP) that is the only risk factor amenable to treatment, is accused for one of the major risk factors of progressive glaucomatous optic neuropathy^[1-3]. Topical and systemic antiglaucomatous medications are generally effective in lowering IOP, however surgical interventions must be scheduled in cases with recalcitrant glaucoma. Although trabeculectomy still remains the gold standard for the surgical treatment of glaucoma, recently nonpenetrating glaucoma surgery is becoming popular since trabeculectomy is fraught with several complications mostly stemmed from overfiltration. Glaucoma drainage device implantation has recently been reported as effective as trabeculectomy at reducing both IOP and the necessity of further reoperations. However, the risk of major complications such as infection, overfiltration and device exposure through the conjunctiva ought to be kept in mind^[4-6]. Visccanalostomy, which was firstly described by Stegmann *et al*^[7] is a commonly preferred nonpenetrating glaucoma surgery. Deroofing Schlemm's canal, creating a Descement's "window", and injecting a high molecular-weight viscoelastic material into the ostia are the major three steps of such surgery. Besides the efficacy on lowering IOP, visccanalostomy that is a relatively new, nonpenetrating glaucoma filtering procedure has been reported as a safer surgical intervention owing to the decreased risk for serious complications such as bleb leaks, hypotony, flat anterior chamber, choroidal detachment, blebitis and endophthalmitis^[3-16].

Since the prevalences of both cataract and glaucoma increase with age, phakic patients who are scheduled for glaucoma surgery may also require cataract extraction. On the other hand, the increased risk of cataract development is a well-known complication of glaucoma surgery^[17]. In

glaucomatous eyes with visually significant cataract, combined cataract and glaucoma surgery has gradually become a popular treatment option. Both the recent developments in small-incision phacoemulsification and much more stable anterior chamber secured with nonpenetrating glaucoma filtering procedures may prompt combined viscocanalostomy and cataract surgery in patients with glaucoma and a coexisting cataract. The minimum limit of postoperative follow-up period was reported as one year in most of the articles evaluating the long-term results of nonpenetrating glaucoma surgery [12-16], whereas surgically treated glaucoma patients with a postoperative follow-up of at least five years were included in our study. Viscocanalostomy and phacoviscocanalostomy have been treatment of choice in favorable patients for nonpenetrating glaucoma surgery in our clinic since 1998. Herein, we evaluated the twelve-year clinical outcomes of viscocanalostomy and phacoviscocanalostomy.

SUBJECTS AND METHODS

The charts of patients who underwent viscocanalostomy or phacoviscocanalostomy surgery between February 1999 and August 2004 were reviewed retrospectively. In this period, a total of 70 eyes of 49 patients were underwent viscocanalostomy or phacoviscocanalostomy. However, 17 cases discontinued the follow-up because of death, 7 because of moving to another city, and 4 were lost to follow-up. A total of 31 eyes of 21 glaucoma patients who underwent viscocanalostomy or phacoviscocanalostomy with a postoperative follow-up of at least 5y were included in the study. A detailed medical history was obtained from each participant to identify concomitant systemic pathologies such as diabetes mellitus, hypertension and current drug therapy. Patients with ocular disease except glaucoma, cataract, and refractive errors, as well as those who underwent any other ocular surgeries except glaucoma or cataract were excluded. All participants were Turkish and underwent a complete ophthalmologic examination including slit-lamp biomicroscopy, testing for best corrected visual acuity (BCVA), Goldmann applanation tonometry, gonioscopy, Humphrey visual field analysis, dilated funduscopy and optic nerve head examinations. This study was conducted in accordance with the methods described adhered to tenets of the Declaration of Helsinki and all subjects gave written informed consent prior to enrollment.

Surgical Technique Viscocanalostomy and phacoviscocanalostomy were performed under topical anesthesia. After creating a superior fornix-based peritomy, limbal-based half-thickness scleral flap (5×5 mm) was made and extended 1.5 mm forward into the clear cornea. Afterwards a deep, smaller scleral flap (approximately 4×4 mm) was prepared below the superficial flap. Subsequently, tissue dissection was performed till Schlemm's canal was reached.

Phacoemulsification was performed at this stage of operation in cases with visually significant cataract and also in cases with angle closure glaucoma. After tight closing of clear corneal incision with 10-0 nylon suture, Schlemm's canal was unroofed and the fibrotic tissue was simultaneously removed from the bottom of the canal. After the Schlemm's canal had been de-roofed and the trabecular-Descemet window had been created, high-viscosity sodium hyaluronate (Healon GV; Abbott Medical Optic Inc., Santa Ana, CA, USA) was injected into the cut ends of Schlemm's canal on both sides *via* a viscocanalostomy cannulation. The deep flap was excised and the superficial flap was sutured with four separate 10-0 nylon sutures. Healon GV was injected under the flap and conjunctival flap was closely sutured. Postoperative management included topical administration of ofloxacin 0.3% drop *qid* with tapered schedule of prednisolone acetate 1%. Antiglaucomatous medication was ceased after surgery in all cases.

Gonioscopic findings, preoperative IOP levels and administered antiglaucomatous medications were recorded for each study eye. Presence of characteristic glaucomatous cupping and cup/disc ratio that was measured *via* both dilated funduscopy and Heidelberg retina tomography (HRT) were noted. Mean deviation (MD) and pattern standard deviation (PSD) scores obtained from standard automated perimetry [full-threshold or Swedish Interactive Threshold Algorithm (SITA) strategy, program 30-2, Humphrey Field Analyzer] were also recorded. Scores of such parameters were also recorded at the last follow-up visit and compared with the preoperative values. For statistical analysis, BCVA was converted into logMAR unit. Visual acuity of patients who could see only hand motions from 2 feet was conceded as 3.00 logMAR^[18]. Long-term surgical outcome was defined as an overall success when IOP was measured ≤ 20 mm Hg at the last follow-up visit, while it was defined as a complete success when IOP was measured ≤ 20 mm Hg without antiglaucomatous medication.

Statistical analysis was performed using software SPSS version 16.0 (SPSS Inc., Chicago, Illinois, USA). Wilcoxon signed rank, Mann-Whitney U , Yates' Chi-squared, and paired-samples t -tests were used in statistical analysis where appropriate, and a P -value less than 0.05 was considered as statistically significant.

RESULTS

A total of 31 eyes of 21 patients were included in the study. Eleven patients were female (52.4%) and 10 patients were male (47.6%). Mean age was 68.1 ± 9.6 y (range, 32-81y). Mean follow-up time was 101.5 ± 27.3 mo (range, 60-144mo). Sixteen eyes (51.6%) had a follow-up time of more than 10y. Twenty eyes (64.5%) had primary open angle glaucoma (POAG), 7 (22.6%) eyes had secondary glaucoma (5 pseudoexfoliation glaucoma; 2 pigmentary glaucoma), and 4

eyes (12.9%) had angle-closure glaucoma. Viscocanalostomy was performed in 8 eyes (25.8%), while phacoviscocanalostomy was performed in 23 eyes (74.2%). Cases with a visually significant dense cataract were strictly advised for combined surgery, but patients with mild or moderate grade cataracts had made their own decision about simultaneous phacoemulsification surgery after information given in detail. Therefore 8 eyes of 7 patients underwent only nonpenetrating glaucoma surgery even though they were all phakic. These cases also had not accepted to undergo any other surgical interventions including phacoemulsification, probably because the fact that any remarkable visual loss was not seen in their operated eyes during the follow-up period. Adjunctive mitomycin C was not applied at the time of surgery in any patients. A collagen implant (Aqua-Flow, Staar Surgical AG, Nidau, Switzerland) was used in the surgical procedure of the first 7 eyes consecutively (22.6%). However, we gave up using such implant afterwards since no significant efficacy could be proven in our implant-positive cases. Intraoperative complications such as microperforation and macroperforation were noted in 4 (12.9%) and 2 (6.5%) eyes, respectively. However, hypotony or choroidal detachment did not develop in any of the study eyes in the postoperative period. At the last control visit, slit-lamp biomicroscopy revealed flat filtering bleb formation in 8 eyes, while long-term hypotony and bleb-associated complications had not developed during the follow-up. Demographics were shown in Table 1.

The mean preoperative IOP was 23.1 ± 7.6 mm Hg (range, 16-55 mm Hg) with 2.1 ± 1.0 (range: 0-4) medications, while mean IOP was measured as 16.8 ± 3.8 mm Hg (range, 11-28 mm Hg) with 0.9 ± 1.1 (range: 0-3) medication at the last follow-up visit. Decrease in both IOP level and the total number of antiglaucomatous medication were found to be statistically significant when analyzed with paired-samples *t*-test (*P* < 0.001 and *P* < 0.001, respectively). None of the study cases required further glaucoma surgery. The changes in mean IOP and mean number of antiglaucomatous medication were demonstrated in Figure 1.

The mean score of BCVA was 0.74 ± 0.53 logMAR at baseline, whereas it was found as 0.47 ± 0.50 logMAR at the last follow-up visit. A statistically significant difference was found in preoperative BCVA between two study groups (*P* = 0.010). The mean score of final BCVA was as 0.91 ± 0.44 logMAR in viscocanalostomy group and 0.31 ± 0.43 logMAR in phacoviscocanalostomy group. Although better visual outcome was achieved in phacoviscocanalostomy group (*P* = 0.004), Mann-Whitney *U* test revealed no significant difference in IOP decrease between the patients who underwent viscocanalostomy and phacoviscocanalostomy (*P* = 0.540). Table 2 demonstrates the visual acuity changes in study eyes.

Table 1 Demographics

Parameters	P-VC	VC	n (%)
Number of patients	14 (66.7)	7 (33.3)	21
Number of eyes	23 (74.2)	8 (25.8)	31
Mean age (a)	68.0 ± 9.4	68.5 ± 10.5	68.1 ± 9.5
Gender			
F	9 (64.3)	2 (28.6)	11 (52.4)
M	5 (35.7)	5 (71.4)	10 (47.6)
Diagnosis			
POAG	16 (69.6)	4 (50.0)	20 (64.5)
SG	3 (13.0)	4 (50.0)	7 (22.6)
ACG	4 (17.4)	-	4 (12.9)
Mean follow-up (mo)	101.4 ± 27.9	101.8 ± 27.5	101.5 ± 27.3
Surgical details			
Adjuvante MMC	-	-	-
Collagen implant	2 (8.7)	5 (62.5)	7 (22.6)
Microperforation	2 (8.7)	2 (25.0)	4 (12.9)
Macroperforation	2 (8.7)	-	2 (6.4)

P-VC: Phacoviscocanalostomy; VC: Viscocanalostomy; POAG: Primary open angle glaucoma; SG: Secondary glaucoma; ACG: Angle-closure glaucoma; MMC: Mitomycin C.

Table 2 Changes in mean BCVA, IOP, and the number of antiglaucomatous medication after nonpenetrating glaucoma surgery in study groups

Parameters	P-VC	VC	<i>P</i>
Preoperative mean BCVA (logMAR)	0.69 ± 0.31	0.90 ± 0.94	0.819
Mean BCVA at the last visit (logMAR)	0.31 ± 0.43	0.91 ± 0.44	0.004
Preoperative mean IOP (mm Hg)	21.5 ± 4.8	27.5 ± 12.2	0.102
Mean number of AGM (preoperatively)	2.3 ± 1.0	1.5 ± 0.9	0.070
Mean IOP at the last visit (mm Hg)	16.0 ± 3.5	19.1 ± 3.9	0.043
Mean number of AGM (at the last visit)	0.6 ± 0.9	1.6 ± 1.1	0.014
Mean IOP decrease (mm Hg)	5.6 ± 3.6	8.4 ± 13.4	0.540

P-VC: Phacoviscocanalostomy; VC: Viscocanalostomy; BCVA: Best corrected visual acuity; IOP: Intraocular pressure; AGM: Antiglaucomatous medication.

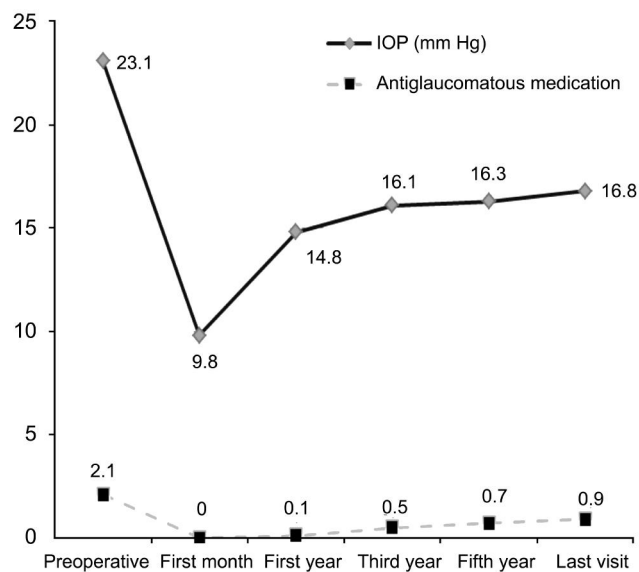


Figure 1 Changes in mean IOP and mean number of antiglaucomatous medication with time.

Overall success was found as 87.1%; however complete success was achieved in 51.6% of the study eyes (Figure 2). Complete success rate was statistically higher in

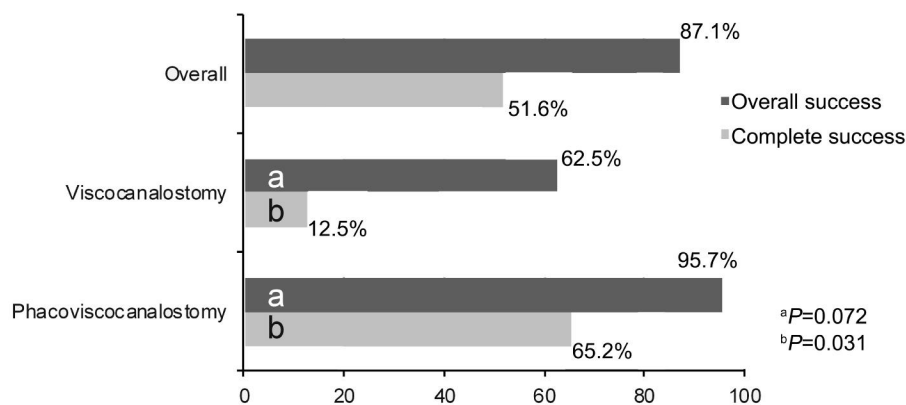


Figure 2 Complete and overall success rates of subgroups.

phacovisco canalostomy when compared to visco canalostomy group ($P=0.031$). However, Yates' Chi-squared test revealed no significant difference in overall success rate between the visco canalostomy and phacovisco canalostomy groups ($P=0.072$). Among 20 eyes with POAG, overall success was statistically higher in phacovisco canalostomy group ($P=0.040$), whereas Yates' Chi-squared test revealed no significant difference in overall success rate between two study groups ($P=0.576$). All of the eyes with angle-closure glaucoma underwent combined surgery, so subgroup analysis could not be performed in such cases. When long-term surgical outcomes were evaluated in patients with secondary glaucoma, no statistically significant difference was found in both complete and overall success rates between visco canalostomy and combined surgery groups ($P=0.277$ and $P=0.810$, respectively). Severe progression in visual field defects were not seen in any of the study eyes. Both MD and PSD scores, which were obtained from visual field analysis (automated perimetry, standard SITA strategy, program 30-2) deteriorated with time in 30 eyes (96.8%), diffuse enlargement in glaucomatous cupping was present in 18 eyes (58.1%).

DISCUSSION

Non-penetrating surgery in glaucoma have gained increasing interest due to the significant IOP reducing effect and minimizing the surgical complications associated with conventional filtration procedures, such as excessive filtration resulting in a flat anterior chamber, choroidal detachment, persistent hypotony and blebitis that may cause endophthalmitis [3-16]. In nonpenetrating glaucoma surgery, abnormal high resistance to trabecular outflow is ameliorated by dilating Schlemm's canal and reestablishing the natural aqueous outflow channels *via* the injection of ophthalmic viscosurgical device. The efficacy of visco canalostomy on lowering IOP in the long term period has been demonstrated by various authors [3-16,19-23]. David *et al* [10] published a complete success (IOP<21 mm Hg without medication) rate of 54% at 60mo after visco canalostomy in eyes with POAG and secondary open angle glaucoma. Although both deep

sclerectomy and visco canalostomy have been reported to be less effective than trabeculectomy in lowering IOP, nonpenetrating glaucoma surgery also causes fewer surgical complications [3-16]. In a Meta-analysis complete success rates (IOP<21 mm Hg without medication) at 4y were found as 35.4%, 22.7% and 47.6% in deep sclerectomy, visco canalostomy, and trabeculectomy, respectively [13]. Although visco canalostomy appears as an effective and safe procedure in reducing IOP in patients with medically uncontrolled glaucoma, the influence of prolonged learning curve on the surgical outcomes of such procedure has to be considered. In a mean follow-up of 28.9mo, Stangos *et al* [19] reported an improved overall success (IOP ≤ 20 mm Hg) from 64% to 91% and also improved complete success (IOP ≤ 20 mm Hg without medication) from 38% to 73% when comparing the first 45 to the last 45 cases of the series. At the mean follow-up of 101.8±27.5mo, overall success was found in 5 eyes (62.5%); however complete success was achieved in one (12.5%) out of our 8 study eyes who underwent visco canalostomy surgery alone.

Similarly efficient and safe IOP reduce is also provided with phacovisco canalostomy in patients with glaucoma and clinically significant cataract [20-23]. Stangos *et al* [20] published the overall success (IOP ≤ 20 mm Hg) and complete success (IOP ≤ 20 mm Hg without medication) rates of phacovisco canalostomy at the last visit for each patient as 86% and 67%, respectively. Hassan and Awadalla [21] reported a complete surgical success rate of 90% after phacovisco canalostomy, while qualified success that was defined as IOP<21 mm Hg with or without glaucoma medication was achieved in 100% of their study population. Greater IOP reduction and fewer requirement of postoperative antiglaucomatous medications after phacovisco canalostomy were published in cases with pseudoexfoliation glaucoma when compared to the cases with POAG [22]. However excellent IOP control and visual acuity improvement in both pseudoexfoliation glaucoma and POAG groups were achieved with phacovisco canalostomy [22]. Wishart *et al* [23] reported complete success (IOP ≤ 18 mm Hg

without medication) rates of 76% with a mean IOP reduction of 29.9% for POAG patients undergoing phacoviscocanalostomy and 67% with a mean IOP reduction of 40% for POAG patients undergoing viscocanalostomy alone. In the same study, complete success rates following phacoviscocanalostomy and viscocanalostomy were 95% with a mean IOP reduction of 42.5% and 63% with a mean IOP reduction of 51% , respectively in eyes with pseudoexfoliation glaucoma. In our study with a mean follow-up time of 101.5 ±27.3mo, an IOP of ≤18 mm Hg was achieved in 78.3% and 75.0% of the study eyes in phacoviscocanalostomy and viscocanalostomy groups, respectively. Moreover, an IOP score that was measured below or equal to 18 mm Hg without any antiglaucomatous medication was achieved in 39.1% and 25.0% of the eyes in our study groups, respectively. Al-Obeidan *et al*^[24] reported the safety and efficacy of deep sclerectomy in patients with uncontrolled open angle glaucoma. In this study complete success (IOP<20 mm Hg without medication) and overall success (IOP<20 mm Hg) rates were found as 82% and 90.2%, respectively. Authors also defined the significant risk factors for surgical failure as being exposed to previous surgeries, higher IOP at baseline, and being lower than 50y at the time of surgery. However glaucoma operation that was combined with cataract extraction and converted to penetrating surgery had been found to be significantly related with improved success rate^[24]. In accordance with the other studies we found overall success as 87.1% and complete success as 51.6% in the current study. Complete success rate was statistically higher in patients underwent phacoviscocanalostomy when compared with the cases in whom cataract extraction was not performed. However no significant difference was found in overall success rate between the eyes underwent viscocanalostomy and phacoviscocanalostomy.

Since conventional glaucoma surgery with conjunctival bleb formation carries a potential risk for post-operative infection in terms of blebitis and related endophthalmitis, the majority of such nightmare complications are largely eliminated by nonpenetrating procedures. Although flat filtering bleb formation was diagnosed in 8 eyes of our study group, long-term hypotony and bleb-associated complications did not develop in any cases.

As retinal ganglion cell dysfunction gradually leads to cell apoptosis through multifactorial mechanisms in glaucoma, continuum optic neuropathy has been well described in such disease^[25]. Despite an effective IOP reduction, patients with glaucoma may suffer from irreversible optic neuropathy and vision loss with time. However both MD and PSD scores of visual field analysis on standard automated perimetry deteriorated by the time in 96.8% of our study eyes. The rate

of progression in glaucomatous cupping was found as 58.1% when compared with the preoperative scores.

In conclusion, viscocanalostomy and phacoviscocanalostomy that provided stable reduction in IOP even in long-term of follow-up, appear to be safe and effective surgical procedures in glaucoma management. However, further long-term studies with large cohorts of patients to determine the very long-term efficacy and safety of such procedures in patients with glaucoma are needed. Although viscocanalostomy has a significant learning curve, high long-term success rates and low complication rates may encourage glaucoma surgeons in order to perform non-penetrating glaucoma surgeries in an ascending trend.

ACKNOWLEDGEMENTS

Conflicts of Interest: Gunenc U, None; Ozturk T, None; Arikan G, None; Kocak N, None.

REFERENCES

- 1 Miglior S, Bertuzzi F. Relationship between intraocular pressure and glaucoma onset and progression. *Curr Opin Pharmacol* 2013;13(1):32–35
- 2 Heijl A, Leske MC, Bengtsson B, Hyman L, Bengtsson B, Hussein M; Early Manifest Glaucoma Trial Group. Reduction of intraocular pressure and glaucoma progression: results from the Early Manifest Glaucoma Trial. *Arch Ophthalmol* 2002;120(10):1268–1279
- 3 Garway-Heath DF, Lascaratos G, Bunce C, Crabb DP, Russel RA, Shah A; United Kingdom Glaucoma Treatment Study Investigators. The United Kingdom Glaucoma Treatment Study: a multicenter, randomized, placebo-controlled clinical trial: design and methodology. *Ophthalmology* 2013;120(1):68–76
- 4 Gedde SJ, Schiffman JC, Feuer WJ, Herndon LW, Brandt JD, Budenz DL; Tube versus Trabeculectomy Study Group. Treatment outcomes in the Tube Versus Trabeculectomy (TVT) study after five years of follow-up. *Am J Ophthalmol* 2012;153(5):789–803.e2
- 5 Muir KW, Lim A, Stinnett S, Kuo A, Tseng H, Walsh MM. Risk factors for exposure of glaucoma drainage devices: a retrospective observational study. *BMJ Open* 2014;4(5):e004560
- 6 Mariotti C, Dahan E, Nicolai M, Levitz L, Bouee S. Long-term outcomes and risk factors for failure with the EX-press glaucoma drainage device. *Eye(Lond)* 2014;28(1):1–8
- 7 Stegmann R, Pienaar A, Miller D. Viscocanalostomy for open-angle glaucoma in black African patients. *J Cataract Refract Surg* 1999;25(3):316–322
- 8 Grieshaber MC. Ab externo Schlemm's canal surgery: viscocanalostomy and canaloplasty. *Dev Ophthalmol* 2012;50:109–124
- 9 Razeghinejad MR, Fudemberg SJ, Spaeth GL. The changing conceptual basis of trabeculectomy: a review of past and current surgical techniques. *Surv Ophthalmol* 2012;57(1):1–25
- 10 David VP, Kutty KG, Somasundaram N, Varghese AM. Five-year results of viscocanalostomy. *Eur J Ophthalmol* 2008;18(3):417–422
- 11 Mendrinós E, Mermoud A, Shaarawy T. Nonpenetrating glaucoma surgery. *Surv Ophthalmol* 2008;53(6):592–630
- 12 Hondur A, Onol M, Hasanreisoglu B. Nonpenetrating glaucoma surgery: meta-analysis of recent results. *J Glaucoma* 2008;17(2):139–146
- 13 Cheng JW, Cheng SW, Cai JP, Li Y, Wei RL. Systematic overview of the efficacy of nonpenetrating glaucoma surgery in the treatment of open angle glaucoma. *Med Sci Monit* 2011;17(7):RA155–163

- 14 Chai C, Loon SC. Meta-analysis of viscocanalostomy versus trabeculectomy in uncontrolled glaucoma. *J Glaucoma* 2010;19 (8): 519-527
- 15 Cheng JW, Xi GL, Wei RL, Cai JP, Li Y. Efficacy and tolerability of nonpenetrating filtering surgery in the treatment of open-angle glaucoma: a meta-analysis. *Ophthalmologica* 2010;224(3):138-146
- 16 Moradian K, Deneshvar R, Saffarian L, Esmaeeli H, Hosseinneshad H. The efficacy of viscocanalostomy for uncontrollable primary open-angle glaucoma in a developing country. *Indian J Ophthalmol* 2013;61(2):71-73
- 17 Patel HY, Danesh-Meyer HV. Incidence and management of cataract after glaucoma surgery. *Curr Opin Ophthalmol* 2013;24(1):15-20
- 18 Holladay JT. Visual acuity measurements. *J Cataract Refract Surg* 2004;30(2):287-290
- 19 Stangos AN, Mavropoulos A, Leuenberger PM, Sunaric-Megevand G. The effect of learning curve on the surgical outcome of viscocanalostomy. *J Glaucoma* 2012;21(6):408-414
- 20 Stangos AN, Mavropoulos A, Sunaric-Megevand G. Phaco-viscocanalostomy for open-angle glaucoma with concomitant age-related cataract. *Clin Ophthalmol* 2007;1(4):497-504
- 21 Hassan KM, Awadalla MA. Results of combined phacoemulsification and viscocanalostomy in patients with cataract and pseudoexfoliative glaucoma. *Eur J Ophthalmol* 2008;18(2):212-219
- 22 Awadalla MA, Hassan KM. Phacoviscocanalostomy in pseudoexfoliation glaucoma versus primary open-angle glaucoma. *Can J Ophthalmol* 2011; 46(1):77-82
- 23 Wishart PK, Wishart MS, Choudhary A, Grierson I. Long-term results of viscocanalostomy in pseudoexfoliative and primary open angle glaucoma. *Clin Experiment Ophthalmol* 2008;36(2):148-155
- 24 Al-Obeidan SA, Mousa A, Naseem A, Abu-Amero KK, Osman EA. Efficacy and safety of non-penetrating deep sclerectomy surgery in Saudi patients with uncontrolled open angle glaucoma. *Saudi Med J* 2013;34(1): 54-61
- 25 Weinreb RN, Friedman DS, Fechtner RD, Cioffi GA, Coleman AL, Girkin CA, Liebmann JM, Singh K, Wilson MR, Wilson R, Kannel WB. Risk assessment in the management of patients with ocular hypertension. *Am J Ophthalmol* 2004;138(3):458-467