

# Visco chop– a new technique for nucleus separation for soft cataracts in femtolaser assisted cataract surgery

*Sri Ganesh, Sheetal Brar*

Department of Phacorefractive, Nethradhama Superspeciality Eye Hospital, Bangalore 560082, India

**Correspondence to:** Sheetal Brar. Department of Phacorefractive, Nethradhama Superspeciality Eye Hospital, 256/14, Kanakapura Main Road, 7<sup>th</sup> Block Jayanagar, Bangalore 560082, India. brar\_sheetal@yahoo.co.in

Received: 2015-03-06 Accepted: 2015-06-01

**DOI:10.3980/j.issn.2222-3959.2015.04.36**

Ganesh S, Brar S. Visco chop– a new technique for nucleus separation for soft cataracts in femtolaser assisted cataract surgery. *Int J Ophthalmol* 2015;8(4):843–845

## INTRODUCTION

Femtosecond laser technology, introduced clinically for ophthalmic surgery as a technique for creating lamellar flaps in laser *in situ* keratomileusis (LASIK), has recently been developed into a tool for cataract surgery. Preliminary experience for femtosecond laser-assisted cataract surgery show appropriate safety and efficacy, and possible advantage over conventional cataract surgery<sup>[1-4]</sup>.

The ability of the femtosecond laser to fragment the lens results in the need for less ultrasound energy to be expended inside the eye. Several studies indicate that less effective phacoemulsification time is needed to emulsify the lens following lens fragmentation by the femtosecond laser<sup>[5-10]</sup>. This translates into less endothelial cell loss due to the shorter phacoemulsification times and less fluid entering and exiting the eye during surgery<sup>[11-13]</sup>. These advantages have been mainly attributed to the feature of lens fragmentation and softening in different patterns provided by the various femtolaser platforms<sup>[14]</sup>. Once the nucleus is fragmented and softened, the grooves made by laser can be easily separated by using a second instrument and nucleus emulsified with standard methods of divide and conquer, stop and chop or direct chopping. Since the grooves created by laser are extremely narrow, the second instrument chosen should also be narrow to allow proper and complete separation of the nucleus. Various instruments such as an Akahoshi chopper (Katena Products, Inc.), Nagahara chopper (Storz Ophthalmics), Cionni chopper (Duckworth & Kent), or a Neuhann chopper (Geuder AG) have been described for this purpose. Creation of a side port for second instrument and the

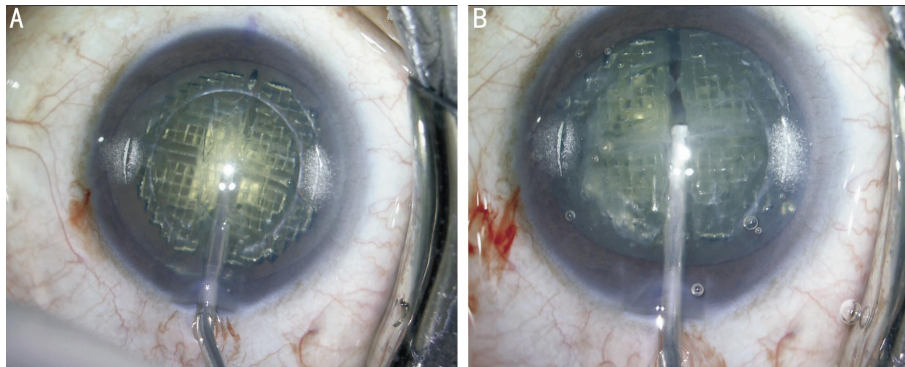
use of second instrument itself in turn may add to the risk and surgical time<sup>[14]</sup>.

We describe a simple and efficient method, the "visco chop" for separation of pre fragmented nucleus using a low viscosity dispersive viscoelastic substance in a one handed technique that may potentially improve the safety and reduce the surgical time in a femtolaser assisted cataract surgery.

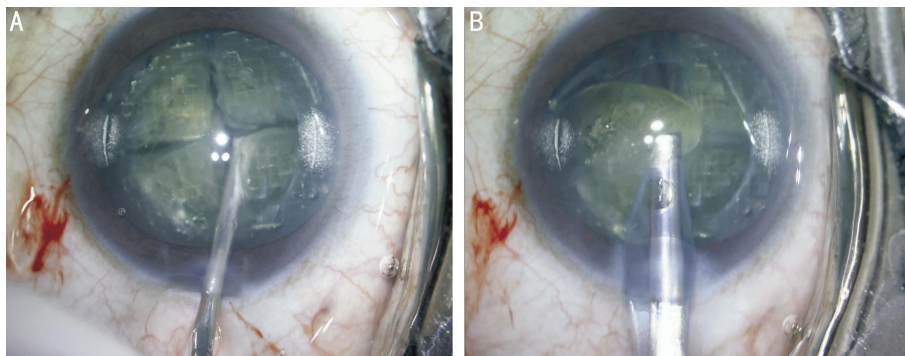
## METHODS

**Surgical Technique** The technique is ideal in nuclear cataracts upto nucleus opalescence grade 3 (NO 3) as graded with the lens opacities classification system III (LOCS III)<sup>[15]</sup> or grades 1 to 2 with clinical grading. In our setting, it is performed using the Catalys femtosecond laser platform (Optimedica, Abbott Medical Optics, Version 3.0) with a pulse rate of upto 120 kHz, although any of the currently available femto laser systems which offer nuclear fragmentation in grid pattern and lens softening may be used. The laser uses a liquid optics patient interface for gentle docking and real time optical coherence tomography (OCT) imaging system for procedural planning and monitoring. A capsulotomy of desired diameter and a lens fragmentation pattern are selected using the graphic user interface screen. Although the number of segments (4, 6 or 8) as well as the degree of lens softening may be varied depending upon the lens grade, we prefer 4 segment fragmentation with lens softening in a grid pattern for all our cases. A safety zone from anterior and posterior capsule (typically 500 µm) is applied by the imaging platform and visualized on the OCT guidance for approval by the surgeon before the laser is applied.

Eye is docked to the optical system *via* the patient interface to ensure stable positioning of the dissection pattern following which laser is fired. Once all the steps are achieved, patient is undocked and shifted from laser to operating microscope for the completion of the surgery. Phaco emulsification machine used in our setting is Signature system (Abbot Medical Optics, USA). A temporal 2.8 mm clear corneal incision is created using diamond blade. Balanced salt solution is injected into the anterior chamber and under the edge of femto assisted capsulotomy to ensure that the capsulotomy is complete and free floating. Minimal hydrodissection is done and nucleus is gently tapped in the centre to release gas bubbles from behind the lens. At this point, 2% hydroxypropyl methyl cellulose (HPMC) is



**Figure 1 A: Injection of 2% HPMC into 50% depth of femtolaser created vertical groove; B: Separation of vertical groove and division of prefragmented nucleus into two heminuclei** HPMC: Hydroxy propyl methyl cellulose.



**Figure 2 A: Well defined separation of nucleus into four quadrants after injection of OVD into horizontal groove; B: Easy emulsification of the separated quadrants of nucleus in the anterior chamber** OVD: Ocular viscosurgical device.

injected into the depth of the central vertical groove first (Figure 1A). The visco cannula is placed at a depth of at least 50% of the groove in the centre. The ocular viscosurgical device (OVD) is injected in a controlled manner until the nucleus is seen separating into two halves (Figure 1B). The two halves are completely separated and this is evidenced by an increase in the red reflex and visibility of the posterior capsule through the groove. The OVD is injected into the horizontal grooves of both heminuclei creating four quadrants (Figure 2A). The separated pieces can then be easily brought into the anterior chamber and emulsified/aspirated using a high flow rate (40-60 mL/min) and high vacuum setting (400-600 mm Hg; Figure 2B). Cortical aspiration with a coaxial irrigation/aspiration probe and foldable intraocular lens implantation can be achieved through the main wound, thus accomplishing the entire surgery without making a side port and using a second instrument.

#### DISCUSSION

Ultrasound phacoemulsification carries risk of corneal injury possibly due to long duration of ultrasound exposure, mechanical manipulation and injury caused by heat and fragmenting lens [16]. Increasing the ultrasound time and energy has also been shown to be directly proportional to cell injury [17,18]. Femtolasers have shown improved safety and decreased complications with consideration to a reduction in ultrasound energy and instrumentation. Overall outcomes and obvious benefits reported in various studies, seem to justify

this technology although studies focusing on techniques of nucleus management per se are limited. Most of the described techniques involve creation of a second port and use of various instruments through this port for separation of prefragmented nucleus. Although no significant risks or complications have been reported with the standard method, our technique of visco chop appears to further enhance the safety and potentially prevent unforeseen complications in a femtolaser assisted cataract surgery.

Viscodissection with low viscosity dispersive OVDs has been described in special situations such as posterior polar cataracts and zonular weakness in pseudoexfoliation syndrome in order to support and stabilize the capsule, decrease zonular stress and assist in peeling cortex off the capsule. It is also been suggested in routine cataract surgery to provide additional safety and decrease the rate of posterior capsular rupture<sup>[19]</sup>.

Similarly, for nuclear separation in femtolaser surgery, a low viscosity dispersive OVD such as 2% HPMC is ideal due to better dissection of spaces, thus achieving a well defined cleavage of grooves and complete separation of prefragmented nucleus. On the other hand, high viscosity OVDs, such as hyaluronic acid derivatives do not dissect spaces well and are injected as a bolus [20]. Also, their use for nucleus separation with this technique may not be safe as the bolus may get trapped between the nucleus and posterior capsule leading to increase in pressure inside the nucleus,

potentially increasing the risk of a posterior capsule rupture. In our experience, this technique works well for nuclear cataracts with LOCS nucleus opalescence grades upto 3. All steps of surgery can be performed through a single main port without creating a side port and using a second instrument. This potentially minimizes fluctuations in the anterior chamber due to wound leak and intraoperative manipulation, which in turn may improve safety.

Sometimes creation of a side port may interfere with femto arcuate incisions for astigmatic correction and the incision site may need to be shifted or created manually with a blade. With a single port surgery, this situation can be avoided. It also reduces surgical time and potentially causes less endothelial cell loss since surgery is faster with less manipulation and chances of instruments touching endothelium are minimal. It is advantageous especially in softer cataracts since the cleavage of quadrants is well defined and there is negligible risk of cheesewiring of nuclear fragments compared to when two instruments are used. Also it is more gentle on the posterior capsule due to minimal manipulation. The technique is easy to perform with good reproducibility and does not involve a steep learning curve for a surgeon who is converting to femtolaser technology. These benefits in turn may further improve safety and efficacy in femtolaser assisted surgery.

What was known: femtoassisted cataract surgery involves creation of a side port and use of a second instrument for separation of prefragmented nucleus and phacoemulsification of the nuclear fragments.

What this paper adds: it is possible to separate the prefragmented nucleus in soft cataracts using a low viscosity dispersive OVD in a single port, single hand technique potentially enhancing the safety in a femtolaser assisted cataract surgery. It is an easy to perform and technically less demanding with no added risks or disadvantages.

#### ACKNOWLEDGEMENTS

**Conflicts of Interest:** Ganesh S, None; Brar S, None.

#### REFERENCES

- 1 Nagy Z, Takacs A, Filkorn T, Sarayba M. Initial clinical evaluation of an intraocular femtosecond laser in cataract surgery. *J Refract Surg* 2009;25(12):1053-1060
- 2 Abell RG, Kerr NM, Vote BJ. Femtosecond laser-assisted cataract surgery compared with conventional cataract surgery. *Clin Experiment Ophthalmol* 2013; 41(5):455-462
- 3 Roberts TV, Lawless M, Chan CC, Jacobs M, Ng D, Bali SJ, Hodge C, Sutton G. Femtosecond laser cataract surgery: technology and clinical practice. *Clin Experiment Ophthalmol* 2013;41(2):180-186
- 4 Nagy ZZ, Mastropasqua L, Knorz MC. The use of femtosecond lasers in

- cataract surgery: review of the published results with the LenSx system. *J Refract Surg* 2014;30(11):730-740
- 5 Reddy KP, Kandulla J, Auffarth GU. Effectiveness and safety of femtosecond laser-assisted lens fragmentation and anterior capsulotomy versus the manual technique in cataract surgery. *J Cataract Refract Surg* 2013;39(9):1297-1306
- 6 Conrad-Hengerer I, Hengerer FH, Shultz T, Dick HB. Effect of femtosecond laser fragmentation of the nucleus with different softening grid sizes on effective phaco time in cataract surgery. *J Cataract Refract Surg* 2012;38(11):1888-1894
- 7 Abell RG, Kerr NM, Vote BJ. Toward zero effective phacoemulsification time using femtosecond laser pretreatment. *Ophthalmology* 2013;120(5):942-948
- 8 Kranitz K, Takacs A, Mihaltz K, Kovacs I, Knorz MC, Nagy ZZ. Femtosecond laser capsulotomy and manual continuous curvilinear capsulorhexis parameters and their effects on intraocular lens centration. *J Refract Surg* 2011;27(8):558-563
- 9 Palanker D, Blumenkranz MS, Andersen D, et al Femtosecond laser-assisted cataract surgery with integrated optical coherence tomography. *Sci Trans Med* 2010;2(58):58ra85
- 10 He L, Sheehy K, Culbertson W. Femtosecond laser-assisted cataract surgery. *Curr Opin Ophthalmol* 2011;22(1):43-52
- 11 Takács AI, Kovács I, Miháltz K, Filkorn T, Knorz MC, Nagy ZZ. Central corneal volume and endothelial cell count following femtosecond laser-assisted refractive cataract surgery compared to conventional phacoemulsification. *J Refract Surg* 2012;28(6):387-391
- 12 Mastropasqua L, Toto L, Mastropasqua A, Vecchiarino L, Mastropasqua R, Pedrotti E, Di Nicola M. Femtosecond laser versus manual clear corneal incision in cataract surgery. *J Refract Surg* 2014;30(1):27-33
- 13 Abell RG, Kerr NM, Howie AR, Mustaffa Kamal MA, Allen PL, Vote BJ. Effect of femtosecond laser-assisted cataract surgery on the corneal endothelium. *J Cataract Refract Surg* 2014;40(11):1777-1783
- 14 Donaldson KE, Braga-Mele R, Cabot F, et al Femtosecond laser-assisted cataract surgery. *J Cataract Refract Surg* 2013;39(11):1753-1763
- 15 Chylack LT Jr, Wolfe JK, Singer DM, Leske MC, Bullimore MA, Bailey IL, Friend J, McCarthy D, Wu SY. The Lens Opacities Classification System III. The Longitudinal Study of Cataract Study Group. *Arch Ophthalmol* 1993;111(6):831-836
- 16 Moshirfar M, Churgin DS, Hsu M. Femtosecond laser-assisted cataract surgery: a current review. *Middle East Afr J Ophthalmol* 2011;18(4):285-291
- 17 Shin YJ, Nishi Y, Engler C, Kang J, Hashmi S, Jun AS, Gehlbach PL, Chuck RS. The effect of phacoemulsification energy on the redox state of cultured human corneal endothelial cells. *Arch Ophthalmol* 2009;127(4):435-441
- 18 Murano N, Ishizaki M, Sato S, Fukuda Y, Takahashi H. Corneal endothelial cell damage by free radicals associated with ultrasound oscillation. *Arch Ophthalmol* 2008;126(6):816-821
- 19 Arshinoff SA, Carbonneau M. Using OVDs for glaucoma surgery. *J Emmetropia* 2013;4:161-169
- 20 Higashide T, Sugiyama K. Use of viscoelastic substance in ophthalmic surgery- focus on sodium hyaluronate. *Clin Ophthalmol* 2008;2(1):21-30