

Extensive full-thickness eyelid reconstruction with rotation flaps through "subcutaneous tunnel" and palatal mucosal grafts

Jian-Xia Cheng, Lan Zuo, Xin-Yu Huang, Ji-Zhe Cui, Shuai Wu, Yuan-Yuan Du

Department of Ocular Plastic Surgery, the Second Hospital of Jilin University, Changchun 130033, Jilin Province, China

Correspondence to: Yuan-Yuan Du. Department of Ocular Plastic Surgery, the Second Hospital of Jilin University, Changchun 130033, Yatai Street No.4026, Jilin Province, China. 18686623812@163.com

Received: 2014-12-05

Accepted: 2015-03-19

DOI:10.3980/j.issn.2222-3959.2015.04.27

Cheng JX , Zuo L, Huang XY, Cui JZ, Wu S, Du YY. Extensive full-thickness eyelid reconstruction with rotation flaps through "subcutaneous tunnel" and palatal mucosal grafts. *Int J Ophthalmol* 2015;8(4):794-799

Abstract

• **AIM:** To reconstruct the extensive full-thickness defects of eyelids is a challenge for the plastic surgeon because of their complex anatomy and special functions. This article presents and discusses an improved surgical technique in which the orbicularis oculi myocutaneous flap is rotated through a "subcutaneous tunnel" in conjunction with a palatal mucosal graft employed for lining.

• **METHODS:** Data from 22 eyes with extensive full-thickness eyelid defects from various causes between 2009 and 2013 were analyzed in this study. After the different layers of eyelid were separated completely, a temporally based orbicularis oculi myocutaneous flap was designed following fishtail lines and was mobilized, leaving the base of the pedicle intact with a submuscular tissue attachment. The flap was then rotated through a "subcutaneous tunnel" to the defect, and the donor site was closed primarily. Posterior lamellar reconstruction was performed with a mucosal graft harvested from the hard palate.

• **RESULTS:** All the flaps were survived without any healing problems. There was no corneal irritation, flap contraction, or significant donor-site morbidity in the follow-up period. The incision scars were almost invisible. The defects were repaired completely, and the evaluations showed satisfactory function and appearance.

• **CONCLUSION:** This technique is an improved single-stage operation and can be applied to repair large, full-thickness eyelid defects from various causes. With our method, the functional and aesthetic results can be obtained in either the upper or lower eyelids.

• **KEYWORDS:** full-thickness eyelid defects; orbicularis oculi myocutaneous flap; subcutaneous tunnel; hard palate mucosa

INTRODUCTION

Eye lids are of paramount importance for the protection of eyeball. The full-thickness eyelid defects have been noted to cause corneal irritation, exposure keratopathy, ulceration and even vision loss. Furthermore, aesthetic problems related to defects often occur at the same time. The goals of eyelid reconstruction are to maintain the function of ocular surface and reproduce the color and texture of the eyelid, following the aesthetic subunit with minimal sacrifice.

Full-thickness defects that exceed 25% of the eyelid's width cannot be directly closed [1]. This means that a skillful operation should be used to repair the defective anterior and posterior lamella of eyelid simultaneously. According to previously reports, several types of autogenous grafts have already been used for repairing the posterior lamella [2-4], including labial mucosa [5], hard palate mucoperiosteum [6,7-9], auricular [8,10-13] and nasoseptal [14] cartilage, *etc*. The labial mucosa is too weak to support the lower eyelid and shrinks substantially during the postoperative period [15]. Auricular or nasoseptal cartilage grafts have sometimes been used, but these are too thick and too stiff to achieve appropriate contact between the eyelid and eyeball [7,16,17]. As for the reconstruction of anterior lamella, some traditional techniques have been reported, as follows: Z-plasty [18], the V-Y advancement flap [9,19], the Cutler-Beard technique [20] and all kinds of pedicled flaps. However, each technique has its own drawbacks. Such as large upper eyelid defects can be reconstructed using V-Y glabellar and midline forehead flaps [21], but the skin texture is thicker and hardly matches that of the upper eyelid. The Cutler-Beard technique has been criticized for tending to shrink and form cicatricial entropion of the reconstructed lid [22,23] not to mention secondary eyelid destroy. The flap that is based on the lateral canthal area and advanced nasally with a V-Y closure is an

effective method to reconstruct lower eyelid. But it is not useful for extensive lower eyelid defect, let alone the upper eyelid defect. As for the reconstruction of lower eyelid with a laterally based orbicularis oculi myocutaneous flap from the upper eyelid, the skin of upper eyelid is too thin and soft to support the lower eyelid, not to mention the destroyed upper eyelid amounts to secondary disfigurement. A supraorbital Fricke flap may result in an up-drawn brow, in addition to the thick skin it provides^[24]. Free flaps have been considered as an option^[12], but contraction leading to depressed areas and color mismatch is among the well-known drawbacks of these skin grafts. Additionally, they do not supply enough blood for the mucosal lining of the palate.

Taking both therapeutic and aesthetic effects into consideration, we present a modified surgical procedure that is using a temporal orbicularis oculi myocutaneous rotation flap in conjunction with a hard palate graft for lining to correct extensive full-thickness eyelid defects. It is worth mentioning that the "cat ear" phenomenon at the pedicle position will be avoided by rotating the flap through "subcutaneous tunnel" skillfully. Furthermore it is a single-stage operation and the shrink of grafts can be controlled effectively. As a result, the reconstruction not only demonstrates a close match to the neighbour skin, but follows a normal eyelid function.

In this paper, we present our eyelid reconstructed technique mentioned above. The outcomes of applying the technique on 22 patients are summarized, including the advantages and possible complications.

SUBJECTS AND METHODS

Ethics Statement This retrospective, interventional, nonrandomized observational study was approved by the local ethics committee (The Second Hospital of Jilin University Ethics Committee) and followed the regulations of good clinical practice (GCP). After a thorough explanation of the nature of the study, all patients agreed to participate and gave their written informed consents to participate prior to study entry.

Indications Twenty-two patients who were presented to the Second Hospital of Jilin University during January 2009 to December 2013 with extensive eyelid defects were subjected to the surgery. The choice criterion of our cases was extensive full-thickness eyelid defect that was affected more than three-quarters width of upper or lower eyelids. These patients included 16 males and 6 females with an age range of 3 to 69 years old and with an average age of 32 years old. The causes of eyelid defects were as follows: tumor excisions in 14 cases, severe eyelid defects after traffic-accident injuries in 7 cases, and a dog bite in the single case of a three-year-old boy. In all cases, the patients were subjected to immediate reconstruction (primary repair)

after injury or excision. Among these patients, 4 cases had developed reconstruction on the upper eyelids and 17 cases on the lower eyelids, the most serious case was involved in both upper and lower eyelid. Patients were subjected to follow up for 3-12mo after surgery.

Surgical Technique All operations were performed under general anesthesia. In the case of malignant tumors, complete excision of the lesion was performed first, until the surgical margin was confirmed to be disease-free pathologically. In injury cases, the necrotic tissues were excised, and a full-thickness defect was created until the fresh wound was thoroughly exposed.

After confirmed the size of defect, a free hard palate mucosal graft avoiding the periosteum was harvested from the hard palate. The graft was approximately 10% longer than the defect in the vertical direction to allow for postoperative shrinkage. The defect of the donor site was pressure-banded with iodoform gauze to stop the bleeding. Then, the graft was cleaned and dipped in a 1:2000 IU gentamicin saline solution for 15min. After removed the adipose tissue, the graft was pruned according to the shape of the defect. Then, the palatal mucosal graft was sutured to the remaining tarsal tissue and conjunctiva. Meticulous attention was paid to obtain the correct graft alignment and to avoid the exposure of sutures and knots on the conjunctival surface. In the cases of upper eyelid defects, the graft was also fixed to the stump of levator aponeurosis to avoid postoperative ptosis. In the cases of total lower eyelid defects, we sutured the graft to the internal canthus nasal bone periosteum and external canthal orbital bone periosteum to place tension of inner eyelid.

According to the defect area of eyelid, we designed a rotation flap in the temporal region (Figure 1A).

The defected area of eyelid was represented as a red shadow. The donor flap area was represented as a blue shadow, which was not only designed symmetrically with red shadow, but image by inversion. That was to say, the donor flap was designed at temporal skin over fissurae palpebrae level when the defect was located at lower eyelid. On the contrary, the donor flap was designed below the fissurae palpebrae level when the defect was located at upper eyelid. In order to conceal the scar of the donor site, the donor flap should be designed along fishtail lines. The "subcutaneous tunnel" that was located at the edge of the lateral orbital bone was under the broken line between the red and blue shadows. It was usually 15-20 mm width and 1.5 mm length so that the loose-bodied pedicle of rotation flap could be turned round inside. Next, the temporal incision was made along the premarked real and broken line. The flap was liberated above the muscular plane until the position of "tunnel". From the edge of the lateral orbital bone, dissection was performed in the submuscular plane. The width of the

Eyelid reconstruction with rotation flaps pass tunnel

muscular pedicle was almost the same as that of the skin flap. Careful dissection was very important to keep the branches of vessels and the facial nerve from injury. After complete isolation, the flap was rotated 120° -180° (Figure 1B) and covered on the palatal mucosal graft to repair the defect of anterior lamella. After the confirmation of tension-free transposition, the flap was sutured to the margin of defect in layers. Finally, the palatal mucosal graft and the rotation flap were sutured with their corresponding palpebral margins. The incision of donor site and "tunnel" was closed primarily (Figure 1C). It was important to note that the lacrimal duct should be repaired with artificial nasolacrimal duct in the second procedure if the defect involved lacrimal canaliculi. The operation area was bandaged properly for 5-7d. The sutures were removed in about 1wk, but the marginal position was not unstitched until 2wk after surgery. The symphysic fissurae palpebral was cut apart 3-6mo after operation.

RESULTS

During the 3-12mo follow-up period, the survival rate of flaps was 100%. In all cases, functional recovery was satisfactory, and corneal protection was obtained. Neither pain nor corneal irritation was reported in the postoperative cases. All patients could open and close their eyelids freely. The texture and color of reconstructed eyelids matched the surrounding skin. The donor site scar healed well and was inconspicuous in all cases. Furthermore, no recurrence was noted in any patient who presented with carcinoma. The details of three cases are presented.

Case 1 A 48-year-old man presented with a severe infection of the left lower eyelid one week after a traffic accident (Figure 2A). After the infected and necrotic tissues were debrided (Figure 2B), a palatal mucosal graft was harvested from the hard palate, avoiding the periosteum (Figure 2C). The defect of the donor site was pressure-banded with iodoform gauze to stop the bleeding (Figure 2D). Then, a flap based on the orbicularis oculi muscle was designed from a point 1 cm lateral to the lateral canthus, along the direction of temporal fishtail lines. After complete isolation, the flap was rotated 120° through the "subcutaneous tunnel" and covered the palatal mucosal graft to repair the anterior layer of the affected eyelid (Figure 2E). The palatal mucosal graft and the rotation flap were sutured with their corresponding palpebral margins. The donor site of the flap was closed primarily (Figure 2F). The results were satisfactory at 7d (Figure 2G) and 3mo (Figure 2H) after the split operation.

Case 2 A 52-year-old man presented with extensive basal-cell carcinoma of the lower eyelid that needed a total resection of the lower lid (Figure 3A). In this patient, we performed a reconstruction in which an orbicularis oculi myocutaneous flap was rotated through a "subcutaneous tunnel" in conjunction with a palatal mucosal graft for lining

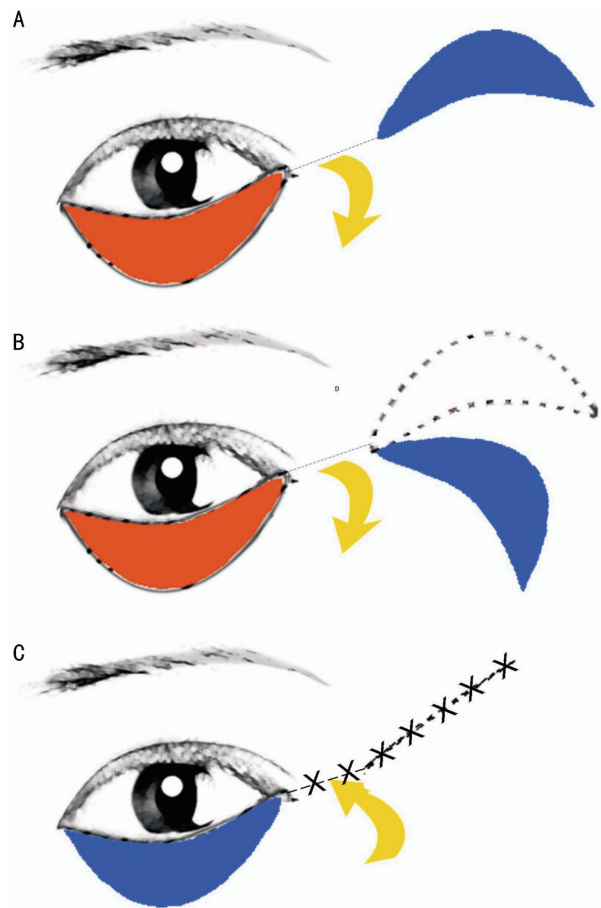


Figure 1 The diagram of operating procedure.

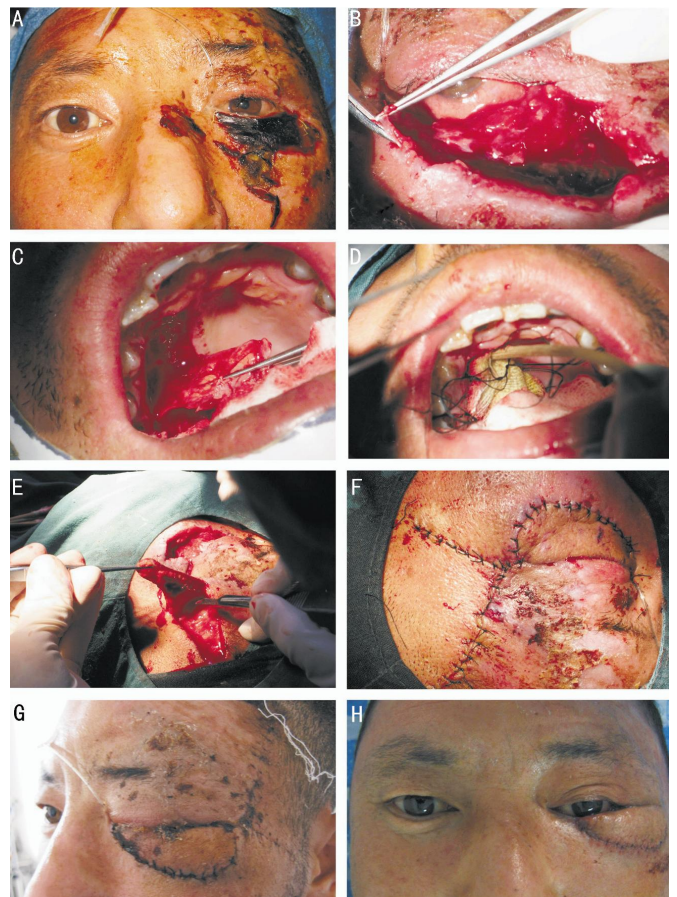


Figure 2 The eyelid reconstruction of a severe infection and defect of left lower eyelid of a 48-year-old man.

(Figure 3B, 3C). Then, the tarso and skin palpebral fissure was sutured more than six months to prevent contraction of the palatal mucosal graft and flap (Figure 3D). The aesthetic and functional outcomes were very good 6mo after surgery (Figure 3E). The donor site healed well, without conspicuous scarring (Figure 3F).

Case 3 Although our technique was predominantly used for full-thickness defects of the lower or upper eyelid, a 61-year-old man with a full-thickness defect involving both the upper and lower eyelids due to a traffic accident (Figure 4A, 4B, 4C) also underwent surgery successfully with the same technique. Despite a serious infection of the wounded eyelid, the reconstructed upper and lower eyelids survived one week after the operation (Figure 4D). Six months after the surgery, he could open and close his eyelids completely (Figure 4E, 4F). No complications were noted (Figure 4G), and an aesthetic and functional final result was achieved.

DISCUSSION

Indications for eyelid reconstruction include the resection of tumors, the correction of congenital or traumatic colobomas, and scar-tissue retractions. A skillful operation should be used to repair the defective anterior and posterior lamella of eyelid simultaneously when the full-thickness defects exceed 25% of the eyelid's width. Numerous techniques have been proposed for full-thickness eyelid reconstruction [25-33]. The ideal results of reconstruction in eyelid surgery should be a movable eyelid, perfect corneal protection, good aesthetic quality, and acceptable sequelae at the donor site.

The techniques of posterior lamella reconstruction have mentioned above, such as labial mucosa, hard palate mucos, hard palate mucoperiosteum, and auricular and nasoseptal cartilage. However, there are still some issues associated with eye lids reconstruction. In 1985, the hard palate mucoperiosteal graft was first introduced by Dr. Siegel [34]. Because of the dual functions of structural support and conjunctival lining, this technique has always been a concern of ophthalmologists, and the clinical applications have become increasingly developed and mature [28,8]. Furthermore, the groups of Ito *et al* [8] and Weinberg *et al* [35] further confirmed the feasibility of substituting tarsoconjunctival organizations with hard palate mucosa in a histological perspective. The results showed that hard palate mucoperiosteal grafts bear a close resemblance histologically to the tarsoconjunctiva. We prefer using hard palate mucosal grafts to reconstruct the defected posterior lamella. As a suitable replacement of eyelid, it has several advantages, as follows: 1) because the histologic composition of graft bears a close resemblance to that of the tarsoconjunctiva [8,35], the large hard palate provides both a conjunctival lining and structural support. It has intrinsic stiffness and yet is pliable [2]; 2) minimal shrinkage [15,34,10,17] of palatal mucosal grafts prevents the reconstructed eyelid from sagging [3]; 3)

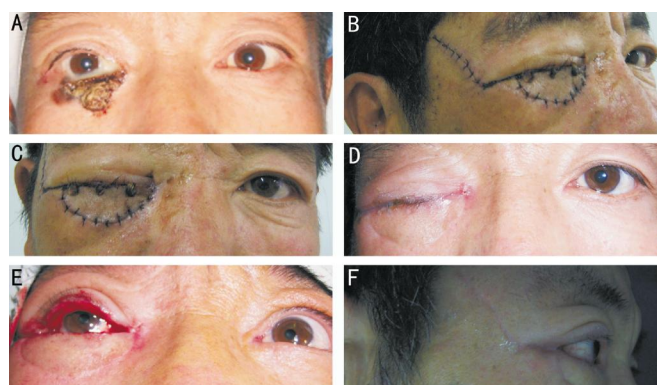


Figure 3 The eyelid reconstruction of a extensive basal-cell carcinoma of right lower eyelid of a 52-year-old man.

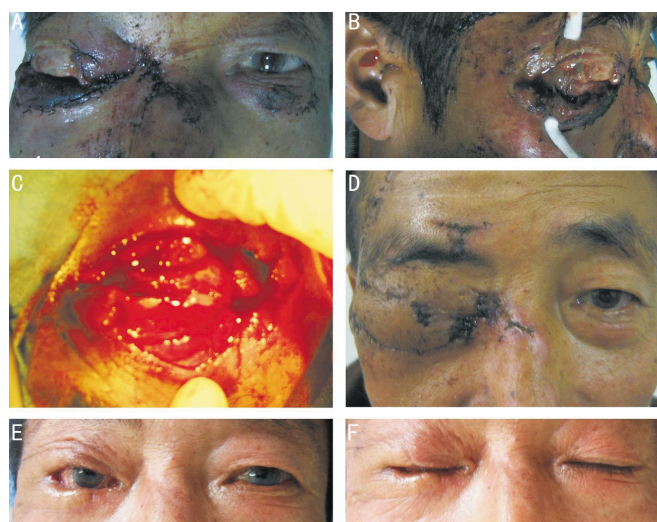

Figure 4 The eyelid reconstruction of a full-thickness defect involving both the upper and lower eyelids of a 61-year-old man.

there is sufficient donor area in the hard palate. It offers spontaneous healing. There is no long-term donor-site morbidity, which is another advantage of the hard palate graft [4]; 4) these grafts showed complete removal, and there were no complications, such as ectropion, entropion, or blepharoptosis.

As for the reconstruction of anterior lamella, a number of procedures are available mentioned above, such as: Z-plasty [18], the V-Y advancement flap [9,19], the Cutler-Beard technique [20] and all kinds of pedicled flaps. Because unsuitable for extensive eyelid defect and the potential for leaving unsightly scars, these techniques come in their different drawbacks. Such as the problem of skin texture, donor amount, secondary disfigurement and blood circulation problems. Our technique is designing a orbicularis oculi myocutaneous flap rotated through a "subcutaneous tunnel" to reconstruct the anterior lamella of eyelid (Figure 1A). In comparison with other methods, this procedure is technically easy and can obtain good aesthetic results with minimal invasion. Their specific advantages are as follows: 1) the first thing to be sure of is the original technique of "subcutaneous tunnel". By

this creative method, we can not only retain the generous pedicle, but also avoid a bloated appearance at the pedicle position, known as "cat ear", which is always required for the secondary reparation; 2) due to its similar color and texture to the eyelid, the temporal rotation flap results in optimal and aesthetic results; 3) this flap uses the rich blood supply in the lateral orbital region, which consists of the zygomaticofacial perforator, the zygomaticotemporal perforator, the zygomatico-orbital artery, and the perforators of the transverse facial artery [36]. Because of its rich arterial network, the rotation flap and its undergraft that is transplanted from palatal mucosal can be survived by the generous submuscular pedicle; 4) this surgical technique has no serious side effects in terms of the function or appearance at the donor site. The temporal skin and subcutaneous tissue are loose, and the donor-site defect can be sutured directly without needing to be repaired using a free skin graft. Furthermore, we can design the flap along the direction of the fishtail lines according to the shape of defect, leaving almost invisible donor-site scars.

With this technique, the valuations of all cases showed satisfactory function and appearance. However, this result requires some key technological points. Our experiences are summarized as follows: 1) in the operation, the orbital branches of the arterial arcade and the facial nerve should be carefully protected, so the key to performing this operation is a thorough knowledge of eyelid anatomy; 2) the lateral pedicle of the flap should be widened enough to ensure the blood supply of rotation flap and its undergraft; 3) attention should be paid to the repair of levator muscle of the upper eyelid and the internal and external canthal ligaments of the lower eyelid; 4) a palpebral fissure permanent suture is not only conducive to the fixation of the transfer flap and its lining, but also helping to prevent postoperative contraction; 5) for the prevention of ischemic necrosis of flap, postoperative care should be taken, such as avoiding the compression at the peduncular position when we compress the flap with pressure-bandaging.

Although successful, our method has some drawbacks. Firstly, our procedures require the occlusion of visual axis for weeks to months, increasing recovery time and posing difficulties for patients who are monocular or who are young enough to be at risk for deprivation amblyopia [37]. To avoid this drawback, we suggest to perform partial "tarsorrhaphy" leaving the visual axis open in special cases. Another problem is the healing of the large hard palate donor site, especially involves the risk of developing maxillary hypoplasia in children. However, this drawback was overcome by avoiding periosteum when harvesting mucosa from the hard palate. Because the palatal mucosal grafts have the drawback of being thick in comparison with the

conjunctiva tarsal plate, thinning of the graft should be done, if necessary, to achieve a smooth transition, as long as supportive strength is not compromised.

In conclusion, our procedure is technically easy, and the defective skin, tarsal plate and conjunctiva can be repaired at the same time. Because of the "subcutaneous tunnel" technique, the cosmetic results can be obtained. Therefore, the good morphologic and dynamic reconstruction can be achieved using our method, it has thus become our favored technique for full-thickness eyelid reconstruction.

ACKNOWLEDGEMENTS

We gratefully acknowledge the valuable help by Dr. Hui Zhang, Ph.D.

Foundation: Supported by Jilin Province Science and Technology Development Plan Project (No.20150414032GH)

Conflicts of Interest: Cheng JX, None; Zuo L, None; Huang XY, None; Cui JZ, None; Wu S, None; Du YY, None.

REFERENCES

- 1 Madge SN, Khine AA, Thaller VT, Davis G, Malhotra R, McNab A, O'Donnell B, Selva D. Globe-sparing surgery for medial canthal basal cell carcinoma with anterior orbital invasion. *Ophthalmology* 2010;117 (11): 2222-2228
- 2 Ael-N AM. The use of composite lid graft and the adjacent temporal myocutaneous tissue with orbicularis muscle mobilization for full-thickness total and subtotal upper lid reconstruction. *Orbit (Amsterdam, Netherlands)* 2005;24(2): 87-93
- 3 Lucci LM, Fonseca Junior NL, Sugano DM, Silverio J. Tarsal switch levator for mitochondrial myogenic ptosis. *Arq Bras Oftalmol* 2009;72(2): 159-163
- 4 Akdag F, van den Bosch W, Ganteris E, Paridaens D. "Sandwich block" for eyelid reconstruction. *Orbit* 2010;29(2):110-113
- 5 Li DM, Qin Y, Chen T, Zhao Y. Use of periocular superficial musculo-aponeurotic system flap and hard palate mucosal graft reconstruction of full-thickness eyelid defects. *Zhonghua Yan Ke Za Zhi* 2007;43(12):1064-1068
- 6 Dai YH, Yue XL, Wang JF. Reconstruction of full-thickness eyelid defects with hard palate mucosa grafting combined with orbicularis musclocutaneous flap transfer. *Int Eye Sci* 2012;12(6):1185-1187
- 7 Dong LL, Cao GP, Yu XQ. The immediate reconstruction on the large areas eyelid defect after the operation of malignant tumors of eyelid. *Int Eye Sci* 2013;13(5):977-979
- 8 Ito R, Fujiwara M, Nagasako R. Hard palate mucoperiosteal graft for posterior lamellar reconstruction of the upper eyelid: histologic rationale. *J Craniofac Surg* 2007;8(3):684-690
- 9 Acikel C, Celikoz B, Yildiz TF. Y-shape hard palate mucoperiosteal graft and V-Y advancement flap in the reconstruction of a combined defect involving lateral canthus and upper and lower eyelids. *Ann Plast Surg* 2004;52(13): 97-101
- 10 Toft PB. Myocutaneous pedicle flap combined with a free skin graft for upper eyelid reconstruction. *Orbit* 2010;29(1):21-24
- 11 Gu J, Wang Z, Sun M, Yuan J, Chen J. Posterior lamellar eyelid reconstruction with acellular dermis allograft in severe cicatricial entropion. *Ann Plast Surg* 2009;62(3):268-274

- 12 Paridaens D, van den Bosch WA. Orbicularis muscle advancement flap combined with free posterior and anterior lamellar grafts: a 1-stage sandwich technique for eyelid reconstruction. *Ophthalmology* 2008;115(1):189-194
- 13 Hashikawa K, Tahara S, Nakahara M, Sanno T, Hanaqaki H, Tsuji Y, Terashi H. Total lower lid support with auricular cartilage graft. *Plast Reconstr Surg* 2005;115(3):880-884
- 14 Harris MA, Vidor IA, Sivak-Calcott J. Amniotic membrane in medial canthal reconstruction. *Ophthal Plast Reconstr Surg* 2011;27(2):135-136
- 15 Fujiwara M. Upper eyelid reconstruction with a hard palate mucosa-lined bipediced myocutaneous flap. *J Craniofac Surg* 2006;17 (5):1011-1015
- 16 Moon JW, Choung HK, Khwarg SI. Correction of lower lid retraction combined with entropion using an ear cartilage graft in the anophthalmic socket. *Korean J Ophthalmol* 2005; 19(3):161-167
- 17 Emesz M, Krall EM, Rasp M, Bauer FM, Grabner G, Arlt EM. Transplants from the hard palate: Method for mucosal graft reconstruction of the upper eyelid. *Ophthalmologic* 2014;111(9):853-861
- 18 Khan JA, Garden VS. Combined flap repair of moderate lower eyelid defects. *Ophthal Plast Reconstr Surg* 2002;18(3):202-204
- 19 Rubino C, Farace F. A large lower eyelid reconstruction: nasojugal flaps plus V-Y advancement flap. *Acta Chir Plast* 2006;48(1):3-4
- 20 Fischer T, Noever G, Langer M, Kammer E. Experience in upper eyelid reconstruction with the Cutler-Beard technique. *Ann Plast Surg* 2001;47 (3):338-342
- 21 Brusati R, Colletti G, Redaelli V. Upper eyelid reconstruction with forehead galeal flap. *J Plast Reconstr Aesthet Surg* 2009;62(7):901-905
- 22 Holloman EL, Carter KD. Modification of the Cuter-Beard procedure using donor achilles tendon for upper eyelid reconstruction. *Ophthal Plast Reconstr Surg* 2005;21(4):267-270
- 23 Yoon MK, McCulley TJ. Secondary tarsoconjunctival graft: a modification to the Cuter-Beard procedure. *Ophthal Plast Reconstr Surg* 2013;29(3):227-230
- 24 Kim SW, Han HH, Junq SN. Orbicularis oculi myocutaneous island flap for upper eyelid reconstruction. *J Craniofac Surg* 2012;23(3):746-748
- 25 Garces JR, Guedes A, Alegre M, Alomar A. Double mucosal and myocutaneous island flap: a one-stage reconstruction for full-thickness lower eyelid defect. *Dermatol Surg* 2009;35(5):779-785
- 26 Pushpoth S, Tambe K, Sandramouli S. The use of AlloDerm in the reconstruction of full-thickness eyelid defects. *Orbit (Amsterdam, Netherlands)* 2008;27(5):337-340
- 27 Parodi PC, Faini G, De Biasio F, Rampino Cordaro E, Guameri GF, Miani F. Full-thickness lower eyelid reconstruction with a conchal chondro-perichondral graft and local coverage with Mio-cutaneous flaps--our divisional experience. *J Oral Maxillofac Surg* 2008;66 (9):1826-1832
- 28 Miyamoto J, Nakajima T, Nagasao T, Konno E, Okabe K, Tanaka T, Fujii S, Kobayashi H. Full-thickness reconstruction of the eyelid with rotation flap based on orbicularis oculi muscle and palatal mucosal graft: Long-term results in 12 cases. *J Plast Reconstr Aesthet Surg* 2008;62(11):1389-1394
- 29 Sa Hs, Wook Kl, Kim YD. Reverse modified Hughes procedure for upper eyelid reconstruction. *Ophthal Plast Reconstr Surg* 2010;26 (3):155-160
- 30 Paarlberg JC, van den Bosch WA., Paridaens D. Reconstruction following subtotal full-thickness upper eyelid resection with preservation of the lid margin. *Orbit (Amsterdam, Netherlands)* 2007;26(4):319-321
- 31 Li DM, Qin Y, Chen T, Zhao Y. Use of periocular superficial musculo-aponeurotic system flap and hard palate mucosal graft in reconstruction of full-thickness eyelid defects. *Zhonghua Yan Ke Za Zhi* 2007;43(12):1064-1068
- 32 Rosa J, Casal D, Moniz P. Upper eyelid reconstruction with a horizontal Y-V myotarsocutaneous advancement flap. *J Plast Reconstr Aesthet Surg* 2010;63(12):2013-2017
- 33 Onoda M, Fujikawa M, Koh K. Full-thickness eyelid reconstruction using orbicularis oculi musculocutaneous flap raised from lateral orbital region. *Ann Plast Surg* 2010; 64(3):294-297
- 34 Siegel RJ. Palatal grafts for eyelid reconstruction. *Plast Reconstr Surg* 1985;76(3):411-414
- 35 Weinberg DA, Tham V, Hardin N, Antley C, Cohen AJ, Hunt K, Glasgow BJ, Baylis HI, Shorr N, Goldberg RA. Eyelid mucous membrane grafts: a histologic study of hard palate, nasal turbinate, and buccal mucosal grafts. *Ophthal Plast Reconstr Surg* 2007; 23(3): 211-216
- 36 Bozikov K, Shaw-Dunn J, Soutar DS, Arnez ZM. Arterial anatomy of the lateral orbital and cheek region and arterial supply to the "peri-zygomatic perforator arteries" flap. *Surg Radiol Anat* 2008;30(1):17-22
- 37 Verity DH, Collin JR. Eyelid reconstruction: the state of the art. *Curr Opin Otolaryngol Head Neck Surg* 2004;12(4):344-348