

# Angle parameter changes of phacoemulsification and combined phacotrabeculectomy for acute primary angle closure

Shi-Wei Li, Yan Chen, Qiang Wu, Bin Lu, Wen-Qing Wang, Jian Fang

Department of Ophthalmology, the Sixth People's Hospital Affiliated of Shanghai Jiaotong University, Shanghai 200233, China

Co-first authors: Shi-Wei Li and Yan Chen

Correspondence to: Qiang Wu. Department of Ophthalmology, the Sixth People's Hospital Affiliated of Shanghai Jiaotong University, Shanghai 200233, China. qiang.wu@shsmu.edu.cn

Received: 2013-10-08

Accepted: 2014-12-17

DOI:10.3980/j.issn.2222-3959.2015.04.18

Li SW, Chen Y, Wu Q, Lu B, Wang WQ, Fang J. Angle parameter changes of phacoemulsification and combined phacotrabeculectomy for acute primary angle closure. *Int J Ophthalmol* 2015;8(4):742-747

## Abstract

• **AIM:** To evaluate the difference in angle parameters and clinical outcome following phacoemulsification and combined phacotrabeculectomy in patients with acute primary angle closure (APAC) using ultrasound biomicroscopy (UBM).

• **METHODS:** Patients ( $n=23$ , 31 eyes) were randomized to receive phacoemulsification or combined phacotrabeculectomy ( $n=24$ , 31 eyes). Best-corrected visual acuity (BCVA), intraocular pressure (IOP), the main complications following surgery, and indentation gonioscopy and angle parameters measured using UBM were documented preoperatively and postoperatively.

• **RESULTS:** The improvement in BCVA in the phacoemulsification group was significantly greater than in the combined group ( $P < 0.05$ ). IOP in the phacoemulsification group was slightly higher than in the combined group following 1wk of follow-up ( $P < 0.05$ ), whereas there was no significant difference between the two groups at the latter follow-up ( $P > 0.05$ ). Phacoemulsification alone resulted in a slight increase in the trabecular ciliary processes distance compared with the combined surgery ( $P < 0.05$ ), whereas the other angle parameters showed no significant difference between the groups. Complications in combined group were greater than phacoemulsification only group.

• **CONCLUSION:** Both surgeries effectively opened the drainage angle and deepened the anterior chamber, and IOP was well controlled postoperatively. However, phacoemulsification showed better efficacy in improving visual function and showed reduced complications following surgery.

• **KEYWORDS:** acute primary angle closure; cataract; phacoemulsification; phacotrabeculectomy

## INTRODUCTION

Acute primary angle closure (APAC) is a condition that is especially common in people of East Asian origin and can potentially lead to blindness. The crystalline lens of the eye plays a major role in the pathophysiology of this disease<sup>[1-3]</sup>. With increasing age, the crystalline lens tends to become more opaque and to swell, which makes the lens thicker. Similarly, eyes with APAC tend to show a shallow anterior chamber and a thick, anteriorly positioned lens when compared with normal eyes. Thus, lens extraction may significantly deepen the anterior chamber, widen the drainage angle and control the intraocular pressure (IOP) effectively in patients with APAC<sup>[4-8]</sup>. It has been reported that combined phacotrabeculectomy in patients with glaucoma and a coexisting cataract may release the pupil block and reopen the anterior chamber angle with the result of regaining control of IOP in primary angle-closure glaucoma (PACG)<sup>[9-11]</sup>. To evaluate the safety of surgery and the outcome of phacoemulsification only and combined phacotrabeculectomy, we performed either of these two surgeries in patients with APAC. We analyzed the best-corrected visual acuity (BCVA) and IOP of the patient preoperatively and postoperatively and measured the anterior segment parameters using ultrasound biomicroscopy (UBM). Our results demonstrate that both phacoemulsification only and combined phacotrabeculectomy effectively reduced IOP and reformed the anterior segment but that there were more complications following combined phacotrabeculectomy versus phacoemulsification only.

## SUBJECTS AND METHODS

This study was approved by the Ethics Committee of the Sixth Peoples' Hospital Affiliated of Shanghai Jiaotong University, Shanghai, China. Forty-seven consecutive Chinese patients (62 eyes) with coexisting cataracts and APAC were enrolled from the Department of Ophthalmology, the Sixth Peoples' Hospital Affiliated of Shanghai Jiaotong University. Written informed consent was obtained from all patients. The patients were randomly divided into two groups using a random number table.

APAC was diagnosed based on reported symptoms and clinical signs [1]. The inclusion criteria were a visually significant cataract with visual acuity of less than 20/50 with an IOP of less than 25 mm Hg within 24h of presentation and after commencement of initial medical treatment. The patients with a history of ocular disease that may cause secondary angle closure, such as anterior chamber inflammation, previous ocular surgery, or systemic diseases, such as diabetes mellitus, were excluded from our study. Patients with more than 270 degrees of peripheral anterior synechiae were also excluded. Patients with fused to enroll, and none were lost to follow-up during the course of this study.

**Preoperative Evaluation** All patients underwent a thorough ocular examination including a recording of BCVA, IOPs, slit-lamp biomicroscopy (SuZhou 66 Co. Ltd., China), indentation gonioscopy (Volk Co. Ltd., USA) and the anterior segment parameters including the anterior chamber distance (ACD), the angle opening distance (AOD<sub>500</sub>), the trabecular iris angle (TIA), the angle recess area (ARA), the trabecular ciliary processes distance (TCPD) using UBM (UD-6000, TOMEY Co. Ltd., Japan). Preoperative BCVA ranged from 20/50 to hand movements using Snellen charts. Visual acuity of counting fingers and hand motion were assigned values of 1/200 and 1/400, respectively [12]. All IOPs were recorded using Goldmann applanation tonometry (TX-F Canon Co. Ltd, China) and were measured between 09:00 and 12:00 following topical anesthesia with 2% lidocaine (ALCON Co. Ltd., USA). All cataracts were graded using the Lens Opacities Classification System III (LOCSIII). Angle parameters were detected using ultrasound biomicroscopy at a 50-MHz probe frequency and a 40-60  $\mu$ m resolution ratio. The ultrasound biomicroscopy was set to a 5.0 $\times$ 5.0-mm<sup>2</sup> field of view and 4-5 mm probe depth with 80 decibels of gain, 5 decibels of gain compensation and a 2.24-3.76 mm delay.

**Protocol for Initial Medical Treatment of Patients with Acute Primary Angle-closure Glaucoma** Initial medical treatment of patients with APAC was standardized to the following: intravenous mannitol (20%) at 1-2 g/kg if IOP was greater than 30 mm Hg unless contraindicated due to systemic disease (*e.g.* in the case of renal failure or diabetes, intravenous glycerol fructose was used at 1-2 g/kg) and a second infusion of intravenous mannitol (20%) at 1-2 g/kg at 12h after initiation of treatment if IOP was still not reduced by 20% from the initial IOP. Patients also received oral acetazolamide, 250 mg twice daily, with potassium, 1.2 g; a topical  $\beta$ -blocker (timolol 0.5%) twice daily (BID) or brimonidine BID if  $\beta$ -blockers were contraindicated; topical pilocarpine (2%) once every 10min 4-5 times and then 4 times daily (QID) after IOP was depressed to below 50 mm Hg by intravenous mannitol and topical  $\beta$ -blocker to avoid iris adiphoria because of ischemia; topical steroids were administered twice if there was comorbid serious uveitis.

**Surgical Technique** The surgeries were performed between 5 and 7d after the IOP lowering to enable improved corneal clarity and reduction of intraocular inflammation. Guttate pilocarpine was terminated the day before the operation. Preoperative intravenous mannitol (20%) at 1-2 g/kg was administered at 2h prior to the start of the operation for those subjects with an IOP persistently above 25 mm Hg. All surgeries were performed by the same experienced surgeon (Wu Q) and were then followed-up by an ophthalmologist (Li SW). The pupil was dilated using 0.5% tropicamide drops (Santen, Osaka, Japan) at 30min prior to surgery, and the other eye was treated with a miotic drug to avoid glaucoma attack. Phacoemulsification was performed under topical anesthesia using 2% lidocaine (ALCON Co. Ltd., USA) and/or local infiltration anesthesia. The incision was performed at the 9 o'clock (right eye) or 2 o'clock (left eye) position of the cornea. The chamber was immediately deepened using Viscoat (SA Alcon-Couvreur NV, Rijksweg, Puurs, Belgium). Using continuous curvilinear capsulorhexis, the nucleus was removed using a standard four-quadrant, 'divide and conquer' technique {stop and chop}. An automated irrigation/aspiration apparatus was introduced into the anterior chamber to remove the cortical remnants and to polish the posterior lens capsule. (ACCURUS600DS, ALCON Co. Ltd., USA). The intra IOL was placed in the capsular bag. The pupil was contracted using an injection of 0.01% carbachol (Bausch & Lomb Freda, China). In the case of combined phacotrabeculectomy (phacotrabeculectomy), all surgeries were performed using peribulbar local anesthesia using 2% lidocaine (ALCON Co. Ltd., USA). Ocular compression was performed in every case. A fornix-based conjunctival flap and a half-thickness sclera flap measuring 4  $\times$ 3-mm<sup>2</sup> were fashioned at the 12 o'clock position. A trabeculectomy of 1-2 mm was performed under the same sclero-corneal tunnel using a 15° scalpel and Vannas scissors. A peripheral iridectomy was performed that was large enough to ensure that the iris could not be visualized in the base of the trabeculectomy opening. The sclera tunnel was closed using one 10/0 nylon suture and the conjunctival wound was closed using 8/0 vicryl continuous sutures.

**Post-operative Care and Follow-up** Post-operative medications routinely employed 1% TobraDex eye drops (SA Alcon-Couvreur NV, Rijksweg, Puurs, Belgium) and 0.1% diclofenac sodium drops (Xingqi Pharmaceutical Co. Ltd., Shenyang, Liaoning Province, China) 3 times per day. All drops were terminated following 4 to 6wk of treatment, and steroids were tapered off during the 4 to 6wk. Post-operative evaluation was conducted on day 7 and months 1, 3, and 6. The patients requiring closer follow-up based on their clinical outcome were evaluated monthly or even weekly. On each occasion, the patients were examined fully using slit lamp biomicroscopy, and the following examinations were also performed: 1) BCVA: the patient postoperative BCVA was

measured the same way as pre-operation. 2) IOP: the postoperative IOPs were measured the same way as pre-operation. For the purpose of this study, the surgery was considered to be a "complete success" when IOP was less than 21 mm Hg without antiglaucoma medication and a "qualified success" when IOP was less than 21 mm Hg with antiglaucoma medication. If patients showed an IOP of 21 mm Hg regardless of medications or had progressive glaucomatous atrophy with visual field loss, they were classified as surgical failures. 3) Corneal endothelial cell density was measured using a corneal endothelial cell counter instrument (SP-2000P Topcon Co. Ltd., Japan). 4) Gonioscopy: gonioscopy was performed at 6mo after surgery. 5) UBM biological parameters: angle parameters were detected using UBM the same way as pre-operation. Any surgery complications were noted.

**Statistical Analysis** Data are reported as the mean±SD. All analyses were performed using SPSS software version 13.0. Paired contrast *t*-tests were used for the preoperative and postoperative comparison of corneal endothelial cell density, AOD<sub>500</sub>, TIA and TCPD. Wilcoxon rank sum *t*-tests were employed for the preoperative and postoperative comparisons of ACD, ARA, BCVA, IOP and the number of antiglaucoma medications.  $\chi^2$ -tests were used for comparisons of changes of the anterior chamber and the condition of the iris bombe following surgery. A value of *P*<0.05 was considered to be statistically significant.

**RESULTS**

**Patient Informantions** The gender composition of the 47 patients was: male, 19 patients (28 eyes); female, 28 (34 eyes). The patients' mean age in years was 67.5±9.12. The mean IOP at the patients' initial visit was 26.21±11.59 mm Hg (range 14-60 mm Hg), and the pre-operative IOP (mm Hg) after treatment with antiglaucoma drugs was 19.38±4.43 mm Hg (range 9.8-24.5 mm Hg). The ocular axis length was 21.26±1.43 mm (range 21.21-23.92 mm).

**Comparison of Best-corrected Visual Acuity Between the Two Groups Preoperatively and Postoperatively** In the phacoemulsification only group, the mean BCVA improved at 1wk to 0.81±0.24, at 1mo to 0.83±0.21, at 3mo to 0.85±0.26 and at 6mo to 0.83±0.27, and the postoperative versus preoperative difference was 0.21±0.16 (*P*<0.001). In the phacotrabeculectomy group, the mean BCVA improved at 1wk to 0.62±0.39, at 1mo to 0.68±0.29, at 3mo to 0.64±0.36 and at 6mo to 0.60±0.36, and the postoperative versus preoperative difference was 0.19±0.17 (*P*<0.01). Figure 1 shows change curves of BCVA in the phacoemulsification and combined phacotrabeculectomy (phacotrabeculectomy) groups. The BCVA of the phacoemulsification only group was significantly higher than the phacotrabeculectomy group (*P*< 0.05).

**Comparison of IOP between the Two Groups Preoperatively and Postoperatively** In the

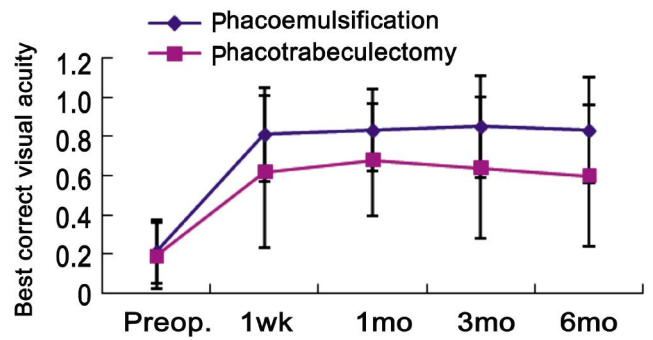


Figure 1 Pre and postoperative BCVA in phacoemulsification group and phacotrabeculectomy group.

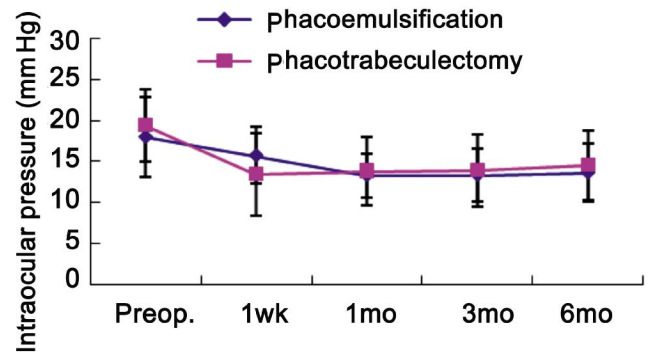


Figure 2 Pre and postoperative IOP (mm Hg) in phacoemulsification group and phacotrabeculectomy group.

phacoemulsification only group, the mean IOPs at 1wk, 1, 3 and 6mo postoperatively were 15.76±3.45 mm Hg, 13.34±2.69 mm Hg, 13.37±3.21 mm Hg and 13.66±3.57 mm Hg, respectively, which were significantly lower than the preoperative value of 18.03±4.89 mm Hg (*P*<0.001). In the phacotrabeculectomy group, the mean IOPs at 1wk, 1, 3 and 6mo postoperatively were 13.48±5.02 mm Hg, 13.85±4.17 mm Hg, 13.95±4.41 mm Hg and 14.51±4.26 mm Hg, respectively, all of which were significantly lower than preoperative values (19.38±4.43 mm Hg; *P*<0.01). At the 1wk follow-up, the IOP in the phacoemulsification only group was slightly higher than the combined phacotrabeculectomy group (*P*<0.05), but there was no significant difference between the preoperative IOP and the latter follow-up in either study group (*P*>0.05). Figure 2 shows change curves of IOP in the phacoemulsification and combined phacotrabeculectomy groups. Rate of "complete success" in the phacoemulsification only group was 48.4% (15 eyes of 31 eyes). Rate of "complete success" in phacotrabeculectomy group was 45.2% (14 eyes of 31 eyes). In the phacoemulsification only group at 6mo after surgery, 1 eye used 3 types of antiglaucoma medication with IOP control to almost 21 mm Hg, 12 eyes used 2 types of antiglaucoma medication with effective IOP control, and 3 eyes used 1 type of antiglaucoma medication with effective IOP control. The mean number of antiglaucoma medications decreased from 2.23±0.59 preoperatively to 0.96±0.65 at 6mo postoperatively (*P*<0.001). In the phacotrabeculectomy group at 6mo after surgery, 1 eye used 3 types of

**Table 1 Comparison of preoperative and postoperative UBM biological parameters in phacoemulsification only group and phacotrabeculectomy group**

Parameters	Phacoemulsificationonly group	Phacotrabeculectomy group	<i>P</i>
Preop. ACD (mm)	1.80±0.72	1.86±0.78	0.669
Postop. ACD (mm)	3.49±0.58	3.37±0.71	0.669
<i>P</i>	0.000	0.000	
Preop. AOD <sub>500</sub> (mm)	0.14±0.15	0.12±0.11	0.566
Postop. AOD <sub>500</sub> (mm)	0.35±0.20	0.26±0.16	0.076
<i>P</i>	0.003	0.002	
Preop. TIA (°)	13.60±15.40	11.59±11.06	0.863
Postop. TIA (°)	29.96±11.94	24.97±11.57	0.060
<i>P</i>	0.002	0.004	
Preop. ARA (mm <sup>2</sup> )	0.07±0.08	0.06±0.07	0.878
Postop. ARA (mm <sup>2</sup> )	0.23±0.17	0.18±0.23	0.268
<i>P</i>	0.003	0.001	
Preop. TCPD (mm)	0.78±0.28	0.78±0.21	0.038
Postop. TCPD (mm)	0.94±0.19	0.81±0.13	0.038
<i>P</i>	0.113	0.779	

antiglaucoma medication with effective IOP control, 10 eyes used 2 types of antiglaucoma medication with effective IOP control, and 4 eyes used 1 type of antiglaucoma medication with effective IOP control. The mean number of antiglaucoma medications decreased from 2.35 ±0.66 preoperatively to 0.73 ±1.00 at 6mo postoperatively (*P*<0.001). The use of antiglaucoma medication in the phacoemulsification only group was slightly more than in the phacotrabeculectomy group (*P*<0.05).

**Comparison of Anterior Chamber Parameters between the Two Groups Preoperatively and Postoperatively**

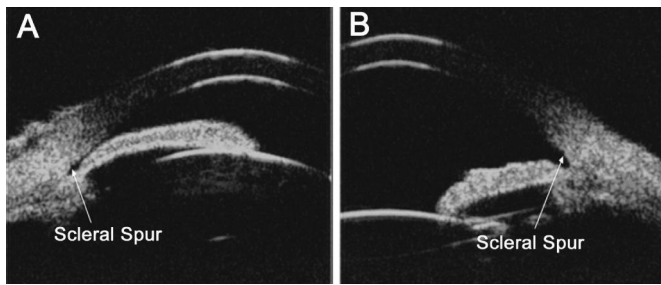
In the phacoemulsification group, the anterior chamber of 83.9% of eyes (26 eyes of 31 eyes) became deeper and the drainage angle reopened following surgery. The iris boot retained a slight iris bombe in 16.1% eyes (5 eyes of 31 eyes) including 12.9% (4 eyes of 31 eyes) with anterior synechia with trabecular meshwork within a range of 180° and 3.2% (1 eye of 31 eyes) with anterior synechia with trabecular meshwork ranging from 180° to 270° with failure of IOP control. In the phacotrabeculectomy group, the anterior chamber of 74.2% of eyes (23 eyes of 31 eyes) became deeper and the drainage angle reopened after surgery. The iris boot retained a slight iris bombe in 25.8% of eyes (8 eyes of 31 eyes) including 19.4% (6 eyes of 31 eyes) with anterior synechia with trabecular meshwork within a range of 180° and 6.5% (2 eyes of 31 eyes) with anterior synechia with trabecular meshwork ranging from 180° to 270° with failure of IOP control. The rate of iris bombe remaining after surgery in the phacoemulsification group was less than in the phacotrabeculectomy group (*P*<0.05).

Table 1 shows the UBM parameters in the phacoemulsification only group and phacotrabeculectomy group, there was significantly increase in ACD, AOD<sub>500</sub>, TIA

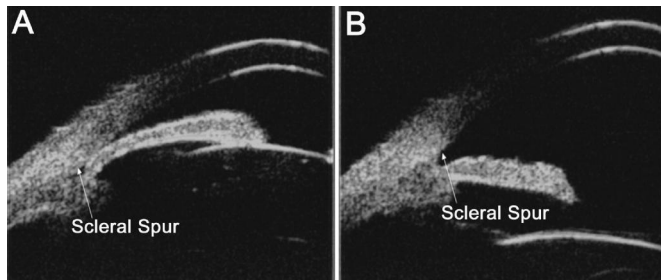
and ARA in both groups respectively before and 6mo after surgery (*P*<0.05), while there was no significant difference in TCPD in both groups before and after surgery (*P*>0.05). And there was significant difference between the two groups in TCPD preoperatively and postoperatively respectively, while there were not in the other parameters. Figure 3 shows an UBM image of anterior chamber configuration prior to phacoemulsification. ACD: 1.54 mm, AOD<sub>500</sub>: 0.06 mm, TIA: 8.56°, ARA: 0.05 mm<sup>2</sup>, TCPD: 0.53 mm. Figure 3B shows an UBM image of anterior chamber configuration of the same patient after phacoemulsification. ACD: 3.86 mm, AOD<sub>500</sub>: 0.21 mm, TIA: 37.91°, ARA: 0.92 mm<sup>2</sup>, TCPD: 0.53 mm by UBM. Figure 4 shows an UBM image of anterior chamber configuration prior to phacoemulsification combined with trabeculectomy. ACD: 1.36 mm, AOD<sub>500</sub>: 0.03 mm, TIA: 3.30°, ARA: 0.05 mm<sup>2</sup>, TCPD: 0.68 mm. Figure 4B shows an UBM image of anterior chamber configuration of the same patient after phacoemulsification combined with trabeculectomy. ACD: 3.23 mm, AOD<sub>500</sub>: 0.19 mm, TIA: 10.42°, ARA: 0.21 mm<sup>2</sup>, TCPD: 0.89 mm by UBM.

**Comparison of the Main Complications between the Two Groups Postoperatively**

In the phacoemulsification only group, the mean corneal endothelial cell density at 6mo postoperatively was 2188.73 ±516.23 cell/mm<sup>2</sup>, which was not significantly different to that of the preoperative value of 2406.43 ±625.41 cell/mm<sup>2</sup> (*P*>0.05). In the phacotrabeculectomy group, the mean corneal endothelial cell density at 6mo postoperatively was 2077.07 ±528.10 cells/mm<sup>2</sup>, which was significantly lower than the preoperative value of 2366.90 ±652.73 cells/mm<sup>2</sup> (*P*<0.01) indicating that the corneal endothelial cells were significantly decreased in the phacotrabeculectomy group but remained relatively unchanged in the phacoemulsification only group. In the



**Figure 3** UBM image shows the drainage angle was narrow before phacoemulsification (A), and the drainage angle was open after surgery in the same eye (B)(arrow shows scleral spur).



**Figure 4** UBM image shows the drainage angle was narrow before phacotrabeculectomy (A), and the drainage angle was open after surgery in the same eye (B) (arrow shows scleral spur).

phacoemulsification only group, the main complications in the early period after surgery were that 10 eyes showed mild and moderate corneal edema, and 1 eye showed an exudative membrane in the pupil that recovered within 1wk. In the phacotrabeculectomy group, the main complications in the early period after surgery were that 14 eyes showed mild and moderate corneal edema that recovered within 1wk, and 4 eyes showed an exudative membrane in the pupil that recovered within 1wk. In 2 eyes, an anterior chamber hemorrhage recovered within 2wk, and in 3 eyes, choroid detachment recovered within 1mo.

**DISCUSSION**

APAC glaucoma (is characterized by an obstruction of the outflow of aqueous humor and a consistent rise in IOP. Although conventional trabeculectomy is often used for this type of disease, trabeculectomy alone in a phakic eye with PACG carries a significant risk of the development of a postoperative flat anterior chamber<sup>[13,14]</sup>.

We found that cataract surgery was as effective as filtering surgery in controlling IOP in cases with APAC by 6mo of follow-up. In our study, IOP in the phacoemulsification group was slightly higher than that in the combined phacotrabeculectomy group by 1wk of follow-up, which may result from excessive filtration of the trabeculectomy. There was no significant difference in IOP between the two groups at the latter follow-up time. And the rate of 'complete success' in the phacoemulsification only group has no significant difference with the rate of 'complete success' in phacotrabeculectomy group. The results were different from the previous studies <sup>[6,15]</sup>. The possible reason for this

difference may be that pupil block may play a major in APAC of oriental patients<sup>[16]</sup>.

As known, the iridocorneal angle, iris, ciliary body, and posterior chamber can be imaged in detail and the anatomic relationships of these structures can also be determined using UBM. Using this type of microscopy, we can distinguish between pupil block and nonpupil-block factors in drainage angle closure <sup>[17]</sup>. In our study, for 87.5% of eyes of both groups, pupil block plays a major role in the drainage angle closure measured by preoperative UBM, and in 12.5% of eyes, narrow drainage resulted from a complicated mechanism including the coexistence of pupil block and nonpupil-block factors. The success rate of anterior chamber deepening and reopening of the drainage angle in the phacoemulsification group was greater than in the phacotrabeculectomy group after surgery. The possible reason for this finding may be that pupil block plays a major in oriental patients, and the drainage of aqueous humor from the anterior chamber by trabeculectomy may have made the anterior chamber shallower.

It has been reported that phacoemulsification may deepen the anterior chamber and widen the drainage angle as measured using UBM <sup>[18-20]</sup>. In our study, the ACD, AOD<sub>500</sub>, TIA and ARA increased by 93.89%, 1.50-fold, 1.20-fold and 1.43-fold in the simple phacoemulsification group at 6mo after surgery. However, there was no significant difference in TCPD between the pre- and postoperative eyes of the phacoemulsification only group. The ACD, AOD<sub>500</sub>, TIA and ARA increased by 74.7%, 1.09-fold, 1.14-fold and 1.32-fold in the combined surgery group, and there was also no significant difference in TCPD between the pre- and postoperative eyes of this group. The reason lack of change in postoperative TCPD may result from the small effects of ciliary processes position due to cataract extraction. The reason for the increase in parameters after phacoemulsification only and combined phacotrabeculectomy may be as follows: 1) after phacoemulsification, the swollen and forward-moving lens is replaced by an IOL and the iris is recessed. These changes result in a deepened anterior chamber and less contact of the lens with the iris, which may decrease pupil block and reduce pressure between the anterior and posterior chamber, resulting in decreased or disappearance of iris bombe; 2) The iris root becomes flattened and more distant from the trabecular meshwork, which reopens the closed drainage angle and improves access of aqueous humor to the trabecular meshwork. Both of the surgeries may deepen the anterior chamber and improve the anatomical structure of the chamber angle.

The high pressure of glaucoma may reduce the numbers of corneal endothelial cells and aggravate the loss of corneal endothelia and lead to corneal edema. Recently, it has been reported that up to 24.85% of corneal endothelia was lost

following combined phacotrabeculectomy<sup>[21]</sup>. In our study, in the phacoemulsification only group, the mean corneal endothelial cell density at 6mo postoperatively was  $2188.73 \pm 516.23$  cell/mm<sup>2</sup>, which was not significantly different from the preoperative value of  $2406.43 \pm 625.41$  cell/mm<sup>2</sup> although the corneal endothelial reduction rate was 9.0% . In phacotrabeculectomy group, the mean corneal endothelial cell density at 6mo postoperatively was  $2077.07$  cells/mm<sup>2</sup>, which was significantly lower than the preoperative value of  $2366.90$  cells/mm<sup>2</sup>, and patients showed 12.25% corneal endothelial loss. These results indicate that the corneal endothelial cell density was significantly decreased in the phacotrabeculectomy group but not changed by much in the phacoemulsification only group. The loss of corneal endothelia may be caused by damage or stimulation of the iris by the phacoemulsification or a surgical instrument. The rate of hyphema and choroid detachment were also higher in the phacotrabeculectomy group compared with the phacoemulsification only group. Thus, there were more complications following phacotrabeculectomy than phacoemulsification only. Furthermore, in our study, postoperative improvement in BCVA in the phacoemulsification only group was significantly greater than that of the combined phacotrabeculectomy group.

Our study revealed that both surgeries effectively deepened the anterior chamber, eliminated the papillary block, retained the configuration of the anterior chamber angle, and increased the inner drainage of the aqueous outflow. Although combined phacotrabeculectomy surgery can also increase the outer drainage of the aqueous outflow, the rate of functional filter blebs was low in this group. Because the IOP was well controlled postoperatively in both groups and the phacoemulsification only group improved the visual function and reduced the complications of the surgery to a greater degree, our study indicated that simple phacoemulsification surgery was an effective therapeutic choice for patients with APAC.

#### ACKNOWLEDGEMENTS

**Conflicts of Interest:** Li SW, None; Chen Y, None; Wu Q, None; Lu B, None; Wang WQ, None; Fang J, None.

#### REFERENCES

- 1 Husain R, Gazzard G, Aung T, Chen Y, Padmanabhan V, Oen FT, Seah SK, Hoh ST. Initial management of acute primary angle closure: a randomized trial comparing phacoemulsification with laser peripheral iridotomy. *Ophthalmology* 2012;119(11):2274-2281
- 2 Tarongoy P, Ho CL, Walton DS. Angle-closure glaucoma: the role of the lens in the pathogenesis, prevention, and treatment. *Surv Ophthalmol* 2009;54(2):211-215
- 3 Park SW, Heo H, Yang KJ. Comparison of ultrasound biomicroscopic changes after glaucoma triple procedure and trabeculectomy in eyes with primary angle closure glaucoma. *J Glaucoma* 2009;18(4):311-315
- 4 Nonaka A, Kondo T, Kikuchi M, Yamashiro K, Fujihara M, Iwakaki T, Yamamoto K, Kurimoto Y. Angle widening and alteration of ciliary process

- configuration after cataract surgery for primary angle closure. *Ophthalmology* 2006;113(3):437-441
- 5 Thomas R, Walland MJ, Parikh RS. Clear lens extraction in angle closure glaucoma. *Curr Opin Ophthalmol* 2011;22(2):110-114
- 6 Lai JS, Tham CC, Chan JC. The clinical outcomes of cataract extraction by phacoemulsification in eyes with primary angle-closure glaucoma (PACG) and co-existing cataract: a prospective case series. *J Glaucoma* 2006;15(1):47-52
- 7 Kim M, Park KH, Kim TW, Kim DM. Anterior chamber configuration changes after cataract surgery in eyes with glaucoma. *Korean J Ophthalmol* 2012;26(2):97-103
- 8 Hata H, Yamane S, Hata S, Shiota H. Preliminary outcomes of primary phacoemulsification plus intraocular lens implantation for primary angle-closure glaucoma. *J Med Invest* 2008;55(3-4):287-291
- 9 Tham CC, Kwong YY, Leung DY, Lam SW, Li FC, Chiu TY, Chan JC, Lam DS, Lai JS. Phacoemulsification vs phacotrabeculectomy in chronic angle glaucoma with cataract: complications [corrected]. *Arch Ophthalmol* 2010;128(3):303-311
- 10 Tham CC, Kwong YY, Leung DY, Lam SW, Li FC, Chiu TY, Chan JC, Lam DS, Lai JS. Phacoemulsification versus combined phacotrabeculectomy in medically uncontrolled chronic angle closure glaucoma with cataracts. *Ophthalmology* 2009;116(4):725-731
- 11 Rhiu S, Hong S, Seong GJ, Kim CY. Phacoemulsification alone versus Phacoemulsification combined with trabeculectomy for primary angle-closure glaucoma. *Yonsei Med J* 2010;51(5):781-783
- 12 Scott IU, Schein OD, West S, Bandeen-Roche K, Enger C, Folstein MF. Functional status and quality of life measurement among ophthalmic patients. *Arch Ophthalmol* 1994;112(3):329-335
- 13 Afekhide EO, Malachi EE, Efeareue TL. Surgical management of primary open-angle glaucoma in Africans. *Expert Rev Ophthalmol* 2010;5(1):95-107
- 14 Tham CC, Kwong YY, Baig N, Leung DY, Li FC, Lam DS. Phacoemulsification versus trabeculectomy in medically uncontrolled chronic angle-closure glaucoma without cataract. *Ophthalmology* 2013;120(1):62-67
- 15 Tham CC, Leung DY, Kwong YY, Li FC, Lai JS, Lam DS. Effects of phacoemulsification versus combined phaco-trabeculectomy on drainage angle status in primary angle closure glaucoma (PACG). *J Glaucoma* 2010;19(2):119-123
- 16 He M, Foster PJ, Johnson GJ, Khaw PT. Angle-closure glaucoma in East Asian and European people. Different diseases? *Eye (Lond)* 2006;20(1):3-12
- 17 Pavlin CJ, Ritch R, Foster FS. Ultrasound biomicroscopy in plateau iris syndrome. *Am J Ophthalmol* 1992;113(4):390-395
- 18 Dada T, Mohan S, Bali SJ, Bhartiya S, Sobti A, Panda A. Ultrasound biomicroscopic assessment of angle parameters in patients with primary angle closure glaucoma undergoing phacoemulsification. *Eur J Ophthalmol* 2011;21(5):559-565
- 19 Pereira FA, Cronemberger S. Ultrasound biomicroscopic study of anterior segment changes after phacoemulsification and foldable intraocular lens implantation. *Ophthalmology* 2003;110(9):1799-1806
- 20 Hejesk L, Pasta J. Ultrasound biomicroscopy of the eye before and after the cataract surgery. *Cesk Slov Oftalmol* 2006;62(1):27-33
- 21 Soro-Martinez MI, Villegas-Perez MP, Sobrado-Calvo P, Ruiz-Gomez JM, Miralles de Imperial Mora-Figureoa J. Corneal endothelial cell loss after trabeculectomy or after phacoemulsification, IOL implantation and trabeculectomy in 1 or 2 steps. *Graciles Arch Clin Exp Ophthalmol* 2010;248(2):249-256