

A knotless, one-haptic fixation of posterior chamber intraocular lenses: one-year results

Pipat Kongsap

Department of Ophthalmology, Prapokklao Hospital, Chanthaburi 22000, Thailand

Correspondence to: Pipat Kongsap. Department of Ophthalmology, Prapokklao Hospital, Chanthaburi 22000, Thailand. pkongsap@yahoo.com; pkongsap@gmail.com

Received: 2014-02-26

Accepted: 2014-08-08

Abstract

• **AIM:** To assess the results of a modified technique for scleral fixation of a posterior chamber intraocular lens (IOL) in eyes which had deficient of posterior capsular support.

• **METHODS:** This retrospective study was comprised of ten patients with deficient posterior capsular support who underwent one-haptic fixation of posterior chamber IOLs, between February 2010 and October 2011. IOL as implanted with one haptic supported on the capsular remnant and the other haptic drawn into the sulcus by anchoring suture without a knot. All patients were evaluated for pre- and postoperative visual acuity, lens centration, intra- and postoperative complications.

• **RESULTS:** A knotless, one-haptic fixation of posterior chamber IOLs has successfully been performed on ten eyes. All cases had inadequate capsular support (*i.e.* a capsular tear ranged from 5 to 7 clock hours). The average age was 74.25 ±8.87y (SD). The average postoperative uncorrected visual acuity was 0.51 logMAR. Complications included hyphema in one eye, a mild inflammatory reaction in the anterior chamber in two eyes, and a transient rise in IOP in one eye. Neither IOL tilt nor dislocation was observed and there were no later complications.

• **CONCLUSION:** In the presence of insufficient capsular support, a knotless, one-haptic fixation of posterior chamber IOLs is a safe and viable option which reduces the operation time, and minimizes postoperative suture-related complications.

• **KEYWORDS:** intraocular lens; scleral fixation; one-haptic fixation; knotless technique

DOI:10.3980/j.issn.2222-3959.2015.01.19

Kongsap P. A knotless, one-haptic fixation of posterior chamber intraocular lenses: one-year results. *Int J Ophthalmol* 2015;8 (1): 104-106

INTRODUCTION

Anterior chamber intraocular lens (IOL) implantation has been used for aphakia correction^[1,2]. Iris claw and iris-sutured posterior chamber IOL implantation have been reported in these cases^[3-7]. Transcleral sutured posterior chamber IOL implantation has been used to implant an IOL in eyes which had deficient posterior capsular support^[8-13].

Transcleral suture fixation technique has been shown to be safe and effective for optical rehabilitation. There have been many modifications of the technique, but these are technically difficult and require long operating time^[14-18]. To simplify and reduce the operating time, the author has developed a modified scleral fixation technique in which the IOL is implanted with one haptic supported on the capsular remnant and other haptic is drawn into the sulcus by anchoring the suture and fixating it to the sclera by a knotless technique.

SUBJECTS AND METHODS

The author reported a retrospective series of ten patients with deficient posterior capsular support who underwent a knotless, one-haptic fixation of posterior chamber IOLs, between February 2010 and October 2011. This study conformed to the Declaration of Helsinki for research involving human subjects and was approved by the Institutional Review Board of Prapokklao Hospital. Written informed consent was obtained from all patients.

All patients were evaluated for operation time, pre- and postoperative visual acuity, lens centration, and intra- and postoperative complications. The operation time for scleral fixation was measured from the start to the completion of the procedure (from conjunctival peritomy to removing the lid speculum).

Surgical Technique All procedures were performed under local anesthesia retrobulbar block. When capsule rupture or zonular dialysis occurred and remaining capsule support was considered insufficient for conventional IOL implantation, anterior vitrectomy was performed with an automated vitrector. An ophthalmic viscosurgical device (PROVISC®, Alcon, Laboratories, SA, USA, Pty/Ltd) is injected into the eye to fill the anterior chamber and the retro pupillary space. Conjunctival peritomy is created at the direction of capsule or zonule tear and half thickness scleral groove of 2.0 to 3.0 mm length is performed 1.5 mm behind the limbus. A 27-gauge needle is passed through the groove into the eye far enough

behind the iris to allow visualization of the bevel tip in the pupillary area.

A double-armed 10/0 prolene on a long straight needle is passed through the cornea opposite to the scleral groove opening into the anterior chamber and docked in the 27-gauge needle; suture and needle are then pulled externally.

The suture at the corneal site is cut and its end is pulled externally with a forceps through the superior scleral tunnel (Figure 1). A single-piece polymethylmethacrylate (PMMA) posterior chamber IOL with haptic eyelet is used (Neo Eye® IOL, RT. ROHTO Laboratories, Cimari, Indonesia). It was 13.5 mm in length with an optic diameter of 6.5 mm. The end of the suture is tied to a haptic eyelet of the IOL (Figure 2A).

IOL is implanted with one haptic supported on the capsular remnant and other haptic is drawn into the sulcus by pulling on the externalized suture (Figure 3). After the IOL is placed and centered, the anchoring suture is fixated to the sclera in a zigzag fashion [8]. The first bite is trimmed to the scleral groove and other bite is trimmed in the sclera with at least five indentations to secure the IOL (Figure 2B-D). The superior scleral tunnel incision is closed using a 10/0 nylon suture and the conjunctiva is then closed with 8-0 vicryl.

RESULTS

This technique was used in 10 patients with an average age of 74.25y (in a range from 57 to 84y). Eight cases had capsule defect during manual small-incision cataract surgery, 2 cases had zonular tear during phacoemulsification. All cases had inadequate capsular support; capsular tear/zonular tear from 5 to 7 clock hours. The locations for scleral fixation were superotemporal (in 3 cases), temporal (in 2 cases), superior (in 2 cases), nasal (in 1 case), inferior (in 1 case) and superonasal (in 1 case). The mean follow-up was 14.25±3.97mo (SD) (in a range from 12 to 23mo).

The operation time of scleral fixation of IOL ranged from 12 to 20min (average 15.75 ±2.71min). One eye developed hyphema which was resolved with conservative management within a few days; neither eye developed vitreous hemorrhage, choroidal hemorrhage, or retinal detachment. Two eyes had a mild inflammatory reaction in the anterior chamber. There was a transient rise in IOP in one of the eyes, while none of the eyes developed glaucoma. Timolol eye drop was used and discontinued within one month. Neither IOL tilt nor dislocation was observed after dilatation (by slit lamp). No suture exposure was noted and there were no later complications.

Snellen visual acuity was converted to the logarithm of minimal angle of resolution (logMAR). The pre-cataract extraction mean logMAR visual acuity was 1.51. The final visual acuity was better than preoperatively in all patients

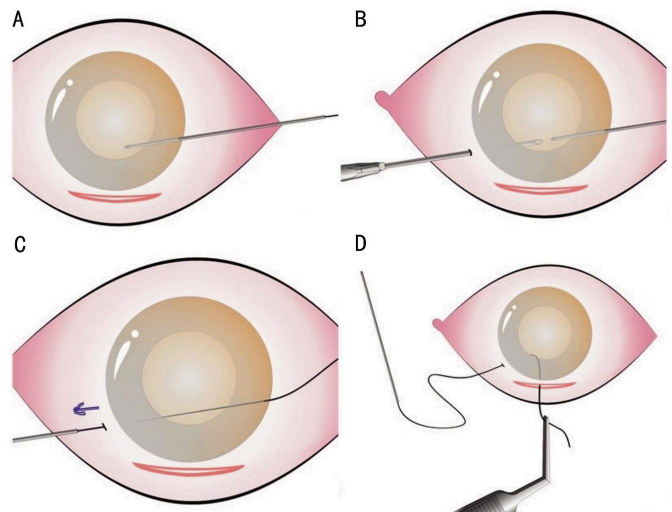


Figure 1 Steps of one-haptics fixation A-C: A double-armed 10/0 prolene on a long straight needle passed through the cornea and docked in the 27-gauge needle; D: One side of suture pulled externally through the superior scleral tunnel.

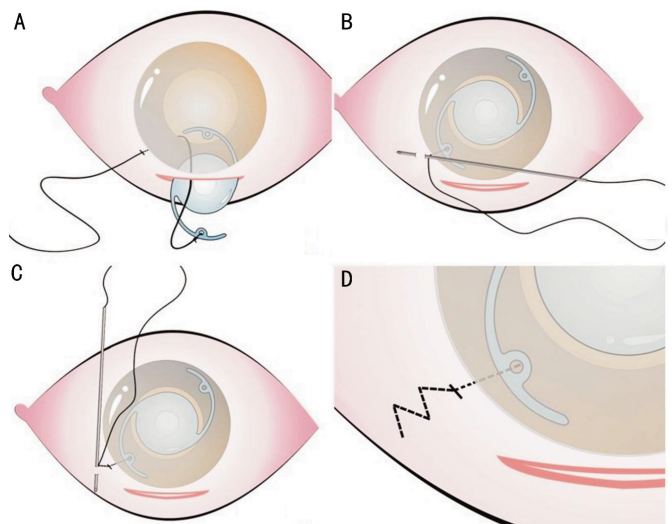


Figure 2 Scleral fixation technique A: The end of the suture tied to a haptic eyelet of the IOL; B-D: The anchoring suture fixated to the sclera in a zigzag fashion.

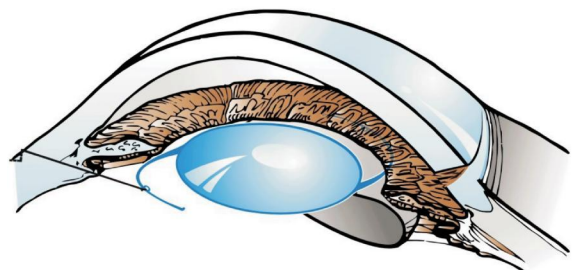


Figure 3 One haptic placed over the capsular remnant and other haptic tied with the externalized suture.

($P < 0.005$). The average uncorrected visual acuity (UCVA) was 0.51 logMAR and best-corrected visual acuity (BCVA) was 0.14 logMAR at one month postoperatively. These results remained stable at 3, 6 and 12mo postoperatively. The mean postoperative intraocular pressure (IOP) was 16.75 mm Hg (in a range from 9 to 20.5 mm Hg).

DISCUSSION

A transscleral suture fixation technique may be used in cataract surgery cases which have inadequate capsular support, a capsular rupture or a zonular tear. There have been many modification of the sclera fixation technique. Moawad and Ghanem^[19] reported a one-haptic fixation technique in which the needle is directed toward the opposite limbus and external end of the suture lie with a flat knot buried under the scleral tunnel. Yadav *et al*^[20] reported a transscleral fixation with the knotless technique in which the external end of suture passes into the sclera without a knot, scleral flap or a scleral tunnel.

A combination of the one haptic-fixation and the knotless technique was used in the present study. A knotless, one-haptic fixation of posterior chamber IOLs has successfully been performed on ten eyes by the method of a long straight needle being passed through the cornea opposite to the scleral groove opening into the anterior chamber and docked in the 27-gauge needle. Both suture and needle are then pulled externally. IOL is then implanted with one haptic supported on the capsular remnant and other haptic drawn into the sulcus by anchoring suture. The intrascleral suture performed in a zigzag fashion minimizes the risk of slippage^[9]. Suturing of the IOL in one side only and the knotless technique reduces surgical time, thus reducing the risk of suture exposure and irritation. The operation time for conventional scleral fixation (two haptic fixation) in my experience is approximately 45min per case but it is only sixteen minutes per case for this one-haptic fixation technique. Suture related complications such as erosion of knots through conjunctiva, slippage of the suture or endophthalmitis was not seen in this study. Any other serious complications such as choroidal detachment, expulsive hemorrhage and endophthalmitis were also not seen in this study.

However, self-limited complications such as hyphema, transient rise in IOP and inflammatory reaction were observed, but these results were no higher than those recorded by other author^[19,20]. There were no IOL dislocations observed in the study.

In conclusion, a knotless, one-haptic fixation of posterior chamber IOLs is a safe and viable option which reduces the operation time. This method also achieves good centration and minimizes postoperative suture-related complications in patients who have insufficient capsular support. However, this results were based on a small series with a short-term follow-up period, the author will continue to study the complications for three years. The comparative study between this technique and conventional scleral fixation is also on-going.

ACKNOWLEDGEMENTS

The author wishes to thank Mr. Chairat Pattana for the pictures in the article.

Conflicts of Interest: Kongsap P, None.

REFERENCES

- Giles K, Ernest M, Christelle D, Georges NT, Raoul C, Come EM, Wiedemann P. Aphakia correction by injection of foldable intra ocular lens in the anterior chamber. *Ophthalmol Eye Dis* 2013;5:17-22
- Omulecki W, Bartela J, Synder A, Palenga-Pydyn D, Wilczynski M. Results of implantation a new type of foldable anterior chamber intraocular lens. *Klin oczna* 2011;113(7-9):216-222
- Hsing YE, Lee GA. Retropupillary iris claw intraocular lens for aphakia. *Clin Experiment Ophthalmol* 2012;40(9):849-854
- Arnalich-Montiel F, Irigoyen C, Barrancos C. Fixation of subluxated iris-claw anterior chamber intraocular lens in complex case using a retrievable suture technique. *J Cataract Refract Surg* 2012;38(3):552-553
- Rao R, Sasidharan A. Iris claw intraocular lens: a viable option in monocular surgical aphakia. *Indian J Ophthalmol* 2013;61(2):74-75
- Zheng D, Wan P, Liang J, Song T, Liu Y. Comparison of clinical outcomes between iris-fixated anterior chamber intraocular lenses and scleral-fixated posterior chamber intraocular lenses in Marfan syndrome with lens subluxation. *Clin Experiment Ophthalmol* 2012;40(3):268-274
- Hirashima DE, Soriano ES, Meirelles RL, Alberti GN, Nose W. Outcomes of iris-claw anterior chamber versus iris-fixated foldable intraocular lens in subluxated lens secondary to Marfan syndrome. *Ophthalmology* 2010;117(8):1479-1485
- Holt DG, Young J, Stagg B, Ambati BK. Anterior chamber intraocular lens, sutured posterior chamber intraocular lens, or glued intraocular lens: where do we stand? *Curr Opin Ophthalmol* 2012;23(1):62-67
- Szurman P, Petermeier K, Aisenbrey S, Spitzer MS, Jaisle GB. Z-suture: a new knotless technique for transscleral suture fixation of intraocular implants. *Br J Ophthalmol* 2010;94(2):167-169
- Ohta T, Toshida H, Murakami A. Simplified and safe method of sutureless intrascleral posterior chamber intraocular lens fixation: Y-fixation technique. *J Cataract Refract Surg* 2014;40(1):2-7
- Liu S, Cheng S. Modified method of sutureless intrascleral posterior chamber intraocular lens fixation without capsular support. *Eur J Ophthalmol* 2013;23(5):732-737
- Agarwal A, Jacob S, Agarwal A, Narasimhan S, Kumar DA, Agarwal A. Glued intraocular lens scaffolding to create an artificial posterior capsule for nucleus removal in eyes with posterior capsule tear and insufficient iris and sulcus support. *J Cataract Refract Surg* 2013;39(3):326-333
- Wu W, Li Q, Yan D, Zhang J, Chen Y, Zhang H. Sulcus transscleral intraocular lens suture fixation through small scleral tunnel incision. *Eye Sci* 2011;26(2):102-107
- Choi KS, Park SY, Sun HJ. Transscleral fixation by injector implantation of a foldable intraocular lens. *Ophthalmic Surg Lasers Imaging* 2010;41(2):272-275
- Kim DH, Heo JW, Hwang SW, Lee JH, Chung H. Modified transscleral fixation using combined temporary haptic externalization and injector intraocular lens implantation. *J Cataract Refract Surg* 2010;36(5):707-711
- Yaguchi S, Yaguchi S, Noda Y, Taguchi Y, Negishi K, Tsubota K. Foldable acrylic intraocular lens with distended haptics for transscleral fixation. *J Cataract Refract Surg* 2009;35(12):2047-2050
- Borkenstein AF, Reuland A, Limberger JJ, Rabsilber TM, Auffarth GU. Transscleral fixation of a toric intraocular lens to correct aphakic keratoplasty with high astigmatism. *J Cataract Refract Surg* 2009;35(5):934-938
- Mannan R, Sinha R, Sharma N, Pruthi A, Titiyal JS, Vajpayee RB. Intrascleral reverse pocket approach of transconjunctival transscleral sulcus fixation of intraocular lens in eyes with ocular trauma. *Eye Contact Lens* 2011;37(5):316-319
- Moawad AI, Ghanem AA. One-haptic fixation of posterior chamber intraocular lenses without scleral flaps. *J Ophthalmol* 2012;2012:891839
- Yadav NK, Kemmanu V, Bhargava M, Shetty B. A truly knotless technique for scleral fixation of intraocular lenses: two-year results. *Indian J Ophthalmol* 2012;60(2):147-148