

Spontaneous or secondary to intravitreal injections of anti-angiogenic agents retinal pigment epithelial tears in age-related macular degeneration

Pia E. Leon, Sandro Saviano, Andrea Zanei, Marco R. Pastore, Elvira Guaglione, Alessandro Mangogna, Daniele Tognetto

University Eye Clinic of Trieste, Ospedale Maggiore, Piazza dell'Ospitale 1, Trieste 34125, Italy

Correspondence to: Pia E. Leon. University Eye Clinic of Trieste, Ospedale Maggiore, Piazza dell'Ospitale 1, Trieste 34125, Italy. pialeon@libero.it

Received: 2013-12-14 Accepted: 2014-03-14

Abstract

• **AIM:** To evaluate the visual function evolution of retinal pigment epithelial (RPE) tears in patients with age-related macular degeneration (AMD) according to type of occurrence [spontaneous or secondary to anti-vascular endothelial growth factor (anti-VEGF) injection] and the topographic location of the tear after a two-year follow-up period.

• **METHODS:** A total of 15 eyes of 14 patients with RPE tears in exudative AMD were analyzed retrospectively at the University Eye Clinic of Trieste. Inclusion criteria were: patient age of 50 or older with AMD and RPE tears both spontaneous occurring or post anti-VEGF treatment. Screening included: careful medical history, complete ophthalmological examination, fluorescein angiography (FA), indocyanine green angiography (ICG), autofluorescence and infrared imaging and optical coherence tomography (OCT). Patients were evaluated every month for visual acuity (VA), fundus examination and OCT. Other data reported were: presence of PED, number of injections before the tear, location of the lesion.

• **RESULTS:** Mean follow-up was 24wk (SD±4wk). A total of 15 eyes were studied for RPE tear. In 6 cases (40%), the RPE tears occurred within two years of anti-VEGF injections the others occurred spontaneously. In 13 cases (86.6%), the RPE tear was associated with pigment epithelial detachment (PED). In 7 cases (46.6%), the RPE tear occurred in the central area of the retina and involved the fovea. Two lesions were found in the parafoveal region, six in the extra-macular area. In all cases visual acuity decreased at the end of the follow-up period ($P < 0.01$) independently of the type or the topographical location of the lesion.

• **CONCLUSION:** RPE tear occurs in exudative AMD as a spontaneous complication or in relation to anti-VEGF injections. Visual acuity decreased significantly and gradually in the follow-up period in all cases. No correlation was found between visual loss and the type of onset or the topographic location of the tears.

• **KEYWORDS:** retinal pigment epithelial; age-related macular degeneration; tears; visual acuity; anti-vascular endothelial growth factor treatment

DOI:10.3980/j.issn.2222-3959.2014.04.18

Leon PE, Saviano S, Zanei A, Pastore MR, Guaglione E, Mangogna A, Tognetto D. Spontaneous or secondary to intravitreal injections of anti-angiogenic agents retinal pigment epithelial tears in age-related macular degeneration. *Int J Ophthalmol* 2014;7(4):681-685

INTRODUCTION

Retinal pigment epithelial (RPE) tears is a serious complication that may occur in patients with age-related-macular disease (AMD)^[1-3]. Hoskin was the first to describe these lesions in association with pigment epithelial detachment (PED) in exudative AMD^[1]. The RPE tear may happen spontaneously or as a result of retinal treatments such as laser photocoagulation, photodynamic therapy or intravitreal injections of primary anti-vascular-endothelial-growth-factor (anti-VEGF) agents^[2-4].

The distinctive appearance on fluorescein angiography is a well-demarcated hyperfluorescent window defect of bare choroid immediately adjacent to marked hypofluorescence due to increased blockage in the area with the contract RPE^[5,6].

In the majority of the cases, patients report sudden or gradual and severe visual loss. The symptoms are related to the location of the tear^[7,8]. In the case of extrafoveal RPE tears, visual acuity (VA) remains generally stable after onset. However, after more than two years, patients often suffer vision loss with VA of 20/200 or less. This poor prognosis is due to progressive scattering of the fibrovascular tissue^[9,10].

In this study, the evolution of visual function over a two-year follow-up period was considered according to type of occurrence (spontaneous or secondary to anti-VEGF injection) and the topographic location of the tear.

Table 1 Inclusion and exclusion criteria for enrollment of patients

Inclusion criteria	Exclusion criteria
Age ≥50a	High myopia
Spontaneous RPE-tear	History of central serous chorioretinopathy (CSC)
RPE-tear attributable to AMD at fundus examination, OCT, FA, ICG, autofluorescence and infrared examination	Laser and photodynamic treatment
RPE-tear secondary of anti-VEGF treatment (bevacizumab or ranibizumab) within a 2-year period before diagnosis	Glaucoma surgery
	Presence of proliferative vitreoretinopathy with primary regmatogenous retinal detachment
	Presence of RPE-tear in association with trauma, angioid streaks, ocular histoplasmosis syndrome (POHS) and PED secondary to idiopathic polypoidal choroidal vasculopathy

SUBJECTS AND METHODS

The authors conducted a retrospective study of a series of cases for a total of 15 eyes of fourteen patients with RPE tears as a complication of exudative AMD. All cases of RPE tears over a 4y period (from March 2008 to December 2012) at the University Eye Clinic of Trieste were reviewed. All participants were followed over a mean of 24wk (SD±4wk). For main eligibility criteria, see Table 1. Neither advanced age nor comorbidity or poor baseline visual acuity were used as an exclusion factor. All lesion types and sizes were eligible for the study.

At the screening visit, a careful medical history and completed ophthalmic evaluation with OCT (Stratus OCT; Carl Zeiss Meditec, Dublin, CA, USA), fluorescein angiography (FA, Heidelberg Engineering, Heidelberg, Germany) indocyanine green angiography (ICG, Heidelberg Engineering, Heidelberg, Germany), autofluorescence and infrared imaging were performed. RPE tears were graded from one to four based on the greatest length in vector direction of the tear and involvement of the fovea, according to Sarraf Grading System [3]: Grade 1 tears with diameter smaller than 200 μm, Grade 2 diameter between 200 μm and one disk diameter, Grade 3 diameter greater than one disk diameter, and Grade 4 diameter greater than one disk diameter involved the foveal center.

Patients were evaluated every month with visual acuity, fundus examination and OCT exam. Visual acuity, fundus examination, OCT, FA, ICG, autofluorescence and infrared imaging were performed at the 6th, 12th and 24th mo. Presence of pigment epithelial detachment (PED) and active choroidal neovascularization (CNV), the number of injections before the appearance of the tear, the type and location (Figure 1) of the lesions were recorded at the baseline visit.

At baseline seven eyes (46.6%) demonstrated an active choroidal neovascularization with leakage at FA and intraretinal edema at the OCT examination. Intravitreal injections of bevacizumab 0.5 mg/0.05 mL (Avastin; Genentech, Inc., South San Francisco, CA, USA) were performed in these cases during the follow-up. Bevacizumab was initiated

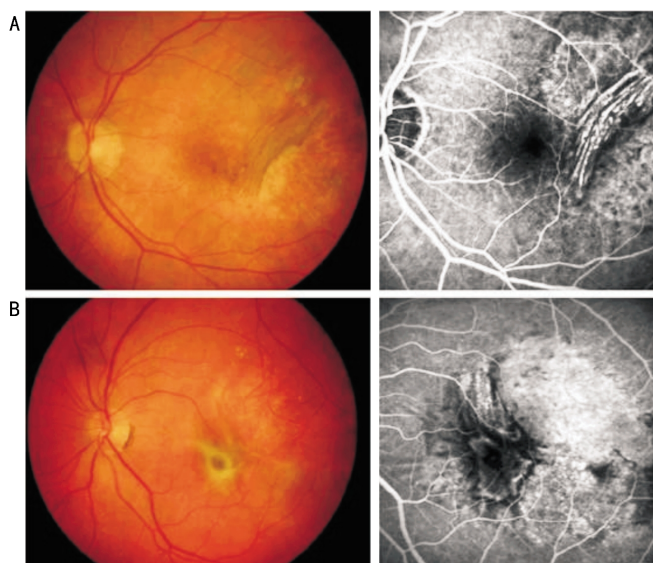


Figure 1 Topographical location of RPE tears Extrafoveal (A) and foveal (B) location.

with 3 consecutive monthly injections, followed by retreatment as needed (pro-re-nata protocol, PRN) with monthly monitoring. Bevacizumab was prepared and placed in a 1 mL syringe in sterile conditions by the hospital pharmacy. Injections were performed as an outpatient procedure under strict aseptic conditions under topical anesthesia. Using a 27 G needle, 0.05 mL of bevacizumab was injected into the vitreous cavity. Topical ofloxacin four times daily for seven days was prescribed after each injection. Patients were examined daily first and fourth after injection.

Patients received additional treatment following the retreatment criteria: loss of visual acuity, increase or permanence of intraretinal edema and permanence of leakage at fluorescein angiography. At the 9th mo of the follow-up, there were no active lesions in any patients treated.

The study was performed in accordance with the tenets of the Declaration of Helsinki, and informed consent was obtained from all subjects. Statistical analysis was performed using IBM® SPSS® Advanced Statistics software version 19.0 (formerly PASW® Advanced Statistics). The level of statistical significance was taken as 1% (P<0.01).

Table 2 Characteristics of the RPE tears

Case	Age	Sex	Eye	PED	VA baseline (LogMAR)	Latest VA (LogMAR)	CNV feature	Type of insurgence		Location of RPE tear	No. anti-VEGF injections before diagnosis	No. anti-VEGF injections during follow-up ²	RPE tear grade ¹
								Spontaneous	After anti-VEGF treatment				
1	80	F	RE	Yes	0.5	0.8	100% Occult	X		Foveal	-	-	4
2	76	M	RE	No	1	1.4	Classic	X		Extrafoveal	-	-	3
3	82	M	LE	Yes	0.3	1.2	100% Occult		X	Extrafoveal	1	6	3
4	78	F	RE	Yes	0.8	0.8	100% Occult		X	Foveal	3	6	4
5	79	F	LE	Yes	0.4	0.8	100% Occult	X		Foveal	-	3	4
6	81	M	RE	Yes	0.3	1	100% Occult		X	Juxtafoveal	4	3	4
7	82	F	RE	Yes	0.3	1	100% Occult	X		Juxtafoveal	-	-	4
8	77	M	RE	Yes	0.5	1.2	100% Occult		X	Extrafoveal	5	6	3
9	78	F	LE	Yes	0.4	0.6	100% Occult		X	Extrafoveal	3	-	2
10	83	M	RE	No	0.7	0.8	100% Occult		X	Foveal	6	-	4
11	76	F	RE	Yes	0.8	1.5	100% Occult		X	Foveal	4	3	4
12	81	F	LE	Yes	0.8	1.6	Predominantly occult	X		Foveal	-	-	4
13	82	F	RE	Yes	0.9	1.4	100% Occult	X		Foveal	-	-	4
14	78	M	RE	Yes	1	1.2	Predominantly occult		X	Extrafoveal	1	-	3
15	81	F	RE	Yes	0.4	0.9	100% Occult		X	Extrafoveal	2	3	3

RPE: Retinal pigment epithelium; PED: Pigment epithelial detachment; VA: Best-corrected Snellen visual acuity; CNV: Choroidal neovascularization. ¹Sarraf's RPE Tear Grade^[3]; ²Anti-VEGF injections during the first 8mo of follow-up: bevacizumab 0.5 mg/0.05 mL following a PRN protocol.

RESULTS

A total of 15 eyes of fourteen patients were studied for RPE tear, which ranged from 76 to 83y. At the moment of diagnosis all of the patients showed RPE tear documented by the FA, ICG, OCT, auto-fluorescence and infrared examinations.

In 6 cases, the RPE tears occurred spontaneously in exudative AMD. In 9 eyes, the RPE tears occurred after previous treatments of anti-VEGF injections within a period of two years before diagnosis. Five eyes were treated with intravitreal injections of ranibizumab 0.5 mg/0.05 mL (Lucentis, Novartis International AG, Basel, Switzerland) and 4 received bevacizumab 0.5 mg/0.05 mL (Avastin; Genentech, Inc., South San Francisco, CA, USA) injections. The mean of anti-VEGF injections performed was 4.55±0.3 for patient. No further treatments were performed after RPE tear.

In 13 cases, the RPE tear was associated with previously-documented PED. All the PED were vascularized with the presence of choroidal neovascularization (CNV) and in the 93.3% of the cases an occult neovascularization was found. In all cases with the precedence of PED, the RPE rip developed as a crescent-shaped parallel to the temporal edge of the PED. Five of 6 spontaneous tears occurred in association with PED. Eight of 13 cases of RPE rip with PED occurred after anti-VEGF treatment (Table 2).

At baseline 7 cases of RPE tears were associated to an active CNV, 8 not presented signs of neovascular activity at FA and intraretinal edema at the OCT exam. All active CNV cases were treated with bevacizumab injections. Four eyes received 3 monthly injections; other 3 patients underwent 6 injections

within 8mo after baseline. At the 9th mo of the follow-up, there were no active lesions in any patients treated.

Morphological aspects of the RPE tears at the baseline FA and OCT examination were collected and documented with the Sarraf Grading System for RPE tears (Table 2)^[3]. Nine cases were categorized as Grade 4, while 6 cases with fovea sparing were classified Grade 2 and 3.

The RPE tear's location was reported in Table 2. In 7 cases (46.6%), the rip occurred in the central area of the retina involving of the fovea. Two lesions (13.4%) were in the parafoveal region and 6 (40%) in the extra-macular area. In the statistical analysis, the parafoveal data were included in the foveal group.

The baseline best corrected VA (BCVA) was 0.60±0.26 logMAR for all of the patients. At the 6, 12, 18 and 24mo of follow-up visual acuity was respectively 0.72±0.27, 0.82±0.23, 0.98±0.28 and 1.08±0.29 logMAR ($P<0.01$, Mann-Whitney test). The BCVA was also considered for the type of occurrence and the topographical location. Table 3 reported the BCVA trend over the 2y of follow-up considering the total group of RPE tears, the type of occurrence (spontaneous, after anti-VEGF injection) or the retinal location (central and parafoveal vs extra-macular). The functional decrease was continuous and gradual for the two years of follow-up. There were no differences among the subgroups considered on the basis of topographical location and type of occurrence.

Moreover, no statistically difference of visual function was observed in the subgroup of RPE-tears treated for active CNV respect the rest of the group at the end of the follow-up ($P=0.21$).

Table 3 BCV for the total group of patients, the type of insurgence and topographical localization of the RPE tears

Types of RPE	VA baseline (LogMAR)	VA 6mo (LogMAR)	VA 12mo (LogMAR)	VA 18mos (LogMAR)	VA 24mo (LogMAR)	P ¹
All patients	0.6	0.72	0.82	0.98	1.08	P<0.01
Insurgence (P<0.01)						
Spontaneous	0.59	0.71	0.79	0.96	1.08	P<0.01
After injection anti-VEGF	0.58	0.70	0.82	0.99	1.07	P<0.01
Localization (P<0.01)						
Extrafoveal	0.61	0.74	0.85	1.00	1.1	P<0.01
Foveal and Juxtafoveal	0.59	0.71	0.79	0.96	1.08	P<0.01

VA: Visual acuity; ¹Friedman test.

DISCUSSION

RPE tears generally occur as a rare complication in patients with age-related macula disease either as a spontaneous occurrence or after anti-VEGF injections. Visual prognosis is poor as demonstrated in several studies which documented a major decrease in visual acuity to less than 20/200^[1-5,11,12]. The current study found that visual acuity decreases gradually and significantly over a long period afterwards. All patients suffered gradual loss of vision and this is correlated to the patho-physiological evolution of the lesion^[11,13]. RPE tears are characterized by a gradual process of atrophy and a deposition of fibrovascular tissue recognized by the OCT examination^[9]. All OCT exams performed at the end of the follow-up period demonstrated a thinner retina fibrosis and atrophy of the subretinal portion in all patients (Figure 2). Further recent studies conducted with spectral domain OCT demonstrated that in old RPE tears (>1y) the retinal layers were impossible to be recognized due to the progressive atrophic degeneration whereas in recent RPE tears (<1y), external limiting membrane, photoreceptor inner and outer segment junction, and nonatrophic outer nuclear layer could be identified in the retina on the RPE denuded area^[9,14,15].

Another purpose of this study was to evaluate the correlation between the visual function and the type of occurrence of the tears. Various long follow-up period studies have been published, with conflicting results^[16-19]. Coscas *et al*^[2] reported a study of 98 eyes with spontaneous RPE tears documented a severe decrease in visual acuity over a period of five years. Introini *et al*^[16] analyzed visual outcome and RPE tear incidence of 132 eyes with wet-AMD. Eyes treated with anti-VEGF therapy showed slight mean visual acuity decrease and an important risk of acute RPE tear^[16].

Moreira *et al*^[17] evaluated the long-term visual results with repeated anti-VEGF therapy not as devastating as previously suggested. Visual acuity and metamorphopsia improved with time as long as the neovascular membrane is inactive. Coco *et al*^[18] and Lesniak *et al*^[19] supported the safety role of anti-VEGF therapy in eyes with spontaneous RPE tear secondary to AMD, and the importance to stabilize or even

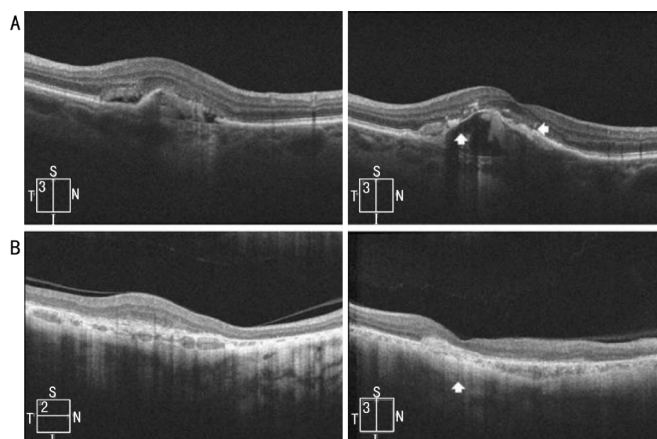


Figure 2 Development of fibrosis of RPE tears after one year of follow-up A: Case of parafoveal RPE tear with the presence of sub-retinal fibrosis in subfoveal area (right, see the arrow); B: Case of extrafoveal RPE tear with the presence of subretinal fibrosis in subretinal area (right, see the arrow).

improve acuity in some cases^[20]. In this study we also considered a subgroup of 7 patients receiving anti-VEGF therapy for activate CNV in presence of RPE-tear. The treatments were effective in all cases producing an inactivation of the CNV with the resolution of the intraretinal edema at OCT exam and leakage at FA at the 9th mo after baseline. No statistically differenced was observed in terms of visual function between these cases and the rest of the group at the end of the follow-up. This finding might suggest a protective effect of the anti-VEGF treatment without which the visual function could be worse for the expansion of the neovascular membrane. Nevertheless further studies and greater numbers of cases are needed to support this finding.

In our study we considered spontaneous insurgences as well as those after anti-VEGF treatment.

We registered a spontaneous decrease in visual acuity among the two subgroups considered for the type of occurrence with no statistical differences between them. No statistically significant correlation was also found for visual acuity according to the topographical location area of the tears. The majority of tears, even if located in the extra-macular area, involved the macula over the two years of follow-up, reducing visual acuity.

An increase in RPE tears was observed in recent years because of the introduction of anti-VEGF therapy^[5,8,16,21]. This is probably attributable to the rapid contraction of the neovascular membrane and the tangential traction of the RPE when the drug is injected into the vitreous cavity.

Several studies focused on RPE tears occurring after anti-VEGF intravitreal therapies and included an analysis of the adverse ocular events after bevacizumab or ranibizumab treatment^[14-16,19]. Spandau *et al*^[22] studied 63 patients who received intravitreal applications of bevacizumab. During the follow-up period of two months, RPE tears were detected in 4 patients (6%). Chang *et al*^[14,23] found the overall risk for RPE tears after intravitreal ranibizumab injection to be relatively low. At least 17.1% of eyes with PEDs may develop RPE tears after intravitreal ranibizumab injection in contrast to the 10% incidence reported in past literature on untreated RPE tears^[9].

Gutfleisch *et al*^[24] observed RPE tears in 12% -15% of treated eyes during anti-VEGF therapy for pigment epithelium detachment in exudative AMD.

In our work no differences were found between ranibizumab and bevacizumab in terms of incidence of RPE tears. This result is in line with several studies published in recent years^[1,6,8,14,15]. The study limitations were the retrospective analysis and the small number of cases evaluated.

In conclusion, clinicians should pay particular attention for this complication especially when utilizing intravitreal injections for treatment of neovascular AMD in eyes with PED. Relevant factor for a seriously negative visual prognosis was the morphologic fibrovascular transformation of the RPE tear. Because the precise origin of RPE tears is still unknown, patients with PED are at notable risk for this occurrence. These results underscore the need for careful follow-up of patients with AMD, especially those receiving anti-VEGF treatments.

ACKNOWLEDGEMENTS

Conflicts of Interest: Leon PE, None; Saviano S, None; Zanei A, None; Pastore MR, None; Guaglione E, None; Mangogna A, None; Tognetto D, None.

REFERENCES

- 1 Chang LK, Sarraf D. Tears of retinal pigment epithelium. An old problem in a new era. *Retina* 2007;27(5):523-534
- 2 Coscas G, Koenig F, Soubrane G. The pretear characteristics of pigment epithelial detachments. *Arch Ophthalmol* 1990;108(12):1687-1693
- 3 Sarraf D, Reddy S, Chiang A, Yu F, Jan A. A new grading system for retinal pigment epithelial tears. *Retina* 2010;30(7):1039-1045
- 4 Lee GKY, Lai TY, Chan WM, Lam DS. Retinal pigment epithelial tear following intravitreal ranibizumab injections for neovascular age-related macular degeneration. *Gracé's Arch Clin Exp Ophthalmol* 2007;245(8):1225-1227
- 5 Dhalla MS, Blinder KJ, Tewari A, Hariprasad SM, Apte RS. Retinal pigment epithelial tear following intravitreal pegaptanib sodium. *Am J Ophthalmol* 2006;141(4):752-754
- 6 Gass JD. Pathogenesis of tears of the retinal pigment epithelium. *Br J Ophthalmol* 1984;68(8):513-519

- 7 Gelissen F, Inhoffen W, Partsch M, Schneider U, Kreissig I. Retinal pigment epithelial tear after photodynamic therapy for choroidal neovascularization. *Am J Ophthalmol* 2001;131(4):518-520
- 8 Meyer CH, Mennel S, Schmidt JC, Kroll P. Acute retinal pigment epithelial tear following intravitreal bevacizumab (Avastin) injection for occult choroidal neovascularization secondary to age related macular degeneration. *Br J Ophthalmol* 2006;90(9):1207-1208
- 9 Giovannini A, Amato G, Mariotti C, Scassellati-Sforzolin B. Optical coherence tomography in the assessment of retinal pigment epithelial tear. *Retina* 2000;20(1):37-40
- 10 Smith BT, Kraus CL, Apte RS. Retinal pigment epithelial tears in ranibizumab-treated eyes. *Retina* 2009;29(29):335
- 11 Chuang EL, Bird AC. The pathogenesis of tears of the retinal pigment epithelium. *Am J Ophthalmol* 1988;105(3):285-290
- 12 Rosenfeld PJ, Moshfeghi AA, Puliafito CA. Optical coherence tomography findings after an intravitreal injection of bevacizumab (Avastin) for neovascular age-related macular degeneration. *Ophthalmic Surg Lasers Imaging* 2005;36(4):331-335
- 13 Decker WL, Sanborn GE, Ridley M, Annesley WH Jr, Sora EM. Retinal pigment epithelium tears. *Ophthalmology* 1983;90(5):507-512
- 14 Chang LK, Flaxel CJ, Lauren AK, Sarraf D. RPE tears after pegaptanib treatment in age-related macular degeneration. *Retina* 2007;27(7):857-863
- 15 Rosenfeld PJ, Brown DM, Heir JS, Boyer DS, Kaiser PK, Chung CY, Kim RY; MARINA Study Group. Ranibizumab for neovascular age-related macular degeneration. *N Engl J Med* 2006;355(14):1419-1431
- 16 Intorini U, Torres Gimeno A, Scotti F, Setaccioli M, Giatsidis S, Bandello F. Vascularized retinal pigment epithelial detachment in age-related macular degeneration: treatment and RPE tear incidence. *Gracé's Arch Clin Exp Ophthalmol* 2012;250(9):1283-1292
- 17 Moreira CA Jr, Arana LA, Zago RJ. Long-term results of repeated anti-vascular endothelial growth factor therapy in eyes with retinal pigment epithelial tears. *Retina* 2013;33(2):277-281
- 18 Coco RM, Sanabria MR, Hernandez AG, Fernández Muñoz M. Retinal pigment epithelium tears in age-related macular degeneration treated with antiangiogenic drugs: a controlled study with long follow-up. *Ophthalmologica* 2012;228(2):78-83
- 19 Lesniak SP, Fine HF, Prenner JL, Roth DB. Long-term follow-up of spontaneous retinal pigment epithelium tears in age-related macular degeneration treated with anti-VEGF therapy. *Eur J Ophthalmol* 2011;21(1):73-76
- 20 Rich RM, Rosenfeld PJ, Puliafito CA, Dubovy SR, Davis JL, Flynn HW Jr, Gonzalez S, Feuer WJ, Lin RC, Lalwani GA, Nguyen JK, Kumar G. Short-term safety and efficacy of intravitreal bevacizumab (Avastin) for neovascular age-related macular degeneration. *Retina* 2006;26(5):495-511
- 21 Gutfleisch M, Heimes B, Schumacher M, Dietzel M, Lommatzsch A, Bird A, Pauleikhoff D. Long-term visual outcome of pigment epithelial tears in association with anti-VEGF therapy of pigment epithelial detachment in AMD. *Eye* 2011;25(9):1181-1186
- 22 Spandau UH, Jonas JB. Retinal pigment epithelium tear after intravitreal bevacizumab for exudative age-related macular degeneration. *Am J Ophthalmol* 2006;142(6):1068-1070
- 23 Chang LK, Lin SG. Retinal pigment epithelial tear after ranibizumab therapy for subfoveal fibrovascular pigment epithelial detachment. *Eur J Ophthalmol* 2007;17(4):674-676
- 24 Gutfleisch M, Heimes B, Schumacher M, Dietzel M, Lommatzsch A, Bird A, Pauleikhoff D. Long-term visual outcome of pigment epithelial tears in association with anti-VEGF therapy of pigment epithelial detachment in AMD. *Eye* 2011;25(9):1181-1186