

# A new technique for Nd:YAG laser posterior capsulotomy

Jung Kee Min<sup>1</sup>, Jae Hwan An<sup>1</sup>, Jin Ho Yim<sup>2</sup>

<sup>1</sup>Department of Ophthalmology, Ulsan University Hospital, Ulsan University College of Medicine, 290-3 Jeonha-dong, Dong-gu, Ulsan 682-714, Republic of Korea

<sup>2</sup>Samsung Eye Clinic, Cheongju 361-270, Republic of Korea  
**Correspondence to:** Jin Ho Yim. Samsung Eye Clinic, 3F G well citymall, Bokdae-dong, Heungdeok-gu, Cheongju, Chungbuk 361-270, Republic of Korea. yimjinho@hanmail.net  
Received: 2013-03-26 Accepted: 2013-12-06

## Abstract

• **AIM:** To investigate the effects of a new opening pattern in neodymium:yttrium –aluminum –garnet (Nd:YAG) laser posterior capsulotomy on visual function.

• **METHODS:** This technique was conducted along a circular pattern. The energy ranged between 0.8 and 1.2 mJ/pulse was consumed and mean total energy levels were 74±21 mJ (mean±standard deviation: SD, from 40 to 167) and laser shots aimed at 150 μm away behind a datum point and went along an imaginary line which extends 0.5 mm inside from optic margin and into the circular en bloc pattern. Vitreous stands were attached with fragment and then they were cut off by the laser after circular application. The circular fragment was completely separated from vitreous, and then this fragment was quickly sunk in intravitreal space.

• **RESULTS:** The follow-up period ranges from at least a week to 40mo, making 15.8mo on average. The procedural outcome showed 96% (74 eyes out of the 77 eyes) enhancement in patients' visual acuity. Cystoid macular edema or retinal detachment was not observed in any of the patients during follow-up periods.

• **CONCLUSION:** This new technique is expected to improve the weaknesses that the conventional procedures have by adding the process to cut off vitreous stands attached with the fragment by the laser to the circular application.

• **KEYWORDS:** cataract; intraocular lens damage; posterior capsular opacification; vitreous strand; YAG laser capsulotomy  
**DOI:10.3980/j.issn.2222-3959.2014.02.28**

Min JK, An JH, Yim JH. A new technique for Nd:YAG laser posterior capsulotomy. *Int J Ophthalmol* 2014;7(2):345-349

## INTRODUCTION

One of the common post-cataract surgery complications is posterior capsular opacification (PCO). The occurrence rate of PCO has been variously reported, but according to the paper reported in 1998, 25 percent of the patients, who had experienced extracapsular cataract surgery developed significant PCO within the following 5y after the procedure<sup>[1]</sup>. Numerous studies have found the development mechanism of PCO<sup>[2-7]</sup>. The understanding of the pathogenesis has led to the improvements of cataract surgery techniques including intraocular lens (IOL) material and designs. Such improvements decreased the incidence rate of PCO (ranged from 2.7% to 20.4 %) or delayed at least PCO onset<sup>[8-11]</sup>. And also, in 2004, Pandey *et al*<sup>[12]</sup> reported the current incidence of PCO was less than 10%. The conventional method used for treatment of PCO is neodymium:yttrium-aluminum-garnet (Nd:YAG) capsulotomy. Laser shots can be applied in several patterns. One of the frequently used techniques is called 'cross pattern method', which is known to be easy to learn and requires relatively less procedural time<sup>[13-16]</sup>. However, pit marks and cracks of along the visual axis of the optic at an IOL may happen since the procedure is performed in axial region, and it may cause forward light scatter from capsule remnants and subsequent glare symptoms. There is also a possibility to increase vitreous floater that is caused by broken pieces during the procedure. Another conventional method is a circular application called 'can opener method' wherein laser capsulotomy is conducted along the circumference of the optic. This procedure can prevent the damage to IOL, but involves a drawback that visual axis can be hidden by large free-floating remnant<sup>[16]</sup>. An inverted U method was introduced to make up for the weaknesses that the two methods possessed, but it is associated with another problem; immediate vision recovery cannot be checked since some time is needed until resultant flap sinks in intravitreal space due to gravity and contraction of capsule as such<sup>[17]</sup>.

The present study introduces a new technique that overcomes the problems associated with conventional methods. Especially, we have focused on advantages of the new method when compared to the conventional applications and its procedural outcome.

## SUBJECTS AND METHODS

**Subjects** This study was approved by the Institutional

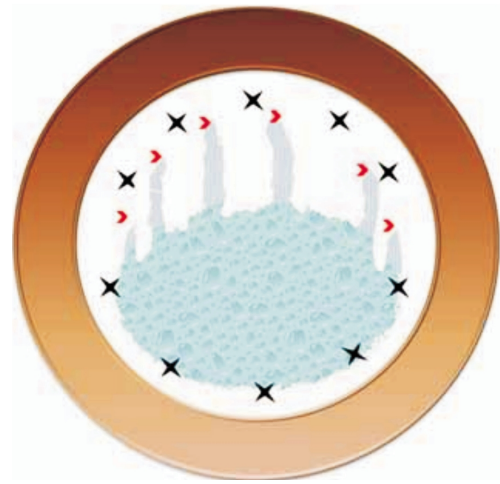
Human Experimentation Committee Review Board of Ulsan University Hospital and performed in accordance with the ethical standards in the Declaration of Helsinki. After a detailed explanation of the procedure benefits and risks, informed consents were obtained from all the patients.

**Methods** This was a prospective interventional study conducted in the Department of Ophthalmology, Ulsan University Hospital, Ulsan, Republic of Korea. All patients went through a baseline ophthalmologic examination before laser capsulotomy including measurements of best-corrected visual acuity (BCVA), Goldmann applanation tonometry and fundus examination. This study is based on PCO on 77 eyes of 76 patients. They previously underwent an uneventful phacoemulsification procedure together with IOL implantation (in-the-bag placement) at least 1y ago. These IOLs were made of hydrophobic acrylic material (70 eyes) and polymethylmethacrylate (PMMA) (7 eyes). This technique was conducted when an eye lost two or more decimal line of BCVA or when the patients complained of blurred vision. One of the authors (Yim JH) verified the presence of definite PCO on slit-lamp exam. Both pearl- and fibrosis-type PCO underwent laser posterior capsulotomy with this new technique. There was convincing evidence of PCO at the center of posterior capsule for all patients.

Patients excluded were those, who had media opacities other than PCO or were not suitable for capsulotomy treatment. For example, there was capsule tear, IOL distortion or subluxation and so on. Patients in whom macular or optic disc pathologies were present were also excluded from the present investigation. The same examiner also carried out all the examinations of the posterior pole. The patients subsequently had Nd:YAG laser (VISULAS YAG III, Carl Zeiss Meditec, Jena, Germany) capsulotomy by the same surgeon (Yim JH).

Sufficient pupil dilatation which made a show of the optic margin was made by instilling several drops of topical 2.5% phenylephrine hydrochloride, approximately 30min prior to the procedure. A capsulotomy contact lens, which was a 12 mm Ocular Abraham Capsulotomy lens (Ocular Instruments, WA, US), was used in all the cases after instilling 2-3 drops of 0.5% proparacaine hydrochloride into the conjunctival sac and 2% hypromellose gel into the contact lens as coupling media. We set the optic center as a point corresponding to visual axis.

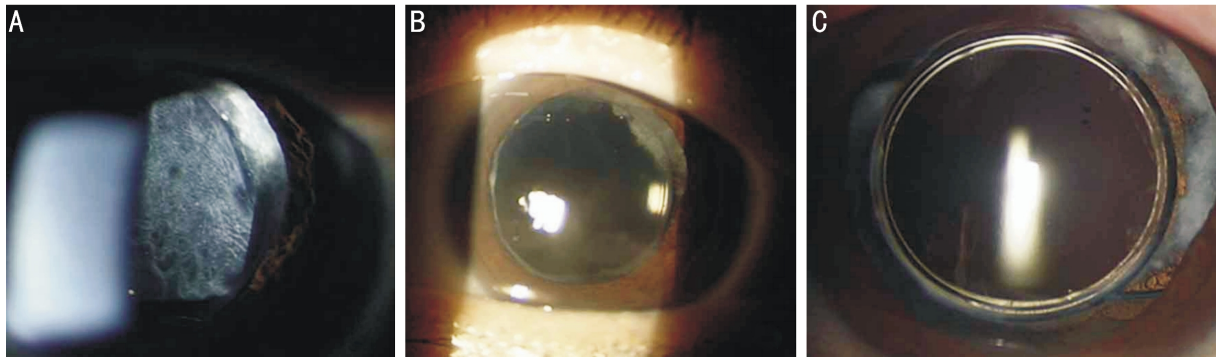
Single pulse mode Nd:YAG laser was used at the minimal amount of energy necessary to obtain breakdown and rupture the capsule and vitreous strand. The energy needed for this procedure was between 0.8 and 1.2 mJ/pulse. The initial energy of 0.8 mJ/pulse was consumed and then it maintained or increased its initial value depending on the degree of breaking of the capsule and mean total energy levels were 74±21 mJ (mean±standard deviation: SD, from 40 to 167).



**Figure 1** A schematic drawing of the procedure showing the site of the new technique, Nd:YAG laser application. A number of laser shots (star points) in the posterior capsule, which were aimed at posterior 150  $\mu\text{m}$  from a datum point were conducted along an imaginary line. After circular application, some vitreous strands (vertical line area), which were attached with a large fragment were cut off by laser (arrow heads). The circular fragment was completely separated from vitreous, and then quickly sunk in intravitreal space.

No difference was given to the initial energy levels according to PCO types. A number of laser shots in the posterior capsule, which were aimed at posterior 150  $\mu\text{m}$  from a datum point were conducted along an imaginary line. This line extended 0.5 mm inside from optic margin or along anterior continuous curvilinear capsulorhexis (CCC) and into circular en bloc pattern. After circular application of laser, vitreous strands which were attached with fragment were cut with the laser. When the procedure was performed, the circular fragment was completely separated from vitreous, and then quickly sunk in intravitreal space (Figure 1). As rise in IOP was perhaps the most common side effect of Nd:YAG laser capsulotomy, all patients had one drop of brimonidine tartrate/timolol maleate ophthalmic solution both before and immediately after and this eye drop two times a day during post treatment 2d. In addition, all patients had 0.1% fluorometholone eye drop four times daily for 1wk. The patients were checked the retinal problems through dilated funduscopic examination on the following 1<sup>st</sup> week and 6<sup>th</sup> month. Also, almost all patients were followed up every 6mo. The follow-up period ranged from at least one week to 40mo, making  $15.8 \pm 11.4\text{mo}$  on an average. Procedural outcome was determined based on the values of BCVA, which were measured before and after the procedure.

**Statistical Analysis** Statistical analysis was carried out using SPSS 18 for Windows (SPSS Inc., Chicago, Illinois, USA). LogMAR visual acuity and IOP were compared between pre- and post-procedural levels and analyzed via paired *t*-test. Correlation was considered significant at *P*



**Figure 2** A 61 year–old female who underwent a phacoemulsification with IOL (hydrophobic acrylate) implantation 8y ago. Anterior segment photographs: before procedure (A), immediately after (B) and 7d (C) following a new technique (C), laser posterior capsulotomy.

**Table 1** New laser capsulotomy procedural outcomes during follow-up period

Outcomes	Preop.	Postop. d1	Postop. last follow-up	<sup>1</sup> P
BCVA (logMAR)	0.58±0.41	0.28±0.30	0.22±0.26	<0.001
Vision improvement (%)		68/77 (88)	74/77 (96)	
IOP (mm Hg)	13.1±3.43	13.5±3.11 (after 1 <sup>st</sup> wk)		0.787

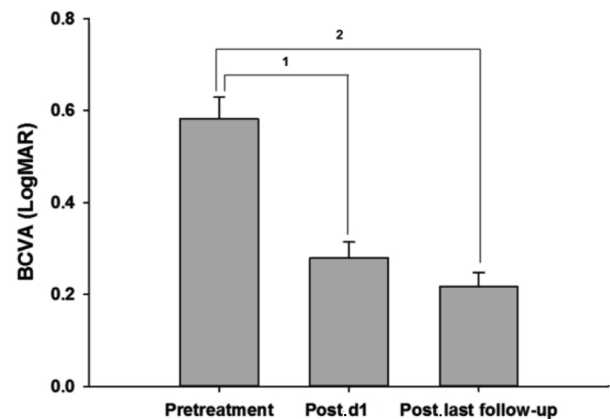
The follow-up period ranged from at least one week to 40mo, making 15.8±11.4mo on an average. BCVA: Best-corrected visual acuity; IOP: Intraocular pressure. Values are mean±SD (standard deviation); <sup>1</sup>Paired *t*-test.

value of <0.05.

## RESULTS

Figure 2 represents anterior segment photographs before procedure (A), immediately after (B) and 7d (C) following a new technique laser posterior capsulotomy. There were no pit marks and cracks of axial lesion of the optic at IOL. Procedural outcomes are listed in Table 1. The mean preprocedural BCVA (LogMAR) was found to be 0.58±0.41 (mean±SD) for all the enrolled patients. On the first day after laser capsulotomy, the mean postprocedural BCVA was found to be 0.28±0.30 and 68 eyes (88%) among 77 eyes was considered as a degree of immediate improvement in the patient's vision. The BCVA remained stable and improved during postprocedural follow-up. At last follow-up after the performance of new method, the mean postprocedural BCVA was found to be 0.22±0.26 and procedural outcome showed 96 % (74 eyes out of the 77 eyes) enhancement in patients' visual acuity. Such increments of the visual acuity levels were in a statistical trusted range as shown in Table 1 and Figure 3 (paired *t*-test, *P* values <0.001). Sixteen eyes with pre-treatment BCVA ≥0.9 in the PCO achieved remarkable progress in visual acuity. After this treatment, the BCVA <0.3 was achieved in 60 eyes (78%) (Table 2).

No differences in mean IOP were observed between pre- and postprocedural states. In addition, no IOP increments after laser treatment were found during follow-up period. Cystoid macular edema (CME) or other retinal problems including retinal detachment were not observed in any of the patients during the follow-up period. There were nil patients, who complained about light scatter and subsequent glare symptoms after laser procedure.



**Figure 3** Mean BCVA (LogMAR) along the course of the follow –up period. At d1 after this procedure, the BCVA (LogMAR) was 0.28 and the BCVA remained stable. Each column and bar represents mean±standard error. <sup>1,2</sup>: Paired *t*-test (*P*<0.001).

**Table 2** Comparison of visual acuity changes between pre and post new technique for laser capsulotomy

BCVA (LogMAR)	Preoperative: n (%)	Postoperative: n (%)
≥0.9	16 (21)	0 (0)
0.6≤BCVA<0.9	21 (27)	2 (3)
0.3≤BCVA<0.6	35 (46)	15 (19)
<0.3	5 (6)	60 (78)
Total	77 (100)	77 (100)

## DISCUSSION

The problems caused by PCO can usually be remedied by laser procedure with Nd:YAG capsulotomy to create an opening in the posterior lens capsule. However, Nd:YAG capsulotomy procedure is associated with complications such as damage to intraocular lenses [18,19], increases in

**Table 3 Comparison of different Nd:YAG laser capsulotomy patterns**

Parameters	This study	Zeki <sup>[17]</sup>	Khanzada <i>et al</i> <sup>[35]</sup>	Hayashi <i>et al</i> <sup>[36]</sup>
Laser pattern type	Circular pattern+ vitreous strand cutting	Inverted 'U' strategy	Cross pattern	Cross pattern (large capsulotomy)
No. of patients	76 patients (77 eyes)	200	320	41
Follow up period	1 wk to 40mo (mean 15.8mo)	6wk to 6mo	4wk	4 to 21mo (mean 13.5mo)
Visual acuity	96% improvement	All patients improvement	96.9% improvement	Contrast VA and glare VA: significantly better than those with the small capsulotomy
Used energy level	0.8-1.2 mJ/pulse Total energy: 40 to 167 mJ	Maximum 1.9 mJ/pulse The number of laser application: 5 to 11	1.5-5 mJ/pulse Total energy: 12 to 180 mJ	0.5-1.5 mJ/pulse 2 times
Complications	CME (-), RD (-)	CME (-), RD (-)	IOL pitting (+, 9.37%) CME(+, 0.62%), RD (-)	CME (-), RD (-)

post-operative IOP, CME, disruption of the anterior vitreous face<sup>[20-24]</sup>, and increased incidence of retinal detachment<sup>[1,25-33]</sup>. We considered the possibility of such complications in laser treatment.

In this study, brimonidin tartrate/timolol maleate eyedrop had been applied to the eyes of patients according to the schedule after the procedure, to prevent the increment of IOP after laser capsulotomy. Many studies have shown increased rates (0.5% to 3.6%) of retinal detachment incidence after Nd:YAG capsulotomy<sup>[25-33]</sup>. However, there was a report, which stated that rate of retinal detachment after laser capsulotomy was so low as to suggest no causal relationship between Nd:YAG capsulotomy and retinal detachment<sup>[34]</sup>. We also thought that there were risks of the development of side effects like, CME due to the disruption of anterior vitreous face or the rise in retinal detachment since this method generated larger capsulotomy size than the conventional cross pattern method and directly cut off vitreous strands that were attached with fragment by laser. So, prior to the procedure, we made sure to check patients' risk factors such as high myopia and lattice degeneration with associated holes and minimize laser energy used in the procedure. We selected patients who passed at least one year after cataract surgery and examined the disorder of capsule and IOL after pupil dilatation and excluded patients who had capsule tear, IOL distortion or subluxation *etc.* In addition, after the treatment, we also ensured to check the development of any complications through dilated funduscopy examination on the following 1<sup>st</sup> wk, 6<sup>th</sup> mo and every 6mo. As a result, no patient in this study developed these complications after the performance of this new laser capsulotomy during the follow-up period. But, there were 9 patients who had less than 3mo follow-up periods. According to our observation so far, we did not see any retinal detachment, but they had been likely to develop retinal detachment if we continuously conducted follow-up on them. Still, it would seem prudent to wait for further studies before adopting this technique, especially in the management of poor-risk eyes.

We compared results obtained by using different conventional methods and summarized those in Table 3<sup>[17,35,36]</sup>. This new method could overcome the drawbacks associated with the conventional procedures without any involvement of complications. Cutting of vitreous strands can be easily performed during laser capsulotomy and then this fragment is quickly sunk in intravitreal space. This technique can prevent any damage near visual axis of IOL and generate sufficiently large size of capsulotomy to restore contrast sensitivity and glare disability<sup>[36]</sup>. It was also effective in preventing vitreous floater, caused by fragment around visual axis and in hindering generation of free-floating remnant. We also presume that dissection of vitreous strand which is attached to posterior capsule would prevent any additional problems such as CME, retinal detachment due to vitreous traction. This new method has been consumed the minimum energy to the vitreous strand cutting, but it also would have a possibility to increase the whole energy in use and result in potential side effects, which be considered a weak point of our study. Finally, we could immediately check vision improvement right after the performance of procedure as opposed to other method, which required some amount of time until natural sinking of flap occurred. We conclude that this new technique can be performed safely and achieved rapid visual recovery. Its use in the routine management of PCO is suggested.

#### ACKNOWLEDGEMENTS

**Conflicts of Interest:** Min JK, None; An JH, None; Yim JH, None.

#### REFERENCES

- Schaumberg DA, Dana MR, Christen WC, Glynn RJ. A systematic overview of the incidence of posterior capsule opacification. *Ophthalmology* 1998;105(7):1213-1221
- Apple DJ, Solonom KD, Tetz MR, Assia EI, Holland EY, Legler UF, Tsai JC, Castaneda VE, Hoggatt JP, Kostick AM. Posterior capsule opacification. *Surv Ophthalmol* 1992;37(2):73-116
- Gwon A. Lens regeneration in mammals: a review. *Surv Ophthalmol* 2006;51(1):51-62
- Findle O, Neumayer T, Hirschall N, Buehl W. Natural course of

- Elschnig pearl formation and disappearance. *Invest Ophthalmol Vis Sci* 2009;51(3):1547-1553
- 5 Neumayer T, Findl O, Buehl W, Sacu S, Menapace R, Georgopoulos M. Long-term changes in the morphology of posterior capsule opacification. *J Cataract Refract Surg* 2005;31(11):2120-2128
- 6 Neumayer T, Findl O, Buehl W, Georgopoulos M. Daily changes in the morphology of Elschnig pearls. *Am J Ophthalmol* 2006;141(3):517-523
- 7 Buehl W, Findl O, Neumayer T, Georgopoulos M, Sacu S. Short-term changes in the morphology of posterior capsule opacification. *J Cataract Refract Surg* 2005;31(5):962-968
- 8 Thompson AM, Sachdev N, Wong T, Riley AF, Grupcheva CN, McGhee CN. The Auckland Cataract Study: 2 year postoperative assessment of aspects of clinical, visual, corneal topographic and satisfaction outcomes. *Br J Ophthalmol* 2004;88(8):1042-1048
- 9 Dholakia SA, Vasavada AR. Intraoperative performance and longterm outcome of phacoemulsification in age-related cataract. *Indian J Ophthalmol* 2004;52(4):311-317
- 10 Khandwala MA, Marjanovic B, Kotagiri AK, Teimory M. Rate of posterior capsule opacification in eyes with the Akeris intraocular lens. *J Cataract Refract Surg* 2007;33(8):1409-1413
- 11 Paracha Q. Cataract surgery at Marie Adelaide Leprosy Centre Karachi: an audit. *J Pak Med Assoc* 2011;61(7):688-690
- 12 Pandey SK, Apple DJ, Werner L, Maloof AJ, Milverton EJ. Posterior capsule opacification: a review of the aetiopathogenesis, experimental and clinical studies and factors for prevention. *Indian J Ophthalmol* 2004;52(2):99-112
- 13 Goble RR, O'Brart DP, Lohmann CP, Fitzke F, Marshall J. The role of light scatter in the degradation of visual performance before and after Nd:YAG capsulotomy. *Eye* 1994;8(Pt 5):530-534
- 14 Hu CY, Woung LC, Wang MC. Change in the area of laser posterior capsulotomy: 3 month follow-up. *J Cataract Refract Surg* 2001;27(4):537-542
- 15 Levy JH, Pisacano AM. Comparison of techniques and clinical results of YAG laser capsulectomy with two Q-switched units. *J Am Intraocul Implant Soc* 1985;11(2):131-133
- 16 Murrill CA, Stanfield DL, Van Brocklin MD. Capsulotomy. *Optom Clin* 1995;4(4):69-83
- 17 Zeki SM. Inverted U' strategy for short pulsed laser posterior capsulotomy. *Acta Ophthalmol Scand* 1999;77(5):575-577
- 18 Newland TJ, McDermott ML, Elliott D, Hazlett LD, Apple DJ, Lambert RJ, Barrett RP. Experimental neodymium:YAG laser damage to acrylic, poly (methyl methacrylate), and silicone intraocular lens materials. *J Cataract Refract Surg* 1999;25(1):72-76
- 19 Trinavarat A, Atchaneeyasakul L, Udompunturak S. Neodymium:YAG laser damage threshold of foldable intraocular lenses. *J Cataract Refract Surg* 2001;27(5):775-780
- 20 Bath PE, Fankhauser F. Long-term results of Nd:YAG laser posterior capsulotomy with the Swiss laser. *J Cataract Refract Surg* 1986;12(2):150-153
- 21 Ge J, Wand M, Chiang R, Paranhos A, Shields MB. Long-term effect of Nd:YAG laser posterior capsulotomy on intraocular pressure. *Arch Ophthalmol* 2000;118(10):1334-1337
- 22 Krauss JM, Puliafito CA, Miglior S, Steinert RF, Cheng HM. Vitreous changes after neodymium-YAG laser photodisruption. *Arch Ophthalmol* 1986;104(4):592-597
- 23 Smith RT, Moscoso WE, Trokel S, Auran J. The barrier function in neodymium-YAG laser capsulotomy. *Arch Ophthalmol* 1995;113(6):645-652
- 24 Ranta P, Tommila P, Immonen I, Summanen P, Kivela T. Retinal breaks before and after neodymium:YAG posterior capsulotomy. *J Cataract Refract Surg* 2000;26(8):1190-1197
- 25 Ambler JS, Constable IJ. Retinal detachment following Nd:YAG capsulotomy. *Aust NZ J Ophthalmol* 1988;16(4):337-341
- 26 Dardenne MU, Gerten GJ, Kokkas K, Kermani O. Retrospective study of retinal detachment following neodymium:YAG laser posterior capsulotomy. *J Cataract Refract Surg* 1989;15(6):676-680
- 27 Javitt JC, Tielsch JM, Canner JK, Kolb MM, Sommer A, Steinberg EP. National outcomes of cataract extraction. Increased risk of retinal complications associated with Nd:YAG laser capsulotomy. The Cataract Patient Outcomes Research Team. *Ophthalmology* 1992;99(10):1487-1497; discussion 1497-1498
- 28 Koch DD, Liu JF, Gill EP, Parke DW 2nd. Axial myopia increases the risk of retinal complications after neodymium-YAG laser posterior capsulotomy. *Arch Ophthalmol* 1989;107(7):986-990
- 29 Kohnen S, Brauweiler P. First results of cataract surgery and implantation of negative power intraocular lenses in highly myopic eyes. *J Cataract Refract Surg* 1996;22(4):416-420
- 30 Powell SK, Olson RJ. Incidence of retinal detachment after cataract surgery and neodymium:YAG laser capsulotomy. *J Cataract Refract Surg* 1995;21(2):132-135
- 31 Rickman-Barger L, Florine CW, Larson RS, Lindstrom RL. Retinal detachment after neodymium:YAG laser posterior capsulotomy. *Am J Ophthalmol* 1989;107(5):531-536
- 32 Shah GR, Gills JP, Durham DG, Ausmus WH. Three thousand YAG lasers in posterior capsulotomies: an analysis of complications and comparison to polishing and surgical dissection. *Ophthalmic Surg* 1986;17(8):473-477
- 33 Steinert RF, Puliafito CA, Kumar SR, Dudak SD, Patel S. Cystoid macular edema, retinal detachment, and glaucoma after Nd:YAG laser posterior capsulotomy. *Am J Ophthalmol* 1991;112(4):373-380
- 34 Nielsen NE, Naeser K. Epidemiology of retinal detachment following extracapsular cataract extraction: a follow-up study with an analysis of risk factors. *J Cataract Refract Surg* 1993;19(6):675-680
- 35 Khazada MA, Jatoi SM, Narsani AK, Dabir SA, Gul S. Is the Nd:YAG laser a safe procedure for posterior capsulotomy? *Pak J Ophthalmol* 2008;24(2):73-78
- 36 Hayashi K, Nakao F, Hayashi H. Influence of size of neodymium:yttrium-aluminium-garnet laser posterior capsulotomy on visual function. *Eye* 2010;24(1):101-106