

Treatment of traumatic globe dislocated completely into the maxillary sinus

Bei Xu¹, Xue-Liang Xu¹, Jia Yan²

¹ Department of Ophthalmology, Xiangya Hospital, Central South University, Changsha 410008, Hunan Province, China

² Department of Ophthalmology, the First People's Hospital, Shaoyang 422001, Hunan Province, China

Correspondence to: Xue-Liang Xu. Department of Ophthalmology, Xiangya Hospital, Central South University, Changsha 410008, Hunan Province, China. Xuxueliang8341@yahoo.com.cn

Received: 2012-05-16 Accepted: 2013-01-10

DOI:10.3980/j.issn.2222-3959.2013.01.22

Xu B, Xu XL, Yan J. Treatment of traumatic globe dislocated completely into the maxillary sinus. *Int J Ophthalmol* 2013;6(1):106-107

Dear Sir,

I am Dr. Bei Xu, from Department of Ophthalmology, Xiangya Hospital, Central South University, Changsha, Hunan Province, China. I want to present a rare case of the treatment of traumatic globe dislocated completely into the maxillary sinus.

A 46-year-old female was admitted to emergency unit due to traffic accident, presenting disturbance of consciousness for nine hours.

Initial examination revealed 3mm superciliary arch laceration and cerebrospinal fluid leaking out through the skin wound. The right globe could not be visualized. CT and MRI showed: 1) pneumocephalus in frontal lobe; 2) fracture of frontal bone; 3) multiple fracture of the orbital floor with a complete dislocation of the right globe into the right maxillary sinus; 4) prolapse of right globe into the right maxillary sinus (Figure 1A, B). The patient underwent debridement and laceration repair, as well as the treatment with antibiotics and hemostasia in the Department of emergency. Subsequently, the patient was transferred to the Department of Ophthalmology for further treatment.

Physical examination in the Department of Ophthalmology: body temperature: 36.3°C, Pulse: 76 beats per minute, Respiration: 20 breaths per minute, Blood pressure: 112/77mmHg. Ophthalmic examination revealed a primary healing of the right superciliary arch wound, inward depression of the right eyelid, absence of the right eyeball and no chemosis (Figure 2). There was no abnormality in the

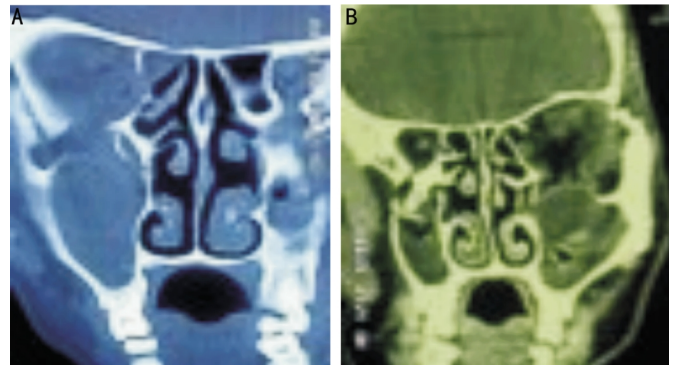


Figure 1 Prolapse of right globe into the right maxillary sinus.

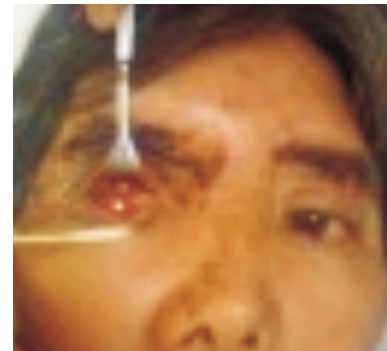

Figure 2 The absence of the right eyeball.

left eye. Main Diagnosis in Ophthalmology: 1) prolapse of right globe into the right maxillary sinus; 2) multiple fractures of the right orbit. The patient was taken to the operating room for the restoration of the right globe and the reduction of the fracture, surgical lower eyelid incision from the lower lid margin about 3mm, separating the soft tissue to the orbital margin, cutting open the periosteum and then continue to separate, a circular fracture which just like the globe size exposed in the middle of the inferior orbital wall, the posterior globe can be seen through the fracture hole, the orbital hernia dislocated completely in the maxillary sinus. The tension of extraocular muscles was extended, which resulted in restricted motility of the eyeball. Thus the globe could not get across the fracture hole when the extraocular muscles were pulled to make the globe repositioned. Rongeur was used to enlarge the hole in the inferior orbital wall. The dislocated globe was repositioned manually into the orbit by periosteum detacher and brain spatula. Upon gross examination, we noted no signs of eyeball rupture, and the pupil appeared moderately dilated. The cornea showed transparent, and anterior chamber had a good depth, with a

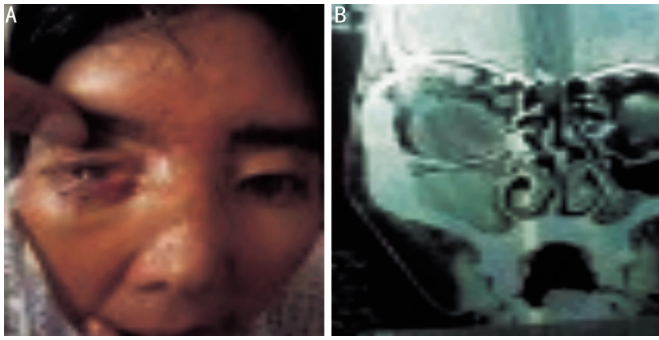


Figure 3 Postoperatively, the eyeball in right eye.

titanium mesh to produce a range of 1mm larger than the inferior orbital wall fracture of the mesh, attached to the fracture zone, the orbital rim fixed with the titanium nail. The incision was sewed up in the lower Fornix conjunctival incision. Postoperatively, the patient reported light perception with restricted motility of the eyeball in right eye (Figure 3A, B).

DISCUSSION

The medial orbital wall and orbital floor are commonly affected in blow-out fracture because of their weak structures. Soft tissue in orbit, such as extraocular muscles, ligaments, and orbital fat, always hernia into the fracture hole, when the orbital endure burst fracture^[1-3]. However, complete dislocation of an intact globe into the maxillary sinus after an extensive blowout fracture is a rare occurrence. In this case, mutiple orbital wall suffered from traumatic fracture, especially the inferolateral wall, which resulted in the globe completely dislocated into the maxillary sinus. We speculated that inferolateral wall and other orbital wall were broken by an instant top-down force, which pushed the globe into the maxillary sinus^[3,4]. Because the eyeball sank into the maxillary sinus, globe lesions could not be checked. Although CT and MRI indicated that the integrity of the globe was not impaired. We analyzed that the globe was extremely likely to be contused in traffic accident. Contusion of the eyeball may result in anterior and central vitreous hemorrhage, lens dislocation, secondary glaucoma, optic nerve damage and other complications^[5-8]. Urgent surgery was indicated to reposition of the globe into the orbit and

repair of the inferior wall of the orbit. Surgery could restore of normal globe position and repair inferolateral orbital wall^[9-11]. In this case, the size of orbital fracture was as large as the eye. It is inevitably result in secondary injury if pull the eye violently. Therefore, it is the necessary to expand the fracture hole so that dislocated globe could be successfully repositioned and further damage could be well prevented. Local and systematical administrations of steroids and antibiotics are also necessary to get a good recovery.

REFERENCES

- 1 Zhang-Nunes SX, Jarullazada I, Mancini R. Late central visual recovery after traumatic globe displacement into the maxillary sinus. *Ophthalm Plast Reconstr Surg* 2012;28(1):e17-19
- 2 Saleh T, Leatherbarrow B. Traumatic prolapse of the globe into the maxillary sinus diagnosed as traumatic enucleation of the globe. *Eye (Lond)* 1999;13(Pt 5):678-680
- 3 Abrishami M, Aletaha M, Bagheri A, Salour SH, Yazdani S. Traumatic subluxation of the globe into the maxillary sinus. *Ophthalm Plast Reconstr Surg* 2007;23(2):156-158
- 4 Smit TJ, Koornneef L, Zonneveld FW. A total orbital floor fracture with prolapse of the globe into the maxillary sinus manifesting as postenucleation socket syndrome. *Am J Ophthalmol* 1990;110(5):569-570
- 5 Akhaddar A, Elmostarchid B, Boucetta M. Images in emergency medicine. Traumatic intraorbital stone with globe displacement into the maxillary sinus. *Emerg Med J* 2010;27(11):828
- 6 Jellab B, Baha AT, Moutaouakil A, Khoumiri R, Raji A, Ghannane H, Samkaoui MA, Ait BS. Management of a severe cranio-orbito-facial trauma with a dislocation of the globe into the maxillary sinus. *Bull Soc Belge Ophthalmol* 2008;(309-310):37-41
- 7 Pelton RW, Rainey AM, Lee AG. Traumatic subluxation of the globe into the maxillary sinus. *Am J Neuroradiol* 1998;19(8):1450-1451
- 8 Berkowitz RA, Putterman AM, Patel DB. Prolapse of the globe into the maxillary sinus after orbital floor fracture. *Am J Ophthalmol* 1981;91(2): 253-257
- 9 Damasceno NAP, Damasceno EF. Traumatic orbital fracture with intact ocular globe displacement into the maxillary sinus. *Rev Bras Oftalmol* 2010;69(1):52-54
- 10 Ramstead C, McCabe J, Alkahtani M, Leong-Sit J, Morhart M. Traumatic dislocation of the globe into the maxillary sinus. *Can J Ophthalmol* 2008;43(3):364-366
- 11 Müller-Richter UD, Kohlhof JK, Driemel O, Wagener H, Reichert TE. Traumatic dislocation of the globe into the maxillary sinus. *Int J Oral Maxillofac Surg* 2007;36(12):1207-1210