

Antifungal efficacy of natamycin in experimental *fusarium solani* keratitis

Xian-Hui Dong, Wei-Juan Gao, Xiao-Ping He

Foundation item: Supported by Major Project of The Ministry of Science and Technology of China (No. 2007BAI26B07)

Laboratory of Spinal Cord Injury and Rehabilitation of Chengde Medical University, Chengde 067000, Hebei Province, China

Correspondence to: Wei-Juan Gao. Laboratory of Spinal Cord Injury and Rehabilitation of Chengde Medical University, Chengde 067000, Hebei Province, China. gwj6088@163.com

Received: 2012-02-14 Accepted: 2012-04-07

Abstract

• **AIM:** To evaluate the efficacy of topical administration Natamycin, which is produced by China, in an experimental rabbit model of *Fusarium solani* keratitis, to provide experimental basis for the application of clinical safety.

• **METHODS:** *Fusarium solani* was induced in the right eye of 30 New Zealand rabbits. Forty-eight hours after inoculation, the animals were divided into 3 different treatment groups, 10 rabbit eyes of each group: Group 1 (Natamycin) treated with topical Natamycin, group 2 (Natacyn) treated with topical Natacyn, group 3 (control) treated with topical saline solution. The eyes of each group was examined clinically with slit lamp using ulcer scoring system on day 4, 10, 15, and 21 for status of healing, corneal vascularisation, iritis, hypopyon and macular nebula. The findings were recorded on day 10 and day 21.

• **RESULTS:** Ulcer score on day 10, day 15, day 21: The score of Natamycin group are 1.45 ± 0.16 , 1.08 ± 0.11 , 0.70 ± 0.40 . The score of Natacyn group are 1.35 ± 0.12 , 1.10 ± 0.12 , 0.65 ± 0.35 . the score of control group are 1.30 ± 0.08 , 3.63 ± 0.28 , 3.80 ± 0.16 . Natamycin group and Natacyn group were different from control group ($P < 0.01$). There is no difference between Natamycin group and Natacyn group. Status of healing on day 10 and day 21: The cure rate of the Natamycin group is 90% on day 10, and 100% on day 21. The cure rate of the Natacyn group is 80% on day 10, and 100% on day 21. Natamycin group and Natacyn group were different from control group ($P < 0.01$). There is no difference between Natamycin group and Natacyn group. Corneal vascularisation, iritis, hypopyon and macular nebula on day 10 and day 21: in Natamycin group, the number of the eyes

which have Corner vascularisation, iritis, hypopyon and macular nebula are 2,0,0,2. In Natamycin group, the number of the eyes which have Corner vascularisation, iritis, hypopyon and macular nebula are 1,0,0,2. In control group, the number of the eyes which have Corner vascularisation, iritis, hypopyon and macular nebula are 9,9,8,9. Natamycin group and Natacyn group were different from control group ($P < 0.01$). There is no difference between Natamycin group and Natacyn group.

• **CONCLUSION:** Natamycin was found to be effective in fungal keratitis, similar to Natacyn, and it can stop the corner vascularisation, iritis, hypopyon and macular nebula to happen. Natamycin manufactured in China is effective against fungal keratitis, with easy availability and low toxicity in its use.

• **KEYWORDS:** *fusarium solani*; fungal keratitis; natamycin; natacyn

DOI:10.3980/j.issn.2222-3959.2012.02.05

Dong XH, Gao WJ, He XP. Antifungal efficacy of natamycin in experimental *fusarium solani* keratitis. *Int J Ophthalmol* 2012;5(2):143-146

INTRODUCTION

Fungal keratitis (keratomycosis) is a major cause of blindness in the developing countries of the world. This situation is especially true in area where trachoma, onchocerciasis, leprosy and other infections of ocular diseases are endemic^[1]. Because pathogenic mechanisms of fungal keratitis is unknown, it's hard to prevent it. Fungal keratitis can lead to serious complications such as endophthalmitis, perforation and blindness. Fungal keratitis continues to be a therapeutic challenge to ophthalmologists. Different classes of antifungal drugs are used for treatment of fungal keratitis include polyenes, triazoles, and echinocandins^[2]. Of these topical Natamycin 5% has been shown to be effective in fungal keratitis^[3], Natacyn (Alcon Laboratories, Inc.) has been recommended as the topical drug of choice for first-line treatment of filamentous fungal keratitis, and its extensively used in china, but there is no antifungal drug manufactured in china with own intellectual property rights. Our research is to investigate the efficacy of Natamycin, which produced by China Shijiazhuang Pharmaceutical Group company, to provide experimental basis for the application of clinical safety.

Table 1 Ulcer score standards

Grade	Focus of infection	
0	No focus of infection	
1	Corneal infiltrate	1.25 Corneal infiltrate limited in the inoculated area
		1.50 Corneal infiltrate \leq 1/2 corneal thickness
		1.75 Corneal infiltrate $>$ 1/2 corneal thickness
2	Corneal ulcer	2.25 Diameter \leq 3 mm
		2.50 $>$ 3 mm diameter $<$ 5 mm
		2.75 Diameter \geq 5 mm
3	Hypopyon	3.25 Altitude \leq 1/3 corneal thickness
		3.50 $>$ 1/3 corneal thickness altitude $<$ 1/2 corneal thickness
		3.75 Altitude $>$ 1/2 corneal thickness
4	Hypopyon and corneal perforation	

MATERIALS AND METHODS

Materials *Fusarium solani* (NO. 3.5840, Institute of Microbiology, Chinese Academy of Sciences) was grown on potato-dextrose agar (Oxoid, Basingstoke, Hampshire, UK) slants at 35°C for the first 48 hours and at 25°C until day 7^[4]. The formed colonies were covered with 2mL sterile 0.9% saline, and suspended by gently probing them with the tip of a Pasteur pipette. The resulting mixture of conidia, hyphal fragments and agar particles was transferred to a sterile test tube. Heavy particles were allowed to settle for 5 minutes, and the upper homogeneous suspension was collected with a micropipette, transferred to another tube and mixed in a vortex for 15 seconds. The density of the conidial suspension was read in a blood cell counting board and adjusted to an optical density, which corresponds to 1.5×10^6 CFU (colony forming unit)/mL.

Methods

Experimental model Thirty male and female white healthy New Zealand rabbits (0.15-0.2kg), which were obtained from the animal house of the experimental animal center of Hebei Province (Certificate number: 1005202). The rabbits were kept under observation for 72 hours to exclude any local or systemic diseases. Before producing intraocular infection, general anaesthesia was induced in the rabbits by an intramuscular injection of 2mL of phenobarbitone sodium (4mg/mL). After topical anaesthesia was achieved with proparacaine HCl 0.5% (Alcane) then the eye was gently exposed with an eye speculum. A microsyringe (10 μ L, Hamilton) was used to create corneal incision approximately 0.1mm in depth in the right eye of each rabbit. A 10 μ L aliquot of the inoculums, containing 1.5×10^6 *Fusarium solani* was injected into the circular corneal incision in the right eye of the 3 rabbit groups. Forty-eight hours after inoculation, the animals were divided into 3 different treatment groups, 10 rabbit eyes of each group: Group 1 (Natamycin) treated with topical Natamycin hourly (9 am-7 pm) for the first 3 days, and then used Natamycin 8-10 times a day till to 21 days; group 2 (Natacyn) treated with topical Natacyn hourly (9 am-7 pm) for the first 3 days, and then used Natacyn 8-10 times a day till to 21 days; group 3 (control) treated with

topical saline solution hourly (9 am-7 pm) for the first 3 days, and then used saline solution 8-10 times a day till to 21 days;. Cultures were taken from the lesion by scraping 48 h after the inoculation. The eyes of each group was examined and record clinically slit lamp using ulcer scoring system on day 4, 10, 15, and 21 for status of healing, corner vascularisation, iritis, hypopyon and macular nebula were examined and photographic recorded along with on day 10 and day 21.

Ulcer score standards are shown in Table 1.

Statistical Analysis The repeated measurement score data were analyzed using the multivariate analysis of variance. The cure rate and the complication data were analyzed using the Fisher's exact probability. Differences with a first-order error of $P < 0.05$ were considered to be statistically significant. All data analyses were performed with SPSS13.0 statistical package.

RESULTS

Animal Model *Fusarium solani* colonie injection into the cornea of the eyes can be used to establish animal models with fungal keratitis successfully. Two days after inoculated fungus, there were corneal edema, ulceration, dryness, rough, uneven and swelling of the 30 rabbit eyes. The diagnosis of *Fusarium solani* keratitis was confirmed from the cultures of corneal scrapings of the rabbit eye (Figure 1).

Ulcer Score on Day 10, Day 15, Day 21 (Table 2) The score of Natamycin group are 1.45 ± 0.16 , 1.08 ± 0.11 , 0.70 ± 0.40 . The score of Natacyn group are 1.35 ± 0.12 , 1.10 ± 0.12 , 0.65 ± 0.35 . the score of control group are 1.30 ± 0.08 , 3.63 ± 0.28 , 3.80 ± 0.16 . Natamycin group and Natacyn group were different from control group ($P < 0.01$). There is no difference between Natamycin group and Natacyn group ($P > 0.05$).

Status of Healing on Day 10 and Day 21 (Table 3) The cure rate of the Natamycin group is 90% on day 10, and 100% on day 21. The cure rate of the Natacyn group is 80% on day 10, and 100% on day 21. Natamycin group and Natacyn group were different from control group ($P < 0.01$). There is no difference between Natamycin group and Natacyn group ($P > 0.05$).

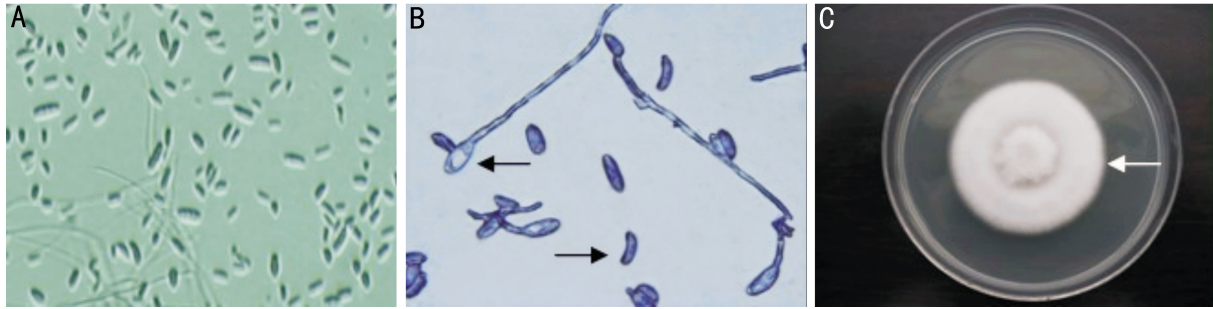


Figure 1 *Fusarium solani* A: KOH smear: The shape of the mature spore were like Sickle, and it was the spore of *Fusarium solani*; B: Giemsa staining: The Mycelium of *Fusarium solani* were budding; C: Cultures were taken from the lesion of cornea, this is the typical *Fusarium solani* colony.

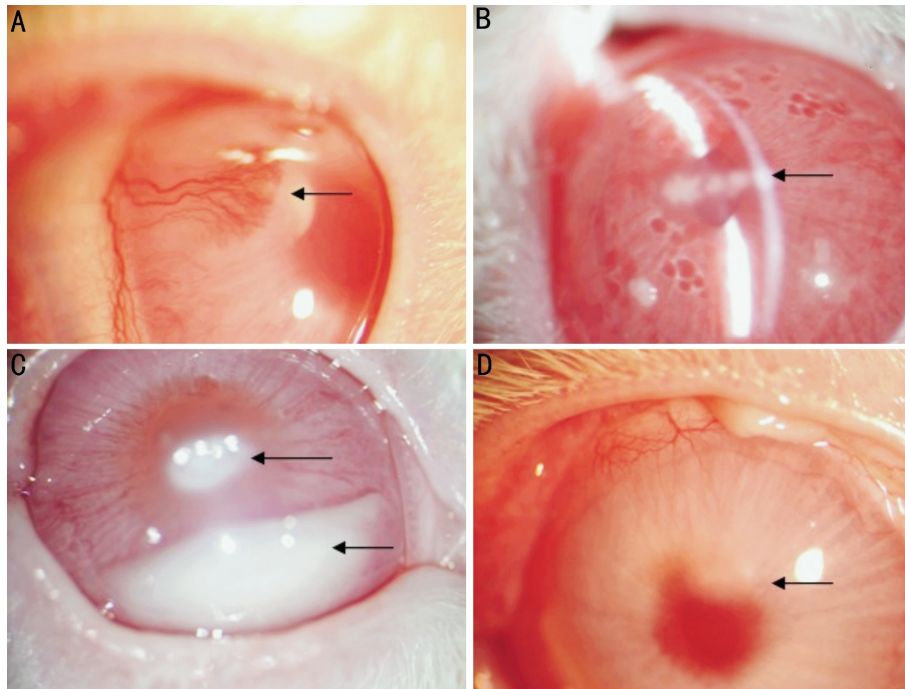


Figure 2 complications A: Corneal new blood vessels; B: Iritis; C: Hypopyon; D: Macular nebula.

Table 2 Influence of natamycin treatment of experimental fungal keratitis in rabbits (n=10, mean±s)

Group	Day 4	Day 10	Day 15	Day 21
Natamycin (1)	1.45±0.16	1.08±0.11	0.70±0.40	0.15±0.24
Natacyn (2)	1.35±0.12	1.10±0.12	0.65±0.35	0.15±0.21
control (3)	1.30±0.08	3.63±0.28	3.80±0.16	3.83±0.18
F	1.293	416.192**	272.886**	511.470**
P(1) : (3)		<0.001	<0.001	<0.001
P(2) : (3)		<0.001	<0.001	<0.001
P(1) : (2)		0.800	0.733	0.688

** P<0.01; $F_{\text{Within group}}=273.963, F_{\text{Between groups}}=955.068, F_{\text{Interactive}}=128.762, P<0.01.$

‘(1)’ indicate Natamycin group. ‘(2)’ indicate Natacyn group. ‘(3)’ indicate control group.

Corner Vascularisation, Iritis, Hypopyon and Macular Nebula on Day 10 and Day 21 (Figure 2, Table 4) In Natamycin group, the number of the eyes which have Corner vascularisation, iritis, hypopyon and macular nebula are 2,0,0,2. In Natacyn group, the number of the eyes which have Corner vascularisation, iritis, hypopyon and macular nebula are 1,0,0,2. In control group, the number of the eyes which have Corner vascularisation, iritis, hypopyon and

macular nebula are 9,9,8,9. Natamycin group and Natacyn group were different from control group ($P<0.01$). There is no difference between Natamycin group and Natacyn group ($P>0.05$).

DISCUSSION

Fungal keratitis primarily affects the corneal epithelium and stroma, although the endothelium and anterior chamber of the eye may get involved in more severe disease. It is most

Antifungal efficacy of natamycin in experimental *Fusarium solani* keratitis

Table 3 Effect of Natamycin treatment with the cure rate of fungal keratitis (n=10)

Group	Day 10		Day 21	
	n(eyes)	Cure rate(%)	n(eyes)	Cure rate(%)
Natamycin (1)	9	90	10	100
Natacyn (2)	8	80	10	100
control (3)	0	0	1	10%
P		<0.001		<0.001
P(1) : (3)		<0.001		<0.001
P(2) : (3)		<0.001		<0.001
P(1) : (2)		0.531		1.000

(1): Natamycin group; (2): Natacyn group; (3): Control group.

Table 4 The influence of Natamycin treatment with complication of fungal keratitis (n=10)

	vascularisation	iritis	Hypopyon	macular nebula
Natamycin (1)	2	0	0	2
Natacyn (2)	1	0	0	2
control (3)	9	9	8	9
P	<0.001	<0.001	<0.001	<0.001
P(1) : (3)	<0.001	<0.001	<0.001	<0.001
P(2) : (3)	<0.001	<0.001	<0.001	<0.001
P(1) : (2)	0.531	1.000	1.000	1.000

(1): Natamycin group; (2): Natacyn group; (3): Control group.

often seen in tropical climates and is rare in temperate areas. Its incidence is between 6%-20% of all microbial keratitis cases depending on the geographic location^[5].

Among suppurative corneal ulcerations, fungal keratitis is responsible for significant ocular morbidity and blindness, primarily in the developing world. It always caused by external injury. For the past few years, the incidence of fungal keratitis has increased quickly. The reason for this is the application of broad-spectrum antibiotic, antitumor drugs, immunosuppressive agents and corticosteroids, and so on. Keratomycosis is the leading cause of ocular morbidity throughout the world and fungi are the principal etiological agents of corneal ulceration.

The activity of Natamycin against yeasts and moulds, but not bacteria, makes it convenient for use in foods that undergo a ripening period after processing. Its low solubility in water and most organic solvents makes it suitable for the surface treatment of foods. Natamycin is used topically in veterinary medicine to treat mycotic infections, such as ringworm in cattle and horses. Previously, it was used topically against fungal infections of the skin and mucous membranes in humans. Its medical use is now confined to topical treatment of corneal fungal infections and the prevention of such infections in contact lens users.

Although the commonly used clinical agents, including

amphotericin B^[6], etoconazole, itraconazole, terbinafine^[7] are efficient^[8], there are different degrees of toxicity to host cells. Therefore, Natamycin eye drops appear to be the first-line drugs in the treatment of fungal keratitis in view of its local and systemic side effects such as kidney toxicity. This is the same as many domestic and international ophthalmic workers^[9].

Natamycin has a broad spectrum of activity against spoilage fungi, although interaction with different environmental factors has not been investigated in detail. It is a very effective antifungal agent as it binds irreversibly to ergosterol, disrupting thus the fungal cell membrane leading to a loss of solutes from the cytoplasm.

Our study demonstrated that the *Fusarium Solani* injection into the cornea of the eyes can be used to establish animal models with fungal keratitis successfully. Natamycin, which is manufactured by China Shijiazhuang Pharmaceutical Group company, was found to be effective in fungal keratitis, as well as Natacyn, and it can stop the corner vascularisation, iritis, hypopyon and macular nebula to happen. As we know, Natacyn comes from American, it is very expensive, and easy to be overdue. So we think Natamycin, from Shijiazhuang Pharmaceutical Group company, china is a kind of effective against fungal keratitis, with easy availability and low toxicity in its use.

REFERENCES

- 1 WHO, *Weekly Epidemiology Record* 1989;64(28):216-217
- 2 Thomas PA. Current perspective in ophthalmic mycosis. *Clin Microbiol Rev* 2003;16(4):730-797
- 3 Tanure MA, Cohen EJ, Sudesh S, Rapuano CJ, Laibson PR. Spectrum of fungal keratitis at Wills Eye Hospital, Philadelphia, Pennsylvania. *Cornea* 2000;19(3):307-312
- 4 Dong XH, Qian T, Gao WJ, He XP. Research of temperature on the growth and spore production of *Fusarium solani*. *J of Microbiol Immunol* 2010;30(9):833-833
- 5 Gopinathan U, Sharma S, Garg P, Rao GN. Review of epidemiological features, microbiological diagnosis and treatment outcome of microbial keratitis: experience of over a decade. *Indian J Ophthalmol* 2009;57(4): 273-279
- 6 Touvron G, Denis D, Doat M, Girard A, Brandely ML, Chast F, Renard G. Successful treatment of resistant *Fusarium solani* keratitis with liposomal amphotericin B. *J Fr Ophthalmol* 2009;32(10):721-726
- 7 Liang QF, Jin XY, Wang XL, Sun XG. Effect of topical application of terbinafine on fungal keratitis. *Chin Med J* 2009;122(16):1884-1888
- 8 Prajna NV, Mascarenhas J, Krishnan T, Reddy PR, Prajna L, Srinivasan M, Vaitilingam CM, Hong KC, Lee SM, McLeod SD, Zegans ME, Porco TC, Lietman TM, Acharya NR. Comparison of natamycin and voriconazole for the treatment of fungal keratitis. *Arch Ophthalmol* 2010;128(6):672-678
- 9 Tuli SS. Fungal keratitis. *Clin Ophthalmol* 2011;5:275-279