

Idiopathic phacodonesis in senile cataract patients in Qinghai, China

Xiao-Wei Liu¹, Zheng Wang², Wei-Hong Yu¹, Zao-Wen Wang¹, Yan-Ning Zhang¹, Jian-Jun Liu³, Rui-Fang Sui¹

Foundation item: Supported by Lifeline Express Hong Kong Foundation, China

¹Department of Ophthalmology, Peking Union Medical College Hospital, Chinese Academy of Medical Sciences & Peking Union Medical College, Beijing 100730, China

²Department of Ophthalmology, Beijing Hospital, Beijing 100730, China

³Department of Anesthesiology, Peking Union Medical College Hospital, Chinese Academy of Medical Sciences & Peking Union Medical College, Beijing 100730, China

Corresponding to: Rui-Fang Sui. Department of Ophthalmology, Peking Union Medical College Hospital, Chinese Academy of Medical Sciences & Peking Union Medical College, Beijing 100730 China. paddyliuxw@hotmail.com

Received:2011-05-03

Accepted:2011-09-10

Abstract

• **AIM:** To investigate the frequency of idiopathic phacodonesis (IP) in senile cataract subjects and the short-term clinical outcomes following cataract surgery.

• **METHODS:** This institutional case-control study included 1301 consecutive low-income cataract subjects from June to November 2009. Anterior segment were carefully evaluated with dilated pupil under slit-lamp. IP were screened and graded by a criteria set by the authors. Risk factors, surgical outcomes, and operative complications were analyzed.

• **RESULTS:** A total of 42 subjects (3.2%) with IP were diagnosed and classified as grade 1 (36 subjects), grade 2 (5 subjects) and grade 3 (1 subject). Harder lenses and intumescent cataracts were observed in the IP group than the control group ($P < 0.05$). Logistics regression test also indicated the main risk factor was the hardness of the lens. The incidence of zonular dialysis during surgery was 23.8% (10 eyes), which was significantly higher than the controls (0.7%, $P < 0.001$). Visual outcomes of the two groups were not statistically or clinically significant.

• **CONCLUSION:** Hard nucleus and intumescent cataract are related to IP in senile cataract subjects in Qinghai, China. With more care being taken, grade 1 and some of the grade 2 IP subjects achieved similar surgical outcomes as compared to controls.

• **KEYWORDS:** phacodonesis; lens nucleus; zonular dialysis

DOI:10.3980/j.issn.2222-3959.2011.05.10

Liu XW, Wang Z, Yu WH, Wang ZW, Zhang YN, Liu JJ, Sui RF. Idiopathic phacodonesis in senile cataract patients in Qinghai, China. *Int J Ophthalmol* 2011;4(5):508-512

INTRODUCTION

Phacodonesis is present if lens trembled upon movement of the eye during slit-lamp examination^[1]. Zonular apparatus is the main support system of human lens, weakness in the zonules could cause instability of the lens, leading to complication during cataract extraction surgery. Phacodonesis is the major sign of weakness of the zonular apparatus^[1,2]. In severe cases, iridodonesis, subluxation or dislocation of the lens could be noted.

While many studies have documented pseudoexfoliation syndrome as a cause of weakness in the zonular apparatus^[3-5], other reports indicated that injury, laser^[6], vitrectomy, glaucoma surgery, glaucoma^[7], uveitis, aging, retinitis pigmentosa^[8], diabetes, Marfan's syndrome^[9], homocystinuria^[10] and Weill-Marchesani syndrome^[11,12] could also weaken the lens apparatus. There remains some phacodonesis cases without known cause^[13].

During the period from June to November 2009, the Chinese Lifeline Express Medical Team, an organization aimed to cure blindness from cataract for the poor, was in Qinghai province. Qinghai is a located in north-east of the Qinghai-Tibet Plateau. Due to high altitude and high ultraviolet radiation intensity, the incidence of age-related cataract is 0.3%. Cataract is the most common cause of blindness and visual impairment among adults. As members of this team, we found some cases of phacodonesis in cataract subjects without the above known causes, so we named this "idiopathic phacodonesis (IP)". We focused on studying the clinical features, risk factors and surgical outcomes of this disease.

For economic and other reasons, the study could only be conducted for a short period, and long-term follow-up was

not possible. Further study on the pathology of IP and long-term evaluation on the surgical outcomes will be published in future reports.

MATERIALS AND METHODS

Materials Subjects for this study were collected from a general ophthalmology practice in a group-model health maintenance organization, Lifeline Express. 1523 low-income cataract subjects were recruited by Qinghai Health Bureau from all districts of Qinghai province. Most of them were of Han ethnicity, (763, 50.1%), other ethnicities included were Hui (239, 15.7%), Sara (181, 11.9%), Tibetans (167, 11.0%), Tu (110, 7.2%), and Mongolians (63, 4.1%) minorities. Detailed past medical history was collected including diabetes, hypertensive disease, ocular trauma, ocular surgery, refractive error and ocular disease.

Methods All subjects underwent a complete ophthalmologic examination including best-corrected visual acuity (BCVA), slit-lamp evaluation of the anterior segment with dilated pupils, detailed fundus assessment, B-mode ultrasound and contact A-scan ultrasound for axial length measurements. Phacodonesis was diagnosed during the preoperative dilated slit-lamp examination by one doctor and confirmed by another. The information of lens nucleus hardness (which was graded by Emery and Little^[14] system), intraocular pressure, retinal pathology, axis length, lens stability and intraoperative complications were recorded immediately. Subjects with pseudoexfoliation, uveitis, diabetes mellitus, ocular trauma, previous ocular surgery, glaucoma, Marfan's syndrome, high myopia and other known disease which could cause lens dislocation were excluded in this study. Also, Morgagnian cataract which could cause the movement of the nucleus alone was excluded.

We established the criteria to grade the IP. Grade 1, phacodonesis could be found by careful slit-lamp examination, without iridodonesis or visible zonular dialysis; Grade 2, phacodonesis could be easily noticed by slit-lamp examination, with or without iridodonesis, also no zonular dialysis noticed; Grade 3, phacodonesis could be easily noticed by slit-lamp examination, accompanied by iridodonesis and zonular dialysis and even dislocation of the lens. According to Lifeline Express policy, only one eye could be operated in this program for each subject, so our study only included the operative eyes.

Surgery was performed mostly using topical anesthesia with a few subjects having retrobulbar anesthesia. Preoperatively, subjects were given 1 drop each of tropicamide 1%, phenylephrine 0.25% (Mydrin-P), oxybuprocaine hydrochloride 0.04% (Benoxil), and repeated every five minutes for four sets. All cases underwent a superior 5.5mm or more scleral pocket incision, 0.06% trypan blue (Aurolab, India) 0.1mL

was injected into the anterior chamber to stain the capsular if necessary and continuous curvilinear capsulorhexis (CCC), hydrodissection, and hydrodelineation followed by phacoemulsification or extracapsular cataract extraction (ECCE) was performed depending on the the hardness of nucleus classification. (Nucleus hardness in all eyes was classified as grade 1-5. Grades 4 and 5 were considered as hard nucleus in this article). After aspiration of the cortex, a PMMA (polymethyl methacrylate, Eye Good Medical Co. Ltd, Zhuhai, China) intraocular lens was implanted into the capsular bag. Anterior vitrectomy was performed when the posterior capsular was compromised and vitreous loss occurred. All operations were performed by two experienced ophthalmologists (W.H.Y & X.W.L). Due to the financial reason, majority of the subjects could be only accommodated and followed-up by our team for 3-7 days, Limited long-term follow-up information could be obtained from local health bureau. To evaluate the zonular apparatus, some of the subjects who were available and lived close to the train were evaluated by ultrasound biomicroscopy (UBM, Suwei Electronic Technology. Co. Ltd. China) preoperatively and 4 weeks postoperatively.

Statistical Analysis Data were analyzed with SPSS 13.0 data processor for Windows. Means and standard deviations were used to compare age, axial length, and anterior chamber depth. Pearson chi-square tests were used to compare the baseline categorical characteristics and incidence of intraoperative complications between subjects with and without IP. A logistic regression model for multiple analyses subsequently was used. A *P*-value of less than 0.05 was considered statistically significant.

RESULTS

Total subjects included in this study were 1301. The mean age of subjects with idiopathic phacodonesis (IP) was 67.4±9.8 years (range 40 to 84 years, 82 eyes of 42 subjects), including 18 males (42.9%) and 24 females (57.1%). The mean age of subjects without phacodonesis (the controls) was 66.4±10.1 years (range 41-91 years, 1259 eyes of 1259 subjects), including 584 males (46.4%) and 675 females (53.6%). The preoperative BCVA ranged from light perception to 0.3 on the Snellen Chart. Phacodonesis was observed bilaterally except in two subjects, one with dense corneal opacity and the other who had undergone remote enucleation in the other eyes. There were no significant differences in phacodonesis between the right eyes and the left eyes in all subjects (two independent samples tests, Mann-Whitney U test $Z = -0.388$, $P = 0.698$). Only the 42 operated eyes were included in this study.

In our study, we identified 36 eyes with grade 1 phacodonesis, and 5 eyes with grade 2, 1 eye with grade 3.

IP in senile cataract subjects

There was no difference between the mean age of the IP subjects and the controls ($t=0.61$, $P=0.54$). Neither did the mean axial length between the two groups differ ($23.59\pm 2.43\text{mm}$ in IP group & $23.50\pm 2.33\text{mm}$ in control group, $t=0.25$, $P=0.80$). More eyes had harder nucleus (grade 4-5) in the IP group than those in the control group (Pearson chi-square test, $\chi^2=7.26$, $P=0.007$). In addition, more intumescent but not mature or hypermature cataract was observed in the IP group (Pearson Chi-square test, $\chi^2=38.90$, $P<0.001$, Table 1).

We identified several risk factors that may be associated with IP, including: age, sex, IOP, the depth of the anterior chamber, axial length, hardness of the lens nucleus, diabetes and cardiovascular diseases. We tested all these risk factors using logistic regression, which showed hardness of lens as the main risk factor ($\chi^2=6,846$, $P=0.011$) associated with IP, and the logistic regression equation was $\text{logit } P = -4.238 + 0.234X_1$. With an increase in lens hardness grade by one, the relative risk increases 1.28 times.

Zonular dialysis was found intraoperatively in 10 eyes (10/42, 23.8%) and one of them (1/42, 2.4%) developed vitreous loss during surgical procedure in the IP group. Up to 3 clock-hours of zonular dialysis occurred in 6 eyes (6/10, 60%, 4 eyes with grade I IP, 2 eyes with grade 2 IP); up to 6 clock-hours of zonular dialysis was observed in 2 cases (2/10, 20%, 1 eye was grade 1 IP, 1 eye was grade 2 IP); more than 6 clock-hours of zonular dialysis was seen in 2 cases (2/10 20%, one was grade 2 IP, and the other was grade 3), one of them with vitreous loss had anterior vitrectomy and no IOL implanted due to poor cooperation, the other without vitreous loss had scleral fixated IOL. Most common site of zonular dialysis was found in the inferotemporal or inferonasal quadrants (7 eyes), and a few were encountered in the superior quadrants (2 eyes). In control group, 9 eyes (0.72%) were found to have zonular dialysis. There was a significant difference in the incidence of zonular dialysis between the IP group and control group (Pearson Chi-square test, $\chi^2=8.37$, $P<0.0001$, Table 2).

Phacoemulsification was performed in 812 subjects in the control group, and 19 in the IP group. ECCE was performed in 447 subjects in the control group and 23 in the IP group. In the IP group, 2 cases of zonular dialysis occurred with phacoemulsification, but 8 cases when ECCE was performed (Pearson Chi-square test, $\chi^2=3.38$, $P=0.066$), in control group, 1 case with phacoemulsification and 8 with ECCE (Pearson Chi-square test, $\chi^2=11.28$, $P=0.001$, Table 3).

Follow-up period was limited to 3-7 days. IOL dislocation was not observed in any subjects. Postoperative BCVA

Table 1 Distribution of nucleus hardness grades and intumescent cataract in the IP subjects and the controls *n*

	Nucleus grade		Cortex	
	1-3	4-5	Non-intumescent	Intumescent
IP	16	26	27	15
control	517	742	1249	100
χ^2	7.26 ^a		38.90 ^b	

^a Pearson Chi-squared test, $P=0.007$ ^b Pearson Chi-squared test, $P<0.001$

Table 2 Intraoperative complications of the IP and control groups *n*

Complication /IOL	IP (n=42)			Total	Control (n=1249)
	Grade1 n=36	Grade 2 n=5	Grade3 n=1		
ZD ^a	5	4	1	10	9
3 CHs ZD	4	2	0	7	8
6 CHs ZD	1	1	0	2	1
>6CHs ZD	0	1	1	2	0
Vitreous loss	0	0	1	1	3
Capsule rapture	0	1		1	4
Suture fixed IOL	0	1	0	1	2

ZD= zonular dialysis CHs= clock-hours ^a Pearson Chi-square test, $\chi^2=8.37$, $P<0.001$

Table 3 Zonular dialysis in ECCE and phacoemulsification procedure *n*

	IP (n=42)		Control (n=1459)	
	PE	ECCE	PE	ECCE
ZD	2	8	1	8
No ZD	17	15	811	439
Total	19	23	812	447
χ^2	3.38		11.28	
<i>P</i>	0.066		0.001	

significantly improved from baseline, except in one subject whose BCVA remained at counting finger due to advanced age-related macular degeneration. There was no significant difference in the BCVA improvement between the 2 groups. Ultrasound biomicroscopy (UBM) was used to evaluate the zonular apparatus of 12 IP subjects and 23 controls who were available pre- and post-operation. Cross-sectional zonular UBM images were obtained circumferentially at eight evenly spaced locations.

UBM showed that grade 1 IP subjects' zonular apparatus appeared similar to controls (Figure 1); however, in some of the grade 2 IP subjects, the zonules were uneven, slack or elongated compared with the controls. And there is a gap between the iris and the lens, which could be a reason for phacodonesis and iridodonesis (Figure 2). After phacoemulsification, phacodonesis of the IOL became more pronounced, the gap between the lens and iris became larger than in preoperative images (Figure 3). In grade 3 eyes, the dialysis of the zonules and the dislocation of the lens were easily observed (Figure 4).

Transient postoperative high IOP was found in 3 cases of IP subjects, but all resolved within 3 days.

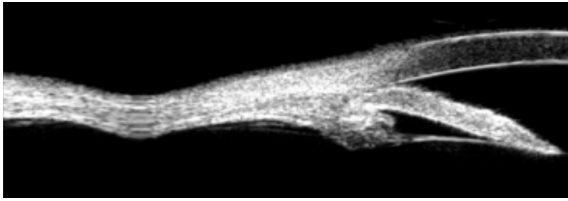


Figure 1 Grade 1 IP patient, the images of the zonules was as normal as normal zonular images, the iris and the lens were contact

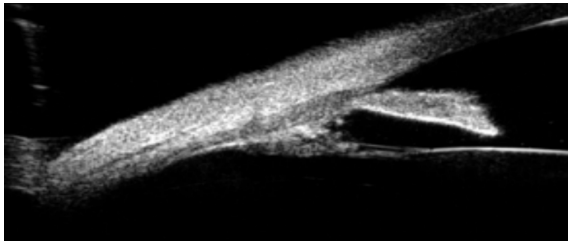


Figure 2 Grade 2 IP (the only one without intraoperative zonular dialysis), which showed the separation of the iris and the lens, although the zonular seemed as normal as that of the controls

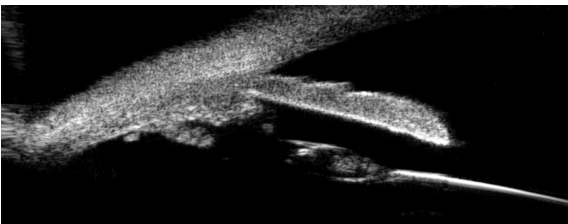


Figure 3 The same eye of Figure 2, postoperative zonules image, showed bigger gap between the iris and the lens, tensionless and lengthened of the zonules

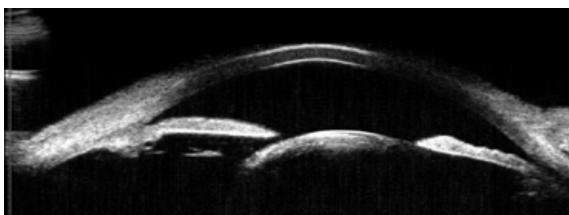


Figure 4 A grade 3 IP eye, which showed dialysis of the zonles and dislocation of the lens

DISCUSSION

In 1970, Bartholomew ^[1] reported 7 cases (9 eyes) of phacodonesis after investigation of 300 cataract eyes and the fellow eyes of 195 subjects with displacement of the lens. Six of them were attributed to pseudoexfoliation, only one case was thought to be idiopathic phacodonesis. He assumed that phacodonesis was the transitory stage before complete lens dislocation. The prevalence of IP has not been reported in literature, the 3.2% prevalence in our study is among the selected cataract elder subjects in Qinghai province, including several ethnic groups. To determine the general prevalence, further studies are needed. Due to the small number in the IP group, we could not implicate if there is an

ethnic or sexual predilection for IP.

In the literature, phacodonesis and dislocation of lens are mostly associated with pseudoexfoliation. In our study, most of the known risks to phacodonesis were excluded, the reason of instability of the lens is still not clear, so we named this sign "idiopathic phacodonesis" (IP). No poor papillary dilation was observed in the IP subjects, a sign commonly seen in pseudoexfoliation syndrome ^[15,16].

The reason for weakness of the zonules remains unclear, but we found that hardness of the lens was one of the major risk factors, which should also be related to the age of the subject. But in our study, the relationship between IP and age was not significant. The authors presumed that is due to the small sample size of subjects with IP. Although intumescent cataract is not a risk factor for IP in logistics regression test in our study, the rates of intumescent cataract subjects in IP group was significantly higher than in the control group, so we still considered intumescent cataract to be closely related to IP. No difference was found in axial length or anterior chamber depth between the two groups. We hypothesize that hard nucleus and intumescent cataract could cause degeneration of the zonular apparatus, this will need pathological studies to confirm.

With UBM examinations, no abnormal image was observed in preoperative and uneventful surgery grade 1 IP eyes. However, in the grade 2 subjects, even though the preoperative zonules image appeared "normal", some of the eyes showed non-contact of the lens and the iris, some of the eyes showed the elongated zonules. In postoperative images, there was discontinuity of the zonules, which could be due to damage of zonules during surgery.

Shingleton ^[17] found that 60% of subjects with zonular weakness confirmed by phacodonesis developed vitreous loss during surgery. Artzen *et al* ^[4] reported phacodonesis was significantly associated with capsular complication during cataract surgery. In our study, we also found that the IP subjects more frequently suffered from zonular dialysis (26.2%) during cataract surgery than the control group (0.7%). The more severe the phacodonesis was, the more likely for zonular dialysis occurred during cataract surgery. Most of the zonular rupture in surgery occurred in the inferonasal or inferotemporal quadrants of eye, which is probably due to increased stress to inferior zonules during phacoemulsification or ECCE. With surgical tools such as capsular tension rings ^[18,19] or surgical technique such as scleral-fixation IOL by experienced surgeons, most of the phacodonesis subjects could achieve good postoperative visual outcome ^[16]. In our study, capsular tension ring was not available, so for some subjects we performed scleral-fixated IOL implantation.

In this study, we found modern phacoemulsification could be safer for zonules than the ECCE in both IP (although not significant) and the controls. Katsimpris *et al*^[20] also believe that phacoemulsification induces less stress on the zonules than ECCE. But, in our study, most ECCE surgeries were performed on brunescant and white cataracts which would be of challenge with either phacoemulsification or ECCE techniques^[21].

Jehan *et al*^[22] reported 8 of pseudoexfoliation eyes with late spontaneous intraocular lens dislocation 57-115 months after uneventful phacoemulsification in pseudoexfoliation syndrome. However, Nagashima^[15] reported 67 eyes with pseudoexfoliation who had phacoemulsification, after a mean follow up of 54.1 months, no IOL dislocation was noted. For our subjects, we were not able to perform long-term follow-up, and some medical information can be obtained from the local health bureau which may provide further information related to long term surgical outcomes.

Phacodonesis in these subjects may be due to zonular degeneration, which was confirmed preoperatively by UBM and/or during surgery. Although only a small part of our subjects were available for UBM evaluation of their zonular apparatus, we still identified some clues of zonular fragility, such as: large gap between the iris and the lens, elongated and laxity of the zonules and even rupture of the zonules. To gain more detailed information by UBM, further study should be carried out.

As a sign of incipient lens dislocation, phacodonesis is significant and its recognition may be taken as an indication for lens extraction before actual dislocation, which can make surgery more challenging. If surgery is to be performed, utmost care should be taken to prevent uncontrolled lens displacement and possible vitreous loss, and these subjects should be operated on by experienced surgeons. Surgery procedure could be as safe as in controls when only mild phacodonesis (grade 1) is identified, but complication rate is significantly increased in advanced phacodonesis (grade 2 and grade 3).

Acknowledgments:The authors thank Dr. Lan Chang for editorial assistance. Many thank Dr. Jinlian Zhu, Dr. Ai Guo, and Lifeline Express officers and Qinghai Health Bureau officers for help in coordinating subject recruitment and schedules. Thanks to Dr. Gangwei Chen for his expertise in UBM.

REFERENCES

1 Bartholomew RS. Phacodonesis. A sign of incipient lens displacement. *Br J Ophthalmol* 1970; 54:663-666
 2 Scherer M, Bertelmann E, Rieck P. Late spontaneous in-the-bag intraocular lens and capsular tension ring dislocation in pseudoexfoliation syndrome. *J Cataract Refract Surg* 2006; 32:672-675

3 Skuta GL, Parrish RK, 2nd, Hodapp E, Forster RK, Rockwood EJ. Zonular dialysis during extracapsular cataract extraction in pseudoexfoliation syndrome. *Arch Ophthalmol* 1987; 105:632-634
 4 Artzen D, Lundstrom M, Behndig A, Stenevi U, Lydahl E, Montan P. Capsule complication during cataract surgery: Case-control study of preoperative and intraoperative risk factors: Swedish Capsule Rupture Study Group report 2. *J Cataract Refract Surg* 2009;35:1688-1693
 5 Drolsum L, Ringvold A, Nicolaiassen B. Cataract and glaucoma surgery in pseudoexfoliation syndrome: a review. *Acta Ophthalmol Scand* 2007;85:810-821
 6 Seong M, Kim MJ, Tchah H. Argon laser iridotomy as a possible cause of anterior dislocation of a crystalline lens. *J Cataract Refract Surg* 2009;190-192
 7 Yang J, Lu Y, Luo Y, Wang L. Clinical efficacy of management of zonular abnormalities with capsular tension ring: a two-year follow-up study. *Zhonghua Yanke Zazhi* 2007;43:519-524
 8 Lee HJ, Min SH, Kim TY. Bilateral spontaneous dislocation of intraocular lenses within the capsular bag in a retinitis pigmentosa patient. *Korean J Ophthalmol* 2004;18:52-57
 9 Doyle A, Hamard P, Puech M, Lachkar Y. Asymmetric pigmentary glaucoma in a patient with Marfan's syndrome. *Graefes Arch Clin Exp Ophthalmol* 2005;243: 955-957
 10 Mulvihill A, O'Keeffe M, Yap S, Naughten E, Howard P, Lanigan B. Ocular axial length in homocystinuria patients with and without ocular changes: effects of early treatment and biochemical control. *J Aapos* 2004;8:254-258
 11 Jethani J, Mishra A, Shetty S, Vijayalakshmi P. Weill-Marchesani syndrome associated with retinitis pigmentosa. *Indian J Ophthalmol* 2007;55:142-143
 12 Burakgazi AZ, Ozbek Z, Rapuano CJ, Rhee DJ. Long-term complications of iris-claw phakic intraocular lens implantation in Weill-Marchesani syndrome. *Cornea* 2006;25:361-363
 13 Moreno-Montanes J, Sainz C, Maldonado MJ. Intraoperative and postoperative complications of Cionni endocapsular ring implantation. *J Cataract Refract Surg* 2003;29:492-497
 14 Emery JM Little JH. Phacoemulsification and aspiration of cataract: surgical techniques, complications, and results. Mosby 1979:179-202
 15 Nagashima RJ. Decreased incidence of capsule complications and vitreous loss during phacoemulsification in eyes with pseudoexfoliation syndrome. *J Cataract Refract Surg* 2004;30:127-131
 16 Susic N, Kalauz-Surac I, Brajkovic J. Phacoemulsification in pseudoexfoliation (PEX) syndrome. *Acta Clin Croat* 2008;47:87-89
 17 Shingleton BJ, Heltzer J, O'Donoghue MW. Outcomes of phacoemulsification in patients with and without pseudoexfoliation syndrome. *J Cataract Refract Surg* 2003;29:1080-1086
 18 Takimoto M, Hayashi K, Hayashi H. Effect of a capsular tension ring on prevention of intraocular lens decentration and tilt and on anterior capsule contraction after cataract surgery. *Jpn J Ophthalmol* 2008;52:363-367
 19 Marques DM, Marques FF, Cionni RJ, Osher RH, Freitas LL. Evaluation of the modified capsular tension ring in cases of traumatic lens subluxation. *Arq Bras Oftalmol* 2007;70:746-751
 20 Katsimpris JM, Petropoulos IK, Apostolakis K, Feretis D. Comparing phacoemulsification and extracapsular cataract extraction in eyes with pseudoexfoliation syndrome, small pupil, and phacodonesis. *Klin Monbl Augenheilkd* 2004;221:328-333
 21 Narendran N, Jaycock P, Johnston RL, Taylor H, Adams M, Tole DM, Asaria RH, Galloway P, Sparrow JM. The Cataract National Dataset electronic multicentre audit of 55,567 operations: risk stratification for posterior capsule rupture and vitreous loss. *Eye (Lond)* 2009;23:31-37
 22 Jehan FS, Mamalis N, Crandall AS. Spontaneous late dislocation of intraocular lens within the capsular bag in pseudoexfoliation patients. *Ophthalmology* 2001; 108:1727-1731