

# Capsule contraction syndrome in Behcet's disease

*Ayşe Gül Koçak Altıntaş<sup>1</sup>, Derya Dal<sup>2</sup>*

<sup>1</sup> Ulucanlar Training and Research Hospital, Ulucanlar Cad. No:59 Ankara, Turkey

<sup>2</sup> Diyarbakır Training and Research Hospital, Elazığ Yolu Üzeri Üçkuyular Mevkii Diyarbakır, Turkey

**Correspondence to:** Derya Dal. Diyarbakır Training and Research Hospital, Elazığ Yolu Üzeri Üçkuyular Mevkii Diyarbakır, Turkey. deryadal@yahoo.com

Received:2010-10-12 Accepted:2010-11-28

## Abstract

• We reported the case of a 39-year-old patient with inactive Behcet's syndrome developed capsule contraction syndrome after uneventful phacoemulsification and a foldable intraocular lens implantation. Two weeks after the operation, the patient was accepted to hospital with severe decrease of visual acuity (VA) on the operated eye. Capsule opening area had been reduced considerably by fibrotic tissue, which evaluated with full dilated pupil. Since capsule contraction syndrome (CCS) had been diagnosed in very early stage and which structure was not severely thick, the fibrotic band was treated successfully, 360 degree circular shape, by neodymium YAG (Nd:YAG) laser. Capsule opening area was remained stable during follow up period of one month. But a significant reocclusion was developed that need surgical reopening 3 months after initial operation. Continuous curvilinear capsulorhexis (CCC) may be recurred again after a successful treatment in patient with uveitis like Behcet's disease.

• **KEYWORDS:** capsule contraction syndrome; Behcet's syndrome; Nd:YAG laser

DOI:10.3980/j.issn.2222-3959.2010.04.20

Altıntaş AGK, Dal D. Capsule contraction syndrome in Behcet's disease. *Int J Ophthalmol* 2010;3(4):358–360

## INTRODUCTION

Lens epithelial cells (LECs) on the inner surface of continuous curvilinear capsulorhexis (CCC) can undergo fibrous metaplasia, resulting in anterior capsule contraction and shrinkage of capsulorhexis [1,2]. This proliferation can lead to intraocular lens (IOL) decentration, impairment of visual function due to opacification of the anterior capsule up to complete occlusion of capsular opening [1,2]. Capsule contraction syndrome (CCS) has been associated with conditions including uveitis, pseudo-

exfoliation syndrome, advanced age, myotonic dystrophy, retinitis pigmentosa [1-4].

CCS has been reported several weeks to months postoperatively, mainly 3 or more months after operation [4].

To the best of our knowledge, ours is the first report of patient with Behcet's syndrome who also had the earliest complete occlusion of the anterior capsule opening and developed a significant secondary occlusion which needed surgical capsulectomy after initially treated by YAG capsulotomy in the literature.

## CASE REPORT

A 39 year old man with Behcet's syndrome underwent per cataract surgery in his left eye (LE). He had history of recurrent both anterior and posterior uveitis in his both eyes without not any uveitic episode for more than 6 months without treatment. He had not any uveitic episode for more than 6 months without treatment.

Best corrected visual acuity (BCVA) was finger counting in one meter in the right eye (RE) and finger counting in 75 cm in the LE. Slit lamp biomicroscopy of the both eyes disclosed pigmented keratic precipitates, significant posterior subcapsular cataract and posterior synechiaes in anterior segments. The cataract in the LE was significantly dense. Scars of laser photocoagulations and cystoid macular edema (CME) were observed in the RE while it was not clearly seen in the LE due to severe cataract.

To prevent postoperative inflammatory response patient received topical steroids (prednisolone asetate 4x1) for one week prior to surgery. During the operation after synechiolysis and pupil stretching, a 5.5mm diameter of CCC was created. Nucleus and cortex was completely removed and the posterior face of the anterior capsule polished using irrigation-aspiration. A foldable hydrophilic acrylic (IOL) (Ocuflex; Polymer Technologies International; India) was inserted in the bag. A subconjunctival antibiotic and steroid combination was given at the end of surgery.

Postoperatively topical fluoroquinilone (Lomefloxacin Hydrochloride 3g/L) and dexamethasone 1g/L eye drops were given 5 times a day and tropicamide once a day for one week. The antibiotic was stopped after first week, both topical steroids and tropicamide continued during first month of follow-up.

The postoperative course for first week was uneventful

without any inflammation. BCVA on the sixth postoperative day was finger counting in two meters. The limited improvement in VA was attributed to the CME which were not clearly observed in preoperative period.

Ten days later, BCVA was dropped to perception of hand motion due to capsule fibrosis with obstruction of the visual axis (Figure 1). The patient was still using both topical steroid and tropicamide regularly.

Nd:YAG laser anterior capsulotomy was performed. Initial laser incisions were started at the previous CCC opening marks and subsequently 360° circular anterior capsulotomy was completed. The first and the last incisions were joined at the resulting free flap was allowed to fall into the anterior chamber. Patient was given topical antiglaucomatous drops, steroids for hourly and topical cyclopentolate 3 times daily. One week later, BCVA was finger counting in 1m which was the same as postoperative first week. Topical antiglaucomatous treatment and cyclopentolate were stopped one week after Nd:YAG laser capsulotomy and topical steroids was continued but progressively reduced. Six months after the YAG capsulotomy BCVA was the same, IOL remained stable, anterior capsule opening was present, but peripheral fibrotic area that cause rolling the superior haptic over the peripheral part of optic was persisting and VA to light perception. The anterior capsule opening was completely occluded by a fibrotic, wrinkled tissue (Figure 1). This secondary fibrotic membrane was so thick that was needed to be surgically removed. First the membrane was puncture and viscoelastic device was injected through this hole to separate it from IOL. Multiple radial cuts were made by band scissors (Figure 2). Because of significant thickness, the membrane could not be removed like a capsulorhexis. Therefore, vitrectorhexis was prepared so the opening was mechanically widened by vitrectomy(Figure 3). The following day the VA improved to 2 meters with no anterior chamber reaction. The patient received topical antibiotic and steroid 4x1 for a week, and steroid continued for one month. The last examination one year after surgery found no shrinkage of capsular opening and anterior chamber reaction (Figure 4).

#### DISCUSSION

CCS is mainly associated with uveitis, pseudoexfoliation syndrome, advanced age etc. Residual LECs which undergo fibrous metaplasia are responsible for the shrinkage and closure of the capsulorhexis [5-7]. Nishi *et al* [8] published a significant reduction in postoperative inflammation when LECs are removed during surgery as we did in our patient. It is found that the fibrous metaplasia is caused by cytokines produced by the epithelial cells. Interleukin-1 (IL 1) and Interleukin 6 (IL 6) which are found in human following cataract extraction and IOL implantation[7,9].

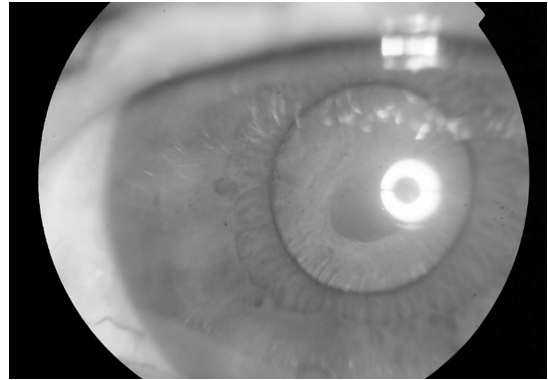


Figure 1 Capsule fibrosis with obstruction of the visual axis

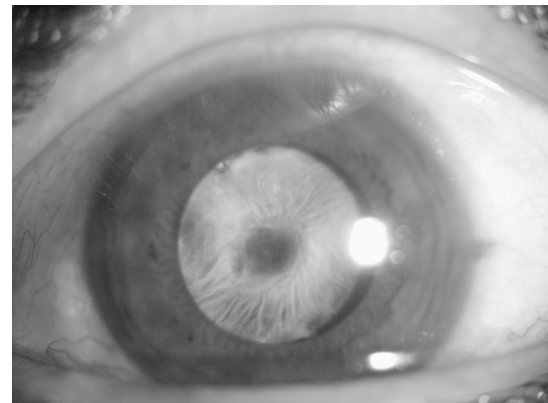


Figure 2 Completely occlusion by a thick fibrotic tissue of CCC opening

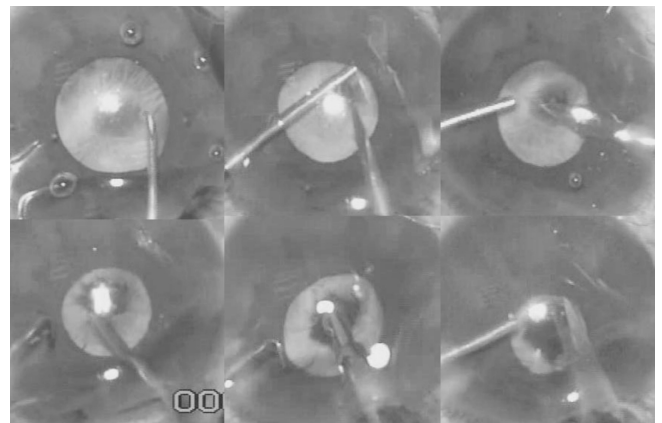


Figure 3 Removing surgically of thick membrane



Figure 4 Postoperative first year appearance

Uveitis, with in which have already impaired the blood aqueous barrier have increased cytokines. Therefore exposing the LECs to cytokine activity triggering the more significant CCS due to fibrous metaplasia as we observed in our patient even given subconjunctival steroid immediately after surgery and using topical steroids postoperatively to prevent more impairment the blood-aqueous barrier.

Behcet's disease is a systemic inflammatory disease of unclear origin which typically affects young men from the eastern Mediterranean region as our patient. Eye involvement in Behcet's disease is characterized with both anterior and posterior uveitis, vitritis, retinitis and occlusive retinal vasculitis. Our patient had signs and sequels of both anterior and posterior previous uveitis such as posterior synechia, macular pucker, retinal vasculitis etc. But because of steroid treatment although not evaluated by a flare cell meter we did not observed any inflammatory reaction and recurrence of uveitis either segments both early postop period, prior the first occlusion and before reocclusion after Nd:YAG capsulotomy. So that we think CCS in uveitic patient is not directly related to increased clinically inflammation.

A higher rate of CCS has been reported in eyes with silicon lens or PMMA and plate haptic lenses than acrylic lens<sup>[3,8,9]</sup>. Therefore we preferred acrylic lenses.

Joo *et al*<sup>[9]</sup> found less anterior capsule contraction in eyes with the CCC diameter was larger than 5.5mm as we performed in our patient.

Hayashi *et al*<sup>[10]</sup> reported stability of CCC at 3 months. Cochener *et al*<sup>[11]</sup> determined a intense contraction during first post op period which continuously progress 150 days postoperatively. Luke *et al*<sup>[3]</sup> reported CCS in two cases age of 58 years and 77 years with uveitis in postoperative 5<sup>th</sup> and 7<sup>th</sup> weeks respectively both of which were earlier than other reports in the literature. According to Luke *et al*<sup>[3]</sup> observation it may say the earlier the age the earlier the CCS. As far as we know, our case is both the earliest report in which capsule closure was observed 2<sup>nd</sup> week postoperatively and recurrent closure after Nd:YAG capsulotomy. Because of being earlier period, even the fibrous band strong enough to pull the haptic to over optic, we performed capsulotomy by Nd:YAG laser successfully. But secondary fibrous proliferation was significantly thicker, that had undergone surgery.

Even though it is recommended that in patients with history of uveitis, intraoperative LEC removal, performing on appropriately sized CCC and precise selection of IOL material and style to help preventing CCS, we observed very early and significant closure of anterior capsule opening and secondary closure after Nd:YAG laser capsulotomy which was thicker than the first one.

According to our observation that the earliest closure of CCC and secondary closure after successful treatment we recommend close follow-up in eyes even without significant postoperative inflammation but with history of uveitis such as Behcet's disease. Using topical steroids in patient with uveitis may not significantly prevent the increasing of cytokines, which aggravate residual LECs proliferation and fibrous contraction. Therefore, systemic steroids may be given postoperatively in addition to topical steroids, in patient even without episodes of uveitis preoperatively, would be a preventive measure.

#### REFERENCES

- 1 Sudhir RR, Rao SK. Capsulorhexis phimosis in retinitis pigmentosa despite capsular tension ring implantation. *J Cataract Refract Surg* 2001;27(10):1691-1694
- 2 Faschinger CW, Eckhardt M. Complete capsulorhexis opening occlusion despite capsular tension ring implantation. *J Cataract Refract Surg* 1999;25(7):1013-1015
- 3 Luke C, Dietlein TS, Jacobi PC, Konen W, Kriegelstein GK. Massive anterior capsule shrinkage after plate-haptic silicone lens implantation in uveitis. *J Cataract Refract Surg* 2001;27(2):333-336
- 4 Altintas AG, Dal D, Simsek S. Significant intraocular lens folding due to severe capsular contraction. *Jpn J Ophthalmol* 2008;52(2):134-136
- 5 Spang KM, Rohrbach JM, Weidle EG. Complete occlusion of the anterior capsular opening after intact capsulorhexis: clinicopathologic correlation. *Am J Ophthalmol* 1999;127(3):343-345
- 6 Waheed K, Eleftheriadis H, Liu C. Anterior capsular phimosis in eyes with a capsular tension ring. *J Cataract Refract Surg* 2001;27(10):1688-1690
- 7 Nishi O, Nishi K. Intraocular lens encapsulation by shrinkage of the capsulorhexis opening. *J Cataract Refract Surg* 1993;19(4):544-549
- 8 Nishi O, Nishi K. Disruption of the blood-aqueous barrier by residual lens epithelial cells after intraocular lens implantation. *Ophthalmic Surg* 1992;23(5):325-329
- 9 Joo CK, Shin JA, Kim JH. Capsular opening contracture after continuous curvilinear capsulorhexis and intraocular lens implantation. *J Cataract Refract Surg* 1996;22(5):585-590
- 10 Hayashi K, Hayashi H, Nakao F, Hayashi F. Reduction in the area of the anterior capsule opening after polymethylmethacrylate, silicone, and soft acrylic intraocular lens implantation. *Am J Ophthalmol* 1997;123(4):441-447
- 11 Cochener B, Jacq PL, Colin J. Capsule contraction after continuous curvilinear capsulorhexis: poly (methyl methacrylate) versus silicone intraocular lenses. *J Cataract Refract Surg* 1999;25(10):1362-1369