

Management of moderate-to-severe Marcus-Gunn syndrome by anastomosis of levator and frontal muscles

Nan Xiang, Wei-Kun Hu, Bin Li, Rong Liu

Foundation item: Independent Innovation Research Foundation of Huazhong University of Science and Technology, China (No. 2010JC010)

Department of Ophthalmology, Tongji Hospital, Huazhong University of Science and Technology, Wuhan 430023, Hubei Province, China

Correspondence to: Rong Liu. Department of Ophthalmology, Tongji Hospital, Huazhong University of Science and Technology, Wuhan 430023, Hubei Province, China. hongnam2@vip.163.com
Received:2010-10-19 Accepted:2010-11-18

Abstract

- **AIM:** To study the effect of clinical management of moderate-to-severe Marcus-Gunn syndrome (MGS) by anastomosis of levator and frontal muscles.
- **METHODS:** The medical records of 13 patients with moderate-to-severe MGS who underwent surgeries in our institute between 2000 and 2007 were reviewed retrospectively. They underwent unilateral anastomosis of levator and frontal muscles under local anesthesia.
- **RESULTS:** Postoperative follow-up periods ranged from 6 to 36 months, with an average of 12 months. All eyelids (100%) showed complete resolution of jaw-winking, ten eyelids (76.9%) had good correction of ptosis, with equal palpebral apertures and symmetrical contours, three (23.1%) showed residual mild ptosis (<2mm).
- **CONCLUSION:** For moderate-to-severe MGS, unilateral anastomosis of levator and frontal muscles provides satisfied correction of jaw-winking and ptosis.
- **KEYWORDS:** Marcus-Gunn syndrome; jaw-winking; ptosis; anastomosis

DOI:10.3980/j.issn.2222-3959.2010.04.15

Liu R, Hu WK, Li B, Xiang N. Management of moderate-to-severe Marcus-Gunn syndrome by anastomosis of levator and frontal muscles. *Int J Ophthalmol* 2010;3(4):342-345

INTRODUCTION

Marcus-Gunn syndrome (MGS), described by Gunn in 1883, is an unusual type of congenital ptosis^[1]. The upper eyelid ptosis when the mouth is open or the mandible is moved forward towards the unaffected side, synkinetic

lifting of the affected eyelid occurs. Etiopathogenesis of the phenomenon is not well defined, the likely underlying mechanism is that of a branch of the 5th cranial nerve being congenitally misdirected into the site of the 3rd cranial nerve supplying the levator muscle^[2]. The aim of surgical treatment is to eliminate synkinetic eyelid movement and correct the ptosis. For moderate-to-severe jaw-winking, obliteration of the levator function followed by frontalis suspension using facia has been considered a good choice^[3,4], but the method is restricted by the resource of facia in some areas. Anastomosis of levator and frontal muscles doesn't have such problem, however, it has not been well reported. We present the results of this method of relieving MGS in this paper.

MATERIALS AND METHODS

From 2000 to 2007, 13 patients for MGS were treated in the Ophthalmology Department of Tongji Hospital. Patients were aged from 16-32 years with mean age 19.4 years old. Five were female and eight were male. MGS was diagnosed unilaterally (left side affected in five, right side in eight). Two patients with strabismus, one with hypotropia combined with superior rectus weakness, the other with congenital hypertropia and exotropia in the unaffected eye, underwent no strabismus surgery because they desired ptosis correction first (Figure 1).

Patients received anastomosis of levator and frontal muscles under local anesthesia of equal parts 20g/L lignocaine with 1:100,000 adrenaline and 5g/L bupivacaine. The first step was levator transection. After a lid crease incision, the orbicularis muscle was dissected to identify the orbital septum. The

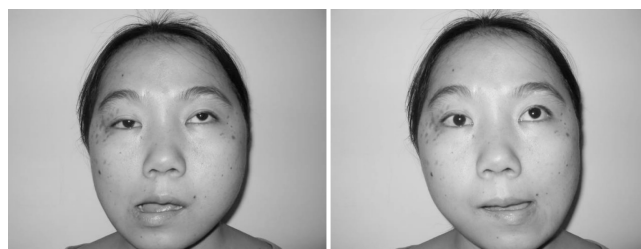


Figure 1 Patient with MGS had right eye ptosis when jaw moving to the right while ptosis disappeared when jaw moving to the left side. The patient had congenital hypertropia and exotropia in the unaffected eye

Table 1 Collective data for patients

Patient number(n)	Sex	Age(yr)	JW (mm)	Ptosis (mm)	LF	PFS pre (mm)		PFS post (mm)	Asymmetry of PFS post	Result
						1	2	1		
1	F	16	2	1.5	6	6.5	8.5	8.5	0	good
2	M	17	4	3.5	7	5.5	9	9	0	good
3	M	16	7	5	9	3.5	8.5	7.5	-1	fair
4	M	32	5.5	4.5	8	5	9	9	0	good
5	M	19	3.5	3	8	6.5	9.5	9	-0.5	good
6*	F	20	5	3	8	6	9	8.5	-0.5	good
7	F	18	10	8	9	1.5	9.5	8.5	-1	fair
8	F	18	7	5	6	3	8	8	0	good
9*	F	20	2	2.5	5	6.5	9	8.5	-0.5	good
10	M	17	3	4.5	8	5.5	9.5	8.5	-1	fair
11	M	18	4	3	8	6.5	9.5	9.5	0	good
12	M	25	5	3	8	5	8	7.5	-0.5	good
13	M	16	3	3	9	5.5	8.5	8.5	0	good

JW: Jaw winking; LF: Levator function; PFS: Palpebral fissure size; 1=the affected eye; 2=the unaffected eye; Asymmetry of PFS post: the asymmetry of PFS between the operated eye and non-affected eye after surgery, number 6* and 9* were two patients with vertical strabismus, number 6 with hypotropia with superior rectus weakness, and number 9 with congenital hypertropia and exotropia in the unaffected eye

orbital septum was opened horizontally, then a Desmarre retractor was used to retract the preaponeurotic fat and allow for blunt dissection of levator muscle above the Whitnall's ligament. The patient was instructed to open the mouth so the operator could see the movement of levator muscle. The medial and lateral edges of the muscle were separated, then two squint hooks were passed under the muscle, which was then clamped with two hemostats, holding levator muscle and transecting the Whitnall's ligament. The patient was told to open the mouth again to confirm that there was no residual synkinesis, levator muscle flap was made without damage of levator aponeurotic attachment.

After levator transection, a subcutaneous tunnel was made from the upper eyelid incision to 1cm above the brow, the horizontal length of the tunnel was about 20mm. Two hemostats were inserted into the tunnel until the orbital margin where frontal muscle attached, turned over the hemostats after frontal muscle was clamped. The combination spot of orbital orbicularis oculi and the edge of frontal muscle was exposed, then the frontal muscle was separated to fashion a quadrangular muscle flap, about 1.5cm×0.5cm. The vertical length of frontal muscle flap was about 0.5cm, so the damage caused by extensive separation of the frontal muscle can be avoided. Then levator muscle was shortened and joined to frontal muscle with three pairs of mattress sutures according to the height and contour of the contralateral normal eyelid. Finally, the redundant levator muscle was cut off and a crescent of excess orbicularis muscle was then excised from the superior margin of the wound, the lid crease was re-established using several

interrupted 6-0 nylon sutures securing the skin edges to top of the tarsal plate.

To assess surgical outcomes, we measured the palpebral fissure sizes of two eyes in all patients pre- and post-surgery. Outcomes were assessed according to the following criteria: 1) existence of jaw-winking phenomenon (yes/no); 2) asymmetry of palpebral fissure sizes (good<1mm; 1mm asymmetry≤fair≤2mm asymmetry; poor>2mm asymmetry); and 3) eyelid contour (good=no entropion, malformation, overhanging skin fold; poor = any contour abnormality /asymmetry). At the follow-up period, we observed the palpebral fissure sizes and symmetry as well as possible jaw-winking phenomenon and complications.

RESULTS

Before surgery, mouth opening or jaw movement to the opposite side elicited jaw-winking in a total of 13 patients. The magnitude of jaw-winking in primary gaze ranged 2-10mm, with nine eyelids showing moderate jaw-winking (2-5mm) and four classed as severe (>5mm)^[5]. All patients considered the jaw-winking problematic enough to require treatment. One patient had minimal ptosis (<2mm), seven had moderate ptosis (≥2mm and ≤4mm), and five had severe ptosis (>4mm).

After the operation, all 13 patients showed complete resolution of jaw-winking synkinesis (Table 1). Ten of them showed equal palpebral apertures and symmetrical contour postoperatively, three had mild ptosis, five had obvious eyelid lag on downgaze just after the surgery, while nearly disappeared half a year later. Five patients could manage postoperative exposure keratopathy with artificial tears

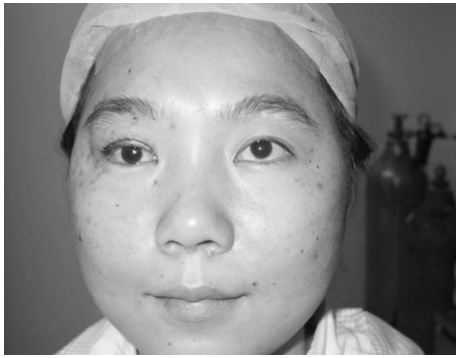

Figure 2 Satisfied outcome after the surgery

because of lagophthalmos, no early postoperative revision was necessary for exposure keratopathy, lagophthalmos recovered about half a year after the surgery. The patients with strabismus were satisfied with the results of ptosis correction and disappeared synkinesis though the strabismus still existed (Figure 2).

DISCUSSION

Robert Marcus Gunn first described a "congenital ptosis with peculiar associated movement of the affected lid" in a 15-year-old girl in 1883^[1], which was then called Marcus-Gunn syndrome or jaw-winking phenomenon. The eyelid wink is triggered by chewing, suction, lateral mandible movement or sternocleidomastoid contraction, causing the tongue to protrude, even when smiling^[6]. In the cases described above, moderate-to-severe synkinesis was observed and the wink resulted from contralateral jaw movement, opening the mouth, chewing or sucking.

Jaw-winking phenomenon is reported in 2%-13% of congenital blepharoptosis patients^[7]. Patients often have associated ophthalmological abnormalities including amblyopia, strabismus, anisometropia or superior rectus palsy^[6]. In this study, two patients had mild vertical strabismus: one with hypotropia combined with superior rectus weakness, the other with congenital hypertropia and exotropia in the unaffected eye. They didn't undergo strabismus surgery because they were more bothered by jaw-winking and desired ptosis correction first. Their palpebral fissure sizes were symmetry after surgery and they were satisfied with the results. To manage jaw-winking and ptosis, both the severity of jaw-winking and the magnitude of ptosis should be considered. In the cases described above, jaw-winking was moderate-to-severe and was considered problematic by the patient, so we chose to obliterate the levator action, then employ techniques to treat ptosis.

To obliterate the levator function, several surgical techniques could be suggested. Excision of the levator aponeurosis and terminal musculature is a choice for many surgeons. Because the levator aponeurosis has numerous attachments below Whitnall's ligament and bisects the lacrimal gland as it goes

into the orbital and palpebral lobes, separating the aponeurosis from all its attachments is frequently incomplete. Furthermore, fibrous connections between levator muscle and eyelid can reform^[5], so normal levator shortening management can not eliminate the synkinesis. Some advocate removal of the entire levator aponeurosis and levator muscle to the apex of the orbit^[8,9], but this method involves extensive surgery that carries some risk to the superior orbital structures^[10]. Although persistence of jaw-winking has been reported after transection of levator muscle above Whitnall's ligament^[11], all patients in this study showed complete resolution of jaw-winking. When we opened the orbital septum, we observed that the synkinesis position was above Whitnall's ligament. After transecting levator muscle above Whitnall's ligament, we told the patient to chew or open the mouth repeatedly to ensure that synkinesis was totally resolved, this step helped ensure a good outcome.

After obliterating the levator function, ptosis must be resolved. Frontalis suspension using autogenous or ectogenous fascia is frequently used^[3-5], new methods such as treating the orbicularis oculi muscle flap have also been reported^[7,12]. Khwarg *et al*^[5] reported the results of 24 patients who underwent frontalis suspension using fascia lata after levator excision for moderate-to-severe jaw-winking ptosis. In the group of five patients underwent bilateral frontalis suspension and levator excision only on the involved side, final results were good in two patients (40%-the habitual margin reflex distance (MRD) in both upper eyelids was 3mm or more and asymmetry between the habitual MRD of both upper eyelids was 1mm or less) and poor in three (60%-the habitual MRD in either upper eyelid was less than 2mm or if asymmetry was greater than 2mm). Of the 19 patients who underwent bilateral levator excision, final results were good in 13 (68.4%) and fair in 6 (31.6%-between good and poor). Kemp *et al*^[13] reported the outcome of brow suspension surgery for ptosis repair performed with mersilene mesh as the suspensory material, three patients with Marcus-Gunn syndrome had poor results. The author concluded previous surgery and Marcus-Gunn syndrome would initially appear to be risk factors for poor outcome of mersilene mesh brow suspension.

Compared with them, the anastomosis way had a better result of outcome. The patients were not restricted by the source of fascia nor did they experience rejection. Furthermore, this method allows for more physiological functions of the upper eyelid. So in our study, six months after the operation, there were no obvious eyelid lag on downgaze and lagophthalmos.

Lemagne *et al*^[14] and Neuhaus *et al*^[15] described techniques of transecting the involved levator muscle followed by

suspension of the eyelid to the frontal muscle. The surgical procedure includes isolation of levator muscle and aponeurosis, transecting the distal levator muscle reflected anteriorly, dividing the distal levator complex into three suspensory segments, passing the suspensory segments into the eyebrow, then fixing them to the frontal muscle. The basic principle of our anastomosis method was the same as the Neuhaus'. In that, we also applied a new motor source to the levator aponeurosis while the levator aponeurotic attachments had not been disturbed. However, our anastomosis method differs in some respects and has certain advantages: First, it requires no brow incisions, reducing the size of incision scars. Second, since this method does not divide the levator complex into three segments, the possibility of muscle rupture or losing the thread can be reduced, especially for patients with a weak levator muscle, moreover, eyelid contour and palpebral fissure height are easier to adjust when not operating through three segments of levator muscle. Third, reoperation is easier to implement if ptosis relapse, as the anatomical level is clearer in anastomosis way.

Many authors advocate bilateral surgery even with unilateral disease^[3,5,9]. They reported a better outcome with bilateral repairs because the surgeon can regulate the lid movement better with bilateral manipulation rather than trying to match the natural ability of the unaffected levator muscle^[16], ensuring a symmetrical result in primary gaze and with eye movements, particularly downgaze, with blinking and eyelid closure. While bilateral surgery requires considerable faith on the part of patients and their parents to allow surgery on the normal eye, and may take longer and involve more pain for the patient compared with unilateral surgery. In our study, we did unilateral surgery under local anesthesia, which allows the operator to check symmetry during the operation. Even so, asymmetry did exist after surgery, especially with downgazing, blinking and eyelid closing, but these phenomena gradually improved over time. At six months after the operation, most patients showed symmetrical results even when downgaze. So for adults and older children, unilateral surgery under local anesthesia is a good choice.

The most common postoperative problems in patients with ptosis include an asymmetrical lid level, undercorrection, overcorrection, loss of lid crease with eyelash ptosis, overhanging skin fold and entropion of the upper eyelid, lagophthalmos and so on^[17]. Compared with the other eye, all the patients in this study had good lid crease, no overhanging skin fold, no entropion and descent of eyebrow level. The patients did not have obvious forehead hypoesthesia, we

presumed that no extensive separation of the frontal muscle was needed in anastomosis technique may reduce damage to local sensory nerves. Five eyes had lagophthalmos, while recovered about half a year after the surgery. Three eyes had residual ptosis, the reason of undercorrection is unclear, it may related to the weakening of levator muscle, we need larger number of cases to acquire the exact reason, the operator can make a slight overcorrection according to his experience to reduce undercorrection. Moreover, the operator had to operate skillfully to control edema or hemorrhage which could increase eyelid bulk, making it difficult to achieve symmetry during the operation.

In summary, for moderate to-severe MGS, anastomosis of levator and frontal muscles generally provides satisfied correction of both jaw-winking synkinesis and ptosis, careful observation and adjustment during the operation will ensure symmetry and obliterating of synkinesis.

REFERENCES

- 1 Gunn RM. Congenital ptosis with peculiar associated movement of the affected lid. *Trans Ophthalmol Soc UK* 1883;3:283-287
- 2 Merriam WW, Ellis FD, Helveston EM. Congenital blepharoptosis, anisometropia, and amblyopia. *Am J Ophthalmol* 1980;89(3):401-407
- 3 Bowyer JD, Sullivan TJ. Management of Marcus Gunn winking synkinesis. *Ophthalm Plast Reconstr Surg* 2004;20(2):92-98
- 4 Bartkowski SB, Zapala J, Wyszyńska-Pawelec G, Krzystkowska KM. Marcus Gunn jaw-winking Phenomenon: management and results of treatment in 19 patients. *J Craniomaxillofac Surg* 1999;27(1):25-29
- 5 Khwarg SI, Tarbet KJ, Dortzbach RK, Lucarelli MJ. Management of moderate to severe Marcus Gunn jaw-winking ptosis. *Ophthalmology* 1999;106(6):1191-1196
- 6 Torres MR, Calixto N Jr, Oliveira LR, Steiner SA, Iscold AM. Marcus Gunn phenomenon: differential diagnosis of palpebral ptosis in children. *J Pediatr* 2004; 80(3):249-252
- 7 Park DH, Choi WS, Yoon SH. Treatment of the jaw-winking syndrome. *Ann Plast Surg* 2008;60(4):404-409
- 8 Bullock JD. Marcus-Gunn jaw-winking ptosis: classification and surgical management. *J Pediatr Ophthalmol Strabismus* 1980;17(6):375-379
- 9 Davis G, Chen C, Selva D. Marcus Gunn syndrome. *Eye* 2004;18(1):88-90
- 10 Dillman DB, Anderson RL. Levator myectomy in synkinetic ptosis. *Arch Ophthalmol* 1984;102(3):422-423
- 11 Manners RM, Rosser P, Collin JR. Levator transposition procedure: a review of 35 cases. *Eye* 1996;10(Pt 5):539-544
- 12 Tsai CC, Lin TM, Lai CS, Lin SD. Use of the orbicularis oculi muscle flap for severe Marcus Gunn ptosis. *Ann Plast Surg* 2002;48(4):431-434
- 13 Kemp EG, MacAndie K. Mersilene mesh as an alternative to autogenous fascia lata in brow suspension. *Ophthalm Plast Reconstr Surg* 2001;17(6):419-422
- 14 Lemagne JM. Transposition of the levator muscle and its reinnervation. *Eye* 1988;2(Pt 2):189-192
- 15 Neuhaus RW. Eyelid suspension with a transposed levator palpebrae superioris muscle. *Am J Ophthalmol* 1985;100(2):308-311
- 16 Koelsch E, Harrington JW. Marcus Gunn jaw-winking synkinesis in a neonate. *Mov Disord* 2007;22(6):871-873
- 17 Collin JR. Complications of ptosis surgery and their management: a review. *J R Soc Med* 1979;72(1):25-26