

Injection of tissue plasminogen activator into the optic nerve in an animal model of retinal vein occlusion

Cai-Hui Jiang¹, Mao-Nian Zhang¹, Motohiro Kamei²

¹ Department of Ophthalmology, the Chinese PLA General Hospital, Beijing 100853, China

² Department of Ophthalmology, Graduate School of Medicine, Osaka University, Suita 565-0871, Japan

Correspondence to: Mao-Nian Zhang. Department of Ophthalmology, the Chinese PLA General Hospital, Beijing 100853, China.

zhangmaonian@msn.com

Received:2009-06-20 Accepted:2009-08-03

Abstract

• **AIM:** To investigate the feasibility and efficacy of tissue plasminogen activator (tPA) injection into the optic nerve as a treatment for retinal vein occlusion in rabbits.

• **METHODS:** Rose Bengal-mediated laser-induced retinal vein occlusions were produced in rabbit eyes. Fluorescein angiography (FA) was performed on each eye 3 days before laser irradiation and 30 minutes after laser irradiation. The treatment group ($n=20$ veins) received intra-optic nerve injection of tPA (12.5 μ g in 0.05mL BSS) and the controls ($n=24$ veins) received 0.05mL BSS. FA was repeated to determine the recanalization of the vessel at 3 and 7 days after treatment, followed by histological examination.

• **RESULTS:** Rose Bengal-mediated laser-induced retinal vein occlusions were successfully developed and confirmed by FA. The incidence of the recanalization of the vessels in treatment animals was 70.0%, while 16.7% in the control animals ($P=0.001$).

• **CONCLUSION:** Intra-optic nerve tPA injection increases the incidence of recanalization of the occluded vessels. Although further studies are needed, our data suggested that injection of tPA into the optic nerve may have a potential benefit in the treatment of central retinal vein occlusion.

• **KEYWORDS:** central retinal vein occlusion; tissue plasminogen activator; intraoptic nerve injection; thrombolysis

Jiang CH, Zhang MN, Kamei M. Injection of tissue plasminogen activator into the optic nerve in an animal model of retinal vein occlusion. *Int J Ophthalmol* 2009;2(4):338–343

INTRODUCTION

Central retinal vein occlusion (CRVO) is one of the most common retinal vascular disorders, and its visual prognosis remains poor [1-3]. Although new therapeutic approaches have been developed in the past few years, current treatment options are subject to controversy [4,5], and no commonly accepted treatment exists to improve visual acuity after CRVO. The only established management, laser photocoagulation, targets the neovascular complications of CRVO. Panretinal laser photocoagulation and grid laser photocoagulation for macular edema are not effective in improving visual acuity [6,7]. Laser-induced chorioretinal anastomosis attempting to bypass venous obstruction has been performed with limited success and significant complications [8-10]. Radial optic neurotomy remains a controversial method of treatment for CRVO [11-16].

The increasing role of hypercoagulability in patients with CRVO supports the use of antithrombotic drug in the treatment of this disease [17-19]. Using thrombolytic agents to dissolve the thrombus in CRVO holds promising as a radical treatment. Recombinant tissue plasminogen activator (tPA) is a relatively clot-selective fibrinolytic agent with a molecular weight of 70Kd. Compared with non-selective fibrinolytic agents such as streptokinase or urokinase, tPA is superior in efficacy in the lysis of thrombi, achieving reperfusion, its enhanced fibrin selectivity and its lack of antigenicity, which leads to greater therapeutic activity for cerebral infarction or myocardial infarction [20].

The systemic administration of tPA to treat RVO has shown some beneficial effects, but was associated with vitreous hemorrhage and serious systemic complications, including patient mortality [21]. Systemic administration of tPA, therefore, is currently not recommended as a treatment for RVO.

Intravitreal administration of tPA, which avoids systemic complications, has been performed with no serious side effects [22-24]. Some of the reports showed benefits [22-24], and others not. The former believed that intravitreal tPA may diffuse across the internal limiting membrane of the retina,

especially at the area of optic nerve head and then into the retinal circulation through the vessels damaged by vein occlusion. The tPA is then transported by residual venous flow to the area of occlusion at the level of the lamina cribrosa. An experimental study in rabbits, however, showed that intravitreal tPA does not diffuse through the neural retina in the absence of a retinal damage^[25], and no study proved that intravitreal tPA can diffuse into the retinal vein in a RVO animal model. A recent study showed that retinal toxicity associated with intravitreally injected tPA increase in a dose-dependent manner and be exacerbated in CRVO eyes^[26].

Vitreotomy with retinal vein cannulation and infusion of tPA was performed with some success, but has technical difficulties and was also with some complications, such as vitreous hemorrhage, retinal detachment and some other potential complications^[27-30]. We have experienced that tPA was unintentionally injected into the optic disc, mainly to the surface layer, during tPA cannulation surgery and symptoms improved in a couple of cases. We, therefore, hypothesize that direct injection of tPA into the area of lamina cribrosa, where the thrombosis is thought to be formed in CRVO^[31], may allow tPA molecules to work more efficiently. The purpose of this study is to investigate the feasibility, and efficacy of injection of tPA into the optic nerve for the treatment of RVO in rabbits.

MATERIALS AND METHODS

Experimental Animals A total of 30 Japanese albino rabbits (Hokusetsu Co. LTD, Osaka, Japan), weighing 2.0 to 2.5kg, were used in this study. All experiments were performed according to the Association for Research in Vision and Ophthalmology Statement for the Use of Animals in Ophthalmic and Vision Research, and the policies in the Guide to the Care and Use of Laboratory Animals by the National Institute of Health.

Retinal Vein Thrombus Formation Rabbits were anesthetized with an intramuscular injection of ketamine hydrochloride (32mg/kg body weight) and xylazine hydrochloride (4mg/kg body weight) for all procedures. Fundus examination was performed to exclude any abnormality and fundus photographs (TRC-50IX, TOPCON, Tokyo, Japan) were taken to record the fundus status.

Rose Bengal-mediated argon laser retinal vein photothrombosis was used to produce RVO near the center of optic disc of 30 rabbit eyes according to the previous reports^[32-34]. Rose Bengal solution at a concentration of 40g/L was prepared by dissolving the Rose Bengal (Nakalai Tesque, INC. Kyoto, Japan) in saline solution and filtering with a 0.22 μ m sterile Millipore filter (Medford, MA). Rose Bengal solution (40mg/kg) was injected through ear vein just before the laser irradiation. The argon laser (COHERENT Ultima 2000SE, Carl Zeiss, Germany) was

used to irradiate the two major retinal veins located within the optic disc. The irradiation conditions were as follows: power: 140mV, spot size: 50m, duration: 0.5 seconds. The number of laser applications necessary to induce complete RVO was recorded for each eye. Fluorescein angiography was performed on each eye 3 days before laser irradiation and 30 minutes after laser irradiation. Sodium fluorescein (100g/L; Alcon) was injected through ear vein (0.5mL/kg) immediately before angiography. Occlusion was confirmed by fluorescein angiography. Eyes were excluded from this study if both treated vessels were only partly occluded. The duration of follow up period in this experiment was 7 days.

Intra-optic Nerve tPA Injection Rabbits were randomly divided into two groups. Rabbits in treatment group (10 eyes, 20 veins) were treated with optic nerve injection of tPA (12.5 μ g in 0.05mL BSS) 1 hour after laser irradiation. Control animals (12 eyes, 24 veins) received optic nerve injection of 0.05mL BSS. Either tPA or BSS was injected into the center of the optic disc with a 30 gauge needle (Becton Dickinson & Co. Franklin Lakes, NJ) through the pars plana and vitreous. The depth of the injection was about 1mm, and the needle stayed in the optic nerve for one minute before being drawn out. FA was repeated at 3 and 7 days after RVO to determine the recanalization. The eyes were harvested for histopathological study on the medullary wings at 7 days after treatment.

Histological Study Rabbits were sacrificed with overdose administration of pentobarbital. The eyes were immediately enucleated, fixed in 40g/L paraformaldehyde at 4°C for 4 hours. After removal of the anterior segment and vitreous, the posterior portion of the eye was postfixed in the same fixative before being placed in 300g/L sucrose overnight at 4°C for cryosection. Tissues were embedded in a supporting medium for frozen tissue specimens (OCT compound, Tissue-Tek, CA, USA). Cryosections of 10 μ m were cut and stained with Hematoxylin-eosin. The sections were examined by light microscopy, and the selected images were digitized using a CCD camera (AxioCam: Carl Zeiss Japan, Tokyo, Japan). The images were processed with AxioVision 2.0 (Carl Zeiss Japan, Tokyo, Japan) software on a Windows-based computer.

Statistical Analysis Statistical comparisons between two groups were done with Student's *t*-test. Fisher's exact test was used to assess the difference of the recanalization of the vessels between treatment and control animals. Difference were accepted as significant at *P*<0.05.

RESULTS

Focal retinal vein occlusion was successfully produced by Rose Bengal-mediated argon laser retinal vein photothrombosis (Figures 1-4). The numbers of laser application needed to produce complete RVO were not significantly different in the treatment and control animals

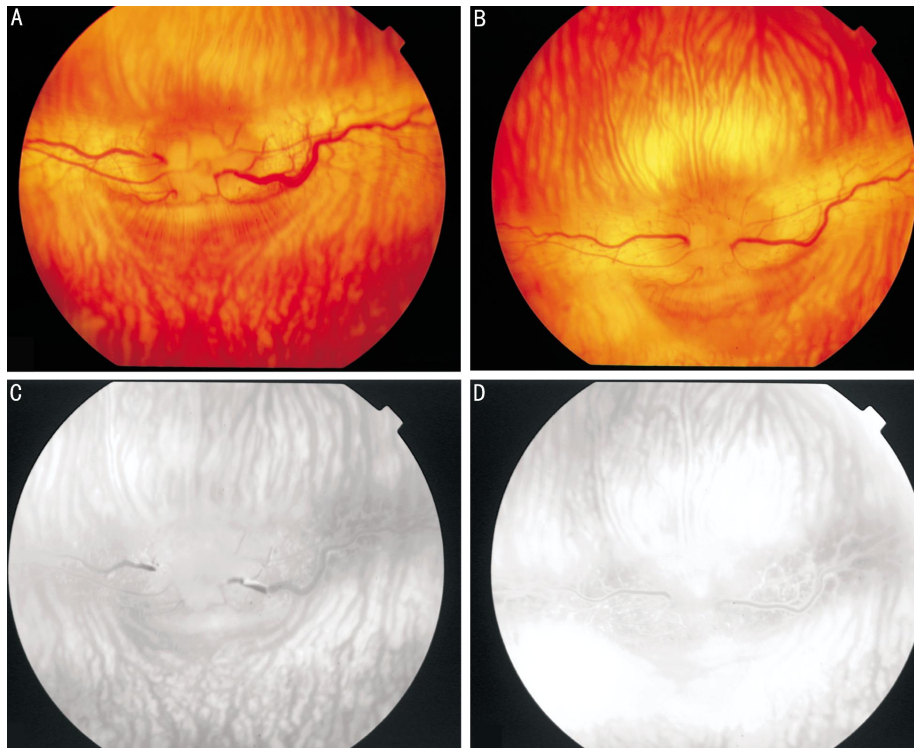


Figure 1 Color photograph and FA of tPA treated rabbit A, C: Occlusion of retinal vein at site of Rose Bengal-mediated argon laser induced photothrombosis; B, D: Seven days after tPA injection, demonstrating normal perfusion of the retinal vein. The thrombi have been resolved

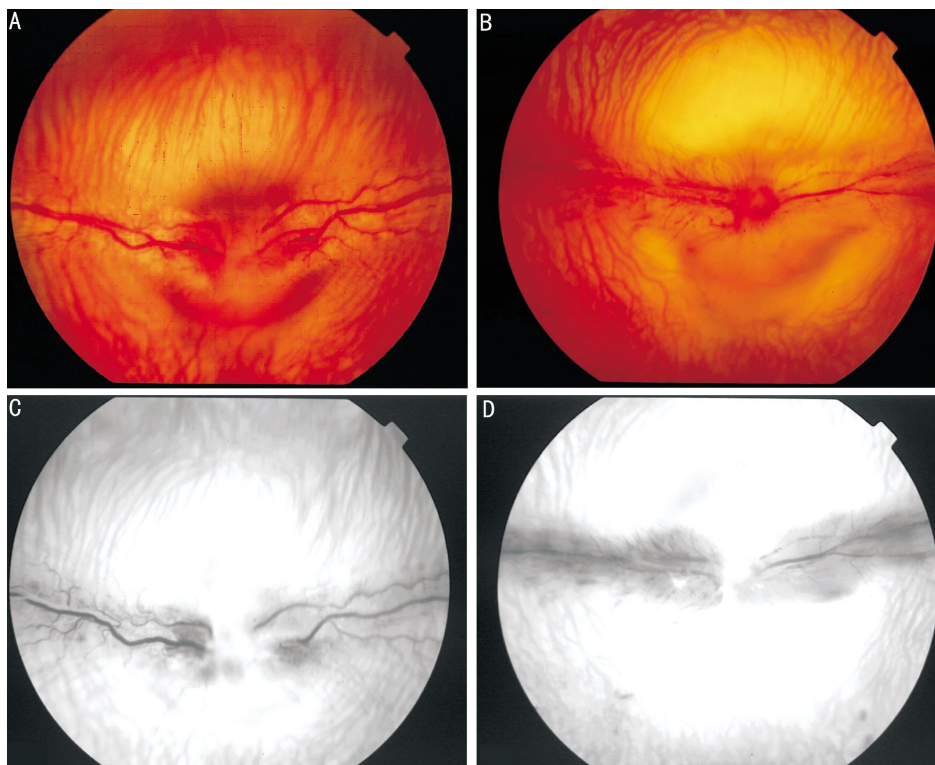


Figure 2 Color photograph and FA of BSS treated rabbit A, C: Occlusion of retinal vein at site of Rose Bengal-mediated argon laser induced photothrombosis; B, D: Seven days after BSS injection, demonstrating complete occlusion of the retinal vein. The thrombi have not been resolved

(Control group: 26.7; Treatment group: 27.6; $P=0.5371$). Immediately after occlusion, there was a marked dilation and tortuosity of the vein peripheral to the site of occlusion

and narrowing of arteries on medullary rays. Vein occlusion was confirmed by the lack of fluorescein filling and the dilation and tortuosity of the veins peripheral to the

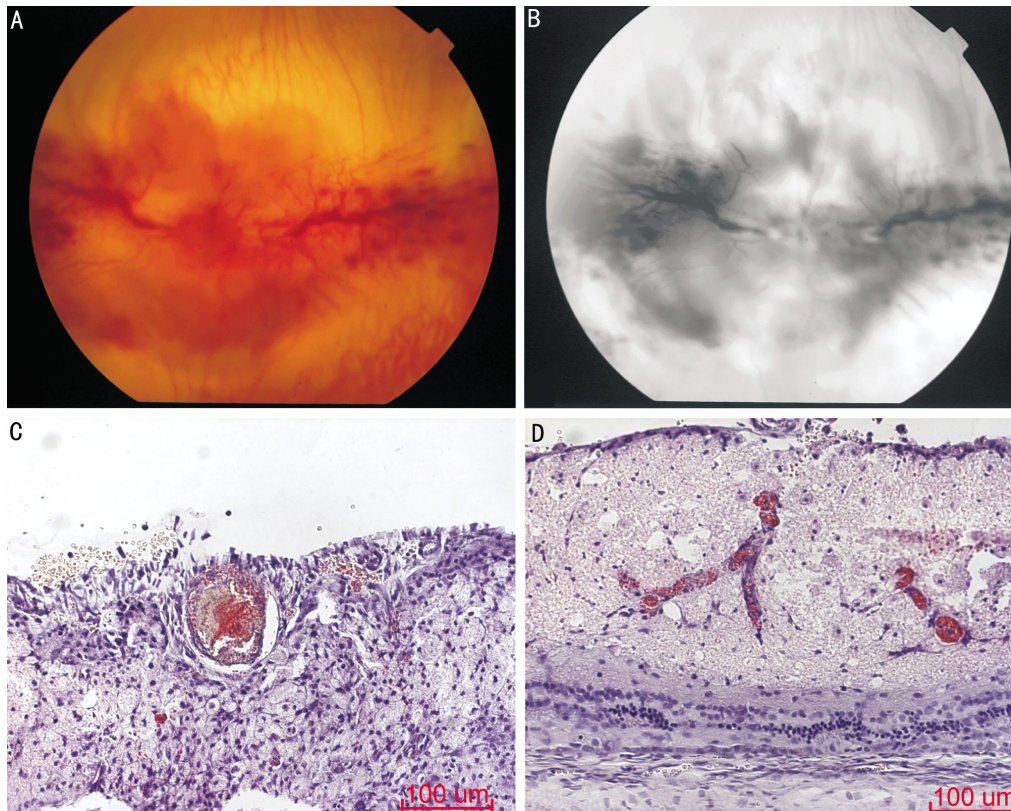


Figure 3 Color photograph and FA of BSS treated rabbit A, B: Seven days after BSS injection, demonstrating complete occlusion of the retinal vein. Retinal hemorrhage along the vascular wing and vitreous hemorrhage are observed; C: Adherent thrombus was seen 7 days after Rose Bengal-mediated argon laser induced photothrombosis; D: Medullary ray of retina 7 days after receiving ON injection of BSS, showing significant damages. Necrosis, hemorrhage and vacuoles are observed in medullary ray

occlusion. Representative color fundus photographs and FA are shown in Figure 1A, 1C and Figure 2A, 2C. Retinal or vitreous hemorrhages were not a prominent feature immediately after occlusion. Retinal hemorrhages, retinal edema on medullary rays and vitreous hemorrhage were evident in some control animals three days after occlusion (Figure 3A). Exudative retinal detachment was not seen in both groups during the follow-up. Collateral vessel development was common in control rabbits (Figure 4). The incidence of the recanalization of the vessels in treatment animals was 70.0% (14/20), while 16.7% (4/24) in the control animals was. There was a statistical significant difference between treatment group and control group ($P=0.001$).

Histological examination showed a thrombus 7 days after laser application (Figure 3C) and severe damage to retina along the medullary rays of all eyes treated with BSS (Figure 3D). Necrosis, hemorrhage and vacuoles were observed in medullary rays.

There were no severe complications such as retinal detachment, vitreous hemorrhage, or laceration of major retinal and optic vessels. The only complication that we experienced was a little hemorrhage located at the site of

injection (5/48 eyes; 10.4%), but this disappeared spontaneously within 2 weeks after injection.

DISCUSSION

In this study, we evaluated the feasibility and efficacy of tPA injection into the optic nerve. There were no severe complications and the only complication that we experienced was a little hemorrhage located at the site of injection. Penetration with 30G needle causes apparently less traumatic damage to the optic nerve when compared with radial optic neurotomy (RON) procedure in which an incision is made in the scleral ring, cribriform plate, and adjacent sclera at the nasal edge of the optic disc^[11-16]. In this animal model of retinal vein occlusion, intra-optic nerve tPA injection significantly increased the recanalization of the occluded vessels, and the recanalization prevented the retina from necrosis. These results suggest that injection of tPA into the optic nerve is a feasible and effective procedure.

We used Rose Bengal-mediated argon laser retinal vein photo-thrombosis to produce focal retinal vein occlusions as close as possible to the center of optic disc. Although exact mimic of CRVO could not be obtained, the findings including dilation and tortuosity of the vein, retinal hemorrhage, retinal edema and vitreous hemorrhage are

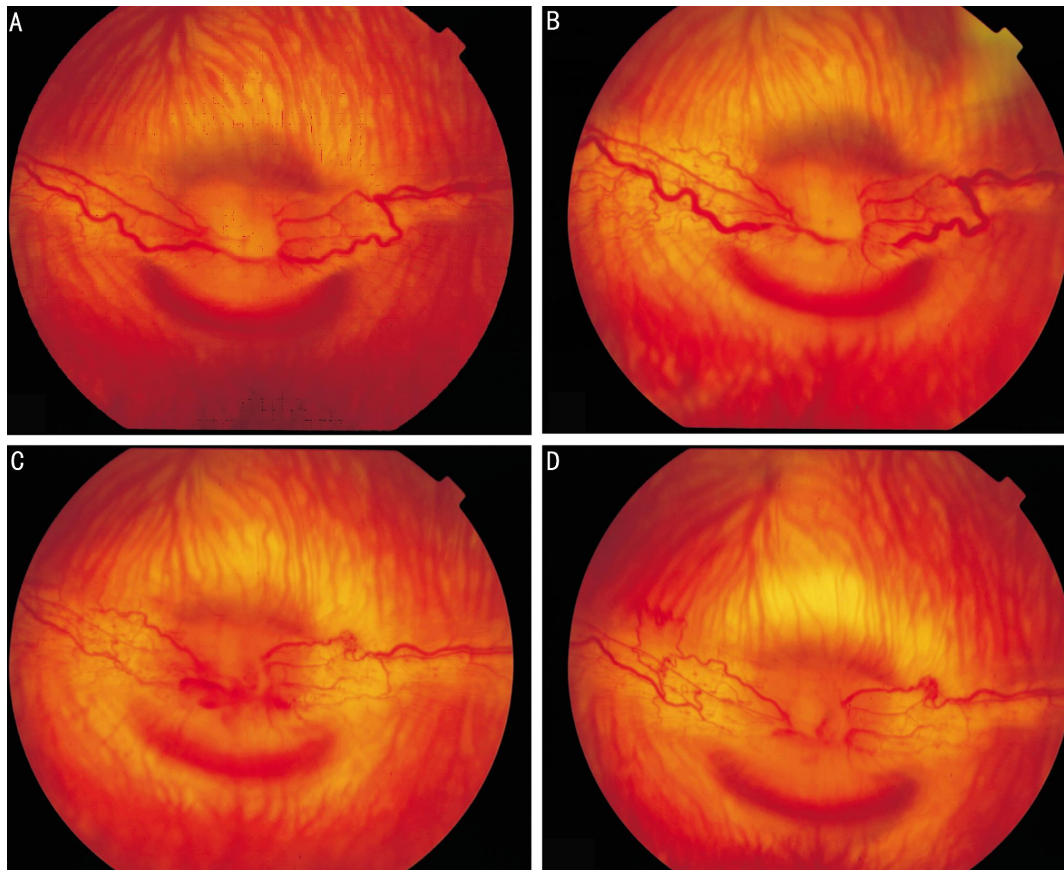


Figure 4 Color photograph of BSS treated rabbit A: Normal vessels before RVO; B: One hour after photothrombosis, demonstrating complete occlusion of the retinal vein at the site of Rose Bengal-mediated argon laser induced photothrombosis. Collateral vessels dilated immediately after occlusion; C, D: Three and seven days after the occlusion of retinal veins respectively, demonstrating collateral vessels gradually developed and matured

similar to CRVO in human. This model has another limitation that thrombus was induced at the edge of the optic disc, not in the optic nerve at the level of the lamina cribrosa. Since the distance between the occlusion site and the injection site was short and the results showed effectiveness of this technique, we hypothesize that direct injection of tPA into the area of lamina cribrosa, where the thrombosis is thought to be formed in the central retinal vein occlusion^[31], could be reasonable and applicable. Injection of tPA into the vicinity of lamina cribrosa may allow tPA molecules to diffuse more easily into retinal vein directly or into venous circulation of the optic nerve head, because the internal limiting membrane could work as a diffusion barrier for intravitreally injected tPA to penetrate the retina.

Intravitreal administration of tPA, which avoids systemic complications, has been performed with no serious side effects^[22-24]. However, an experimental study in rabbits showed that intravitreal tPA does not diffuse through the neural retina in the absence of a retinal damage^[25]. In addition, ischemic conditions may decrease threshold of tPA retinal toxicity because it is reported that neuronal toxicity increases under ischemia^[35]. A recent study showed that

retinal toxicity associated with intravitreally injected tPA increase in a dose-dependent manner and be exacerbated in CRVO eyes^[26]. This study did not aim to compare intravitreal injection and intra-optic nerve injection of tPA for CRVO, a further study is needed to determine which technique is more safe and effective.

In conclusion, injection of tPA into the optic nerve seems to be a simple, feasible and effective treatment for the experimental retinal vein occlusion, and may have a potential benefit in the treatment of CRVO. Further studies are needed to determine the optimal dose of tPA and optimal time of injection.

REFERENCES

- 1 Orth DH, Patz A. Retinal branch vein occlusion. *Surv Ophthalmol* 1978;22(6): 357-376
- 2 The Central Vein Occlusion Study Group. Baseline and early natural history report. *Arch Ophthalmol* 1993;111(8):1087-1095
- 3 The Central Vein Occlusion Study Group. Natural history and clinical management of central retinal vein occlusion. *Arch Ophthalmol* 1997;115 (4): 486-491
- 4 Hayreh SS. Management of central retinal vein occlusion. *Ophthalmologica* 2003; 217(3):167-188
- 5 Williamson TH. Central retinal vein occlusion: what's the story? *Br J Ophthalmol* 1997;81(8):698-704

- 6 The Central Vein Occlusion Study Group N report. A randomized clinical study of early panretinal photocoagulation for ischemic central vein occlusion. *Ophthalmology* 1995;102(10):1434-1444
- 7 The Central Vein Occlusion Study Group M report. Evaluation of grid pattern photocoagulation for macular edema in central vein occlusion. *Ophthalmology* 1995;102(10):1425-1433
- 8 McAllister IL, Constable IJ. Laser-induced chorioretinal venous anastomosis for treatment of nonischemic central retinal vein occlusion. *Arch Ophthalmol* 1995; 113(4):456-462
- 9 Fekrat S, Goldverg MF, Finkelstein D. Laser-induced chorioretinal venous anastomosis for nonischemic central or branch retinal vein occlusion. *Arch Ophthalmol* 1998;116(1):43-52
- 10 Browning DJ, antoszyk AN. Laser chorioretinal venous anastomosis for nonischemic central retinal vein occlusion. *Ophthalmology* 1998;105(4):670-679
- 11 Czajka MP, Cummings TJ, McCuen BW 2nd. Radial optic neurotomy in the porcine eye without retinal vein occlusion. *Arch Ophthalmol* 2004;122 (8): 1185-1189
- 12 Hayreh SS. Radial optic neurotomy for central retinal vein occlusion. *Retina* 2002;22(6):374-379
- 13 Weizer JS, Stinnett SS, Fekrat S. Radial optic neurotomy as treatment for central retinal vein occlusion. *Am J Ophthalmol* 2003;136(5):814-819
- 14 Opremac EM, Bruce RA, Lomeo MD, Ridenour CD, Letson AD, Rehmar AJ. Radial optic neurotomy for central retinal vein occlusion: a retrospective pilot study of 11 consecutive cases. *Retina* 2001;21(5):408-415
- 15 Garcia-Arumi J, Boixadera A, Martinez-Castillo V, Castillo R, Dou A, Corcostegui B. Chorioretinal anastomosis after radial optic neurotomy for central retinal vein occlusion. *Arch Ophthalmol* 2003;121(10):1385-1391
- 16 Hayreh SS. Radial optic neurotomy for nonischemic central retinal vein occlusion. *Arch Ophthalmol* 2004;122(10):1572-1573
- 17 Prisco D, Marcucci R. Retinal vein thrombosis: risk factors, pathogenesis and therapeutic approach. *Pathophysiol Haemost Thromb* 2002;32(5-6):308-311
- 18 Vine AK, Samama MM. The role of abnormalities in the anticoagulant and fibrinolytic systems in retinal vascular occlusion. *Surv Ophthalmol* 1993;37 (4): 283-292
- 19 Williamson TH, Rumley A, Lowe GD. Blood viscosity, coagulation, and activated protein C resistance in central retinal vein occlusion: a population controlled study. *Br J Ophthalmol* 1996;80(3):203-208
- 20 Glacet-Bernard A, Kuhn D, Vine AK, Oubraham H, Coscas G, Soubrane G. Treatment of recent onset central retinal vein occlusion with intravitreal tissue plasminogen activator: a pilot study. *Br J Ophthalmol* 2000;84(6):609-613
- 21 Elman MJ. Thrombolytic therapy for central retinal vein occlusion: results of a pilot study. *Trans Am Ophthalmol Soc* 1996;94:471-504
- 22 Lahey JM, Fong DS, Kearney J. Intravitreal tissue plasminogen activator for acute central retinal vein occlusion. *Ophthalmic Surg Lasers* 1999;30(6):427-434
- 23 Elman MJ, Raden RZ, Carrigan A. Intravitreal injection of tissue plasminogen activator for central retinal vein occlusion. *Trans Am Ophthalmol Soc* 2001;99: 219-221
- 24 Ghazi NG, Nouredine B, Haddad RS, Jurdi FA, Bashshur ZF. Intravitreal tissue plasminogen activator in the management of central retinal vein occlusion. *Retina* 2003;23(6):780-784
- 25 Kamei M, Misono K, Lewis H. A study of the ability of tissue plasminogen activator to diffuse into the subretinal space after intravitreal injection in rabbits. *Am J Ophthalmol* 1999;128(6):739-746
- 26 Yomamoto T, Kamei M, Kunavisarut P, Suzuki M, Tano Y. Increased retinal toxicity of intravitreal tissue plasminogen activator in a central retinal vein occlusion model. *Graefes Arch Clin Exp Ophthalmol* 2008;246(4):509-514
- 27 Weiss JN, Bynoe LA. Injection of tissue plasminogen activator into a branch retinal vein in eyes with central retinal vein occlusion. *Ophthalmology* 2001;108 (12):2249-2257
- 28 Zhang XL, Ma ZZ, Hu YT, Fan J. Direct tissue plasminogen activator administration through a microinjection device in a pig model of retinal vein thrombosis. *Current Eye Research* 2002;24(4):263-267
- 29 Suzuki Y, Matsushashi H, Nakazawa M. *In vivo* retinal vascular cannulation in rabbits. *Graefes Arch Clin Exp Ophthalmol* 2003;241(7):585-588
- 30 Hayreh SS. t-PA in CRVO. *Ophthalmology* 2002;109(10):1758-1763
- 31 Green WR, Chan CC, Hutchins GM, Terry JM. Central retinal vein occlusion: a prospective histopathologic study of 29 eyes in 28 cases. *Trans Am Ophthalmol* 1981;79:371-422
- 32 Oku H, Yamaguchi H, Sugiyama T, Kojima S, Ota M, Azuma I. Retinal toxicity of nitric oxide released by administration of a nitric oxide donor in the albino rabbit. *Invest Ophthalmol Vis Sci* 1997;38(12):2540-2544
- 33 Oncel M, Peyman GA, Khoobehi B. Tissue plasminogen activator in the treatment of experimental retinal vein occlusion. *Retina* 1989;9(1):1-7
- 34 Arroyo JG, Dastgheib K, Hatchell DL. Anti-thrombotic effect of Ticlopidine in an experimental model of retinal vein occlusion. *Jpn J Ophthalmol* 2001;45 (4): 359-362
- 35 Liu D, Cheng T, Guo H, Fernández JA, Griffin JH, Song X, Zlokovic BV. Tissue plasminogen activator neurovascular toxicity is controlled by activated protein C. *Nat Med* 2004;10(12):1379-1383