

Expression of erythropoietin and its receptor in normal and neovascularized murine corneas induced by alkali burns

Ling Luo^{1,2}, Yuuki Kaminoh², Hao-Yu Chen², Mao-Nian Zhang¹, Kang Zhang², Balamurali K Ambati²

¹Department of Ophthalmology, General Hospital of Chinese PLA, Beijing 100853, China

²Department of Ophthalmology and Visual Science, Moran Eye Center, University of Utah, Salt Lake City, UT 84112, USA

Correspondence to: Kang Zhang. Department of Ophthalmology and Visual Science, Moran Eye Center, University of Utah, Salt Lake City, UT 84112, USA. zhang.kang@hsc.edu.utah; Balamurali K Ambati. Department of Ophthalmology and Visual Science, Moran Eye Center, University of Utah, Salt Lake City, UT 84112, USA. ambati@gmail.com; Ling Luo. Department of Ophthalmology, General Hospital of Chinese PLA, Beijing 100853, China; Department of Ophthalmology and Visual Science, Moran Eye Center, University of Utah, Salt Lake City, UT 84112, USA. ling.luoling1208@gmail.com
Received: 2008-12-28 Accepted: 2009-02-09

Abstract

• **AIM:** To test the expression of erythropoietin (Epo) and its receptor EpoR in normal and neovascularized murine corneas induced by alkali burns, and to investigate whether Epo/EpoR is involved in the process of corneal angiogenesis.

• **METHODS:** The expression of Epo/EpoR was tested in normal and neovascularized murine corneas induced by alkali burns through immunohistochemistry of corneal frozen sections. Epo cloning, expression, and purification were carried out. Then Epo protein (6 μ L, 1 μ g) and control (6 μ L of vector control or saline) were injected into the corneal stroma respectively, and the corneas were checked at the 14th day after injection to see whether corneal neovascularization occurred.

• **RESULTS:** Epo/EpoR was expressed in epithelial cells, endothelial cells and stromal cells in normal and neovascularized corneas induced by alkaline burns, and also expressed strongly in neovascularized cornea. They were expressed at the same time in stromal inflammatory cells and new vessels. Corneal neovascularization was induced by Epo intrastromal injection in 5 out of 6 eyes, but no new vessels were observed in all controls ($n=6$) at day 14 after vector control or saline intrastromal injection in normal corneas.

• **CONCLUSION:** This paper first reported the expression of

Epo and its receptor in normal and neovascularized cornea. Injection of Epo into the corneal stroma may induce the corneal neovascularization. Epo/EpoR is associated with the formation of corneal neovascularization.

• **KEYWORDS:** erythropoietin; cornea; neovascularization

Luo L, Kaminoh Y, Chen HY, Zhang MN, Zhang K, Ambati BK. Expression of erythropoietin and its receptor in normal and neovascularized murine corneas induced by alkali burns. *Int J Ophthalmol* 2009; 2(1):30-33

INTRODUCTION

Pathological revascularization within the normally avascular cornea is a serious event that can interfere with normal vision. The regulation of corneal angiogenesis is a complex process which involves the equilibrium between pro- and anti-angiogenic factors. Several angiogenic factors including vascular endothelial growth factor (VEGF), basic fibroblast growth factor (bFGF), and transforming growth factor (TGF)- α and - β have a vital role in corneal neovascularization (NV). However, previous strategies to inhibit VEGF action have generally been able to reduce neovascularization by only 30% to 50%. One explanation might be that there are other important angiogenic factors involved that are not affected by the anti-VEGF agents. Erythropoietin (Epo) is a hematopoietic cytokine that regulates the production of red blood cells^[1]. Epo is produced primarily in the kidney in response to anemia and hypoxia. Its receptor (EpoR), is localized also in non-hematopoietic tissues, eg. liver, uterus, central nervous system, vascular endothelial cells, myocardium, vascular smooth muscle, and mesangial cells and solid tumors. On endothelial cells, erythropoietin reported could induce cell proliferation and induce angiogenesis^[2]. Elevated levels of Epo were found in the vitreous samples of patients with proliferative diabetic retinopathy (PDR)^[3,4], or with retinopathy of prematurity (ROP)^[5], and high Epo con-

centrations in the human vitreous are more strongly associated with PDR than is VEGF [2-4]. These instances of Epo/EpoR linking to retinal neovascularization showed a potential association with pathological revascularization in other ocular tissues such as cornea. However, the role of Epo/EpoR in normal cornea and corneal NV is largely unknown. In this study, we hypothesized that Epo/EpoR may also be expressed in the normal cornea and abnormal expression in cornea contributes to the corneal neovascularization.

MATERIALS AND METHODS

All experiments were conducted in accordance with the Declaration of Helsinki and the ARVO Statement for the Use of Animals in Ophthalmic and Vision Research.

Epo Cloning and Expression The full length EPO cDNA was amplified from normal person's 1st strand cDNA with primer H-EPO-pET32a-L (SalI): ACGCGTCGACAAATGGGGGTGCACGAATGTCC/H-EPO-pET32a-R (NotI): ATAAGAATGCGGCCGCTCATCTGTCCCCTGTCCTGC. PCR fragment was cloned into pET32a vector. Positive clones were identified by bacterial PCR with T7 promoter and T7 terminator primer. Plasmid was extracted from positive clone using Qiagen mini-prep kit. The plasmid was transformed into BL21 E. coli strain after verified by enzyme digestion and sequencing. The recombinant protein was purified from E. coli using Ni-NTA column (Qiagen) after Isopropyl- β -D-thiogalactopyranoside (IPTG) induction. Epo control is vector control, pET 32a.

Model of Corneal Neovascularization by Alkaline Burn

The C57BL/6 mice used in the experiment were obtained from Kang's Laboratory. All mice were male at the age of 6-8 weeks. Under intramuscular general anesthesia and additional topical application of lidocaine. NV was induced by application of 2 μ L of 0.15mmol/L NaOH to the right central cornea of each mouse for 60 seconds, rinsed extensively with phosphate-buffered saline (PBS) for 2 minutes. The corneal epithelium was subsequently scraped off with a corneal knife in a rotary motion parallel to the limbus. The limbal areas were gently massaged over 360° for 3 minutes. The ocular surface was then irrigated with 20mL physiological saline. To prevent infection, eyes were administered with antibiotic ointment.

Immunohistochemistry of Corneal Frozen Sections

Mice were killed at 14 days after corneal injury. Eucleated eyes were fixed in 40g/L paraformaldehyde, transferred to 150g/L sucrose for 1 hour and then transferred to 300g/L sucrose overnight at 4°C, washed with PBS, and embedded in optimal cutting temperature (OCT) medium (Sakura Finetek,

Torrance, CA). Frozen sections of 6 μ m were washed with 1g/L Triton X-100/PBS and blocked for 1 hour with 100mL/L donkey serum before overnight incubation with rabbit polyclonal CD31 (1:400; Pharmingen, USA) and Goat Epo/EpoR (1:20; R&D System, Inc, USA). After washed by PBS for 5 minutes each time and 3 times, the sections were subsequently incubated with Rhodamine-conjugated polyclonal donkey anti-rabbit antibodies (1:400; Invitrogen-Molecular Probes, Eugene, OR) and FITC-conjugated polyclonal donkey anti-goat (1:200) preceded by a 1-hour at room temperature.

Corneal Intrastromal Injection Under direct microscopic observation, a nick in the epithelium and anterior stroma of the mouse cornea was made in the mid-periphery with a 0.5-in, 30-gauge needle (BD Biosciences, Franklin Lakes, NJ). A 0.5-in., 33-gauge needle with a 30° bevel on a 10 μ L gas-tight syringe (Hamilton, Reno, NV) was introduced into the corneal stroma and advanced 1.5mm to the corneal center. 6 μ L of Epo protein (extracted and purified in E.coli), or Control (6 μ L of vector control or saline) was forcibly injected into the stroma^[6].

RESULTS

Epo/EpoR Expressed in Normal Cornea To test the hypothesis that Epo/EpoR was expressed in the normal cornea, we first analyzed the presence of Epo/EpoR in murine cornea by using immunohistochemistry. As revealed in Figure 1, Epo was expressed in corneal epithelial cells, capillary endothelial cells, and also expressed in keratocytes. EpoR was observed in the same cells.

Epo/EpoR Expressed in NV A preliminary study revealed that corneal neovascularization was maximal in 57BL/6 mice around 14 days after scraping. Therefore, on day 14 we examined corneas for co-expression of the endothelial cell marker CD31 and Epo/EpoR. Results showed that the CD31 marked vessels within the cornea co-expressed the Epo (Figure 2A,B,C) or EpoR (Figure 2D,E,F). Furthermore, Epo/EpoR was expressed more strongly on inflammatory cells, epithelial cells, endothelial cells and keratocytes in NV than those in normal cornea (Figure 2 G,H,I).

NV Induced by Corneal Intrastromal Injection of Epo

No vessels were observed in all normal eyes ($n=6$) at day 14 after vector control or saline intrastromal injection (6 μ L) in normal corneas (Figure 3A). In contrast, some new vessels were observed in 5 out of 6 eyes at day 14 after Epo injection (6 μ L, 1.0 μ g). The picture (Figure 3B) showed the most obvious new vessels in cornea of all cases. The new vessels were growing through the limbal area stretching to the center but not reaching the center of cornea at day 14.

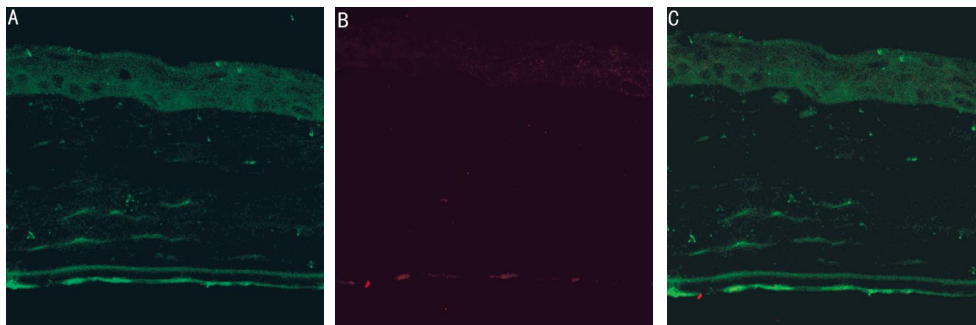


Figure 1 Expression of Epo in normal cornea. Epo was expressed in corneal epithelial cells, capillary endothelial cells and keratocytes ($\times 200$) A: Epo (green); B: CD31 (red), a mark of vessels; C: Overlay: merger of the two images

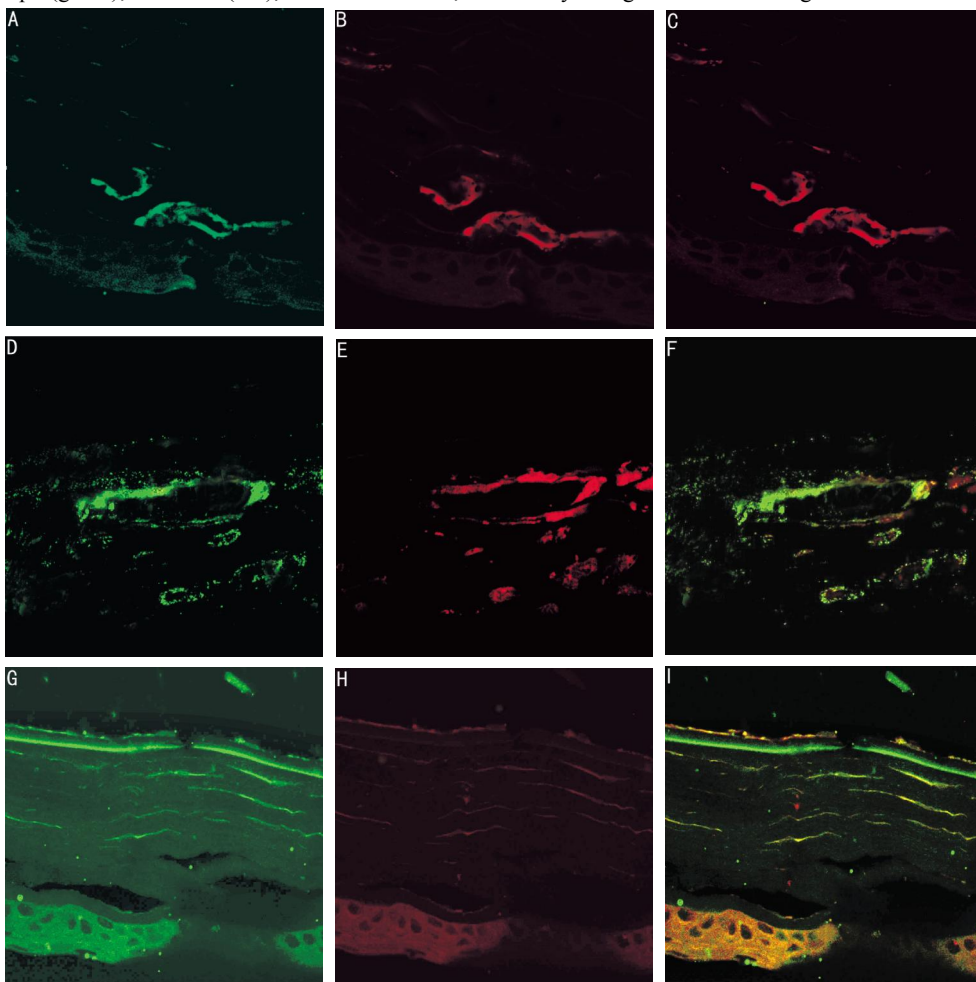


Figure 2 Expression of Epo/EpoR on the alkali-induced neovascularized cornea ($\times 200$) A: Epo (green); B: CD31 marked vessels (red); C: Overlay: merger of the two images; D: EpoR (green); E: CD31 marked vessels (red); F: Overlay: merger of the two images; G, H, I: Epo was also expressed on inflammatory cells, epithelial cells, endothelial cells and keratocytes in cornea NV

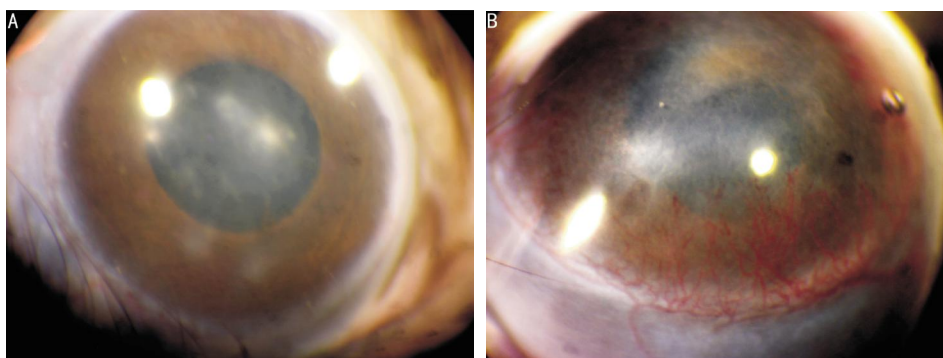


Figure 3 Representative photographs of corneal NV 14 days after Epo intrastromal injection in normal cornea A: control (saline or vector control); B: Epo injection ($6\mu\text{L}$, $1\mu\text{g}$), new vessels coming through limbal area stretching to the center of cornea

DISCUSSION

Ocular abnormal angiogenesis is the co-pathological character with a hallmark of abnormal and excessive blood vessel growth in retina, as well as in cornea. The influence of Epo on angiogenesis of retinopathy is beginning to be defined^[7]. Some evidence suggests that the role of Epo extends beyond orthogenesis. Epo has been found to promote endothelial cell proliferation and vessel growth^[8]. In the eye, Epo levels are elevated in the vitreous of patients with proliferative diabetic retinopathy, and Epo in the proliferative phase in the mouse model of retinopathy can inhibit retinal neovascularization^[3,4]. It is important to understand the role of Epo in the development of abnormal new vessels in ocular diseases. The effect of Epo on angiogenesis is likely to be important not only for retinopathy but also for other diseases as well as cornea neovascularization. However, the role of Epo in the ocular neovascularization has not been described.

Our study revealed that the Epo/EpoR was expressed in normal cornea, including epithelial cells, endothelial cells and keratocytes. We also found that the Epo and EpoR were co-expressed on the new vessels in the NV induced by alkali. Furthermore, Epo/EpoR was also observed being expressed on inflammatory cells and may have enhanced expression in epithelial cells, endothelial cells and keratocytes in NV. These evidences suggested that Epo/EpoR existed in normal cornea and on new vessels of vascularized cornea induced by alkali.

However, since previous studies which examined Epo receptor localization in the retina have been contradictory^[9,10]. This inconsistency might partially reflect the finding that Epo receptor antibodies are unreliable for immunohistochemistry^[11]. To overcome antibody nonspecificity, laser capture microdissection of corneal layers and vessels with quantitative real-time RT-PCR to localize mRNA expression of Epo and EpoR should be used in the cornea in the further study.

VEGF is probably the most important cytokine in the pathogenesis of NV. It enhances endothelial proliferation, migration, basement membrane degradation, and permeability^[12]. Although Epo and VEGF exhibit similar angiogenic potential^[13], the role of Epo in the vessel development has not been well described. Epo production appears to be independent of VEGF^[3,14]. Exogenous Epo does not change VEGF or VEGF receptor expression. In animals, an intrastromal pellet loaded with 500 or 750ng VEGF can induce corneal NV^[15].

Next, to test whether Epo protein injection can induce cornea neovascularization, we directly injected Epo protein to corneal stroma. In this study, 5 out of 6 mice were observed to have new vessels in cornea after Epo injection. However, we noticed that the new vessels did not cover the whole cornea or stretch to the center of cornea at the day 14 after injection. Epo seemed to induce corneal neovascularization not as strongly as VEGF did. One possible reason is

that the Epo's half-life is 3-4 hours in blood, and its effect probably won't be lasting long enough by only one injection without intrastromal pellet. Anyway, more models of Epo intrastromal injection are necessary and the effect of Epo should be studied further.

In summary, the current findings first provide the demonstration of Epo/EpoR expressed in normal cornea. Epo/EpoR has been associated with neovascularization in the eye, not only in retina, but also in cornea. It suggests that Epo is another important candidate factor for ocular neovascularization. It is likely that future treatments will address this and that we will have a mixture of angiogenesis inhibitors that target several angiogenic factors at the same time in treating ocular neovascularization^[16].

REFERENCES

- 1 Li D, Duan XC. Neuroprotective properties of erythropoietin on neuro-retinopathy. *Int J Ophthalmol(Guoji Yanke Zazhi)*2006;6(4):860-864
- 2 Ribatti D, Vacca A, Roccaro AM, Crivellato E, Presta M. Erythropoietin as an angiogenic factor. *Eur J Clin Invest*2003;33:891-896
- 3 Katsura Y, Okano T, Matsuno K, Osako M, Kure M, Watanabe T, Iwaki Y, Noritake M, Kosano H, Nishigori H, Matsuoka T. Erythropoietin is highly elevated in vitreous fluid of patients with proliferative diabetic retinopathy. *Diabetes Care*2005;28:2252-2254
- 4 Watanabe D, Suzuma K, Matsui S, Kurimoto M, Kiryu J, Kita M, Suzuma I, Ohashi H, Ojima T, Murakami T, Kobayashi T, Masuda S, Nagao M, Yoshimura N, Takagi H. Erythropoietin as a retinal angiogenic factor in proliferative diabetic retinopathy. *N Engl J Med*2005;353:782-792
- 5 Smith LE, Wesolowski E, McLellan A, Kostyk SK, D'Amato R, Sullivan R, D'Amore PA. Oxygen-induced retinopathy in the mouse. *Invest Ophthalmol Vis Sci*1994;35:101-111
- 6 Singh N, Jani PD, Suthar T, Amin S, Ambati BK. Flt-1 intraceptor induces the unfolded protein response, apoptotic factors, and regression of murine injury-induced corneal neovascularization. *Invest Ophthalmol Vis Sci*2006; 47 (11):4787-4793
- 7 Guo Y, Wang WH. The protective function of erythropoietin to the rat retina after acute intraocular hypertension. *Int J Ophthalmol(Guoji Yanke Zazhi)*2007;7 (3):688-691
- 8 Wang YJ, Liu S. Study advances of the protective effect of erythropoietin on retina. *Int J Ophthalmol(Guoji Yanke Zazhi)*2007;7(1):162-164
- 9 Grimm C, Wenzel A, Groszer M, Maysner H, Seeliger M, Samardzija M, Bauer C, Gassmann M, Rem CE. HIF-1-induced erythropoietin in the hypoxic retina protects against light-induced retinal degeneration. *Nat Med*2002;8:718-724
- 10 Kilic U, Kilic E, Soliz J, Bassetti CI, Gassmann M, Hermann DM. Erythropoietin protects from axotomy-induced degeneration of retinal ganglion cells by activating ERK-1/-2. *FASEB J*2005;19:249-251
- 11 Elliott S, Busse L, Bass MB, Lu H, Sarosi I, Sinclair AM, Spahr C, Um M, Van G, Begley CG. Anti-Epo receptor antibodies do not predict Epo receptor expression. *Blood*2006;107:1892-1895
- 12 Gebarowska D, Stitt AW, Gardiner TA, Harriott P, Greer B, Nelson J. Synthetic peptides interacting with the 67-kd laminin receptor can reduce retinal ischemia and inhibit hypoxia-induced retinal neovascularization. *Am J Pathol* 2002;160:307-313
- 13 Jaquet K, Krause K, Tawakol-Khodai M, Geidel S, Kuck KH. Erythropoietin and VEGF exhibit equal angiogenic potential. *Microvasc Res*2002;64:326-333
- 14 Chen J, Connor KM, Aderman CM, Smith LE. Erythropoietin deficiency decreases vascular stability in mice. *J Clin Invest*2008;118(2): 526-533
- 15 Kruse FE, Jousen AM, Rohrschneider K, Becker MD, V Icker HE. Thalidomide inhibits corneal angiogenesis induced by vascular endothelial growth factor. *Graefes Arch Clin Exp Ophthalmol*1998;236:461-466
- 16 Liu PF, Hui YN, Xie XP. Inhibitory effects of erythropoietin receptor antibody on retinal neovascularization in mice. *Int J Ophthalmol(Guoji Yanke Zazhi)*2008; 8 (3):507-509