

# Alteration of intraocular pigment epithelium-derived factor and vascular endothelial growth factor in patients with diabetic retinopathy

Lei Cui, Hai Lu

Department of Ophthalmology, Beijing Tongren Hospital, Capital Medical University, Beijing 100730, China

**Correspondence to:** Hai Lu. Department of Ophthalmology, Beijing Tongren Hospital, Capital Medical University, Beijing 100730, China. luhai@trhos.com

Received: 2008-05-12 Accepted: 2008-09-06

## Abstract

• **AIM:** To determine the aqueous, vitreous, serum levels of pigment epithelium-derived factor (PEDF) and vascular endothelial growth factor (VEGF) in patients with proliferative diabetic retinopathy (PDR), and to speculate on the source of the change in concentration and to discuss its clinical significance.

• **METHODS:** Forty-one eyes with proliferative diabetic retinopathy were included in the study, 16 of which were complicated by neovascularization of iris (NVI). Twenty-one eyes with idiopathic macular hole (MH) were as controls. The aqueous, vitreous, serum levels of PEDF and VEGF of all the groups were determined with ELISA. PEDF, VEGF and the levels in the three groups were compared with analysis of variance (ANOVA). The PEDF, VEGF concentrations in aqueous, vitreous and serum were analyzed with Pearson correlation test, and the correlation of PEDF and VEGF levels was also analyzed with Pearson correlation test.

• **RESULTS:** The aqueous levels of PEDF decreased significantly in sequence in groups of control, PDR without NVI, PDR with NVI. VEGF levels increased coordinately. The similar findings existed in vitreous samples. The PEDF, VEGF levels in aqueous were not correlated significantly with those in serum, but correlated positively with those in vitreous. The intraocular levels of PEDF had a negative correlation to those of VEGF.

• **CONCLUSION:** The reduction of intraocular PEDF level and elevation of intraocular VEGF level may play an important role in the occurrence and progression of PDR. In the development of PDR, the PEDF, VEGF levels in aqueous may be mainly effected by local pathological changes, as anti-angiogenic and pro-angiogenic factors, their unbalanced intraocular distribution may promote the angiogenesis of the iris and retina.

• **KEYWORDS:** pigment epithelium-derived factor; vascular endothelial growth factor; rubeosis iridis; diabetic retinopathy; angiogenesis

Cui L, Lu H. Alteration of intraocular pigment epithelium-derived factor and vascular endothelial growth factor in patients with diabetic retinopathy. *Int J Ophthalmol* 2008;1(4):332-335

## INTRODUCTION

Neovascular eye diseases, like age-related macular degeneration, diabetic retinopathy, neovascular glaucoma, are among the leading causes of blindness. The routine therapies usually cannot achieve satisfying results. It was found that some anti-angiogenic and pro-angiogenic cytokines, represented by pigment epithelium-derived factor (PEDF) and vascular endothelial growth factor (VEGF), opened a new field for therapeutic modalities of neovascular eye diseases. Impaired levels of PEDF and VEGF were found to be related significantly to choroidal and retinal neovascularization. Several experiments showed that, compared to controls and non-proliferative diabetic retinopathy (NPDR), the aqueous PEDF levels in patients with proliferative diabetic retinopathy (PDR) were reduced and VEGF elevated<sup>[1-3]</sup>. In our report, the aqueous, vitreous, serum levels of PEDF and VEGF were measured in patients with or without neovascularization of iris (NVI) secondary to PDR. The possible sources of the change in concentration were speculated and its clinical significance was discussed.

## MATERIALS AND METHODS

**Samples** The patients were admitted in the eye centre of Beijing Tongren Hospital between November 2005 and July 2006. Undiluted aqueous, vitreous, serum samples were collected from 62 eyes of 62 individuals who underwent pars plana vitrectomy for proliferative diabetic retinopathy and idiopathic macular hole (MH). Specimens were collected in sterile tubes, placed immediately on ice, centrifuged to separate the cell contents, and stored at -80°C until they were analyzed. The baseline characteristics of the subjects are shown in Table 1.

**PEDF Detection** The PEDF levels of various samples were measured with enzyme-linked immunosorbent assay (ELISA) kit (Chemicon International). The urea-treated samples were incubated on ice for one hour and another hour at 37°C in 96-well microplates coated by a mouse monoclonal anti-PEDF antibody. Then the plates were washed.

**Table 1 Baseline characteristics of the patients with diabetic retinopathy**

Characteristics		Macular hole (MH)(n=21)	PDR without NVI(n=25)	PDR with NVI(n=16)
Sex:	Male	9	12	7
	Female	12	13	9
Age (yr):	Mean	56.0	57.2	58.7
	Range	45-72	43-75	42-72
	Type 1 DM	0	2	0
	Type 2 DM	0	23	16

100 $\mu$ L/well biotinylated mouse anti-human PEDF monoclonal antibody was added and incubated. After washing, streptavidin peroxidase-labeled polyclonal antibody was used, and a TMB/E substrate was added. After stopped with the stop solution, the plate was read at 450nm using a microplate reader. **VEGF Detection** The concentrations of VEGF were quantitative using an ELISA kit (R&D Systems). 200 $\mu$ L diluted samples were added into each well and incubated. Then washing of the plates and adding of streptavidin peroxidase-labeled polyclonal antibody. After incubation and washing, a substrate solution was used and protected from light for 20 minutes at room temperature. The plate was read at 450nm and corrected at 540nm immediately after stopped by stop solution.

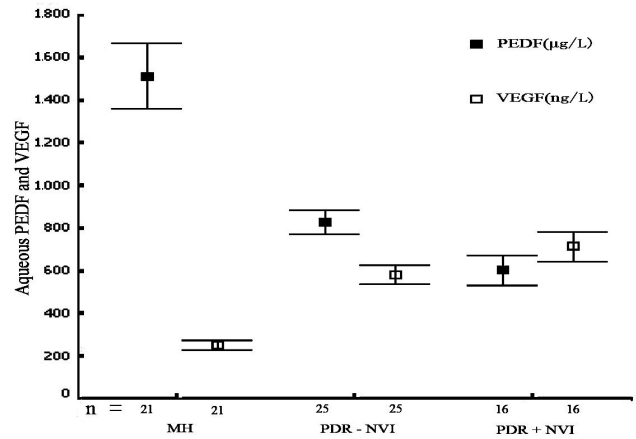
**Statistical Analysis** Statistical calculations were performed using SPSS 11.5. One-way analysis of variance (ANOVA) was used for the comparison of PEDF and VEGF levels in various groups. Correlations between groups were studied by Pearson correlation test. *P* values less than 0.05 were accepted as statistically significant.

**RESULTS**

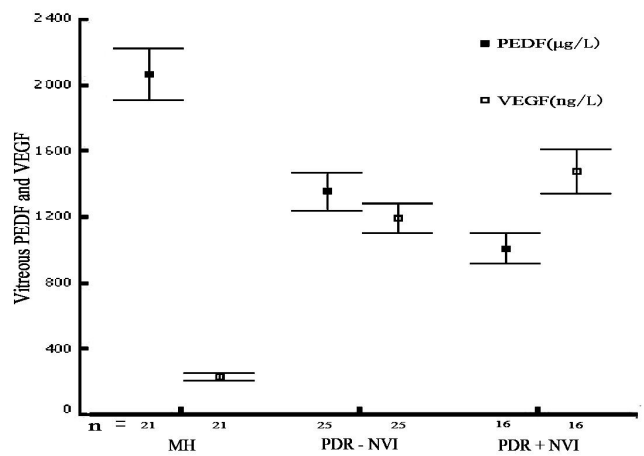
**Aqueous PEDF and VEGF** The aqueous levels of PEDF decreased significantly in sequence in groups of macular hole (MH), proliferative diabetic retinopathy (PDR) without neovascularization of iris (NVI), PDR with NVI. The aqueous levels VEGF increased significantly in sequence in groups of MH, PDR without neovascularization of NVI, PDR with NVI. Significant differences were found between any two groups (*P*<0.01, Figure 1).

**Vitreous PEDF and VEGF** The vitreous levels of PEDF decreased significantly in sequence in groups of MH, PDR without NVI, PDR with NVI. The vitreous levels of VEGF increased significantly in sequence in groups of MH, PDR without NVI, PDR with NVI. There were significant differences between any two groups (*P*<0.01, Figure 2).

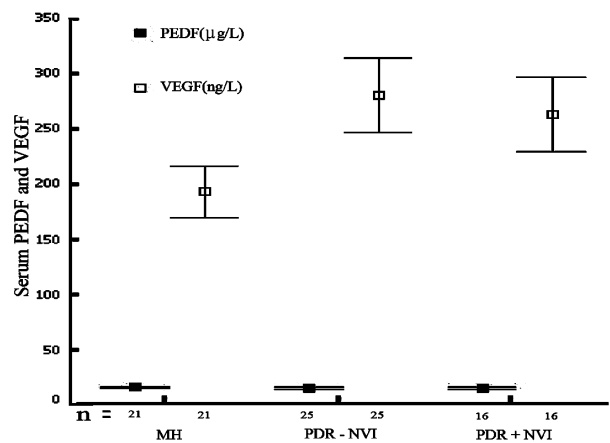
**Serum PEDF and VEGF** There was no statistical difference of serum PEDF concentrations among the three groups (*P*>0.05). The serum VEGF concentration in group PDR with NVI corresponded to that in group PDR without NVI (*P*>0.05). The serum VEGF level in either of the two groups was much higher than that in the control group (*P*<0.01, Figure 3).



**Figure 1 Aqueous PEDF and VEGF**



**Figure 2 Vitreous PEDF and VEGF**



**Figure 3 Serum PEDF and VEGF**

**Correlations of PEDF and VEGF between Aqueous and Serum/ vitreous** In the three groups, the PEDF, VEGF levels in aqueous humor were not found to correlate significantly to those in serum (*P*>0.05). Similar results were found between aqueous humor and vitreous in MH group. In PDR without NVI group, there was a positive correlation of PEDF, VEGF levels in aqueous humor and in vitreous are represented in Figures 4 and 5. In the PDR group with NVI,

## Alteration of intraocular PEDF and VEGF in PDR

the aqueous PEDF levels correlated positively to the ones of the vitreous (Figure 4), and the aqueous VEGF levels were not significantly correlated to the vitreous levels (Figure 5). In patients with PDR +/- NVI, the aqueous PEDF concentration increased with the vitreous level ( $r=0.76$ ,  $P<0.05$ ;  $r=0.53$ ,  $P<0.05$ ). No significant correlation was found in the control group ( $r=0.22$ ,  $P>0.05$ ). In group PDR without NVI, a positive correlation was found between the aqueous and vitreous VEGF levels ( $r=0.76$ ,  $P<0.01$ ). No significant correlation was found in the PDR group with NVI and in the control group ( $r=0.60$ ,  $P>0.05$ ;  $r=-0.304$ ,  $P>0.05$ ).

**Correlation of PEDF and VEGF** A negative correlation between PEDF levels and VEGF levels in aqueous was found in the three groups (Figure 6). We also found a negative correlation between PEDF levels and VEGF levels in vitreous in the three groups (Figure 7). No statistical correlation between PEDF levels and VEGF levels was found in serum. A negative correlation between PEDF levels and VEGF levels in aqueous was measured in the three groups:  $r=-0.71$ ,  $P<0.01$  in patients with NVI,  $r=-0.57$ ,  $P<0.05$  in patients without NVI,  $r=-0.69$ ,  $P<0.05$  in control group. A negative correlation between PEDF levels and VEGF levels in the vitreous was present in the three groups:  $r=-0.65$ ,  $P<0.05$  in patients with NVI,  $r=-0.66$ ,  $P<0.01$  in patients without NVI,  $r=-0.74$ ,  $P<0.01$  in control group.

## DISCUSSION

VEGF is known as an important pro-angiogenesis cytokine, which plays an important regulating role in both physiological and pathological angiogenesis process. Since PEDF was found to be a potent anti-angiogenesis factor, it has been progressively considered significant and was reported to inhibit retinal capillary endothelial cell proliferation and migration induced by VEGF. Many experiments demonstrated that, it was the impaired levels of PEDF and VEGF that may promote pathological angiogenesis [4,5]. We found that the aqueous and vitreous VEGF levels in patients with PDR were significantly higher than those of control. The aqueous and vitreous VEGF levels in patients of PDR with NVI were higher than those without PDR. On the contrary, the aqueous and vitreous PEDF levels were much lower than those of the control. The aqueous and vitreous PEDF levels in patients with PDR and NVI were lower than those without PDR. Boehm performed the ELISA and immunoblotting test to detect the aqueous PEDF and VEGF concentrations in diabetic retinopathy patients [3]. Our experiments could support the conclusion that a change in PEDF and VEGF concentrations may relate to the development of retinal neovascularization. Furthermore, we measured the aqueous levels of the two factors in patients with NVI, and found that a further decrease of PEDF and increase of VEGF may be related to NVI.

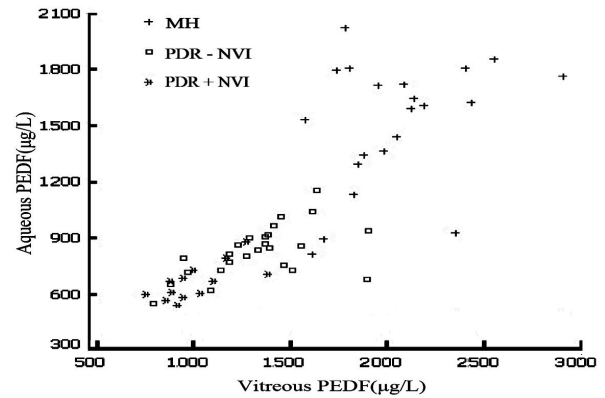


Figure 4 Relationship of PEDF between aqueous humor and vitreous

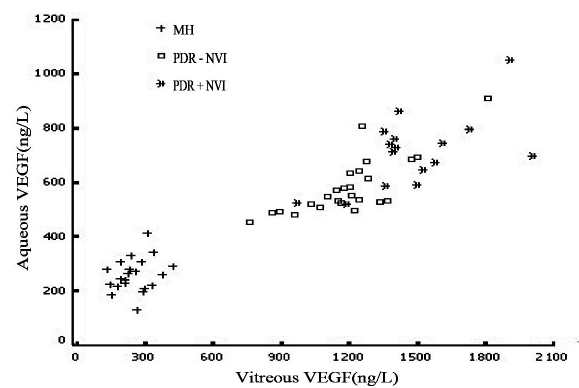


Figure 5 Relationship of VEGF between aqueous humor and vitreous

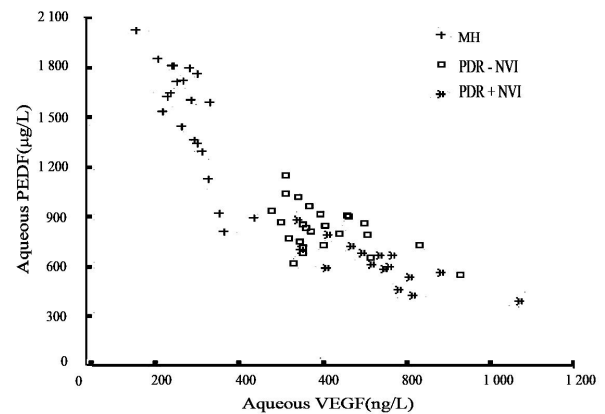


Figure 6 Correlation of PEDF and VEGF in aqueous humor

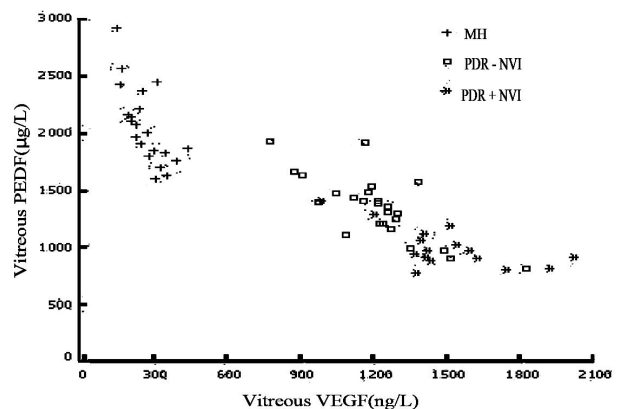


Figure 7 Correlation of PEDF and VEGF in vitreous

In aphakic eyes, the incidence of iris rubeosis after vitrectomy was higher than in phakic eyes. It has been proposed that angiogenic factors released from the ischemic retina may cause retinal and iris neovascularization [6]. We found no significant correlation of PEDF and VEGF levels between the aqueous humor and serum. This suggested that the aqueous concentrations of the two factors may be less likely influenced by systemic conditions. In the control group, the PEDF and VEGF levels in the aqueous humor did not obviously correlate to those in the vitreous. This might support the conclusion that some amount of PEDF and VEGF may be expressed in the anterior and posterior tissues to maintain its homeostasis. In normal eyes, retinal pigment epithelial cells, Müller cells, ciliary epithelial cells can express and secrete PEDF to keep the cornea and vitreous avascular. Vascular endothelial cells in iris stroma express a small amount of VEGF, which contributes to the reparation and repopulation of vascular endothelial cells [7,8]. Our results showed a positive correlation of PEDF levels between aqueous humor and vitreous in PDR patients. In the process of PDR, the decrease of aqueous PEDF concentrations may be a result of vitreous changes. The corneal endothelium and ciliary epithelium also have the function of secreting PEDF, which was not found to be lowered in the process of PDR [9]. We also found that in the PDR group without NVI, which the VEGF levels in aqueous humor positively correlated with that in the vitreous, while in the PDR group with NVI, no correlation of VEGF levels was found between the aqueous humor and the vitreous. In the ischemic diabetic retina, abundant VEGF was expressed in optic neuroganglion cells, retinal pigment epithelial cells, and retinal vascular endothelial cells. Previous studies demonstrated that no abnormal VEGF expression was found in the tissue of rubeosis iridis, including the iris pigment epithelial cell, stromal cell, and endothelial cell [10]. A great deal of VEGF expression was found only in neovascular endothelial cells on the surface of the iris. In patients with PDR, the retina with the condition of chronic ischemia secreted VEGF into the vitreous, which simultaneously diffused to the anterior segment. Once NVI developed, the iris neovascular endothelial cells may produce VEGF in a self-secreting fashion. According to previous and our experimental results, the increased aqueous VEGF levels in patients of PDR with NVI may derive from both, vitreous diffusion and iris neovascular endothelial cells secretion [11]. Our findings also demonstrated that in aqueous humor and vitreous samples, PEDF levels and VEGF levels had negative correlations, which implied that both PEDF and VEGF behaved like an antagonists to each other. This hypothesis was supported by previous researches. *In vitro*

exogenous VEGF reduced the secretion of PEDF by Müller cells. In the experimental research of retinopathy of premature, PEDF was found to be the substrate to matrix metal protease-2 and -9 (MMP-2, MMP-9). Hypoxia and VEGF resulted in degradation of PEDF by up-regulating MMP-2, MMP-9. However, the real mechanism of the interaction of PEDF and VEGF needs further study. In summary, the decrease of intraocular PEDF levels and increase of VEGF levels may play an important role in the development of PDR. In the process of PDR, the variation of the two factors of aqueous concentrations may be most of the part more locally than systematically effected. Unbalanced distribution of PEDF and VEGF in eyes may play a role in the pathogenesis of NVI and retinal neovascularization. Further research is needed to analyze the source of the changes in PEDF and VEGF levels of PDR patients; this could provide theoretical guidelines for the clinical diagnosis and treatment.

#### REFERENCES

- 1 Ohno-Matsui K, Morita I, Tombran-Tink J, Mrazek D, Onodera M, Uetama T, Hayano M, Murota SI, Mochizuki M. Novel mechanism for age-related macular degeneration: an equilibrium shift between the angiogenesis factors VEGF and PEDF. *J Cell Physiol*2001;189(3):323-333
- 2 Gao G, Li Y, Zhang D, Gee S, Crosson C, Ma J. Unbalanced expression of VEGF and PEDF in ischemia-induced retinal neovascularization. *FEBS Lett*2001;489(2-3):270-276
- 3 Boehm BO, Lang G, Feldmann B, Kurkhaus A, Rosinger S, Volpert O, Lang GK, Bouck N. Proliferative diabetic retinopathy is associated with a low level of the natural ocular anti-angiogenic agent pigment epithelium-derived factor (PEDF) in aqueous humor. A pilot study. *Horm Metab Res*2003;35(6):382-386
- 4 Dawson DW, Volpert OV, Gillis P, Crawford SE, Xu HJ, Benedict W, Bounck NP. Pigment epithelium-derived factor: a potent inhibitor of angiogenesis. *Science*1999;285(5425):245-248
- 5 Duh EJ, Yang HS, Suzuma I, Miyagi M, Youngman E, Mori K, Katai M, Yan L, Suzuma K, West K, Davarya S, Tong P, Gehlbach P, Pearlman J, Crabb JW, Aiello LP, Campochiaro PA, Zack DJ. Pigment epithelium-derived factor suppresses ischemia-induced retinal neovascularization and VEGF-induced migration and growth. *Invest Ophthalmol Vis Sci*2002;43(3):821-829
- 6 Rice TA, Michels RG, Maguire MG, Rice EF. The effect of lensectomy on the incidence of iris neovascularization and neovascular glaucoma after vitrectomy for diabetic retinopathy. *Am J Ophthalmol*1983;95(1):1-11
- 7 Ortego J, Escibano J, Becerra SP, Coca-Prados M. Gene expression of the neurotrophic pigment-epithelium derived factor in the human ciliary epithelium. *Invest Ophthalmol Vis Sci*1996;37(13):2759-2767
- 8 Eichler W, Yafai Y, Keller T, Peter W, Andreas R. PEDF derived from glial Müller cells: a possible regulator of retinal angiogenesis. *Exp Cell Res*2004;299(1):68-78
- 9 Amin RH, Frank RN, Kennedy A. Vascular endothelial growth factor is present in glial cells of the retina and optic nerve of human subjects with nonproliferative diabetic retinopathy. *Invest Ophthalmol Vis Sci*1997;38(1):36-37
- 10 Li GY, Song W, Zhang Y. Expression of vascular endothelial growth factor in the Iris with diabetic neovascular glaucoma and its clinical significance. *Chin Ophthalm Res*2000;18(5): 430-432
- 11 Notari L, Miller A, Martinez A, Amaral J, Ju M, Robinson G, Smith LEH, Becerra SP. Pigment epithelium-derived factor is a substrate for matrix metalloproteinase type 2 and type 9: implications for downregulation in hypoxia. *Invest Ophthalmol Vis Sci*2005;46(8):2736-2747