

Clinical study on "one-stitch anastomosis through the skin" repair of canalicular laceration

Hai Tao, Wei Wang, Peng Wang, Jie Zhao, Wei-Qun Yu, Hai-Yang Wu, Chuan Liu, Bao-Jie Hou, Qing Xu

Department of Ophthalmology, Armed Police General Hospital, Beijing 100039, China

Correspondence to: Hai Tao. Department of Ophthalmology, Armed Police General Hospital, Beijing 100039, China. taohaiwj@sina.com

Received:2008-03-21 Accepted:2008-05-12

Abstract

• **AIM:** To evaluate the efficacy and safety of "one-stitch anastomosis through the skin" repair of canalicular laceration. **METHODS:** The data of 32 cases (32 eyes) of canalicular laceration who underwent repair of lacerated canaliculi with one-stitch anastomosis through the skin were retrospectively reviewed, inferior canalicular laceration in 29 patients, superior canalicular laceration in 1 patient, 2 cases involving both the inferior and superior canalicular laceration. All the operations were performed under surgical microscope, 5-0 silk sutures were used and silicone tube of 0.8mm diameter was employed in intubation. The stents were left in place for 3 months postoperatively and then removed. The follow-up period was 1 to 36 months.

• **RESULTS:** In 32 patients, 28 (88%) patients were cured entirely, 3 (9%) patients were meliorated, and 1(3%) patient had no effects. A total of 29 patients complied with scheduled follow up 1-36 months (average 12 months) after stent removal, and 3 patients were lost in follow-up. All the patients had got good recovery of eyelid laceration with no traumatic deformity in eyelid and canthus.

• **CONCLUSION:** In "one-stitch anastomosis through the skin" repair of canalicular laceration, the cut ends could be anastomosed directly, for there was no suture remained in the wound permanently, so there was no suture-related granuloma which might cause obstruction or stenosis of canaliculi. It was simple, economical, effective and safe.

• **KEYWORDS:** canalicular laceration; repair; one-stitch anastomosis; through the skin

Tao H, Wang W, Wang P, Zhao Jie, Yu WQ, Wu HY, Liu C, Hou BJ, Xu Q. Clinical study on "one-stitch anastomosis through the skin"

repair of canalicular laceration. *Int J Ophthalmol* 2008;1(2):155-157

INTRODUCTION

Canalicular laceration is one of the most common ocular injuries. To achieve better outcomes of repair, the oculists had to lay stress on how to simplify the anastomosis operation and reduce postoperative stenosis or obstruction of canaliculi. Kersten *et al*^[1] reported "one-stitch" canalicular repair, a simplified approach to repair canalicular lacerations in 1996. From October 2002 to July 2006, we modified this procedure, and used "one-stitch anastomosis through the skin" approach to repair 32 cases of canalicular lacerations. This procedure has proven to be simple and safe, and better outcomes were achieved.

MATERIALS AND METHODS

Subjects Thirty-two cases of canalicular laceration were identified in our hospital and all of them were male. The age ranged from 15 to 86 years old, and the average was 36.5 years old. Right eye in 18 cases and left eye in 14 cases were selected. Inferior canalicular laceration occurred in 29 patients, superior canalicular laceration in 1 patient, 2 cases involving both the inferior and superior canalicular laceration. 24 patients underwent operations within 24 hours after injuries, 6 within 48 hours, 2 within 72 hours. The patient admission criteria are as follows: (1) proximal (medial) cut end of canalicular laceration could be found; (2) the distance between the lacrimal punctum and lacerated spot was more than 3mm; (3) not too much tissue was lost, and a good anastomosis could be performed.

Methods All lacerated canaliculi were repaired under local anesthesia. The operating microscope was available in all cases to identify the proximal (medial) cut end of the canaliculus. Once this proximal cut was identified, a silicone stent (diameter was 0.8mm) was passed through the punctum and exited at the lateral end. Under microscope magnification, the stent then was directed through the common canaliculus into lacrimal sac. The stent then was

"One-stitch anastomosis through the skin" repair of canalicular laceration

directed through the nasolacrimal duct where it was retrieved in the nose. The opposing canaliculus then was intubated similarly with the opposing end of the silicone stent. In those patients who had combined superior and inferior canalicular lacerations, similar identification of the proximal cut end had to be performed in both the upper and lower systems. The two cut ends were then anastomosed, and a 5-0 silk suture was passed in a horizontal mattress fashion through the skin. Anastomosis procedure is as follows: firstly make a suture through the skin of eyelid on the gray line 2.5mm apart from the cut end, as the needle meeting the silicone tube, go along with it, take the needle out from the distal cut end lumen; then advanced into the proximal (medial) cut end lumen 1.5mm; then prick the needle out from the skin of eyelid 2.5mm apart from the cut end; make a knot after a horizontal mattress stitch; continue suturing the skin and conjunctiva, and repair the eye lid margin; cover the wounded eye with gauze (Figure 1). We changed dressings everyday postoperatively, and took off stitches 7 days later. The stents were left in place for 3 months and then removed. At the time of silicone stent removal, probing with a probe and syringing were carried out to determine the extent of canalicular patency. The patients were scheduled for returning to the office 3 to 6 months after stent removal, during which they underwent 20g/L fluorescein drainage testing. Those patients with delay of fluorescein dye disappearance again underwent dilation and irrigation of lacrimal canals. The patients were followed up 1 to 36 months after stent removal.

Criteria for therapeutic effects: Cured entirely: no epiphora; there was no canalicular obstruction or stenosis when probing. The result of 20g/L fluorescein test is normal. Meliorated: mild epiphora or canalicular stenosis when probing. The result of 20g/L fluorescein test is normal. No effects: epiphora; obstruction occurred when probing; there was delay of dye disappearance in 20g/L fluorescein test.

RESULTS

In 32 patients, 28 (88%) patients were cured entirely, 3 (9%) patients were meliorated, and 1 (3%) patient had no effects. A mild laceration of lacrimal punctum was found in a patient 6 days postoperatively. A patient drew out the stent himself by accident, so he underwent another implantation operation and had no negative effects on recovery. A total of 29 patients complied with scheduled follow-up 1-36 months (average 12 months) after stent removal. 3 patients were lost

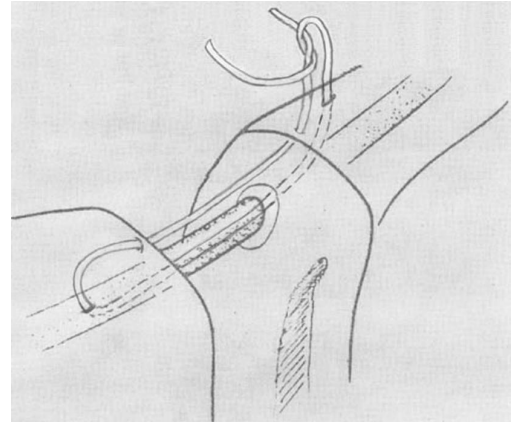


Figure 1 One-stitch anastomosis through the skin repair

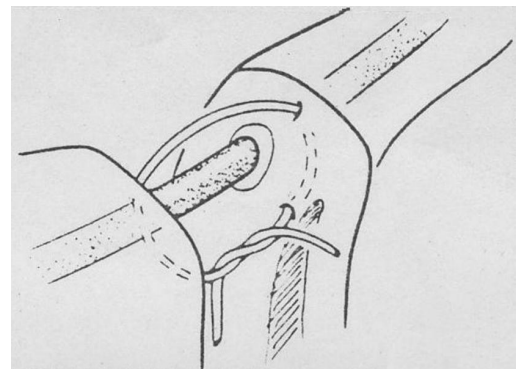


Figure 2 Kersten's "one-stitch" repair^[1]

in follow-up. All the patients had got good recovery of eyelid laceration without traumatic deformity in eyelid and canthus.

DISCUSSION

It has been widely believed that direct microsurgical reanastomosis of the canalicular epithelium is necessary for satisfactory repair of canalicular lacerations ^[1]. However, placement of multiple fine sutures through the canalicular epithelium is arduous, time consuming, and may damage the delicate tissue. The permanently remained sutures in the wound could cause inflammatory granuloma which would induce canalicular stenosis or obstruction after repair surgery. Some doctors suggest that using absorbable sutures in anastomosis, however, there were still some inflammation granulomas caused by the absorbable sutures during their absorbing process.

Kersten *et al* ^[2] reported firstly the method of one-stitch canaliculi repair which had been proven successful in 1996 (Figure 2). The method is anastomosing the two cut ends by single 7-horizontal mattress sutures, which were passed in the plane immediately anterior to the canaliculus. It reduced iatrogenic injury to lacrimal canaliculus epithelium and probability of canalicular obstruction, and simplified the

operation. Yet the two underlying canalicular edges could not be anastomosed together accurately, which might bring about a bigger scar in the anastomosis site. Some scholars suggested that 2 or 3 sutures in connective tissue surround the lacrimal canaliculus be retained with the merit of accurate anastomosis [3], but there was still probability of inflammatory granuloma and lacrimal canalicular obstruction. In 1998 we reported good effects of dacryocystorhinostomy with suspending anterior flap through the skin in treatment of chronic dacryocystitis [4]. We anastomosed underlying lumens with anterior flap suspending. The method had the merit of avoiding collapse of anterior flap and preventing development of inflammatory granuloma and lumen obstruction. We combined two kinds of technique to modify the repair of canalicular laceration, so we adopted the method of "one-stitch anastomosis through the skin" to simplify the operation and prevent lacrimal canalicular obstruction. The sutures were made through the lumen in anastomosis to confirm same layer appositions of cut ends. Furthermore, 5-0 silk suture could bear more stress, and it was economical and easier to be handled than that of 7-0 microsurgical suture.

There was no severe complication in our research. Only one patient drew out the stent himself by accident and another implantation operation was performed, but this had no negative effects on recovery.

Cautions for the operation are as follows: (1) If there was much stress in wound, 1 or 2 more stitches should be made in the soft tissue surrounding the cut ends through the skin in addition to the suture of grey line along the eyelid margin; (2) make sure the silicone tube in intubation does not induce too much traction to the lacrimal punctum; (3) make more practice and be careful when anastomosing.

Based on this research, we made following conclusion: In "one-stitch anastomosis through the skin" repair of canalicular laceration, the cut ends could be anastomosed directly, for there was no suture remained in the wound permanently, so there was no suture-related granuloma which might cause obstruction or stenosis of canaliculi. It was simple, economical, effective and safe. Of course, we hope to confirm these therapeutic effects in a greater number of cases and in longer term.

REFERENCES

- 1 Dortzbach RK, Angrst RA. Silicone intubation for lacerated lacrimal canaliculi. *Ophthalmic Surg* 1985;16(10):639-642
- 2 Kersten RC, Kulwin DR. "One-stitch" canalicular repair: a simplified approach for canalicular laceration. *Ophthalmology*, 1996;103:785-789
- 3 He SZ. *Ophthalmological Surgery Atlas*. Beijing: People Health Publishing House, 2000:41-44
- 4 Tao H, Lou Q X. Dacryocystorhinostomy suspending anterior flap through skin in treatment of chronic dacryocystitis 75 cases. *Chin J Ocular Trauma Occup Eye Dis* 1998;20(6):628-629