

A review of optic perineuritis

Evelyn Tai Li Min^{1,3}, Jessica Mani Penny Tevaraj^{1,3}, Lakana Kumar Thavaratnam^{1,3}, Raja Azmi Mohd Noor^{1,3}, Win Mar Salmah^{2,3}, Wan Hazabbah Wan Hitam^{1,3}

¹Department of Ophthalmology; ²Department of Radiology, School of Medical Sciences, Health Campus, Universiti Sains Malaysia, Kubang Kerian, Kelantan 16150, Malaysia; ³Hospital Universiti Sains Malaysia, Kubang Kerian, Kelantan 16150, Malaysia

Correspondence to: Evelyn Tai Li Min. Department of Ophthalmology, School of Medical Sciences, Health Campus, Universiti Sains Malaysia, Kubang Kerian, Kelantan 16150, Malaysia. daileid@yahoo.com

Received:2016-05-17 Accepted:2016-10-18

视神经周围炎的研究进展

Evelyn Tai Li Min^{1,3}, Jessica Mani Penny Tevaraj^{1,3}, Lakana Kumar Thavaratnam^{1,3}, Raja Azmi Mohd Noor^{1,3}, Win Mar Salmah^{2,3}, Wan Hazabbah Wan Hitam^{1,3}

(作者单位:¹马来西亚, 吉兰丹 16150, 古邦阁亮, 马来西亚理科大学, 健康卫生医学院眼科;²放射科;³马来西亚, 吉兰丹 16150, 马来西亚理科大学医院)

通讯作者:Evelyn Tai Li Min. daileid@yahoo.com

摘要

视神经周围炎(OPN)是指涉及视神经鞘膜的一系列病理性炎症。OPN的经典三联征包括单侧视神经病变伴随疼痛和/或视盘水肿,此病症与其它视神经病变相似,导致诊断延迟和治疗欠佳。2016年1月,我们对发表于Medline和Ovid数据库的关键词为“视神经周围炎”的各种语言的文献进行了检索,共查找到60篇文献,发表于1956-2015年。两位作者(Tai ELM和Tevaraj JMP)分别对论文摘要进行了独立筛选,并筛选出相关文章。本次综述,我们强调OPN的特点,特别是OPN和视神经炎之间的临床差异。虽然大多数OPN的病例是特发性的,但仍需进行调查以排除特异性感染和继发性OPN的炎症原因。MRI是非常重要的检查方法,由于OPN视神经周围炎症的影像学诊断。糖皮质激素治疗可使症状与体征迅速好转,长期口服糖皮质激素并慢速递减可以降低复发的风险。

关键词:视神经周围炎;视神经炎;视神经疾病

引用:Tai ELM, Tevaraj JMP, Thavaratnam LK, Mohd-Noor RA, Salmah WM, Wan-Hazabbah WH. 视神经周围炎的研究进展. 国际眼科杂志 2017;17(2):213-216

Abstract

• Optic perineuritis (OPN) refers to a spectrum of conditions involving pathologic inflammation of the optic nerve sheath. The classic triad of OPN consists of unilateral optic neuropathy associated with pain and/or disc oedema, but the condition often mimics other optic

neuropathies, resulting in delayed diagnosis and suboptimal treatment. We performed a database search of Medline and Ovid in January 2016 for articles published in any language with the keywords ‘optic perineuritis’. Sixty articles were found, published from 1956 to 2015. Two reviewers (Tai ELM and Tevaraj JMP) performed an independent screening of abstracts. Articles of interest were subsequently examined. In this review, we highlight the salient features of OPN, with particular emphasis on the clinical differences between OPN and optic neuritis. Although the majority of cases of OPN are idiopathic, investigations are required to rule out specific infectious and inflammatory causes of secondary OPN. MRI is an invaluable component of the workup, as radiographic demonstration of peri-neural inflammation is diagnostic of OPN. Corticosteroid therapy results in dramatic and rapid reversal of the signs and symptoms, but prolonged therapy with slow tapering of oral corticosteroids may be necessary to reduce the risk of relapses.

• **KEYWORDS:** optic perineuritis; optic neuritis; optic nerve diseases

DOI:10.3980/j.issn.1672-5123.2017.2.05

Citation:Tai ELM, Tevaraj JMP, Thavaratnam LK, Mohd-Noor RA, Salmah WM, Wan-Hazabbah WH. A review of optic perineuritis. *Guoji Yanke Zazhi(Int Eye Sci)* 2017;17(2):213-216

INTRODUCTION

Orbital inflammatory disease (OID) may involve multiple tissues, such as in diffuse anterior OID, or be restricted to specific structures, as occurs in orbital pseudotumour, myositis, periscleritis and perineuritis^[1-5]. Optic perineuritis (OPN) is a rare presentation within the spectrum of conditions classified as (OID), in which optic nerve sheath is the predominant tissue involved^[1,6-7].

First described in 1883, OPN encompasses a range of disorders characterized by pathologic inflammation of the optic nerve sheath, resulting in marked thickening due to nonspecific fibrosis^[1]. It is usually unilateral and idiopathic, although infectious^[8] and autoimmune^[9-11] causes have been reported. Clinically, this disease may mimic retrobulbar optic neuritis (ON), or cause optic disc swelling that may simulate an optic nerve sheath meningioma^[12-13] (Figure 1).

METHODS

We performed a database search of Medline and Ovid in January 2016 for articles published in any language with the keywords ‘optic perineuritis’. Sixty articles were found, published from 1956 to 2015. Two reviewers (Tai ELM and

Table 1 Key differences between optic perineuritis and optic neuritis

Features	Optic Perineuritis	Optic Neuritis
Pathology	Optic sheath inflammation	Optic nerve inflammation
Age distribution	Older	Younger
Onset of visual loss	Subacute	Acute
Scotoma	Paracentral/arcuate	Central
MRI findings	Peri-neural enhancement (‘tram track sign’ on axial view and ‘doughnut sign’ on coronal view). Fat streakiness may also be present	Intra-neural enhancement
Response to corticosteroids	Visual function often improves dramatically with corticosteroid treatment	Intravenous methylprednisolone followed by oral prednisolone may speed recovery, but does not affect final visual outcome
Relapse in relation to corticosteroid therapy	Risk of relapse if duration of corticosteroid therapy is inadequate	Higher risk of recurrence with use of oral prednisolone alone (without a preceding course of intravenous methylprednisolone)
Natural history	Progressive deterioration without treatment	Recovers spontaneously

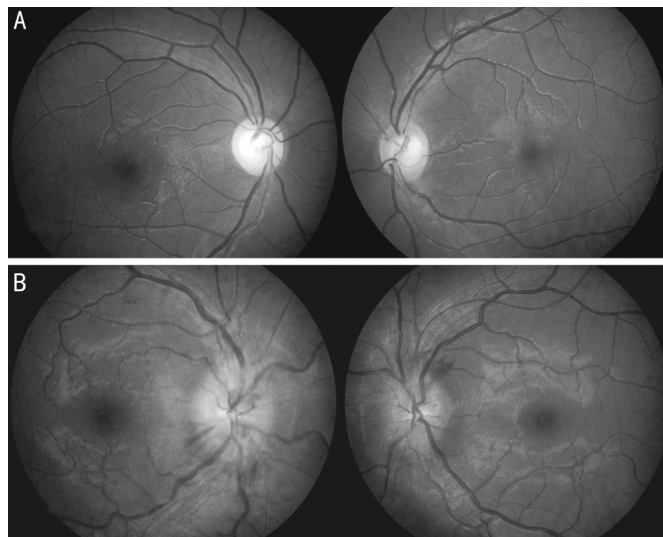


Figure 1 Fundus photos of various presentations of OPN
 A: normal optic disc, B: bilateral generalised optic disc swelling with splinter haemorrhages.

Tevaraj JMP) performed an independent screening of abstracts. Photo essays and poster abstracts were excluded. Articles of interest were subsequently examined for the clinical presentation, etiology, natural history and outcome of this condition. In cases where references to previous publications were made, we screened these references for potentially relevant studies, and where applicable, the original publication is cited.

CLINICAL FEATURES

Clinically, OPN usually presents with an optic neuropathy accompanied by pain and disc edema^[1]. Involvement tends to be unilateral, with pain exacerbated by eye movements^[1]. As most patients with OPN tend to be female, as occurs in optic neuritis (ON), it is difficult to distinguish these two on the basis of clinical presentation alone, especially as its unilateral presentation tends to mimic optic neuritis^[1,14-15]. Bilateral OPN is rare, and often attributed to underlying systemic disease^[12,16-19].

Clues to the diagnosis of OPN may be derived from minor differences between the presentation and course of OPN and ON. Firstly, the age distribution of patients with OPN is broader, and the average age of patients older than in ON, with the mean being in middle age^[1,20-21]. Secondly, patients with OPN tend to have a paracentral or arcuate scotoma, rather than the central scotoma commonly associated with ON^[1]. Thirdly, subacute onset of the disease (over weeks), with progressive visual loss without treatment, is typical of OPN^[1]. The key features differentiating optic perineuritis from optic neuritis are outlined in the following table (Table 1). Although the majority of cases of OPN are idiopathic, physical examination should be performed to look for signs of specific infectious and inflammatory causes, such as syphilis^[18], tuberculosis^[8], sarcoidosis^[9], giant cell arteritis^[19] and Wegener’s granulomatosis^[10,22]. Previous literature has attributed most cases of bilateral OPN to systemic conditions, especially syphilis^[12,16,18]. Autoimmune causes are emerging as another significant risk factor^[23-24], with a recent review observing that almost 50% of patients diagnosed with OPN over a 7 year period had associated Behcet’s disease^[25]. The majority of patients in that study were only diagnosed with Behcet’s disease after the diagnosis of OPN was made, which suggests that OPN may be a precursor to other autoimmune conditions^[25].

INVESTIGATIONS

The diagnosis of OPN itself can be confirmed by histopathologic or radiographic demonstration of peri-neural inflammation. The histological feature is inflammation of the optic nerve sheath, evidenced by a predominantly lymphocytic infiltrate and/or peri-neural fibrous tissue^[1,13,26]. However, an optic nerve biopsy is not routinely indicated, as the diagnosis may be readily made based on the clinical and radiographic findings^[1].

Radiological imaging is indispensable in making a diagnosis of OPN. The characteristic finding in OPN is contrast enhancement of the intra-orbital optic nerve sheath with

sparing of the optic nerve, seen as a ‘tram track sign’ on axial view and a ‘doughnut sign’ on coronal view^[1] (Figure 2). Although these abnormalities may be detected on computed tomography (CT) scanning, the spatial resolution of CT is insufficient to distinguish peri-neural enhancement from the intra-neural enhancement seen in demyelinating ON^[1].

Ideally, a fat-suppressed, post-gadolinium contrast magnetic resonance imaging (MRI) of the orbit should be performed to look for the classic perineural contrast enhancement of OPN^[1,21,27]. The optic nerve itself may occasionally also show enhancement, due to contiguous inflammation of the intra-neural pial septa. Other radiographic findings include streaky enhancement of orbital fat and subtle enhancement of extra-ocular muscles and/or sclera^[1]. These findings are in contrast to the radiological appearance of optic neuritis, in which the mean cross-sectional area of the optic nerve is initially increased, due to oedema; subsequently, optic atrophy usually develops^[28].

Other investigations which may be useful to rule out infectious, inflammatory or autoimmune diseases include serological tests for syphilis^[18], a Mantoux test and chest radiograph for tuberculosis^[8], serum angiotensin converting enzyme for sarcoidosis^[9], as well as erythrocyte sedimentation rate, which is usually raised in giant cell arteritis^[19], Wegener’s granulomatosis^[10,22], and Behcet’s disease^[25].

MANAGEMENT

Corticosteroid therapy in OPN is known to cause dramatic and rapid reversal of the signs and symptoms, but relapse commonly occurs with a short course of treatment^[1,6,29]. The myriad potential adverse effects of chronic use of corticosteroids have been well reported^[30-33], and may complicate the management of this condition. In some cases, vision may fail to improve despite corticosteroid therapy^[25]. The cause of the poor visual outcome has been attributed to chronic inflammatory infiltration with concentric deposition of fibro-connective tissue in the dural sheath, causing compressive optic neuropathy with ischemic infarction^[34].

It is difficult to give a conclusive statement regarding the prognosis of OPN, as the rarity of this condition precludes the availability of large, long-term studies, and most of our knowledge has been pieced together from isolated case reports or small case series^[19,21,27,35-38]. The largest case series of OPN up to date, which included 14 patients seen in 2 neuro-ophthalmology clinics, concluded that patients with OPN respond more dramatically to corticosteroids than their counterparts do in optic neuritis, but that they are more prone to recurrences after discontinuation of treatment^[1,39]. Spontaneous resolution of this condition is rarely documented^[35,40]. In our setting, we usually treat our OPN patients with an extended course of oral corticosteroids, gradually tapering the dose to a maintenance level which is continued for a period of months.

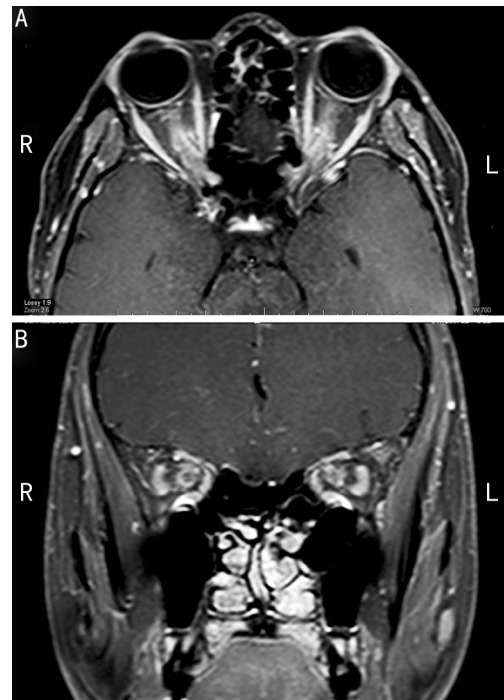


Figure 2 Contrast-enhanced MR images showing marked enhancement of the optic nerve sheath on A: Axial view (tram track sign); B: Coronal view (doughnut sign).

CONCLUSION

OPN is a rare condition. Although the classic triad of pain, optic neuropathy, and optic disc swelling is usually present, its clinical presentation may easily mimic other optic neuropathies. MRI is thus an invaluable component of the diagnostic workup of this condition. It is pertinent to keep in mind, too, that despite the dramatic response to corticosteroids, prolonged therapy, with slow tapering of the dose, may be necessary to reduce the risk of relapses.

REFERENCES

- 1 Purvin V, Kawasaki A, Jacobson DM. Optic perineuritis: clinical and radiographic features. *Arch Ophthalmol* 2001;119(9):1299-1306
- 2 Gordon LK. Diagnostic dilemmas in orbital inflammatory disease. *Ocul Immunol Inflamm* 2003;11(1):3-15
- 3 Pakdaman MN, Sepahdari AR, Elkhamary SM. Orbital inflammatory disease: Pictorial review and differential diagnosis. *World J Radiol* 2014; 6(4):106-115
- 4 Yan J, Qiu H, Wu Z, Li Y. Idiopathic orbital inflammatory pseudotumor in Chinese children. *Orbit* 2006;25(1):1-4
- 5 Yan J, Wu Z, Li Y. A clinical analysis of idiopathic orbital inflammatory pseudotumor. *Eye science* 2000;16(3):208-213
- 6 Grosso S, Cornacchione S, Romano D, Bertrando S, Franceschini R, Balestri P. Optic perineuritis: a further cause of visual loss and disc edema in children. *Brain Dev* 2014, 36(10):932-935
- 7 Nishijima H, Suzuki C, Tomiyama M. Bilateral episcleritis followed by right optic perineuritis with severe visual loss: a case report. *Neurol Sci* 2015;36(11):2139-2140
- 8 Jacob M, Kodjikian L, Ponceau B, Grange JD. Can optic perineuritis be triggered by Mycobacterium tuberculosis? *J Fr Ophthalmol* 2006; 29(3):e7
- 9 Yu-Wai-Man P, Crompton DE, Graham JY, Black FM, Dayan MR. Optic perineuritis as a rare initial presentation of sarcoidosis. *Clin Experiment Ophthalmol* 2007;35(7):682-684

- 10 Takazawa T, Ikeda K, Nagaoka T, Hirayama T, Yamamoto T, Yanagihashi M, Tochikubo T, Iwasaki Y. Wegener granulomatosis – associated optic perineuritis. *Orbit* 2014;33(1):13–16
- 11 Nakajima H, Yamane K, Kimura F, Oku H. Optic perineuritis associated with antineutrophil cytoplasmic autoantibody – related hypertrophic pachymeningitis: a case report. *Neurol Sci* 2016;37(4):641–643
- 12 Parker SE, Pula JH. Neurosyphilis presenting as asymptomatic optic perineuritis. *Case Rep Ophthalmol Med* 2012;2012:621872
- 13 Dutton JJ, Anderson RL. Idiopathic inflammatory peri optic neuritis simulating optic nerve sheath meningioma. *Am J Ophthalmol* 1985;100(3):424–430
- 14 Sadiq SB, Corbett JJ, Abubakr A. Idiopathic optic perineuritis: disguised as recurrent optic neuritis. *Clin Neurol Neurosurg* 2015;132:12–15
- 15 Ameilia A, Shatriah I, Wan–Hitam WH, Yunus R. A unilateral optic perineuritis in a teenager – A case report. *Brain Dev* 2015;37(6):635–637
- 16 O’Connell K, Marnane M, McGuigan C. Bilateral ocular perineuritis as the presenting feature of acute syphilis infection. *J Neurol* 2012;259(1):191–192
- 17 Gartaganis S, Georgiou S, Monastirli A, Katsimpris J, Pasmatzis E, Tsambaos D. Asymptomatic bilateral optic perineuritis in secondary syphilis. *Acta Derm Venereol* 2000;80(1):75–76
- 18 Meehan K, Rodman J. Ocular perineuritis secondary to neurosyphilis. *Optom Vis Sci* 2010;87(10):E790–E796
- 19 Morotti AI, Liberini P, Padovani A. Bilateral optic perineuritis as the presenting feature of giant cell arteritis. *BMJ Case Rep* 2013;2013
- 20 Tatsugawa M, Noma H, Mimura T, Funatsu H. High–dose steroid therapy for idiopathic optic perineuritis: a case series. *J Med Case Rep* 2010;4:404
- 21 Kang H M, Kim H Y. Clinical Manifestations of Idiopathic Optic Perineuritis in Korea. *J Korean Ophthalmology* 2012;53(7):1016–1022
- 22 Purvin V, Kawasaki A. Optic perineuritis secondary to Wegener’s granulomatosis. *Clin Experiment Ophthalmol* 2009;37(7):712–717
- 23 McClelland C, Zaveri M, Walsh R, Fleisher J, Galetta S. Optic perineuritis as the presenting feature of Crohn disease. *J Neuroophthalmol* 2012;32(4):345–347
- 24 Yamamoto M, Hashimoto M, Takahashi H, Shinomura Y. IgG4 disease. *J Neuroophthalmol* 2014;34(4):393–399
- 25 Lai C, Sun Y, Wang J, Purvin VA, He Y, Yang Q, Jing Y, Yin H, Zhu J. Optic Perineuritis in Behçet Disease. *J Neuroophthalmol* 2015;35(4):342–347
- 26 Margo CE, Levy MH, Beck RW. Bilateral idiopathic inflammation of the optic nerve sheaths. Light and electron microscopic findings. *Ophthalmology* 1989;96(2):200–206
- 27 Cheng AC, Chan NC, Chan CK. Acute and subacute inflammation of the optic nerve and its sheath: clinical features in Chinese patients. *Xianggang yi xue za zhi* 2012;18(2):115–122
- 28 Bennett JL, Nickerson M, Costello F, Sergott RC, Calkwood JC, Galetta SL, Balcer LJ, Markowitz CE, Vartanian T, Morrow M, Moster ML, Taylor AW, Pace TW, Frohman T, Frohman EM. Re–evaluating the treatment of acute optic neuritis. *J Neurol Neurosurg Psychiatr* 2015;86(7):799–808
- 29 Tevaraj JMP, Tai ELM, Mohd–Noor RA, Thavaratnam LK, Salmah WM, Wan–Hazabbah WH. Atypical Presentation of Idiopathic Bilateral Optic Perineuritis in a Young Patient. *Case Reports in Ophthalmological Medicine* 2016;(2016):4
- 30 Walters JA, Tan DJ, White CJ, Gibson PG, Wood–Baker R, Walters EH. Systemic corticosteroids for acute exacerbations of chronic obstructive pulmonary disease. *Cochrane Database Syst Rev* 2014;(9):CD001288
- 31 Azevedo P, Costa J, Vaz–Carneiro A. Analysis of the Cochrane Review: [Use of systemic corticosteroids for acute exacerbations of chronic obstructive pulmonary disease. *Cochrane Database Syst Rev* 2014;9:CD001288]. *Acta Med Port* 2014;27(5):537–540
- 32 Satyanarayananasetty D, Pawar K, Nadig P, Haran A. Multiple Adverse Effects of Systemic Corticosteroids: A Case Report. *J Clin Diagn Res* 2015;9(5):FD01–2
- 33 Namazy JA, Murphy VE, Powell H, Gibson PG, Chambers C, Schatz M. Effects of asthma severity, exacerbations and oral corticosteroids on perinatal outcomes. *Eur Respir J* 2013;41(5):1082–1090
- 34 Hykin PG, Spalton DJ. Bilateral perineuritis of the optic nerves. *J Neurol Neurosurg Psychiatr* 1991;54(4):375–376
- 35 Tung C, Hashemi N, Lee AG. Spontaneous resolution of optic perineuritis. *J Neuroophthalmol* 2013;33(1):93–95
- 36 Townsend JH, Dubovy SR, Pasol J, Lam BL. Transient optic perineuritis as the initial presentation of central nervous system involvement by pre–B cell lymphocytic leukemia. *J Neuroophthalmol* 2013;33(2):162–164
- 37 Byon IS, Jung JH, Kim HY, Park SW, Lee JE. Optic perineuritis secondary to acute retinal necrosis. *J Neuroophthalmol* 2013;33(4):419–421
- 38 Kim JY, Baek SH, Kim US. Recurrent abducens nerve palsy with optic perineuritis. *Int J Ophthalmol* 2012;5(2):249–250
- 39 Beck RW, Cleary PA. Optic neuritis treatment trial. One – year follow–up results. *Arch Ophthalmol* 1993;111(6):773–775
- 40 Wals KT, Ansari H, Kiss S, Langton K, Silver AJ, Odel JG. Simultaneous occurrence of neuroretinitis and optic perineuritis in a single eye. *J Neuroophthalmol* 2003;23(1):24–27