

Effects of parabolbar application of triamcinolone acetonide on uveitic macular edema with or without epiretinal membranes

Jelena Paovic¹, Predrag Paovic¹, Vojislav Sredovic²

¹Department of vitreoretinal diseases, University Eye Clinic, Clinical Center of Serbia, Belgrade 11000, Serbia; ²Department of general ophthalmology, Primary Health Care Center "Dr Dragan Funduk", Pecinci 22419, Serbia

Correspondence to: Jelena Paovic. Department of vitreoretinal diseases, University Eye Clinic, Clinical Center of Serbia, Belgrade 11000, Serbia. maliceda@eunet.rs
Received: 2015-11-17 Accepted: 2016-08-04

球周注射曲安奈德治疗葡萄膜炎并发黄斑水肿

Jelena Paovic¹, Predrag Paovic¹, Vojislav Sredovic²
(作者单位:¹11000 塞尔维亚贝尔格莱德塞尔维亚临床中心大学眼科诊所玻璃体视网膜疾病科;²22419 塞尔维亚 Pecinci 基层卫生保健中心 Dragan Funduk 医生综合眼科)
通讯作者:Jelena Paovic. 11000 塞尔维亚贝尔格莱德塞尔维亚临床中心大学眼科诊所玻璃体视网膜疾病科. maliceda@eunet.rs

摘要

目的:通过高分辨率的 OCT 参数(中央和平均黄斑厚度及体积)和它们与视觉效率的相关性来评估球周反复注射曲安奈德在有视网膜前膜下对葡萄膜炎并发黄斑水肿的影响。

方法:研究葡萄膜炎并发黄斑水肿患者共计 140 眼,基于有无视网膜前膜分为两组。球周每 3~4wk 注射一次曲安奈德(每次 40mg),共注射三次,此外所有患者还接受非甾体类抗炎药物局部治疗。相关患者还进行了视觉效率、眼内压、高分辨率谱频域 OCT 检查。

结果:在无视网膜前膜下黄斑水肿患者的最佳治疗效果的平均厚度、体积和中央厚度显著低于治疗前。在有视网膜前膜下黄斑水肿患者的体积和厚度值下降,中央厚度值增加。总之,后者从最初检查到完成治疗,眼内压和中央厚度没有统计意义上的显著差别,但平均厚度、体积统计意义上显著降低,而视觉效率显著增加。两组视觉效率与中央厚度密切相关。

结论:目前球周反复注射曲安奈德在无视网膜前膜下对葡萄膜炎并发黄斑水肿更有疗效。

关键词:葡萄膜炎;黄斑水肿;视网膜前膜;光学相干断层扫描;中央厚度;平均厚度;体积;球周;曲安奈德

引用:Paovic J, Paovic P, Sredovic V. 球周注射曲安奈德治疗葡萄膜炎并发黄斑水肿. 国际眼科杂志 2016;16(10):1805-1811

Abstract

• **AIM:** To do the assesement of the effects of repeated

parabolbar application of triamcinolone acetonide (TA) on uveitic macular edema (ME) with and without epiretinal membranes (ERM) obtained via high resolution optical coherence tomography(OCT) parameters (central and average macular thicknesses, and volume) and their correlation with visual efficiency.

• **METHODS:** This study depicts treatment results obtained for 140 eyes in patients with uveitic macular edema divided into two groups based on absence or presence of epiretinal membranes. Three repeated doses of triamcinolone acetonide (40 mg each) were parabolbarly applied every 3-4wk, and besides which all patients also received local treatment of nonsteroidal anti-inflammatory drugs. Patients' visual efficiency, intraocular pressure, and high resolution spectral domain optical coherence tomography (SD-OCT) examination was performed.

• **RESULTS:** Best results were achieved in patients with macular edema without epiretinal membranes where average values for average thickness, volume, and central field thickness were statistically significantly lower than the same values at the beginning of treatment. Following treatment of eyes with macular edema in a group with ERM, besides decreased values of volume and average thickness, there was also increased central field thickness. Overall, from initial examination to treatment completion, there was no statistically significant change of intraocular pressure and central field thickness, but there was statistically significant decrease in average thickness, volume, while visual efficiency statistically increased. In both groups visual efficiency highly correlated with central field thickness.

• **CONCLUSION:** Repeated parabolbar application of triamcinolone acetonide had better outcome on uveitic macular edema without epiretinal membranes being present.

• **KEYWORDS:** uveitis; macular edema; epiretinal membranes; optical coherence tomography; central field thickness; average thickness; volume; parabolbar; triamcinolone acetonide

DOI:10.3980/j.issn.1672-5123.2016.10.05

Citation:Paovic J, Paovic P, Sredovic V. Effects of parabolbar application of triamcinolone acetonide on uveitic macular edema with or without epiretinal membranes. *Guoji Yanke Zazhi (Int Eye Sci)* 2016;16(10):1805-1811

INTRODUCTION

Macular edema (ME) is a nonspecific condition which can manifest in a variety of diseases and pathological conditions. Uveitic ME is one the possible manifestations and most severe complications of chronic uveitis, which can result in decreased visual efficiency (VE). ME most commonly develops in patients with posterior uveitis; intermediate uveitis, and chronic retinal vasculitis. Mostly, systemic diseases such as Behcet's disease; Birdshot retinopathy, and sarcoidosis are followed by ME, which in turn can in some cases also occur in association with anterior segment inflammation particularly HLA-B27 related uveitic syndrome and juvenile rheumatoid arthritis (JRA)^[1-4].

Uveitic ME can be both intra- and extra-cellular. Intracellular edema (cytotoxic) is excess intracellular fluid accumulation which occurs due to changed ionic channels, and is generally consequence of toxic cellular damage, ischemia, or trauma. Extracellular edema can occur as consequence of blood-retinal barrier (BRB) breakdown due to release of inflammatory mediators involved in etiopathogenesis of uveitic ME. Endothelial capillary cells and those of the retinal pigment epithelium (RPE) are both the source and target of mediators such as prostaglandins; leukotrienes; cytokines: interleukin-6 (IL-6), interleukin-10 (IL-10), tumour necrosing factor- α (TNF- α); growth factors: vascular endothelial growth factor (VEGF) and others^[5-6]. Increase in numbers and adhesion of leukocytes to the blood vessels endothelial wall is mediated by adhesive molecules and nitrogen monoxide, and leads to damage of epithelial cells (EC); an increased capillary permeability; and accumulation of fluids in the retina^[7]. Seeing this, application of corticosteroids inhibits interaction between the leukocytes and blood vessels EC^[8-12].

As part of vitreomacular traction (VMT) syndromes, one of the reasons for development of uveitic ME is tractional stress on the macula caused by perifoveal vitreous adhesion^[13]. BRB breakdown comes about as consequence of tractional stress, which in turn occurs due to retinal and RPE separation, damage of Muller cells, capillary leakage and edema formation^[14-16].

Development of ME can also be influenced by numerous other factors such as hypertension and cigarette smoking^[17-18]. Additionally, local conditions, such as leakage from optic discs circulation is often associated with uveitis, and can abet and affect development of macular edema^[19].

Clinical assessment of ME depends on the following parameters: how widespread is ME; how edema is arranged in the macular region (diffused or focal); central foveal involvement; fluorescein leakage; signs of ischemia, or in other words state of perifoveal capillary network; presence or absence of vitreal traction; macular thickness; and chronicity of the edema.

Clinical symptoms and signs of macular edema (in order of appearance) are: reduced contrast and colour sensitivity, decreased VE, micropsia, metamorphopsia; and presence of central scotomas. During the course of clinical examination, significant signs of ME that can be seen are: a clinically significant foveal edema and loss of foveal reflex (in case that there is retinal thickening $>300\ \mu\text{m}$). This type of assessment of subclinical foveal edema (macular thickness $<300\ \mu\text{m}$) will however not reveal ME^[20]. As is the case with clinically significant ME, biomicroscopic assessment can show cystic spaces localized in the foveal region. Nonetheless, in most instances for diagnosing ME, both fluorescein angiography (FA) and optical coherence tomography (OCT) are used but seeing that OCT is less invasive it is the method of choice for follow-up^[19-21].

High definition OCT (HD-OCT) can show vitreoretinal surface area and its associated disorders [e. g. VMT, epiretinal membranes (ERM), etc.]^[21-22]. OCT measurement of central thickness; volume; average macular thickness and fluid distribution, allows for differentiation of diffused from cystoid edema, and at the same time progression of ME during the course of an applied therapy^[23-25]. Treatment of ME is dependant on clinical state, severity, associated active process, and localisation (unilateral or bilateral) of the disease.

Even though a consensus has not been reached as to when and how to treat it, if there is an inflammatory process at work, immediate treatment is to be applied. In case that ME is not associated with ischemia or atrophy, and in view of managing the condition, it is necessary to include systemic drugs as part of the treatment plan^[20,26]. The most common treatment of ME thus consists of oral corticosteroids in conjunction with parabolbar application of triamcinolone acetone (TA)^[26-27]. Topical application of medication is of little use with regards to posterior uveitis and ME.

The aim of this study was to asses the effects of repeated parabolbar application of TA on uveitic ME with and without ERM obtained via high resolution OCT parameters (central and average macular thicknesses, and volume) and their correlation with visual efficiency.

SUBJECTS AND METHODS

This study is comprised of 94 patients (140 eyes) suffering from uveitis with associated ME. In all cases inflammation was localized on the posterior segment of the eye (intermediate uveitis and retinal vasculitis). Depending on ME association with ERM, patients were divided in two groups.

Before each treatment application, patients VE and intraocular pressure (IOP) were taken, and biomicroscopic and Goldmann's three mirror contact lens examinations performed. Average and central macular thickness, and volume were assessed with the aid of high resolution spectral domain OCT (SD-OCT) (SOCT Copernicus).

Besides TA all patients also received topical nonsteroidal anti-inflammatory drugs (NSAIDs), corticosteroids and immunosuppressive systemic treatment. ME was in all cases an associated manifestation of an evolutive process.

Table 1 Follow-up of VE, IOP, and OCT parameters, in uveitic macular edema, during the course of treatment

Parameters	Examination and follow-up			
	Initial	2 nd	3 rd	4 th
VE	0.72±0.30	0.79±0.25	0.89±0.19	0.92±0.16
IOP	13.84±1.66	15.34±3.79	15.21±2.91	13.74±1.59
CFT	297.75±69.45	272.84±57.91	275.49±39.33	289.99±54.99
AT	305.59±27.26	289.55±21.07	296.27±14.52	292.04±20.02
VOL	7.64±0.80	7.86±1.58	7.32±0.39	7.30±0.50

VE: Visual efficiency; IOP: Intraocular pressure; CFT: Central field thickness; AT: Average thickness; VOL: Volume; OCT: Optical coherence tomography.

Patients which received more than three parabolbar applications of TA; those who were on anti-VEGF therapy; those who, due to ME, received carbonic anhydrase inhibitors; as well as those who underwent vitrectomy with membrane peeling, were excluded from this study.

All data was analysed in SPSS (version 20.0), and with the aid of various descriptive statistical tools; paired - sample t-test; one-way ANOVA (Fisher correlation coefficient) and Pearson's correlation coefficient. Confidence interval for statistical significance was 95%.

During the research, principles outlined in the Declaration of Helsinki (2008) were followed. Oral informed consent was obtained from all patients. Neither patients nor researchers received any stipend for this research.

RESULTS

Upon treatment completion, in all 140 eyes (with or without ERM) there was a statistically significant high improvement in VE ($t=9.478$; $P=0.009$) (Table 1).

Results obtained for statistical significance with regards to IOP following initial examination (before treatment) and after three consecutive parabolbar applications of TA were: $t_{1-2}=4.919$; $t_{2-3}=1.092$; $t_{3-4}=8.473$; and $P_{1-2}=0.006$; $P_{2-3}=0.277$; $P_{3-4}=0.009$; respectively. Overall average values of IOP indicated that there was no statistically significant change at the beginning and the end of treatment ($t_{1-4}=0.767$, $P_{1-4}=0.444$) (Table 1).

Results obtained for statistical significance with regards to central field thickness (CFT) following initial examination (before treatment) and after three consecutive parabolbar applications of TA were: $t_{1-2}=5.090$; $t_{2-3}=0.630$; $t_{3-4}=3.511$; and $P_{1-2}=0.002$; $P_{2-3}=0.530$; $P_{3-4}=0.001$; respectively. Overall there was no statistically significant change of CFT from initial to final examination ($t_{1-4}=1.321$, $P_{1-4}=0.189$) (Table 1).

Results obtained for statistical significance with regards to AT following initial examination (before treatment) and after three consecutive parabolbar applications of TA were: $t_{1-2}=8.527$; $t_{2-3}=4.679$; $t_{3-4}=3.269$; and $P_{1-2}=0.002$; $P_{2-3}=0.010$; $P_{3-4}=0.001$; respectively. Overall there was statistically significant decrease in AT from initial to final examination ($t_{1-4}=6.267$, $P_{1-4}=0.003$) (Table 1).

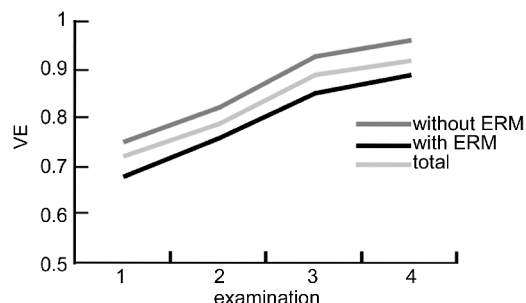


Figure 1 Visual efficiency; uveitic macular edema with and without epiretinal membranes (ERM); follow-up.

Results obtained for statistical significance with regards to volume (VOL) following initial examination (before treatment) and after three consecutive parabolbar applications of TA were: $t_{1-2}=1.446$; $t_{2-3}=4.158$; $t_{3-4}=0.658$; and $P_{1-2}=0.145$; $P_{2-3}=0.005$; $P_{3-4}=0.511$; respectively. Overall there was statistically significant decrease in VOL from initial to final examination ($t_{1-4}=5.558$, $P_{1-4}=0.004$) (Table 1).

Comparison between groups with and without ERM, from initial to final examination, showed increase of average values of VE, which was statistically significant between groups, second treatment ($F_3=7.260$, $P=0.008$), and following third treatment ($F_4=5.614$, $P=0.019$) (Table 2, Figure 1).

Comparison between groups with and without ERM, from initial to final examination, showed statistically significant increase of average values of IOP for the group without ERM comparing to the group with ERM, after first treatment ($F_2=6.726$, $P=0.011$); as well as following second treatment ($F_3=5.160$, $P=0.025$) (Table 2, Figure 2).

Initial examination illustrated higher statistically significant difference of average values of CFT for the group with ERM vs without ERM ($F_1=12.362$, $P=0.001$), whilst both groups showed a decrease of these values following initial treatment with intergroup average values difference of CFT which was of no statistical significance ($F_2=4.671$, $P=0.032$). Following second and third treatment there was a statistically significant increase for the group with ERM vs decrease in the group without ERM ($F_3=22.664$, $P=0.009$; and $F_4=449.208$, $P=0.001$; respectively) (Table 2, Figure 3). Subsequently to each treatment, as well as at the end of the entire treatment course, AT showed significant variation with

Table 2 Follow-up of VE, IOP, and OCT parameters, in uveitic macular edema with or without epiretinal membranes, during the course of treatment

Parameters	ERM	Examination and follow-up			
		Initial	2 nd	3 rd	4 th
VE	Without	0.75±0.30	0.82±0.25	0.93±0.16	0.96±0.13
	With	0.68±0.31	0.76±0.25	0.85±0.22	0.89±0.18
	Total	0.72±0.30	0.79±0.25	0.89±0.19	0.92±0.16
IOP	Without	14.01±1.72	16.16±4.23	15.76±3.08	13.84±1.75
	With	13.66±1.59	14.53±3.12	14.66±2.64	13.63±1.43
	Total	13.84±1.66	15.34±3.79	15.21±2.91	13.74±1.59
CFT	Without	277.91±54.66	262.40±49.28	260.77±19.37	242.06±12.69
	With	317.59±76.99	283.28±64.09	290.21±47.98	337.92±35.65
	Total	297.75±69.45	272.84±57.91	275.49±39.33	289.99±54.99
AT	Without	293.47±26.09	280.00±15.88	288.63±10.83	273.50±2.19
	With	317.71±22.76	299.11±21.38	303.90±13.75	310.58±10.24
	Total	305.59±27.26	289.55±21.07	296.27±14.52	292.04±20.02
VOL	Without	7.27±0.63	8.01±1.76	7.04±0.16	6.84±0.05
	With	8.02±0.78	7.71±1.39	7.60±0.34	7.77±0.26
	Total	7.64±0.80	7.86±1.58	7.32±0.39	7.30±0.50

VE; Visual efficiency; IOP; Intraocular pressure; CFT; Central field thickness; AT; Average thickness; VOL; Volume; OCT; Optical coherence tomography.

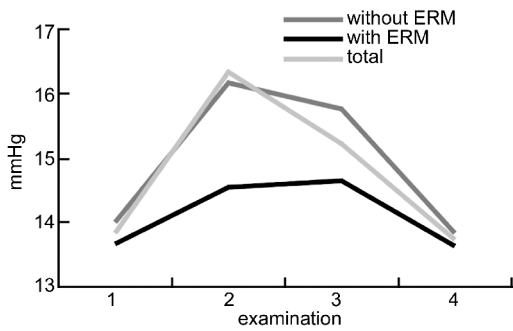


Figure 2 Intraocular pressure; uveitic macular edema with and without epiretinal membranes (ERM); follow-up.

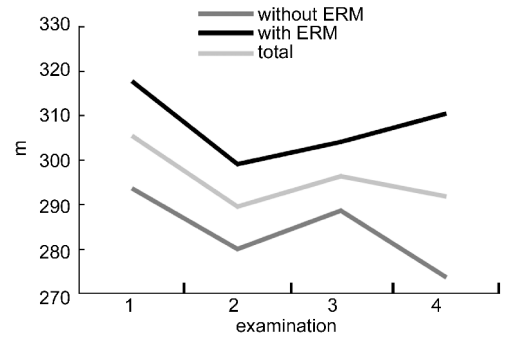


Figure 4 Average thickness; uveitic macular edema with and without epiretinal membranes (ERM); follow-up.

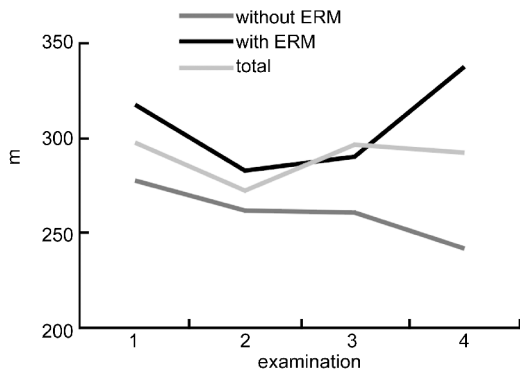


Figure 3 Central field thickness; uveitic macular edema with and without epiretinal membranes (ERM); follow-up.

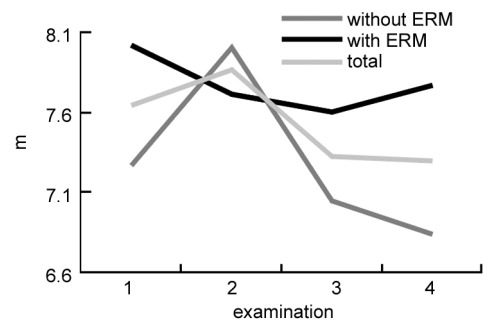


Figure 5 Volumen; uveitic macular edema with and without epiretinal membranes (ERM); follow-up.

an intergroup increase following third treatment application. These variations are substantiated by results obtained for both groups. *i. e.* group with ERM showed continual increase (and final was higher than initial), whilst group without ERM showed continual decrease of these values (Table 2, Figure 4). Intergroup average values for AT differed significantly both before treatment and following each treatment application.

However, following third parabolbar application of TA, this difference became ever higher as the statistical significance of AT within the group without ERM decreased, whilst opposite occurred in the group with ERM (but were still lower than initial ones) ($F_4 = 877.301, P = 0.001$) (Figure 4). Before treatment was initialized, intergroup results showed highly significant differences in average values of VOL ($F_1 = 38.317, P = 0.001$) (Table 2, Figure 5).

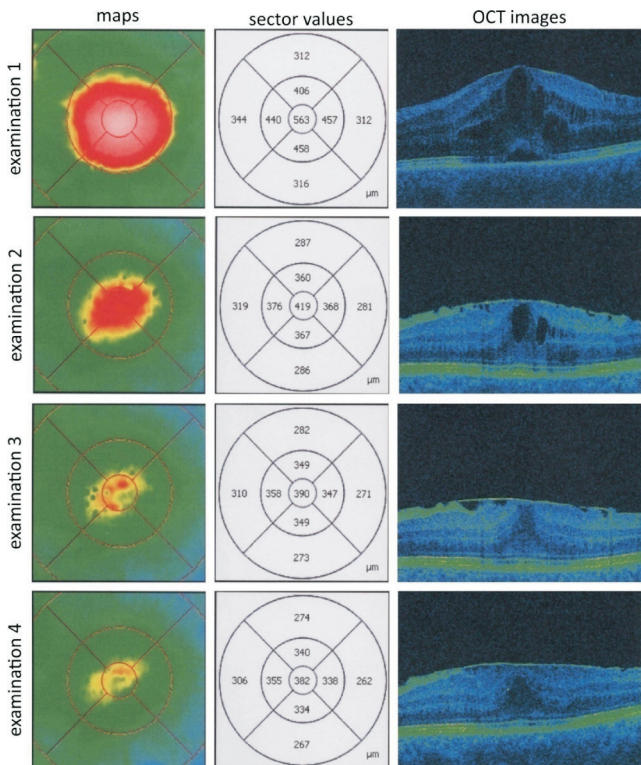


Figure 6 Uveitic macular edema with epiretinal membranes during treatment with repeated parabolbar applications of triamcinolone acetonide; OCT follow-up (maps, sector values and OCT images).

Subsequently to initial treatment, results showed lower average values of VOL in the group with ERM, whilst opposite had occurred in the group without ERM, and an intergroup difference of average values of volume had no statistical importance ($F_2 = 1.295, P = 0.257$). After second treatment there was decrease of average values of VOL in both groups, with an intergroup analysis depicting that the group without ERM had a more statistically significant one as opposed to the group with ERM ($F_3 = 152.663, P = 0.003$). Following final treatment application there was continual decrease in the group without ERM, whilst group with ERM showed increase of these values (with the final still being lower than at initial examination) ($F_4 = 874.556, P = 0.001$) (Figure 5).

OCT follow up of a patient with uveitic ME and ERM reveals decrease of all relevant parameters and increased VE, but even though CFT had decreased it had not reached normal limits at the time of parabolbar TA treatment completion (Figure 6, 7). For these reasons parsplana vitrectomy (PPV) with membrane peeling was applied.

Correlation between VE, IOP, and OCT parameters showed that: At the beginning of treatment VE had negative correlation with VOL which was of no statistical significance (correlation coefficient = $-0.127, P = 0.136$), while this negative correlation was upon treatment completion of statistical significance (correlation coefficient = $-0.196, P = 0.020$). VE also showed negative correlation with CFT (upon treatment commencement) which was of no statistical importance (correlation coefficient = $-0.192, P = 0.230$).

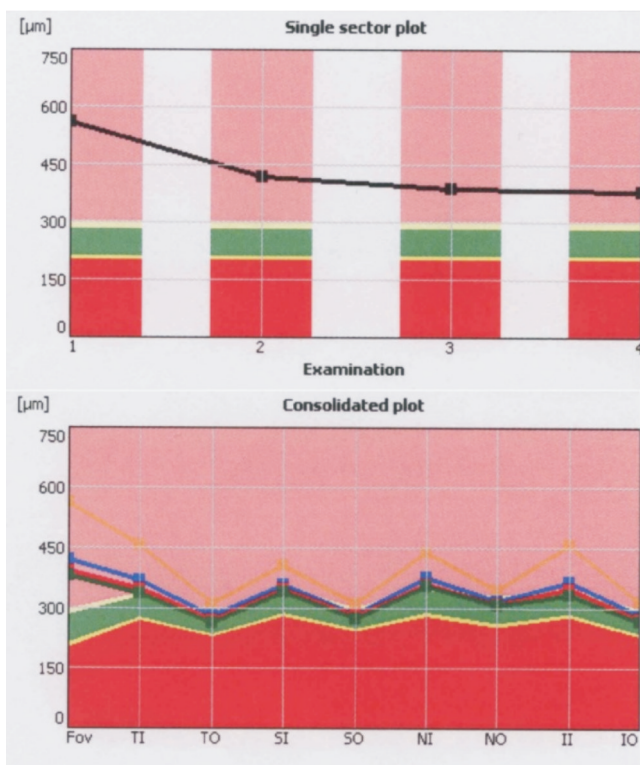


Figure 7 Uveitic macular edema with epiretinal membranes during treatment with repeated parabolbar applications of triamcinolone acetonide; OCT follow-up (single and consolidated plots).

Upon treatment completion CFT had high statistically significant negative correlation (correlation coefficient = $-0.228, P = 0.007$). Statistically significant negative correlation was also confirmed between VE and AT, both at the beginning (highly significant negative correlation) and at the end of treatment (correlation coefficient = $-0.250, P = 0.003$; correlation coefficient = $-0.196, P = 0.020$; respectively) (Tables 3,4).

DISCUSSION

ME is a common complication of uveitis that occurs on the posterior segment of the eye, and can either be diffused or focal, with or without ERM. Inflammatory mediators associated with uveitis disrupt the inner and outer BRB thus leading to accumulated levels of fluid in the retina. *i. e.* edema, which if left untreated becomes chronic in nature and may lead do permanently damaged central vision. There exist many factors that can be responsible for decreased central visual acuity. As a line which separates inner and outer segments (IS/OS) of photoreceptors gets disrupted, one can expect a worse visual outcome (*e. g.* in case of chronic edemas), thus making OCT an irreplaceable tool for diagnosing structural macular changes^[2,28-29].

Initial treatment of acute bilateral inflammation associated with ME consists of systemic corticosteroids applied until such time when control over the previously mentioned state has been reached. It has been shown that by inhibition of enzyme phospholipase A2 corticosteroids also decrease production of prostaglandins and leukotrienes^[29-30]. Additionally, one of the

Table 3 Correlation matrix of VE, IOP, and OCT parameters

Parameters	VE				IOP			
	1 st	2 nd	3 rd	4 th	1 st	2 nd	3 rd	4 th
1 st	1	0.807 ^b	0.625 ^b	0.539 ^b	-0.020	-0.079	-0.052	-0.122
2 nd	0.807 ^b	1	0.744 ^b	0.698 ^b	-0.013	-0.086	-0.058	-0.078
3 rd	0.625 ^b	0.744 ^b	1	0.904 ^b	-0.009	-0.004	0.005	-0.054
4 th	0.539 ^b	0.698 ^b	0.904 ^b	1	0.002	0.030	0.057	0.017

VE: Visual efficiency; IOP: Intraocular pressure; OCT: Optical coherence tomography.

Table 4 Correlation matrix of OCT parameters

Parameters	CFT				AV				VOL			
	1 st	2 nd	3 rd	4 th	1 st	2 nd	3 rd	4 th	1 st	2 nd	3 rd	4 th
1 st	-0.192 ^a	-0.161	-0.154	-0.170 ^a	-0.250 ^b	-0.077	-0.155	-0.111	-0.127	-0.089	-0.138	-0.111
2 nd	-0.164	-0.204 ^a	-0.142	-0.162	-0.285 ^b	-0.153	-0.154	-0.105	-0.157	-0.125	-0.121	-0.105
3 rd	-0.239 ^b	-0.332 ^b	-0.176 ^a	-0.306 ^b	-0.295 ^b	-0.225 ^b	-0.231 ^b	-0.232 ^b	-0.184 ^a	-0.133	-0.230 ^b	-0.232 ^b
4 th	-0.128	-0.272 ^b	-0.130	-0.228 ^b	-0.213 ^a	-0.070	-0.198 ^a	-0.196 ^a	-0.127	-0.096	-0.205 ^a	-0.196 ^a

1st: Initial examination; VE: Visual efficiency; CFT: Central field thickness; AT: Average thickness; VOL: Volume; ^a: Correlation is significant at the 0.05 level; ^b: Correlation is significant at the level 0.01; OCT: Optical coherence tomography.

roles of corticosteroids is to inhibit VEGF production through platelet-derived growth factor-dependent activation and to inhibit IL-6 by blocking their receptors^[30]. It has been shown that the manner in which various agents have been applied (intravitreally or subtenonally) has similar outcomes.

Corticosteroid delivery systems which are usually used in treatment of unilateral uveitic ME may be applied parabolbarly (along the orbital floor) or subtenonally (continually along the sclera in order to increase absorption), where Noziks' technique or episcleral canella via Tenons' capsule are used for the later^[31-34]. Through constant monitoring of VE, IOP, and OCT parameters one can follow the effects of parabolbar injection of TA^[35-38].

Intravitreal application of TA as well as slow release intravitreal delivery systems (dexamethasone and fluocinolone implants) are associated with higher risk of complications (*i.e.* endophthalmitis and intraocular hypertension)^[33-37].

The entire group consisted of patients with ME treated with systemic medication due to uveitic inflammation (intermediate uveitis or vasculitis). Uveitic ME was further treated by repeated parabolbar TA (40 mg applied every 3-4wk). Subsequent to third application of TA, in all 140 eyes with ME, with or without associated ERM, there was statistically significant decrease of parameters such as AT, and VOL, whilst CFT demonstrate a decrease which was not statistically significant. Following initial treatment there were decreased average values of two OCT parameters: CFT and AT in both groups, while average values of Vol. showed an increase in the group without ERM. At the end of treatment this latter group depicted a continual decrease of values and a statistically significant difference was reached in relation to the initial examination. Overall at the end of treatment followup, the group with ERM had increased average CFT values.

Macular volume generally depends on the degree of

inflammation and thus in these cases volume decreased irrelevant of presence or absence of ERM. Seeing that ME associated with ERM generally occurs due to VMT, medical treatment alone is insufficient and thus further surgical PPV with membrane peeling is required.

Changes in IOP were of no statistical importance.

The best correlation was achieved between VE and CFT, or in other words VE mostly depends on CFT. Negative correlation that exists between VE, AT, and VOL is not highly statistically significant. So, best results were achieved in patients with ME without ERM where average values for all three OCT parameters were statistically significantly lower than the same values at the beginning of treatment.

Second group of drugs which is used in treatment of ME are carbonic anhydrase inhibitors whose aim is to modulate distribution of carbonic anhydrase on the level of RPE, thus allowing for reabsorption of fluids from retina and choroidea, and so approximately 70% of subretinal fluid is, under normal circumstances, and via metabolic transport, moved to the choroid.

In treatment of uveitic ME, besides carbonic anhydrase inhibitors and corticosteroid medication, there is a use for anti-VEGF therapy as well^[5,38-39].

Moreover, it has been shown that besides previously mentioned agents certain cytokines such as TNF- α and IL-6 have been especially associated to the severity of uveitis, in view of which anti-TNF- α and anti-IL-6 agents are deemed to be of use^[39-40].

Surgical treatment of ME is applied in case of structural macular changes as consequence of VMT. Pharmacological vitreolysis or mechanical release of traction could lead to reduced ME.

REFERENCES

1 Lardenoye CW, van Kooij B, Rothova A. Impact of macular edema on visual acuity in uveitis. *Ophthalmology* 2006;113(8):1446-1449
 2 Monnet D, Levinson RD, Holland GN, Haddad L, Yu F, Brézín AP.

- Longitudinal cohort study of patients with birdshot chorioretinopathy. III. Macular imaging at baseline. *Am J Ophthalmol* 2007;144(6):818–828
- 3 Johnson MW. Etiology and treatment of macular edema. *Am J Ophthalmol* 2009;147(1):11–21. e1
- 4 Paovic J, Paovic P, Sredovic V. Behcet's disease: systemic and ocular manifestations. *Biomed Res Int* 2013;2013:247345
- 5 van Kooij B, Rothova A, Rijkers GT, de Groot–Mijnes JD. Distinct cytokine and chemokine profiles in the aqueous of patients with uveitis and cystoid macular edema. *Am J Ophthalmol* 2006;142(1):192–194
- 6 Curnow SJ, Falciani F, Durrani OM, Cheung CM, Ross EJ, Wloka K, Rauz S, Wallace GR, Salmon M, Murray PI. Multiplex bead immunoassay analysis of aqueous humor reveals distinct cytokine profiles in uveitis. *Invest Ophthalmol Vis Sci* 2005;46(11):4251–4259
- 7 Leal EC, Manivannan A, Hosoya K, Terasaki T, Cunha – Vaz J, Ambrósio AF, Forrester JV. Inducible nitric oxide synthase isoform is a key mediator of leukostasis and blood – retinal barrier breakdown in diabetic retinopathy. *Invest Ophthalmol Vis Sci* 2007;48(11):5257–5265
- 8 Mizuno S, Nishiwaki A, Morita H, Miyake T, Ogura Y. Effects of periocular administration of triamcinolone acetonide on leukocyte – endothelium interactions in the ischemic retina. *Invest Ophthalmol Vis Sci* 2007;48(6):2831–2836
- 9 Catier A, Tadayoni R, Paques M, Erginay A, Haouchine B, Gaudric A, Massin P. Characterization of macular edema from various etiologies by optical coherence tomography. *Am J Ophthalmol* 2005;140(2):200–206
- 10 Tran TH, de Smet MD, Bodaghi B, Fardeau C, Cassoux N, Lehoang P. Uveitic macular oedema: correlation between optical coherence tomography patterns with visual acuity and fluorescein angiography. *Br J Ophthalmol* 2008;92(7):922–927
- 11 Scholl S, Kirchhof J, Augustin AJ. Pathophysiology of macular edema. *Ophthalmologica* 2010;224(Suppl 1):8–15
- 12 Scholl S, Augustin A, Loewenstein A, Rizzo S, Kupperman B. General pathophysiology of macular edema. *Eur J Ophthalmol* 2011;21(Suppl 6):S10–S19
- 13 Bottós J, Elizalde J, Rodrigues EB, Farah M, Maia M. Classifications of vitreomacular traction syndrome: diameter vs morphology. *Eye (Lond)* 2014;28(9):1107–1112
- 14 Lindqvist N, Liu Q, Zajadacz J, Franze K, Reichenbach A. Retinal glial (Müller) cells: sensing and responding to tissue stretch. *Invest Ophthalmol Vis Sci* 2010;51(3):1683–1690
- 15 Augustin A, Loewenstein A, Kuppermann BD. Macular edema. General pathophysiology. *Dev Ophthalmol* 2010;47:10–26
- 16 Praidou A, Papakonstantinou E, Androudi S, Georgiadis N, Karakiulakis G, Dimitrakos S. Vitreous and serum levels of vascular endothelial growth factor and platelet – derived growth factor and their correlation in patients with non – proliferative diabetic retinopathy and clinically significant macula oedema. *Acta Ophthalmol* 2011;89(3):248–254
- 17 Lin P, Loh AR, Margolis TP, Acharya NR. Cigarette smoking as a risk factor for uveitis. *Ophthalmology* 2010;117(3):585–590
- 18 Thorne JE, Daniel E, Jabs DA, Kedhar SR, Peters GB, Dunn JP. Smoking as a risk factor for cystoid macular edema complicating intermediate uveitis. *Am J Ophthalmol* 2008;145(5):841–846
- 19 van Kooij B, Probst K, Fijnheer R, Roest M, de Loos W, Rothova A. Risk factors for cystoid macular oedema in patients with uveitis. *Eye (Lond)* 2008;22(2):256–260
- 20 Staurenghi G, Invernizzi A, de Polo L, Pellegrini M. Macular edema. Diagnosis and detection. *Dev Ophthalmol* 2010;47:27–48
- 21 Legarreta JE, Gregori G, Knighton RW, Punjabi OS, Lalwani GA, Puliafito CA. Three – dimensional spectral – domain optical coherence tomography images of the retina in the presence of epiretinal membranes. *Am J Ophthalmol* 2008;145(6):1023–1030
- 22 Gupta V, Gupta P, Singh R, Dogra MR, Gupta A. Spectral–domain Cirrus high–definition optical coherence tomography is better than time– domain Stratus optical coherence tomography for evaluation of macular pathologic features in uveitis. *Am J Ophthalmol* 2008;145(6):1018–1022
- 23 Shelsta HN, Jampol LM. Pharmacologic therapy of pseudophakic cystoid macular edema: 2010 update. *Retina (Philadelphia, Pa)* 2011;31(1):4–12
- 24 Roesel M, Henschel A, Heinz C, Spital G, Heiligenhaus A. Time– domain and spectral – domain optical coherence tomography in uveitic macular edema. *Am J Ophthalmol* 2008;146(4):626–627
- 25 Onal S, Tugal–Tutkun I, Neri P, P Herbort C. Optical coherence tomography imaging in uveitis. *Int Ophthalmol* 2014;34(2):401–435
- 26 Rhen T, Cidrowski JA. Antiinflammatory action of glucocorticoids – new mechanisms for old drugs. *N Engl J Med* 2005;353(16):1711–1723
- 27 Venkatesh P, Abhas Z, Garg S, Vohra R. Prospective optical coherence tomographic evaluation of the efficacy of oral and posterior subtenon corticosteroids in patients with intermediate uveitis. *Graefes Arch Clin Exp Ophthalmol* 2007;245(1):59–67
- 28 Roesel M, Henschel A, Heinz C, Dietzel M, Spital G, Heiligenhaus A. Fundus autofluorescence and spectral domain optical coherence tomography in uveitic macular edema. *Graefes Arch Clin Exp Ophthalmol* 2009;247(12):1685–1689
- 29 Paovic J, Paovic P, Paovic AS, Sredovic V. Diagnostic Procedures and Follow Up of Macular Microstructural Changes in Patients with Uveitis as Seen on Optical Coherence Tomography. *J Cytol Histol* 2014;5(2):211–218
- 30 Cunningham MA, Edelman JL, Kaushal S. Intravitreal steroids for macular edema: the past, the present, and the future. *Surv Ophthalmol* 2008;53(2):139–149
- 31 Sallam A, Comer RM, Chang JH, Grigg JR, Andrews R, McCluskey PJ, Lightman S. Short – term safety and efficacy of intravitreal triamcinolone acetonide for uveitic macular edema in children. *Arch Ophthalmol* 2008;126(2):200–205
- 32 Sen HN, Vitale S, Gangaputra SS, Nussenblatt RB, Liesegang TL, Levy–Clarke GA, Rosenbaum JT, Suhler EB, Thorne JE, Foster CS, Jabs DA, Kempen JH. Periocular corticosteroid injections in uveitis: effects and complications. *Ophthalmology* 2014;121(11):2275–2286
- 33 Kok H, Lau C, Maycock N, McCluskey P, Lightman S. Outcome of intravitreal triamcinolone in uveitis. *Ophthalmology* 2005;112(11):1916–1911
- 34 Yamamoto Y, Komatsu T, Koura Y, Nishino K, Fukushima A, Ueno H. Intraocular pressure elevation after intravitreal or posterior sub–Tenon triamcinolone acetonide injection. *Can J Ophthalmol* 2008;43(1):42–47
- 35 Bleriot A, Couret C, Le Meur G, Lebranchu P, Weber M. Safety and efficacy of subconjunctival triamcinolone injections in the management of uveitic macular edema: retrospective study of thirty – one cases. *J Fr Ophthalmol* 2014;37(8):599–604
- 36 Maca SM, Abela – Formanek C, Kiss CG, Sacu SG, Benesch T, Barisani – Asenbauer T. Intravitreal triamcinolone for persistent cystoid macular oedema in eyes with quiescent uveitis. *Clin Experiment Ophthalmol* 2009;37(4):389–396
- 37 Deuter CM, Koetter I, Guenaydin I, Stuebiger N, Zierhut M. Interferon alfa – 2a: a new treatment option for long lasting refractory cystoid macular edema in uveitis? A pilot study. *Retina (Philadelphia, Pa)* 2006;26(7):786–791
- 38 Thomas ER, Wang J, Ege E, Madsen R, Hainsworth DP. Intravitreal triamcinolone acetonide concentration after subtenon injection. *Am J Ophthalmol* 2006;142(5):860–861
- 39 Harhaj NS, Felinski EA, Wolpert EB, Sundstrom JM, Gardner TW, Antonetti DA. VEGF activation of protein kinase C stimulates occludin phosphorylation and contributes to endothelial permeability. *Invest Ophthalmol Vis Sci* 2006;47(11):5106–5115
- 40 Rothova A. Inflammatory cystoid macular edema. *Curr Opin Ophthalmol* 2007;18(6):487–492