

Interleukin – 8 and tumor necrosis factor – α levels in vitreous samples from patients with diabetic retinopathy

Rifat Rasier¹, Ozgur Artunay², Uzay Gormus³, Erdal Yuzbasioglu¹, Alper Sengul¹, Amber Senel Kukner¹, Murat Oncel¹, Halil Bahcecioglu¹

¹Department of Ophthalmology, School of Medicine, Istanbul Bilim University, Istanbul 34381, Turkey

²Department of Ophthalmology, School of Medicine, Bezmialem Vakif University, Istanbul 34381, Turkey

³Department of Biochemistry, School of Medicine, Istanbul Bilim University, Istanbul 34381, Turkey

Correspondence to: Amber Senel Kukner. Sisli Florence Nigthingale Hospital, Sisli, Istanbul 34381, Turkey. ambersenel@gmail.com

Received: 2013-07-23 Accepted: 2013-11-18

糖尿病视网膜病变患者玻璃体样本中白细胞介素-8和肿瘤坏死因子- α 水平

Rifat Rasier¹, Ozgur Artunay², Uzay Gormus³, Erdal Yuzbasioglu¹, Alper Sengul¹, Amber Senel Kukner¹, Murat Oncel¹, Halil Bahcecioglu¹

(作者单位:¹土耳其,伊斯坦布尔 34381,伊斯坦布尔 Bilim 大学医学院眼科系;²土耳其,伊斯坦布尔 34381, Bezmialem Vakif 大学医学院眼科系;³土耳其,伊斯坦布尔 34381,伊斯坦布尔 Bilim 大学医学院生物化学系)

通讯作者:Amber Senel Kukner. ambersenel@gmail.com

摘要

目的:测量糖尿病性视网膜病变(DR)行玻璃体切除术(PPV)患者玻璃体样品中白细胞介素-8(IL-8),肿瘤坏死因子- α (TNF- α)的水平,与对照组比较结果并探讨其对DR的影响。

方法:将伊斯坦布尔 Bilim 大学眼科系的 57 例(57 眼)DR 患者和 22 例黄斑裂孔未伴有增生性玻璃体视网膜病变患者分为研究组和对照组。对所有 79 例患者行 3 切口,20G PPV。PPV 手术眼内灌注前,用 Vitrector 抽吸 0.5mL 玻璃体样品并稀释。样品转至冷藏室,存放在-70℃。IL-8 和 TNF- α 的测量结果用酶联免疫吸附法以 pg/mL 为单位计算。

结果:DR 患者玻璃体样本中 IL-8 水平[82.7891±74.08700(0.08-307.09)pg/mL]明显高于对照组患者[2.9805±3.77546(0.08-18.53)pg/mL]($P<0.001$)。同样,DR 患者 TNF- α 水平[18.0007±13.90015(2.32-51.11)pg/mL]也显著高于对照组[1.7005±1.26949(0.1-5.17)pg/mL]($P<0.001$)。

结论:在视网膜新生血管形成中起重要作用的 TNF- α 和

作为炎症和血管生成介体的 IL-8 水平在 DR 患者玻璃体样本中明显高。

关键词:糖尿病性视网膜病变;白细胞介素-8;玻璃体切除术;肿瘤坏死因子- α

引用:Rasier R, Artunay O, Gormus U, Yuzbasioglu E, Sengul A, Kukner AS, Oncel M, Bahcecioglu H. 糖尿病视网膜病变患者玻璃体样本中白细胞介素-8 和肿瘤坏死因子- α 水平. 国际眼科杂志 2013;13(12):2365-2369

Abstract

• **AIM:** To measure the interleukin-8 (IL-8) and tumor necrosis factor- α (TNF- α) levels in vitreous samples obtained the patients undergoing pars plana vitrectomy (PPV) due to diabetic retinopathy (DR), then to compare these results with those of the control group and to state their impact on DR pathogenesis.

• **METHODS:** From Istanbul Bilim University Ophthalmology Department, 57 eyes of 57 diabetes mellitus (DM) patients who had been diagnosed with proliferative diabetic retinopathy and 22 cases of macular hole, with no proliferative vitreoretinopathy were included in the study as the study and the control groups respectively. All of the 79 patients underwent a 3-port, 20 gauge PPV. Vitreous samples of 0.5mL were aspirated with vitrector at the beginning of the PPV operation before the intraocular infusion and being diluted. Samples were transferred to the freezer to be stored at -70℃. Results of IL-8 and TNF- α were calculated as pg/mL with ELISA method.

• **RESULTS:** IL-8 levels [82.7891±74.08700(0.08-307.09)pg/mL] in which vitreous samples obtained DR patients during vitrectomy were significantly elevated when compared to IL-8 levels [2.9805±3.77546(0.08-18.53)pg/mL] of control patients ($P<0.001$). Similarly, TNF- α level [18.0007±13.90015(2.32-51.11)pg/mL] was also significantly elevated in DR patients when compared to control patients' TNF- α level [1.7005±1.26949(0.1-5.17)pg/mL] ($P<0.001$).

• **CONCLUSION:** The levels of TNF- α , which plays a role in retinal neovascularization, and, IL-8, which acts as an inflammatory and angiogenic mediator were found to be high in DR patients.

• **KEYWORDS:** diabetic retinopathy; interleukin - 8; pars plana vitrectomy; tumor necrosis factor- α
DOI:10.3980/j.issn.1672-5123.2013.12.01

Citation: Rasier R, Artunay O, Gormus U, Yuzbasioglu E, Sengul A, Kukner AS, Oncel M, Bahcecioglu H. Interleukin-8 and tumor necrosis factor - α levels in vitreous samples from patients with diabetic retinopathy. *Guoji Yanke Zazhi (Int Eye Sci)* 2013; 13 (12):2365-2369

INTRODUCTION

Diabetes mellitus (DM), characterized by lack of insulin or peripheral insulin insensitivity is a multisystem disease that also impacts humoral responses and tissues, and also entails carbohydrate, protein and lipid metabolism impairments. The metabolic processes that cause diabetic retinopathy (DR) are not completely defined yet. There are several theories that relate aldose reductase, vasoproliferative factors, growth hormone, and platelet and blood viscosity to retinopathy. Interleukin-8 (IL-8), is a member of the family formed by many structurally homologous cytokines, which are produced in T cells, fibroblasts, endothelial cells, keratinocytes, neutrophils, epithelial cells, and mononuclear phagocytes that are activated by antigens^[1,2]. Its synthesis can be started rapidly by cytokines such as interleukin-1 (IL-1) and tumor necrosis factor (TNF). Polymorphonuclear leukocytes, monocytes and macrophages are shown to be secreted after endotoxemia.

IL-8 molecule is accepted as a proinflammatory mediator that has a chemotactic effect on neutrophils. IL-8 is a powerful activator of neutrophils and eosinophils, and is recognized to reduce IgE production in B lymphocytes by increasing interleukin-4 (IL-4) production^[1,3]. Neutrophil activation initiated by TNF and IL-1 is associated with production of mainly IL-8 stimulated by TNF and IL-1, and the associated proteins. IL-8 and cytokines of this family act as secondary regulators in inflammation. IL-8 accelerates the adhesion of neutrophils to endothelial cells and the matrix proteins under the endothelial cells. IL-8 enables neutrophils after stimulation to bond to endothelial cells and to pass into the parenchyma afterwards. IL-8 is shown to be produced from glial and endothelial cells in the retina as a result of angiogenesis occurring in ischemic conditions^[4,5].

Mononuclear phagocytes are the source of TNF. T cells, activated Natural Killer (NK) cells and activated mast cells secrete this protein. TNF is a local paracrine and autocrine regulator for leukocytes and endothelial cells in low concentrations. Plasma TNF levels in healthy individuals range between 0 and 35pg/mL. There are two types of TNF:

1) TNF - α (also called cachectin) secreted from active macrophages; 2) TNF - β (lymphotoxin) secreted from active T cells^[6,7]. TNF - α is an important cytokine that causes immune, metabolic, and inflammatory events and plays a role in neovascular formations. TNF - α has a mediating and regulating role in development of diabetic nephropathy and all of the diabetes related complications^[8].

DR is a pathology characterized by microangiopathy and ischemic retinal angiogenesis induced by the activation of proinflammatory cytokines IL-8 and TNF- α ^[9,10]. The goal of this study is to measure the IL-8 and TNF - α levels in vitreous samples from patients undergoing pars plana vitrectomy (PPV) due to DR, to compare these measurements with those of the control group, and to demonstrate their impact on DR pathogenesis.

SUBJECTS AND METHODS

Fifty-seven patients with diabetic retinopathy diagnosis at T. C. Istanbul Bilim University Medical School Department of Ophthalmology, who were to undergo the operation formed the study group and the control group consisted of 22 macular hole cases that did not have proliferative vitreoretinopathy.

All of the patients diagnosed with PDR were high risk proliferative PDR patients. Vitrectomy indications for PDR patients were tractional retinal detachment associated with vitreous hemorrhage, tractional retinal detachment not associated with vitreous hemorrhage, and macular edema presenting with tractional and proliferative membrane. All of the diabetes patients were selected from type-II diabetics. All cases in the study group underwent a 3-port 20 gauge pars plana vitrectomy (PPV) operation. The mean age for the patients included in the study group and the control group were 65.92 ± 6.18 and 64.32 ± 5.22 , respectively ($P < 0.05$). The goal was to eliminate the impact of age on the parameters and to have both groups evaluated under identical conditions.

While enrolling patients in the study and the control group, presence of any additional macular pathologies like age related macular degeneration that could impact vitreous IL-8 and TNF- α levels, history of ocular inflammation, and history of laser photocoagulation application within the past three months were checked. If any of these conditions existed, the patients were excluded from the study.

A detailed preoperative ophthalmological examination was performed on all participants and the comprehensive history of each patient was examined. Presence of ocular trauma history, glaucoma, uveitis sequelae or other ocular pathologies were used as exclusion criteria. The goal was to compare the IL-8 and TNF- α levels in diabetic retinopathy pathology with those of the control group.

Vitreous sample collection and storage Vitreous samples of 0.5mL were aspirated with vitrector at the beginning of the PPV operation before the intraocular infusion and being diluted. The aspirated samples were immediately placed in sterile Eppendorf tubes. Samples were protected from sunlight and transferred to the freezer at -70°C , as soon as possible. All samples were taken by the same surgeon. No complications developed due to extracting vitreous in any of the operations. The results of IL - 8, and TNF - α were calculated in pg/mL.

Vitreous IL - 8 and TNF - α quantitative analysis methods The quantitative analysis of IL-8 and TNF- α in the vitreous samples taken were performed using the ELISA (Enzyme-linked immunosorbent assay) method, *via* human TNF- α measurement kit (AviBion, Helsinki, Finland) and human IL-8 measurement kit (AviBion, Helsinki, Finland) following the manufacturer's application guidelines

Statistical Analysis Data from the study and the control group are reported as mean, median, standard deviation, minimum and maximum values, numbers and percentages where appropriate. The alpha level of significance was set at 0.01. SPSS version 12 (SPSS Inc., Chicago, IL) was used for statistical analysis. Variance analysis was conducted for multivariate comparisons. T-test was used to compare the TNF- α and IL-8 levels between the control group and the diabetic retinopathy group.

RESULTS

A total of 79 patients were included in the study; 57 of which with diabetic retinopathy and a decision for operation were assigned to the study group and 22 with a macular hole were assigned to the control group. The gender distribution among the cases with diabetes was 23 (40.35%) females and 34 (59.65%) males, and 12 (55%) females and 10 (45%) males among the control group cases.

IL-8 and TNF- α parameters in the vitreous samples of all cases were investigated using the ELISA method. In the vitreous samples obtained during vitrectomy, IL - 8 level [82.7891 \pm 74.08700(0.08-307.09) pg/mL] and the TNF- α level [18.0007 \pm 13.90015(2.32-51.11) pg/mL] in the DR group were significantly higher than the IL-8 level [2.9805 \pm 3.77546 (0.08 - 18.53) pg/mL] and the TNF - α level [1.7005 \pm 1.26949 (0.1 - 5.17) pg/mL] obtained in the control group ($P < 0.001$). These findings are presented in Table 1.

No correlation was found between the TNF- α and IL-8 levels of all patients and the DR patients. The scatter diagrams of TNF- α and IL-8 levels in vitreous are displayed in Figure 1A and B.

Table 1 TNF- α vs IL-8 mean, standart deviation and mean standart error values in diabetic retinopathy and control group

| Parameters | n | Mean | Std. deviation | Std. error |
|---------------|----|---------|----------------|------------|
| TNF- α | | | | |
| DR | 57 | 18.0007 | 13.90015 | 1.84112 |
| Control | 22 | 1.7005 | 1.26949 | 0.27066 |
| IL-8 | | | | |
| DR | 57 | 82.7891 | 74.08700 | 9.81306 |
| Control | 22 | 2.9805 | 3.77546 | 0.80493 |

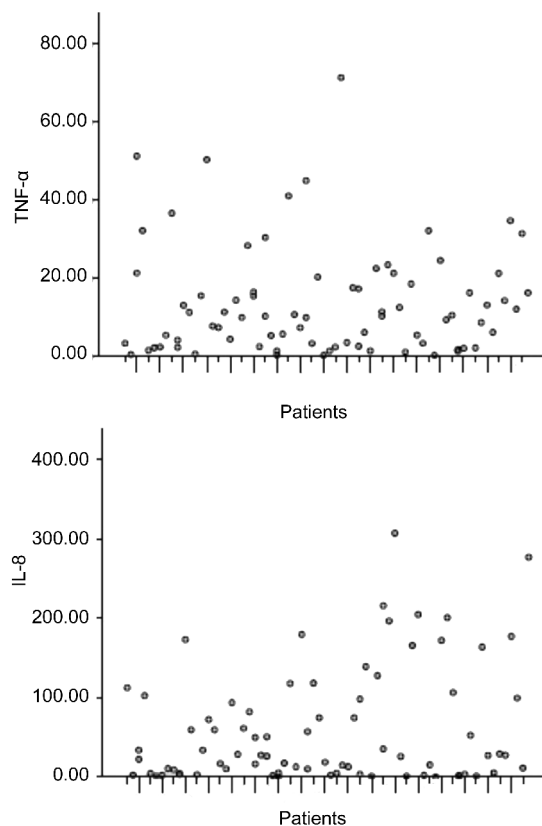


Figure 1 Scatter diagram of TNF - α (A) and IL - 8 (B) amounts in patient's vitreous samples.

DISCUSSION

This study investigated the association between vitreous IL-8 and TNF - α levels and diabetic retinopathy. The results indicate that the vitreous IL - 8 and TNF - α levels are significantly higher among the diabetic retinopathy patients, compared to the control group.

Some of the serum components that enter the vitreous as a result of deterioration of the blood retinal barrier are shown to contribute to fibrovascular membrane formation^[11-13]. Mediators released from the ischemic retinal regions are shown to be responsible for proliferative effect and neovascularization^[11,14,15]. IL - 8, which is an inflammatory and angiogenic mediator, is shown to be produced from glial and endothelial cells in the retina as a result of angiogenesis occurring in ischemic conditions^[4,5]. A relationship between the gliotic occlusion of major vessels in the retina and vitreous IL-8 levels was determined^[16]. Previous studies have shown

that human recombinant IL-8 leads to development of neovascularization in rabbit cornea^[17]. Aksünger *et al*^[18]'s study demonstrated that IL-8 levels were high in vitreous samples of patients with PDR.

Neutrophils are enabled to bond to endothelial cells *via* IL-8 stimulation and to enter the parenchyma with increased $\beta 2$ integrin expression. PDR is characterized by the impairment of the blood retina barrier due to loss of pericytes and endothelial cells of the retinal microvascular structures. In PDR, membranous structures from the retinal tissue to vitreous are observed. In vitreous samplings, IL-8 is observed to be high when CXCL-10 is inactive while PDR is active^[19, 20]. While IL-8 has angiogenic effects, CXCL-10 has angiostatic effects. Both antagonistic cytokines peak at different phases of the disease. IL-8 expression is observed mainly in vascular endothelial cells and retinal glial cells. In hypoxia, neovascularization is activated with IL-8 and VEGF synthesis from glial cells^[21].

In our previous study, we investigated to determine intravitreal IL-8 level in patients with non-complicated acute RD which induces cellular proliferation and inflammation, and, it was reported that intravitreal IL-8 increases may related to inflammation after retinal detachment^[22]. The high levels of IL-8, which has chemotactic and angiogenic effects and is common in proliferative ocular diseases, in vitreous samples of PDR patients shows that IL-8 may play a role in the pathogenesis of PDR^[17, 18]. In line with findings of other studies, IL-8 levels of the patients with proliferative diabetic retinopathy, compared to the control group, were found to be significantly higher in our study.

TNF- α is an important cytokine that causes immune, metabolic, and inflammatory events, and plays a role in neovascular formations. TNF system effects the pathogenesis of some aspects of the insulin resistance syndrome through cellular mechanisms caused by TNFR1, the dominant one of the two TNF- α receptor types; TNFR1 (type 1) and TNFR2 (type 2). Recent studies show that mutations in the TNFR1 gene play an important role in type 2 DM pathogenesis^[23]. In type 2 DM and its associated microvascular complications, TNF- α has important functions such as stimulating growth, cytotoxicity, and angiogenesis.

Mononuclear phagocytes are the source of TNF and TNF is a local paracrine and autocrine regulator for leukocytes and endothelial cells in low concentrations. It has been previously reported that TNF- α is expressed in human retina during proliferative eye diseases but the mechanism of TNF- α 's impact on retinal neovascularization is not fully explained yet^[24-26]. Li *et al*^[27] and Elner *et al*^[28] were stated that in face of a ischemic condition, TNF- α could be one of the

factors triggering the cytokine cascade and inducing retinal neovascularization. The observations of TNF- α -dependent IL-8 induction in retinal cells shows that the increase in the IL-8 levels in the vitreous fluid due to ischemic retina may be associated with TNF- α upregulation. These two inflammatory cytokines that we examined the vitreous levels of in our study can be considered determinative risk factors in development of proliferative DR. In our study, we also aimed at examining the vitreous TNF- α and IL-8 relationship in PDR etiopathogenesis and to guide further studies that can form novel treatment alternatives in PDR treatment via blockage of these cytokines.

Consequently, it is inevitable that the DM related changes in cytokine levels will be reflected in the vitreous due to the adverse affects that diabetes has on the inner blood retina barrier. Our findings show that the inflammatory and angiogenic mediator IL-8 may be associated with the progression of DR into PDR. The observations of TNF- α -dependent IL-8 induction in retinal cells shows that the increase in the IL-8 levels in the vitreous fluid due to ischemic retina may be associated with TNF- α upregulation. Further studies are needed to investigate the relationship between DR and cytokines.

REFERENCES

- 1 Koskela UE, Kuusisto SM, Nissinen AE, Savolainen MJ, Liinamaa MJ. High vitreous concentration of IL-6 and IL-8, but not of adhesion molecules in relation to plasma concentrations in proliferative diabetic retinopathy. *Ophthalmic Res* 2013;49:108-114
- 2 Pichert A, Schlorke D, Franz S, Arnholt J. Functional aspects of the interaction between interleukin-8 and sulfated glycosaminoglycans. *Biomater* 2012;23:142-148
- 3 Van Kaer L, Rabacal WA, Scott Algood HM, Parekh VV, Olivares-Villagómez D. *In vitro* induction of regulatory CD4⁺CD8 α ⁺ T cells by TGF- β , IL-7 and IFN- γ . *PLoS One* 2013;8:e67821
- 4 Yuuki T, Kanda T, Kimura Y, Kotajima N, Tamura J, Kobayashi I, Kishi S. Inflammatory cytokines in vitreous fluid and serum of patients with diabetic vitreoretinopathy. *J Diabetes Complications* 2001;15:257-259
- 5 Hernandez C, Segura RM, Fonollosa A, Carrasco E, Francisco G, Simo R. Interleukin-8, monocyte chemoattractant protein-1 and IL-10 in the vitreous fluid of patients with proliferative diabetic retinopathy. *Diabetes Med* 2005;22:719-722
- 6 Emral R. Adiponectin and other cytokines. *Turkiye Klinikleri J Med Sci* 2006;26:409-420
- 7 Abbas AK, Lichtman AH, Poper JS. Cytokines. Cellular and Molecular Immunology Philadelphia; WB Saunders Company 1994; 240-261
- 8 Navarro JF, Mora C, Maca M, Garca J. Inflammatory parameters are independently associated with urinary albumin in type 2 diabetes mellitus. *Am J Kidney Dis* 2003;42:53-61
- 9 McCarter RJ, Hempe JM, Gomez R, Chalew SA. Biological variation in HbA1c predicts risk of retinopathy and nephropathy in type 1 diabetes. *Diabetes Care* 2004;27:1259-1264

- 10 Yokoi M, Yamagishi SI, Takeuchi M. Elevations of AGE and vascular endothelial growth factor with decreased total antioxidant status in the vitreous fluid of diabetic patients with retinopathy. *Br J Ophthalmol* 2005;89:673-675
- 11 Tomic M, Ljubic S, Kastelan S. The role of inflammation and endothelial dysfunction in the pathogenesis of diabetic retinopathy. *Coll Antropol* 2013;37:51-57
- 12 Or C, Cui J, Matsubara J, Forooghian F. Pro-inflammatory and anti-angiogenic effects of bisphosphonates on human cultured retinal pigment epithelial cells. *Br J Ophthalmol* 2013;97:1074-1078
- 13 de Boer JH, Hack CE, Verhoeven JA, Barsma GS, de Jong PT, Rademabers AJ, de Vries - Knoppert WA, Rothova A, Kijlstra A. Chemoattractant and neutrophil degranulation activities related to interleukin-8 in vitreous fluid in uveitis and vitreoretinal disorders. *Invest Ophthalmol Vis Sci* 1993;34:3376-3385
- 14 Heng LZ, Comyn O, Peto T, Tadros C, Ng E, Sivaprasad S, Hykin PG. Diabetic retinopathy: pathogenesis, clinical grading, management and future developments. *Diabet Med* 2013;30:640-650
- 15 Woo SJ, Ahn SJ, Ahn J, Park KH, Lee K. Elevated systemic neutrophil count in diabetic retinopathy and diabetes; a hospital-based cross-sectional study of 30,793 Korean subjects. *Invest Ophthalmol Vis Sci* 2011;52:7697-7703
- 16 Petrovic M. G, Korosec P, Kosnik M, Hawlina M. Vitreous levels of interleukin-8 in patients with proliferative diabetic retinopathy. *Am J Ophthalmol* 2007;143:175-176
- 17 Ghasemi H, Ghazanfari T, Yaraee R, Faghihzadeh S, Hassan ZM. Roles of IL-8 in ocular inflammations: a review. *Ocul Immunol Inflamm* 2011;19:401-412
- 18 Aksünger A, Akbatur H. H, Or M, Güven D, Okur H, Hasanreisöglü B. The Role of Interleukin 8 Neuroleptic malignant syndrome in advanced proliferative diabetic retinopathy. *Retina-vitreus* 1994;2:63-66
- 19 Hooks JJ, Nagineni CN, Hooper LC, Hayashi K, Detrick B. IFN- β provides immuno-protection in the retina by inhibiting ICAM-1 and CXCL9 in retinal pigment epithelial cells. *J Immunol* 2008;180:3789-3796
- 20 Cohen J, Sundar K, Bleich D. Pathogenesis of type 1 diabetes: regulation of adhesion molecules and immune cell trafficking. *Curr Immunol Reviews* 2007;3:87-100
- 21 Aksünger A, Or M, Okur H, Hasanreisöglü B, Akbatur H. Role of interleukin 8 in the pathogenesis of proliferative vitreoretinopathy. *Ophthalmologica* 1997;211:223-225
- 22 Rasier R, Gormuş U, Artunay O, Yuzbasioğlu E, Oncel M, Bahcecioglu H. Vitreous levels of VEGF, IL-8, and TNF-alpha in retinal detachment. *Curr Eye Res* 2010;35:505-509
- 23 Vendrell J, Broch M, Fernandez-Real JM. Tumour necrosis factor receptors (TNFRs) in type 2 diabetes. Analysis of soluble plasma fractions and genetic variations of TNFR2 gene in a case-control study. *Diabet Med* 2005;22:387-392
- 24 Limb GA, Hollifield RD, Webster L, Charteris DG, Chignell AH. Soluble TNF receptors in vitreoretinal proliferative disease. *Invest Ophthalmol Vis Sci* 2001;42:1586-1591
- 25 Gustavsson C, Agardh CD, Agardh E. Profile of intraocular tumour necrosis factor-alpha and interleukin-6 in diabetic subjects with different degrees of diabetic retinopathy. *Acta Ophthalmol* 2013;91:445-452
- 26 Demircan N, Safran BG, Soyulu M, Ozcan AA, Sizmaz S. Determination of vitreous interleukin-1 (IL-1) and tumour necrosis factor (TNF) levels in proliferative diabetic retinopathy cytokines in proliferative diabetic retinopathy. *Eye* 2006;20:1366-1369
- 27 Li S, Fu XA, Zhou XF, Chen YY, Chen WQ. Angiogenesis-related cytokines in serum of proliferative diabetic retinopathy patients before and after vitrectomy. *Int J Ophthalmol* 2012;5:726-730
- 28 Yoshida A, Yoshida S, Khalil AK, Ishibashi T, Inomata H. Role of NF-kappaB-mediated interleukin-8 expression in intraocular neovascularization. *Invest Ophthalmol Vis Sci* 1998;39:1097-1106