

A case of branch retinal artery obstruction complicated after anterior ischemic optic neuropathy

Ungsoo Samuel Kim, Hyoung Seok Kim, Young Ju Lew

Department of Ophthalmology, Kim's Eye Hospital, Konyang University College of Medicine, Seoul, Korea

Correspondence to: Ungsoo Samuel Kim. Department of Ophthalmology, Kim's Eye Hospital, Konyang University College of Medicine, Youngdeungpo 4th 156, Youngdeungpo-gu, Seoul, Korea. ungsookim@kimeye.com

Received:2011-06-29 Accepted:2011-07-20

Abstract

• **AIM:** To report a case of branch retinal artery obstruction (BRAO) complicated after anterior ischemic optic neuropathy (AION).

• **METHODS:** A 42-year-old woman who complained of visual disturbance was performed ophthalmological examinations such as fundus photography, fluorescent angiography (FAG) and visual field test.

• **RESULTS:** At first visit, disc swelling was noted and arterial circulation was intact, however, 1 week after onset, the inferior branch retinal artery began to shrink and the flame hemorrhage intensified. Sixteen months later, the optic disc evidenced an atrophic change; additionally, a ghost vessel in the inferior branch retinal artery was found.

• **CONCLUSION:** We report a case of complications of BRAO arising after AION which caused the mechanical compression on the arterial circulation.

• **KEYWORDS:** anterior ischemic optic neuropathy; branch retinal artery obstruction; complication; fluorescent angiography

DOI:10.3969/j.issn.1672-5123.2011.09.005

Kim US, Kim HS, Lew YJ. A case of branch retinal artery obstruction complicated after anterior ischemic optic neuropathy. *Gugji Yanke Zazhi* (*Int J Ophthalmol*) 2011;11(9):1511-1513

INTRODUCTION

Many etiologies have been reported for branch retinal artery obstruction (BRAO). Most cases of this condition are related to embolus, trauma, coagulopathy, and collagen-vascular diseases, as well as a variety of miscellaneous conditions; however, BRAO is rarely related to optic nerve disease, and few such cases have been reported thus far^[1,2]. Therefore, we report a case of complications of BRAO arising after anterior ischemic optic neuropathy (AION).

CASE REPORT

A 42 year-old woman complained of visual defect. Her best-corrected visual acuity was 20/40 in the right eye and 20/25 in the left eye. The 24-2 Humphrey visual field test showed a superior altitudinal visual field defect in the right eye. Fundus examination showed a markedly swollen optic disc and splinter hemorrhage in the inferior rim of the disc; the arterial phase of fluorescent angiography (FAG) revealed a filling defect in the inferior area of the disc and no abnormal leaking or obstruction of arterial circulation (Figures 1A and 1B).

We conducted orbit magnetic resonance imaging (MRI) and magnetic resonance angiography to rule out compressive optic neuropathy and vascular abnormalities; however, no abnormalities were observed on the MRI. The erythrocyte sediment rate (ESR) and C-reactive protein (CRP) measurements were 1mm/hour and 0.02 (<0.30) respectively. One week later, the inferior branch retinal artery began to shrink and the flame hemorrhage intensified (Figures 1C and 1D). The visual acuity of the right eye was reduced to 20/100.

Sixteen months later, best-corrected visual acuity was 20/40 in the patient's right eye. The optic disc evidenced an atrophic change; additionally, a ghost vessel in the inferior branch retinal artery and a retinal hemorrhage at the margin of ischemic area were noted. FAG revealed total obstruction of the inferior branch retinal artery and venous filling was observed in the late phase by collateral circulation (Figure 2).

DISCUSSION

BRAO complicated with optic nerve disease is a very rare condition. Although Perkins *et al*^[3] previously reported an association between central retinal artery obstruction (CRAO) and AION, the patient had a five-month interval between the two diseases. Several reports of BRAO occurring in conjunction with AION have been reported; however, in the majority of cases these conditions occur simultaneously as the result of hemodynamic dysfunctions such as cavernous sinus thrombophlebitis, polyarteritis nodosa, and giant cell arteritis^[4,5]. The diagnosis of giant cell arteritis is based on laboratory tests including ESR and CRP, and was confirmed via temporal artery biopsy. The case described in this work evidenced normal ESR and CRP. The patient had not complained of headache and tenderness around the temporal

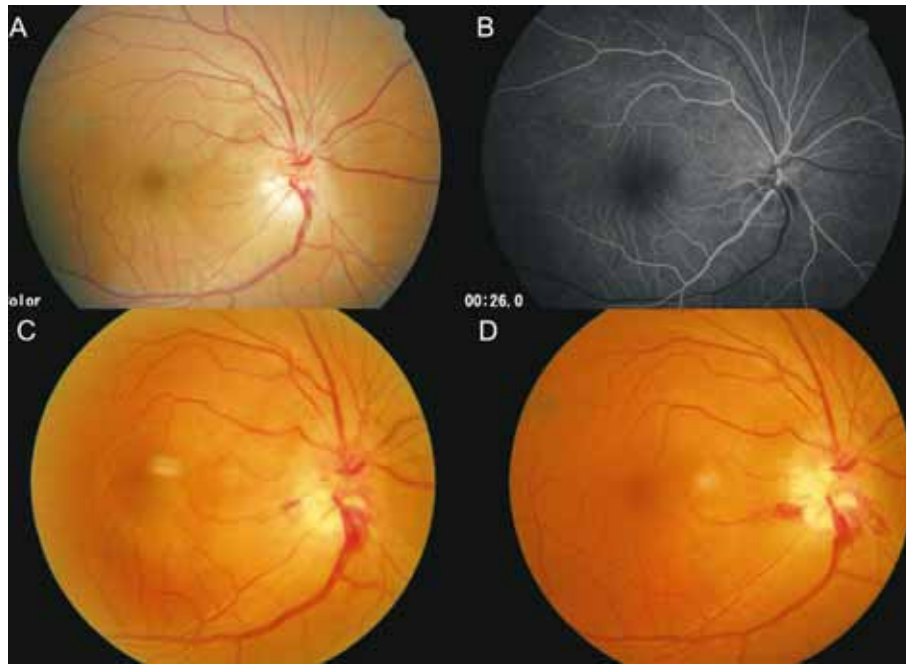


Figure 1 A: The disc swelling and flame-shaped disc hemorrhage were noted; B: Arterial filling was normal and hypofluorescent area was revealed in the inferior rim of disc; C: 1 week after onset, the inferior retinal vein engorgement and narrowing of the inferior retinal artery were noted; D: 3 weeks later, the venous engorgement was decreased and retinal artery was almost shrunken.

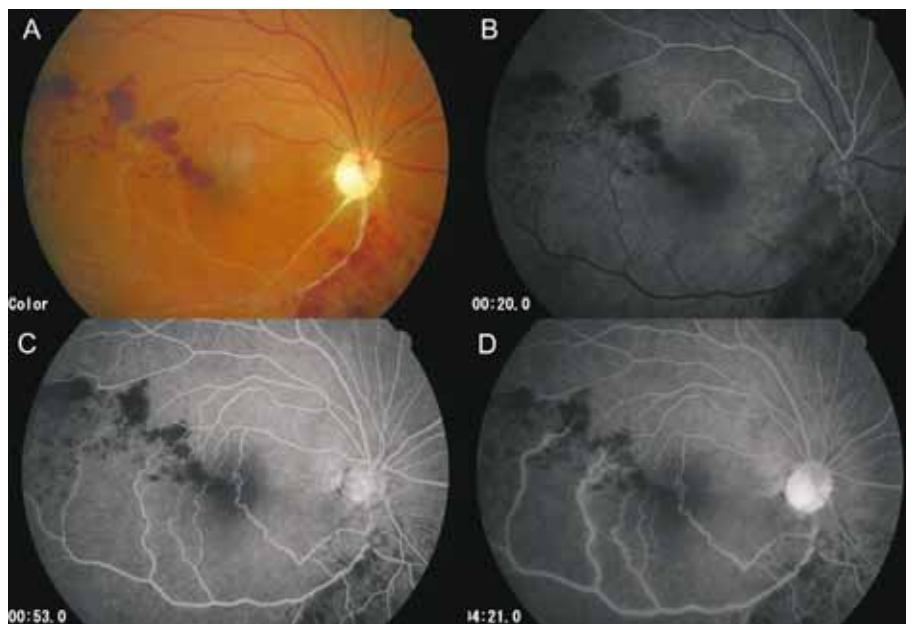


Figure 2 A: Inferior branch retinal artery was changed into a ghost vessel; B: Total filling defect was found in the inferior branch retinal artery; C and D: Venous filling was built up by collateral circulation in the late phase.

area. She had no systemic symptoms suggestive of polyarteritis nodosa such as malaise, weight loss, or Raynaud's phenomenon. In cases of AION, disc swelling is the most characteristic feature and severe optic disc swelling may be sufficient to compress the retinal artery. In the present case, therefore, BRAO may have resulted from the mechanical compressive effect on retinal artery circulation around the optic disc owing to the severe optic disc swelling inherent to anterior ischemic optic neuropathy.

REFERENCES

1 Gupta A, Jalali S, Bansal RK, Grewal SP. Anterior ischemic optic neuropathy and branch retinal artery occlusion in cavernous sinus

thrombosis. *J Clin Neuroophthalmol* 1990;10(3):193-196

2 Williams GC, Lee AG, Adler HL, Coburn A, Rosas AL, Tang RA, Scardino PT. Bilateral anterior ischemic optic neuropathy and branch retinal artery occlusion after radical prostatectomy. *J Urol* 1999;162(4):1384-1385

3 Perkins SA, Magargal LE, Maizel RD, Robb-Doyle E. Resolved incomplete central retinal-artery obstruction simulating ischemic optic neuropathy. *Ann Ophthalmol* 1988;20(2):61-63

4 Hayreh SS, Podhajsky PA, Zimmerman B. Ocular manifestations of giant cell arteritis. *Am J Ophthalmol* 1998;125(4):509-520

5 Emad Y, Basaffar S, Ragab Y, Zeinhom F, Cheita T. A case of polyarteritis nodosa complicated by left central retinal artery occlusion, ischemic optic neuropathy, and retinal vasculitis. *Clin Rheumatol* 2007;26(5):814-816

前部缺血性视神经病变并发视网膜分支动脉阻塞 1 例

Ungsoo Samuel Kim, Hyoung-Seok Kim, Young Ju Lew
(作者单位:韩国首尔, Konyang 大学医学院, Kim 眼科医院眼科)
通讯作者: Ungsoo Samuel Kim. ungsokim@kimeye.com

摘要

目的: 报告 1 例前部缺血性视神经病变 (anterior ischemic optic neuropathy, AION) 并发视网膜分支动脉阻塞 (branch retinal artery obstruction, BRAO)。

方法: 患者, 女, 42 岁, 因视力障碍进行如下眼科检查: 眼

底照相、荧光血管造影 (fluorescent angiography, FAG) 和视野测试。

结果: 第一次就诊时, 患者视盘肿胀, 动脉循环完整, 发病 1wk 后, 视网膜下支动脉开始萎缩并火焰状出血加剧。16mo 后, 视盘呈萎缩性改变, 此外, 发现视网膜下分支动脉血管影一条。

结论: AION 并发 BRAO 可造成动脉循环的机械性压迫。

关键词: 前部缺血性视神经病变; 视网膜分支动脉阻塞; 并发症; 荧光血管造影

Letter from Prof. G. O. H. Naumann, Immediate Past-President of ICO

Dear President and Chief Editor!

Dear Colleague Prof. Xiu-Wen Hu!

Thank you so much for your kind email of February 25, 2011. I congratulate you that your Journal was accepted for coverage by the SCIE.

Following your request I send you for your new section "Introduction to the World Leading Ophthalmologists" as attachment

1. Abbreviated curriculum vitae
2. 10 pictures outlining the contributions from our group. Thank you so much for your interest.

We also cherish the memories of our meeting at the WOC 2010 in Berlin.

Looking forward to the next opportunity to meet again, I remain

Sincerely Yours

G. O. H. Naumann, MD, ML, FRCOphth. (Hon.)
Immediate Past-President International Council Ophthalmology
Professor Emeritus Department of Ophthalmology
University Erlangen-Nürnberg
Schwabachanlage 6 (Kopfkrlinikum)
D-91054 Erlangen/Germany